

# Transcirculation microballoon-assisted coil embolization for dorsal pancreatic artery aneurysm due to celiac artery dissection: A case report

SAGE Open Medical Case Reports  
Volume 9: 1–5  
© The Author(s) 2021  
Article reuse guidelines:  
sagepub.com/journals-permissions  
DOI: 10.1177/2050313X20987340  
journals.sagepub.com/home/sco



Yuki Takara<sup>1</sup>, Daisuke Yunaiyama<sup>1</sup> , Toru Saguchi<sup>1</sup>,  
Natsuhiko Shirota<sup>1</sup>, Takafumi Yamada<sup>1</sup>, Junetsu Akasaka<sup>2</sup>  
and Kazuhiro Saito<sup>1</sup>

## Abstract

The dorsal pancreatic artery is a part of peripancreatic arcade connecting celiac artery to transpancreatic artery. A dorsal pancreatic artery aneurysm derived from dissection of celiac artery is a rare pathology, and it sometimes requires ingenious strategy in an endovascular surgery. Hereby, we report a case of a patient who underwent coil embolization for dorsal pancreatic artery aneurysm due to celiac artery dissection by applying transcirculation approach of a balloon catheter through the peripancreatic arcade, which was successfully achieved.

## Keywords

Transcirculation approach, microballoon-assisted coil embolization, dorsal pancreatic artery aneurysm, celiac artery dissection

Date received: 12 November 2020; accepted: 17 December 2020

## Introduction

The balloon-assist coil embolization for the purpose of remodeling a neck of an aneurysm, protecting coil migration, or achieving tight packing have been described.<sup>1–3</sup> Transcirculation approach is a technique of inserting a balloon catheter through the Circle of Willis to perform neck remodeling of an aneurysm in the neurosurgical embolization procedure. This technique was first described by Moret et al.<sup>4</sup> as a retrograde approach, and its safety and efficacy have also been reported.<sup>5</sup> However, to the best of our knowledge, the transcirculation approach for endovascular embolization of visceral aneurysms has not been reported. We report a case in which coil embolization was successfully performed for a dorsal pancreatic artery (DPA) aneurysm (DPAA) associated with celiac artery (CA) dissection by applying transcirculation approach of a balloon catheter through the peripancreatic arcade.

## Case presentation

A 40-year-old man was referred to gastrointestinal surgeons for pancreatic mass pointed out by an abdominal

ultrasonography in a medical check-up. The patient did not show any symptoms. Abdominal contrast-enhanced computed tomography (CT) revealed dissection from the CA (Figure 1(a)), DPA, and splenic artery (SA). This aneurysm was not seen on an abdominal unenhanced CT taken 6 years ago in a medical check-up. The enhancing inner lumen of the DPA was derived from false lumen and that of the SA was derived from true lumen. The stenosis of proximal side of SA, an aneurysm measuring 2.5 cm on DPAA with unenhanced mural thrombus, and the connection of the distal side of the DPAA to transverse pancreatic artery (TPA) with stenotic change were confirmed (Figure 1(b)). A connection with DPA and the superior mesenteric artery (SMA) was undetermined. The current diagnosis was the

<sup>1</sup>Department of Radiology, Tokyo Medical University, Shinjuku-ku, Tokyo, Japan

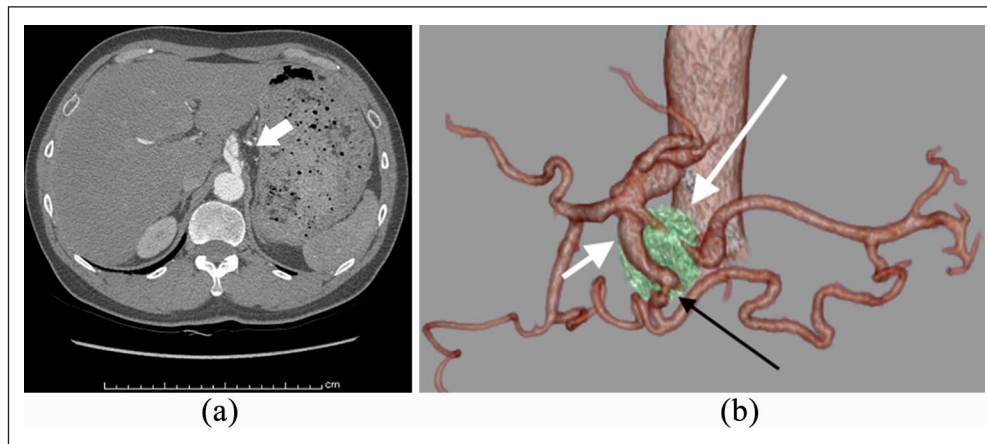
<sup>2</sup>Department of Cardiovascular Surgery, Tokyo Medical University Hachioji Medical Center, Hachioji, Japan

### Corresponding Author:

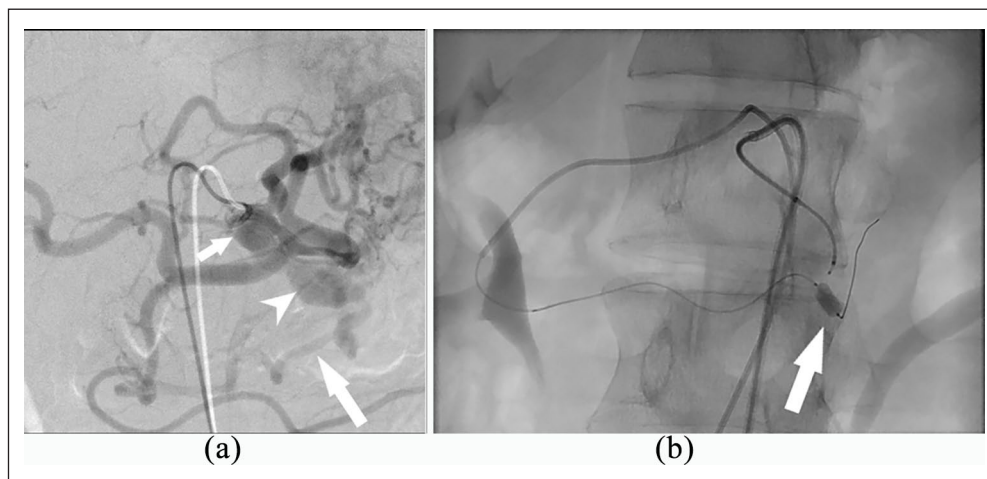
Daisuke Yunaiyama, Department of Radiology, Tokyo Medical University, 6-7-1 Nishishinjuku, Shinjuku-ku, Tokyo 160-0023, Japan.

Email: yuunai@tokyo-med.ac.jp





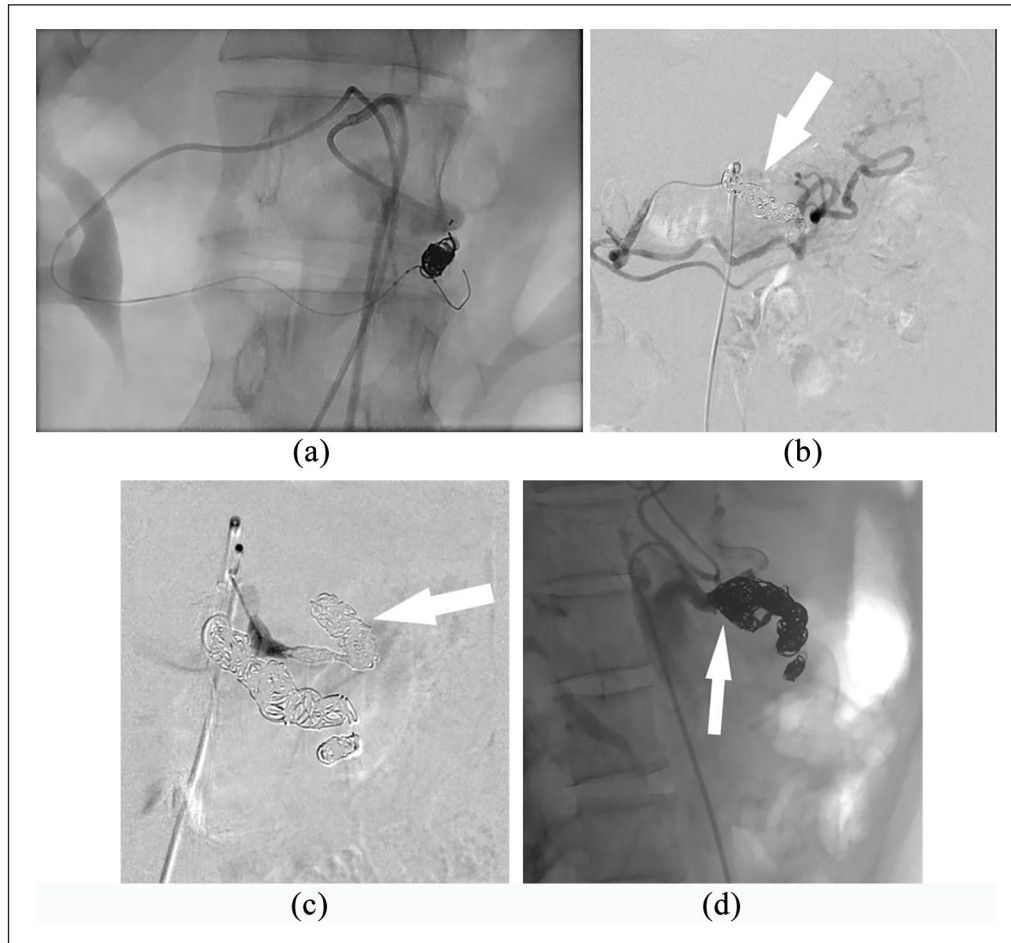
**Figure 1.** An axial CT image of arterial phase demonstrates the dilated celiac artery with a flap that implies the dissection (arrow) (a). Three-dimensionally reformatted CT image of arterial phase demonstrates the stenosis of the proximal side of SA (large white arrow), enhancing inner lumen of dorsal pancreatic artery aneurysm (small arrow), stenotic connection between dorsal pancreatic artery aneurysm and transverse pancreatic artery (arrowhead), and unenhanced mural thrombus (green area).



**Figure 2.** An angiography from celiac artery demonstrates the dilated celiac artery (arrow) and dorsal pancreatic artery (arrowhead) that connects to the transverse pancreatic artery (large arrow) (a). A balloon catheter was inflated at the sufficient point of the dorsal pancreatic artery (b, arrow).

dissection of the CA to DPA and SA, resulting in DPAA and SA stenosis. After the diagnosis was made, the patient was referred to the department of radiology by a vascular surgeon for the consultation of endovascular surgery to prevent aneurysm rupture because open surgery was thought to be quite invasive as it required distal pancreatectomy with splenectomy and CA repair. He had received medications for hypertension. There were no remarkable findings in his initial laboratory data. We planned to embolize DPAA, SA, and dissected area of CA that allow to preserve vascular supply to hepatic artery from SMA via peripancreatic arcade and to distal side of SA via gastroduodenal artery (GDA) to TPA. An angiography from the CA revealed the enhancing inner lumen of DPAA from false lumen of dissected CA connecting to TPA (Figure 2(a)).

TPA was revealed between the peripancreatic arcade from GDA and pancreatic tail artery that connected to the distal side of SA. A 4.5 Fr. Shepherd hook-type guiding sheath (Parent Plus 45: Medikit, Tokyo, Japan), carrying a triple coaxial system, consisted of a 4 Fr. intermediate catheter (Cerulean G: Medikit, Tokyo, Japan), 2.6 Fr. high-flow catheter (Masters HF: Asahi Intech, Aichi, Japan), 1.9 Fr. microcatheter (Carnelian Marvel: Tokai Medical Products, Aichi, Japan), was hooked on the CA. To prevent the coil migration into the TPA, a microballoon catheter (Logos: Piolax, Yokohama, Japan) was advanced to the distal side of the DPAA via the GDA to pancreatoduodenal artery and inflated at the sufficient point of the TPA through the additional 4 Fr. shepherd hook catheter placed in the CA from the contralateral groin site (Figure 2(b)). The 4.5 Fr



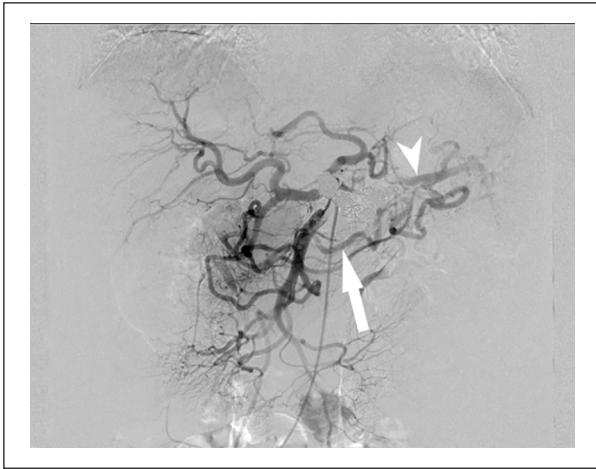
**Figure 3.** The coil embolization was performed at the distal side of dorsal pancreatic aneurysm with the assist of a balloon catheter (a). Coil embolization of the aneurysm and the proximal side of the dorsal pancreatic artery was performed (b, arrow). The splenic artery coil embolization was performed (c, arrow). The celiac artery coil embolization was performed (d, arrow).

guiding sheath and the 4 Fr. Shepherd hook catheter were inserted from the right and left side of the common femoral artery, respectively. Under microballoon catheter inflation, the distal side of the DPAA was embolized with detachable coils (PRESIDIO 6 mm  $\times$  20 cm, GALAXY 6 mm  $\times$  15 cm) through a 1.9 Fr microcatheter (Figure 3(a)). Afterward, the microballoon catheter was deflated. Then, intra-aneurysmal coil embolization was performed with detachable coils (Interlock-35 10 mm  $\times$  40 cm, 2 of 8 mm  $\times$  40 cm, 6 mm  $\times$  20 cm) through the 4 Fr. intermediate catheter (Figure 3(b)). Later, the microcatheter in the intermediate catheter was carefully advanced through the dissected portion of the SA and embolization of the affected area was performed with detachable coils (Penumbra POD 6 mm  $\times$  50 cm, Penumbra 6 mm  $\times$  15 cm, 4 mm  $\times$  8 cm, GALAXY 2 of 7 mm  $\times$  21 cm, 2 of 4 mm  $\times$  15 cm) (Figure 3(c)). Finally, coil embolization of the dissected CA was performed using detachable coils (Interlock-35 10 mm  $\times$  40 cm, 2 of 8 mm  $\times$  40 cm, 6 mm  $\times$  10 cm, 4 mm  $\times$  10 cm, 6 mm  $\times$  10 cm, Penumbra coil 400 2 of 10 mm

$\times$  30 cm) (Figure 3(d)). The final angiography from SMA after pulling out all the systems revealed complete occlusion of the DPAA, the proximal side of SA, preserving GDA to the TPA to the distal side of SA and preserving GDA to common hepatic artery to left gastric artery (Figure 4). No complication including post-coiling ischemia or transient laboratory abnormalities in transaminases, amylases, or lipase was observed during and after the endovascular surgery. The patient was followed up for 2 years at the near hospital; however, DPAA has not shown regrowth by contrast enhancement CT.

## Discussion

This case report is the first in which coil embolization was successfully performed for a DPAA associated with CA dissection by applying transcirculation approach, which is used in neurointervention area. The balloon was placed at the confluence of DPA and TPA covering the exit of DPA through the peripancreatic arcade. The reasons are as follows: there



**Figure 4.** The angiogram after finishing coil embolization and pulling out the balloon catheter from the superior mesenteric artery demonstrates preserving the transverse pancreatic artery (arrow) and the distal side of splenic artery (arrowhead).

was not enough length to inflate balloon at the distal side of DPAA by inserting the balloon catheter through the DPAA to perform significant embolization of the distal side of DPAA, and the diameter of DPA was smaller than TPA, so there was a risk of balloon dislocation from DPA to TPA during coil embolization if the balloon was inflated covering DPA to TPA. Hence, we had to insert balloon catheter to the confluence via the peripancreatic arcade in order to perform remodeling of the confluence. Moret et al. reported the retrograde approach in neurointervention that introduces catheters to the destination via collateral pathway like anterior communicating artery or posterior communicating artery.<sup>4</sup> By applying this technique, we introduced balloon catheter via the GDA to the peripancreatic arcade and TPA. The transcirculation approach for the purpose of the vessel plasty by a balloon catheter was feasible in this case. A collateral pathway of visceral artery is quite long way in the abdominal intervention compared with the neural intervention so that it requires sufficient device considerations to access the destination.

Takasaka et al. reported compact microcoil embolization under distal balloon inflation to create a sufficient resistance against the vascular wall to prevent migration.<sup>2</sup> The balloon that we placed at the confluence could create an effective resistance to prevent coil migration and pack the coils tightly. By combining these aforementioned techniques, the controlled coil embolization at the distal side of DPAA could be achieved safely and successfully. In addition, using a guiding sheath enables us to carry a coaxial system, which allows us to use the various size of the coils and advancing. Using a 4 Fr. intermediate catheter increases the back-up force during coil embolization.

A DPAA is an indication for a therapeutic procedure,<sup>6</sup> and the aneurysm in this case increased in size at least in 6 years; therefore, we performed endovascular surgery. A general

treatment strategy for a visceral aneurysm is an isolation technique with or without aneurysmal packing, or aneurysmal packing alone.<sup>7</sup> In this case, various connecting arteries might affect the aneurysm as an endoleak if isolation or aneurysmal packing alone were performed because DPA is one of the centers of the arterial network around pancreas that should have potential connecting arteries. Therefore, the isolation and aneurysmal packing were performed.

The DPAAAs reported previously were associated with a stenosis or occlusion of the CA<sup>8,9</sup> derived from median arcuate ligament syndrome or iatrogenic injury,<sup>10</sup> whereas there were no reported cases associated with dissection of the CA. To the best of our search, we were unable to find a report discussing the relationship between CA dissection and DPAAAs.

Under this consideration, this case is considered a very rare case of CA dissection to DPA and SA or segmental arterial mediolysis; however, we cannot determine because this patient did not undergo surgical repair.

## Conclusion

The coil embolization to DPAA, SA, and CA was successfully performed by a balloon assist technique through the collateral pathway to reach the distal side of dissection. Using the intermediate size of catheter in the guiding sheath enables radiologist to use various coils that may be appropriate for the target vessels.

## Acknowledgements

The authors would like to thank Enago ([www.enago.jp](http://www.enago.jp)) for English language editing.

## Declaration of conflicting interests

The author(s) declared no potential conflicts of interest with respect to the research, authorship, and/or publication of this article.

## Ethical approval

Our institution does not require ethical approval for reporting individual cases or case series.

## Funding

The author(s) received no financial support for the research, authorship, and/or publication of this article.

## Informed consent

Informed consent has been obtained from the patient for publication of the case report and accompanying images.

## ORCID iD

Daisuke Yunaiyama  <https://orcid.org/0000-0001-6576-5029>

## References

1. Moret J, Cognard C, Weill A, et al. The “Remodelling Technique” in the treatment of wide neck intracranial aneurysms.

- Angiographic results and clinical follow-up in 56 cases. *Interv Neuroradiol* 1997; 3(1): 21–35.
2. Takasaka I, Kawai N, Sato M, et al. Preoperative microcoil embolization of the common hepatic artery for pancreatic body cancer. *World J Gastroenterol* 2012; 18(16): 1940–1945.
  3. Yunaiyama D, Saguchi T, Moriya T, et al. Short-segment coil embolization using a double-balloon technique in an experimental vascular model. *Cardiovasc Intervent Radiol* 2017; 40(8): 1255–1260.
  4. Moret J, Ross IB, Weill A, et al. The retrograde approach: a consideration for the endovascular treatment of aneurysms. *AJNR Am J Neuroradiol* 2000; 21(2): 262–268.
  5. Roa JA, Ortega-Gutierrez S, Martinez-Galdamez M, et al. Transcirculation approach for endovascular embolization of intracranial aneurysms, arteriovenous malformations, and dural fistulas: a multicenter study. *World Neurosurg* 2020; 134: e1015–e1027.
  6. Chaer RA, Abularrage CJ, Coleman DM, et al. The society for vascular surgery clinical practice guidelines on the management of visceral aneurysms. *J Vasc Surg* 2020; 72(1S): 3S–39S.
  7. Lagana D, Carrafiello G, Mangini M, et al. Multimodal approach to endovascular treatment of visceral artery aneurysms and pseudoaneurysms. *Eur J Radiol* 2006; 59(1): 104–111.
  8. Uchiyama D and Yoshida S. Dorsal pancreatic artery aneurysm with celiac trunk occlusion. *Intern Med* 2012; 51(6): 667–668.
  9. Suzuki K, Kashimura H, Sato M, et al. Pancreaticoduodenal artery aneurysms associated with celiac axis stenosis due to compression by median arcuate ligament and celiac plexus. *J Gastroenterol* 1998; 33(3): 434–438.
  10. Kanazawa A, Tanaka H, Hirohashi K, et al. Pseudoaneurysm of the dorsal pancreatic artery with obstruction of the celiac axis after pancreatoduodenectomy: report of a case. *Surg Today* 2005; 35(4): 332–335.