

Masson's tumour of the kidney

S Van den Bogaert*, K Boel*, H Van Poppel*, R Oyen[†] and B Van Damme[‡]

Departments of *Urology, [†]Radiology and [‡]Pathology, University Hospitals, Herestraat 49,
B-3000 Leuven, Belgium

Corresponding address: Dr R Oyen, Department of Radiology, University Hospitals, Herestraat 49,
B-3000 Leuven, Belgium. E-mail: ravmond.oyen@uz.kuleuven.ac.be

Date accepted for publication 20 February 2002

Abstract

In 1923 Masson described a neo-plastic process consisting of papillary hyperplasia of the vascular endothelial cells, with a consequent obliteration of the vascular lumen, followed by degenerative changes. He introduced the term 'vegetant intravascular hemangioendothelioma'. However, these days it is more commonly known as papillary endothelial hyperplasia (PEH)^[1]. Although relatively rare, there are numerous accounts of PEH in literature, describing its predilection for the head and neck region. Our case report describes the finding of a PEH within the kidney; a site previously described only once in the literature.

Keywords: *Kidney neoplasms; kidney; CT; MR; kidney pseudotumor; diagnosis.*

Case report

A 64-year-old man was admitted to the hospital for resection of a sigmoid colon adenocarcinoma. He had no medical antecedents. Physical examination was normal. There was no flank mass or tenderness, nor cutaneous vascular lesions. Routine laboratory tests were normal. Renal ultrasound demonstrated a small rounded lesion in the centre of the left kidney (Fig. 1). The lesion was

slightly hyperechoic compared to the renal cortex. Color-coded duplex sonography demonstrated intralesional flow, with a resistance index of 0.69. Heterogeneous lesional enhancement was seen on contrast enhanced computed tomography (CT) (Fig. 2); the lesion was isodense on to the renal parenchyma on pre-contrast scans.

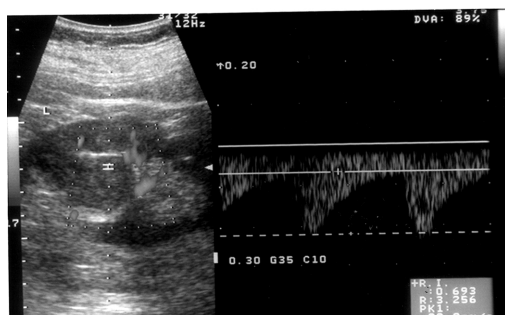


Figure 1 Color-coded duplex sonography, coronal plane. The lesion that is slightly hyperechoic compared to the renal parenchyma and Doppler spectrum demonstrates intralesional flow with a normal resistance pattern (resistance index 0.69).

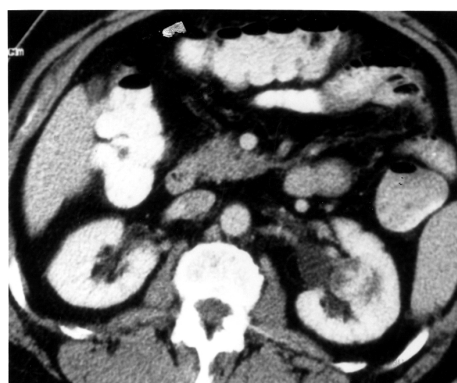

Figure 2 Contrast-enhanced CT, venous phase. A heterogeneous lesion is seen in the sinus of the left kidney.

This paper is available online at <http://www.cancerimaging.org>. In the event of a change in the URL address, please use the DOI provided to locate the paper.

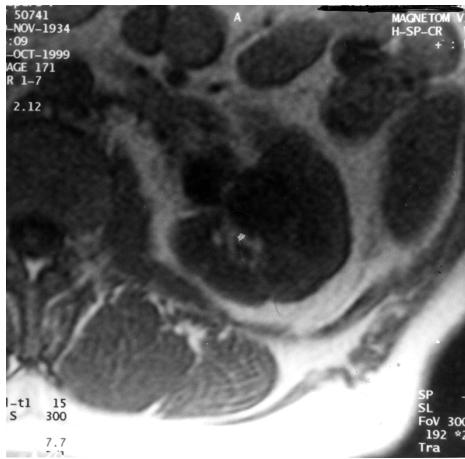


Figure 3 T1-weighted (TE 4.2 msec/TR 7.7 msec) image, axial plane. The tumor is hypointense compared to the renal cortex.

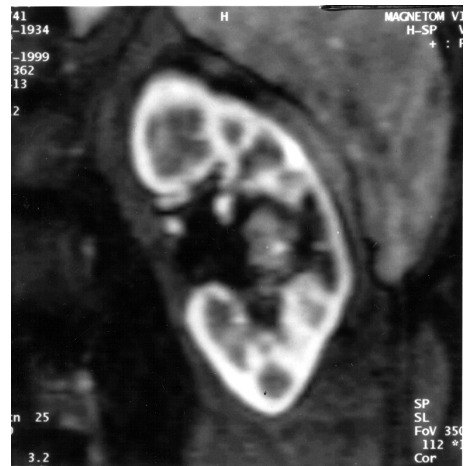


Figure 5 3D contrast-enhanced MR-angiography, coronal plane, corticomedullary phase. The lesion is slightly hypovascular compared to the renal cortex.

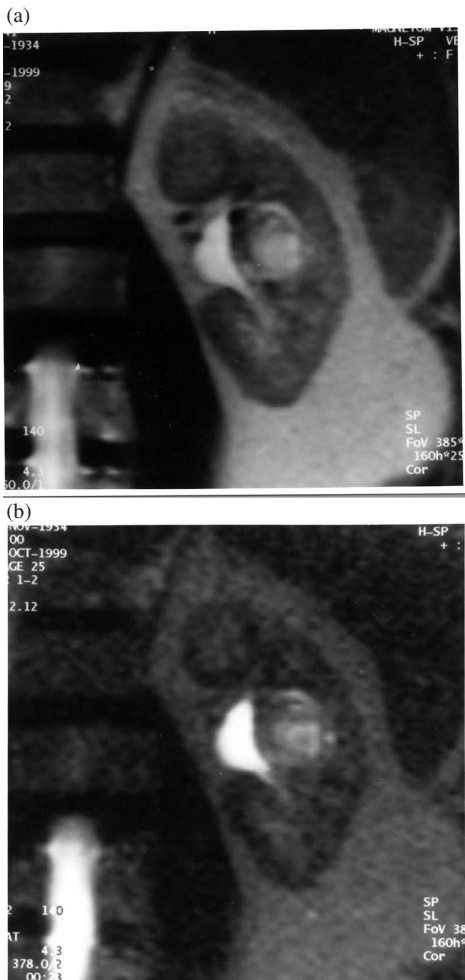

Figure 4 (a) T2-weighted (TE 60 msec/TR 4.3 msec) image, coronal plane. The lesion abuts the renal pelvis and is predominantly hyperintense; some intralesional hypointense strands are present, fading out from the medial border of the tumor. (b) Heavily T2-weighted image (TE 378 msec/TE 4.3 msec). The tumor is less intense than the content of the renal pelvis; the intralesional hypointense strands are seen more clearly.

MRI was performed, showing a lesion isointense to the renal cortex on T1-weighted images (TR 7.7/TE 4.2 msec) (Fig. 3) and predominantly hyperintense on T2-weighted images (TR 4.3/TE 60 msec) (Fig. 4(a,b)). The latter also demonstrated small intratumoral hypointense strands, fanning out from the medial border of the lesion. 3D contrast-enhanced MR-angiography (Fig. 5) in the coronal plane demonstrated lesional enhancement, slightly less than the renal cortex. The renal artery and vein appeared normal. The tumor abutted the renal pelvis without invasion. No metastases were demonstrated.

At the time of the resection of the sigmoid, a nephrectomy was performed. Because of the central location of the lesion and the strong suspicion of malignancy, in the presence of a normal contralateral kidney, partial nephrectomy was not attempted. Convalescence was normal.

Pathology of the radical nephrectomy specimen

On section, a well-circumscribed dark brown nodule with a diameter of 2.6 cm was noted within the renal medulla. No vessel wall was seen surrounding the nodule. Beneath the lesion a normal pelvis was observed. After formalin fixation, tissue blocks were embedded in paraffin. 5 μ m sections for hematoxylin and eosin staining revealed a dilated intrarenal vein, containing papillary proliferations lined by a monolayer of benign-looking endothelial cells associated with a thrombus (Fig. 6(a,b)). The process was entirely intravascular. No necrosis was observed. Atypical cells or nuclear changes were absent. A Masson's trichrome staining showed that a vascular wall (Fig. 6(c)) surrounded the papillary mass. The renal artery branches showed intimal proliferation and mucinous degeneration of the media. The renal parenchyma and collecting system showed no abnormalities.

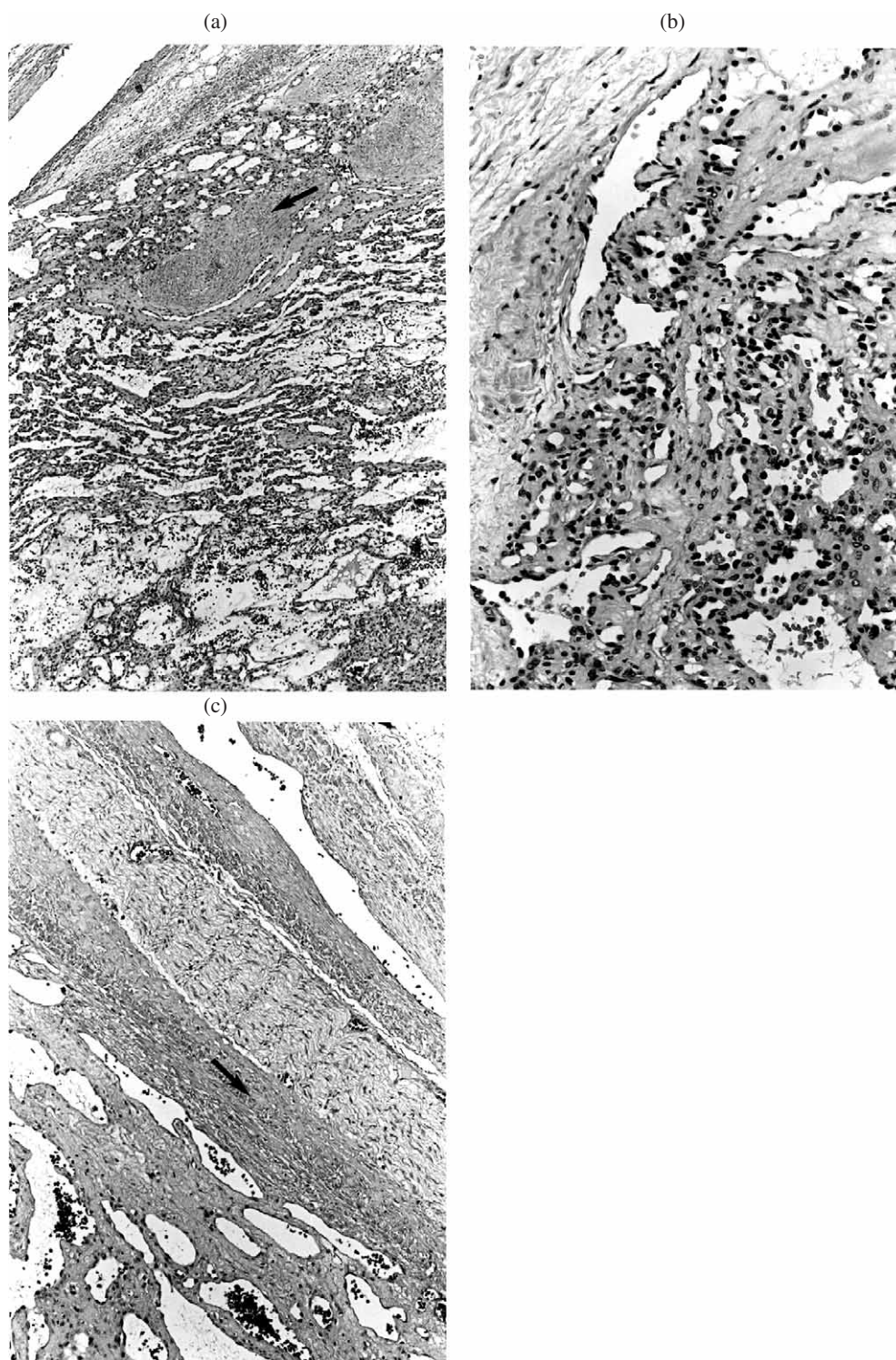


Figure 6 (a) Low magnification shows an intravascular papillary tumor. A portion of the vessel wall is visible (arrow) (Hematoxylin-eosin, magnification $\times 5$). (b) The papillae are lined by a monolayer of benign-appearing endothelial cells (Hematoxylin-eosin, magnification $\times 25$). (c) Around the papillary mass, a vessel wall is seen (arrow) (Masson's trichrome, magnification $\times 10$).

Discussion

Intravascular PEH is a rare reactive lesion first recognized by Ewing in 1922. Masson first described this lesion in a hemorrhoidal vein in 1923 as a neo-plastic process consisting of papillary hyperplasia of the endothelial cells, with a consequent obliteration of the vascular lumen, followed by degenerative changes. Since then the tumor is commonly known as Masson's tumor^[1]. Less than 200 cases have been reported, describing a predilection for skin and head and neck region. The only two previously reported cases from the genitourinary tract are a renal lesion^[1], clinically presenting with hematuria and a lesion in the penis^[2]. The overall prevalence of the lesion is higher in women, suggesting a possible hormonal influence. Three forms of PEH have been described: a pure or primary form occurring within dilated vascular spaces, a mixed or secondary form occurring within a pre-existing vascular lesion (e.g. hemangioma or pyogenic granuloma), and a rare third form which is extravascular and arises in a hematoma^[3]. The specific interest of this lesion is that it should be distinguished from malignancies to avoid radical surgery. The imaging characteristics of the lesion are indeed atypical^[4]. Radiological examination demonstrates a heterogenic solid lesion with contrast enhancement. Differential diagnosis includes renal cell carcinoma and oncocytoma. The absence of intratumoral fat virtually excludes angiomyolipoma. In retrospect, analysis of the spectral curve obtained by duplex sonography shows

a normal resistance pattern, which is more likely to be found in benign masses. In malignant lesions a low-resistance arterial flow pattern is expected due to intratumoral angiogenesis. The characteristics on MRI (hypointense on T1-weighted and hyperintense on T2-weighted images) are atypical as well. The reason for the intralesional hypointense strands on T2-weighted images is not clear. One could suggest the presence of fibrovascular stalks or an intralesional thrombus; however, this could not be demonstrated on pathological examination. Since no radiological examination can rule out the presence of malignancy, surgery is usually warranted. On pathological examination, the process has well-defined features which might be mistaken for angiosarcoma by a pathologist who is not familiar with this entity. Malignant behaviour or degeneration has never been described.

References

- [1] Garber BB, Prestipino AJ, Pollack HM, Levine SR, Whitmore KE. Masson's tumor of the kidney: a new renal lesion. *J Urol* 1990; 143: 344–6.
- [2] Paul AB, Johnston CA, Nawroz I. Masson's tumour of the penis. *Br J Urol* 1994; 74: 261–2.
- [3] Kuo T, Sayers CP, Rosai J. Masson's 'Vegetant intravascular hemangioendothelioma': a lesion often mistaken for angiosarcoma. *Cancer* 1976; 38: 1227–36.
- [4] Johraku A, Miyayaga N, Sekido N *et al.* A case of intravascular papillary endothelial hyperplasia (Masson's tumor) arising from renal sinus. *Jpn J Clin Oncol* 1997; 27: 433–6.