



# Severe and Life-Threatening Paroxysmal Laryngospasm: Uncommon Presentation of COVID-19

Shahin Abdollahifakhim<sup>1</sup>, Seyedpouya Paknezhad<sup>2</sup>, Alireza Ala<sup>2</sup>, Reza Javad Rashid<sup>3</sup> and Hassan Soleimanpour<sup>2,\*</sup>

<sup>1</sup>Department of Otolaryngology and Head and Neck Surgery, Faculty of Medicine, Tabriz University of Medical Sciences, Tabriz, Iran

<sup>2</sup>Emergency and Trauma Care Research Center, Tabriz University of Medical Sciences, Tabriz, Iran

<sup>3</sup>Department of Radiology, Imam Reza General Hospital, Tabriz University of Medical Sciences, Tabriz, Iran

\*Corresponding author: Emergency and Trauma Care Research Center, Tabriz University of Medical Sciences, Tabriz, Iran. Email: h.soleimanpour@gmail.com

Received 2022 August 17; Revised 2022 November 20; Accepted 2022 December 20.

## Abstract

**Introduction:** Laryngospasm is a life-threatening condition caused due to involuntary contraction in laryngeal muscles. It can last seconds to minutes and may cause hypoxemia, loss of consciousness, and death.

**Case Presentation:** We report a case of laryngospasm in a patient with Coronavirus-2 infection who was admitted to the emergency department for the first time. Laryngospasm was revealed after treatment.

**Conclusions:** The clinician should note that laryngospasm can be triggered by Coronavirus-2 infection.

**Keywords:** Laryngospasm, Coronavirus-2 Infection, Emergency Department

## 1. Introduction

Laryngospasm is a potentially life-threatening condition characterized by an involuntary laryngeal muscle spasm obstructing the glottis that manifests as severe dyspnea and stridor. This obstruction can last seconds to minutes and may cause hypoxemia, loss of consciousness, bradycardia, and death (1). Laryngospasm may have different etiologies. It can be an adverse event during anesthesia. Gastroesophageal reflux disease (GERD), emotional stress, tobacco smoke exposure, and upper respiratory tract infections (URI) can also cause laryngospasm (2). So far, there have been no reported cases of laryngospasm due to Coronavirus disease 19 (COVID-19). We report a case of laryngospasm as a complication of COVID-19 in a middle-aged lady.

## 2. Case Presentation

A 56-year-old lady presented to the emergency department (ED) with severe respiratory distress, which suddenly started minutes before ED admission. The patient was a pediatric otolaryngologist. Her symptoms started three days before her presentation to ED, with a low-grade fever and myalgia, followed by a sore throat and anosmia the next day. On the third day, hoarseness and coughing were

added to her symptoms. She experienced sudden and severe dyspnea, and stridor started minutes before her ED visit. At ED presenting time, her respiratory rate and SpO<sub>2</sub> were 35/min and 76%, with a pulse rate and blood pressure of 128 beats per minute (bpm) and 125/85 mmHg, respectively. She was agitated with evident air hunger, asking for a tracheostomy to maintain her airway patency. Supplementary oxygen started immediately, and 0.5 mg of intramuscular epinephrine was administered with 200 mg of intravenous hydrocortisone. Five minutes after epinephrine and oxygen administration, an improvement was observed in her SpO<sub>2</sub> and respiratory distress, but the stridor did not respond to therapy. Due to her clinical improvement, she did not undergo oro-tracheal intubation, but close monitoring and double airway setup were stood by the patient all ED time.

Urgent computed tomography (CT) results revealed stenosis in the glottis with a normal lung field. No radiologic manifestation of COVID-19 infection was reported in pulmonary CT (Figures 1 and 2). Her medical history was positive for tonsillectomy, lumbar discopathy, and discectomy, both of which were performed years ago. She had a history of COVID-19 infection 14 months before and completed the COVID-19 vaccination history. Her medical history was otherwise unremarkable. She was not a smoker and did not consume alcohol or recreational drugs. On

the first day of her symptoms, she took acetaminophen and azithromycin orally and had no severe symptoms until her ED presentation. The patient was then admitted to the intensive care unit (ICU) and received continuous oxygen therapy. Corticosteroids started for her as a maintenance dose of 250 mg methylprednisolone twice a day, which she tapered in the following days. A positive result was obtained for the nasopharyngeal and oropharyngeal swabs of SARS CoV2 RTPCR. Table 1 shows laboratory test results on hospital stay days. The patient had an uneventful hospital stay in three days and was discharged home with a corticosteroid prescription. She had no complications or new complaints in the follow-up and fully recovered.

**Table 1.** Laboratory Findings in ED and ICU

Variables	ED Admission	ICU 1st Day	ICU 3rd Day
WBC	7200	6000	6300
Lymph	880	830	870
Hb	13.4	12.7	12.8
Plt	246000	191000	197000
PT	13.5	13.5	13.5
INR	1.1	1.1	1.1
PIT	27	29	28
LDH	516	522	505
CRP	53	62	60
Blood sugar	106	98	110
Urea	20	22	21
Creatinine	0.8	0.8	0.7
Na	143	142	139
K	4.2	4	4.1
Ca	10.3		
Cholesterol		230	
TG		30	
LDL		146	
HDL		37	
IL-6		2	
TSH		1	
T4		11	
T3		0.7	
RTPCR		positive	

### 3. Discussion

Closure of the glottic opening by vocal cord constriction is a protective reflex to avoid aspiration. Laryngospasm is an exaggerated form of this reflex that can

cause life-threatening complications. Laryngospasm mainly occurs as an anesthetic adverse event in light planes of anesthesia. It is the most common cause of upper respiratory tract obstruction during the extubation of patients. Although laryngospasm is not an uncommon anesthesiologic event, it is rare outside the operation room and may have various etiologies. In the literature, paroxysmal laryngospasm is described as a rare cause of laryngospasm. Bai et al. studied paroxysmal laryngospasm in 12 patients and found a history of GERD in seven patients. In patients with GERD, laryngeal irritation due to pepsin and acid can end in exaggerated laryngeal reflexes manifested as laryngospasm (3). Our patient did not have a history of GERD.

The second most frequent trigger was cough in the study of Bai et al. Although our patient had had non-productive coughs since the third day of her symptoms, she denied that her laryngospasm started with coughing as a trigger. Moreover, she did not have emotional stress that could trigger paroxysmal laryngospasm. Hypocalcemia can cause laryngospasm, and a case of hypocalcemic laryngospasm was described by Van Veelen et al. (4). However, our patient had no electrolyte disturbance, including hypocalcemia. URIs can trigger laryngospasm. Influenza has been described as a trigger by Minagi et al. (5). We did not find any report about laryngospasm triggered by COVID-19, and we believe that our patient is the first case of laryngospasm induced by COVID-19 infection. Corona spread in December 2019 and has affected the world since then. Therefore, in addition to the common manifestations of this disease, identifying its rare manifestations can also help to understand this pandemic as much as possible (6-9).

### Acknowledgments

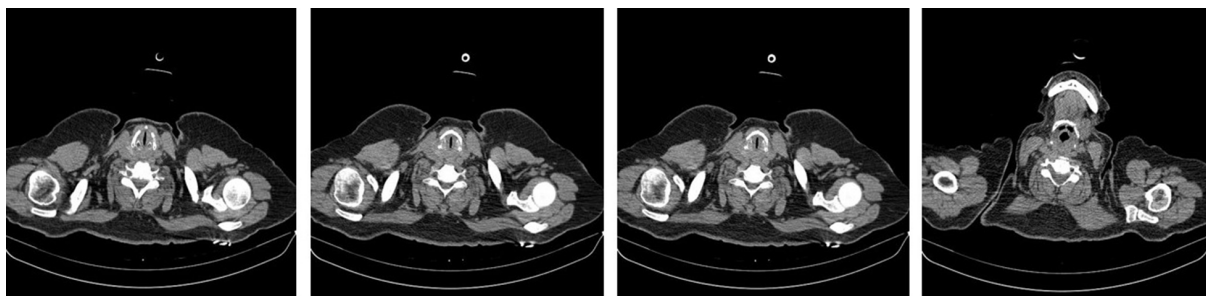
We would like to appreciate the cooperation of the Clinical Research Development Unit, the Imam Reza General Hospital, Tabriz, Iran, in conducting this research.

### Footnotes

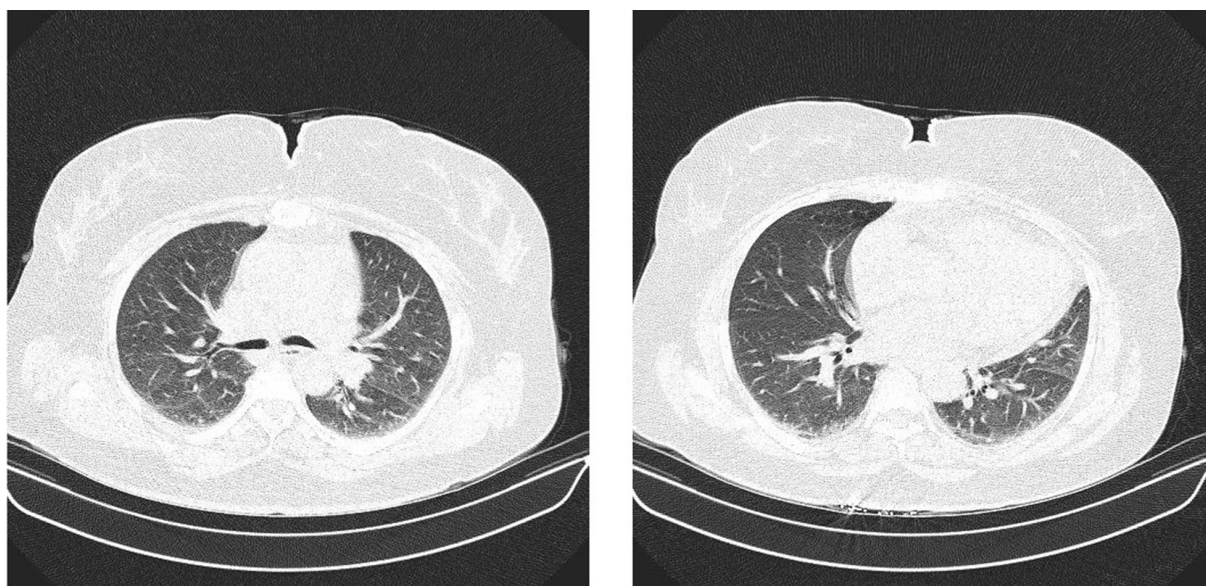
**Authors' Contribution:** S.A., S.P.P., A.A., H.S., and R.J.R. wrote the main manuscript. All authors read and approved the final manuscript.

**Conflict of Interests:** The authors declare that they have no conflicts of interest.

**Data Reproducibility:** The datasets generated and analyzed during the current study are not publicly available due to legal reasons but are available from the corresponding author, H.S. on reasonable request.



**Figure 1.** Axial CT images from the larynx showing severe closure of vocal cords causing airway stenosis



**Figure 2.** Axial images of the lung showing no evident opacities

**Ethical Approval:** The current study has been approved for publication by the Research Ethics Committees of Tabriz University of Medical Sciences, Tabriz, Iran (approval ID: IR.TBZMED.REC.1400.1254) and has been performed under the ethical standards as laid down in the 1964 Declaration of Helsinki and its later amendments or comparable ethical standards.

**Funding/Support:** No funding/support was received for this manuscript.

**Informed Consent:** Written informed consent was obtained from the patient to publish this case report and accompanying images.

## References

- Gavel G, Walker RW. Laryngospasm in anaesthesia. *Continuing Anesth Pain Med.* 2023;13(1):e130926.
- Hong L, Li S, Feng Q, Feng X, Jin Y, Zhao Q, et al. H. pylori infection may cause sleep-related laryngospasm for a patient in climacteric. *J Pain Symptom Manage.* 2010;39(6):e6-7. [PubMed ID: 20538179]. <https://doi.org/10.1016/j.jpainsymman.2010.02.002>.
- Bai Y, Jing XR, Xia Y, Tao XN. Paroxysmal Laryngospasm: A Rare Condition That Respiratory Physicians Must Distinguish from Other Diseases with a Chief Complaint of Dyspnea. *Can Respir J.* 2020;2020:2451703. [PubMed ID: 32695244]. [PubMed Central ID: PMC7361892]. <https://doi.org/10.1155/2020/2451703>.
- van Veelen MJ, Visser MF, Baggen MG, Dees A. Hypocalcaemic laryngospasm in the emergency department. *BMJ Case Rep.* 2011;2011. [PubMed ID: 22707499]. [PubMed Central ID: PMC3062878]. <https://doi.org/10.1136/bcr.11.2010.3555>.
- Minagi M, Inokuchi I, Ayada N, Egusa K, Fukumasu I, Kohno T. [A case of laryngospasm following to influenza infection]. *Otolaryngol Head Neck Surg.* 2016;88(8):591-4. Japanese. <https://doi.org/10.11477/mf.1411201035>.
- Bagi HM, Soleimanpour M, Abdollahi F, Soleimanpour H. Evaluation of clinical outcomes of patients with mild symptoms of coronavirus

- disease 2019 (COVID-19) discharged from the emergency department. *PLoS One*. 2021;**16**(10). e0258697. [PubMed ID: 34673806]. [PubMed Central ID: PMC8530279]. <https://doi.org/10.1371/journal.pone.0258697>.
7. Mahmoodpour A, Shadvar K, Ghamari AA, Mohammadzadeh Lameh M, Asghari Ardebili R, Hamidi M, et al. Management of Critically Ill Patients with COVID-19: What We Learned and What We Do. *Anesth Pain Med*. 2020;**10**(3). e104900. [PubMed ID: 32944565]. [PubMed Central ID: PMC7472789]. <https://doi.org/10.5812/aapm.104900>.
  8. Shahsavarinia K, Amiri P, Mousavi Z, Gilani N, Saadati M, Soleimanpour H. Prediction of PTSD related to COVID-19 in emergency staff based on the components of self-compassion and perceived social support. *BMC Psychiatry*. 2022;**22**(1):368. [PubMed ID: 35641937]. [PubMed Central ID: PMC9154198]. <https://doi.org/10.1186/s12888-022-04017-8>.
  9. Mahmoodpour A, Imani F, Soleimanpour H. COVID-19 Is Not Over and Needs Prediction Scores: An Endless Road!. *Anesth Pain Med*. 2021;**11**(6). e121654. [PubMed ID: 35291407]. [PubMed Central ID: PMC8909521]. <https://doi.org/10.5812/aapm.121654>.