

*Nephroquiz*  
(Section Editor: M. Zeier)

## Nephrotic syndrome and chronic kidney disease in a young African patient from Saint Thomas and Prince: what is the link?

Sara Gonçalves<sup>1</sup>, José António Lopes<sup>1</sup>, Paulo Fernandes<sup>1</sup>, Fernando Abreu<sup>1</sup>, Alice Fortes<sup>1</sup>, José Barbas<sup>1</sup>, Maria João Palhano<sup>2</sup> and Mateus Martins Prata<sup>1</sup>

<sup>1</sup>Department of Nephrology and Renal Transplantation and <sup>2</sup>Department of Pathology, Hospital de Santa Maria, Lisbon, Portugal

**Keywords:** African patient; chronic kidney disease; nephrotic syndrome

### Question

What is your diagnosis?

### Answer to the quiz

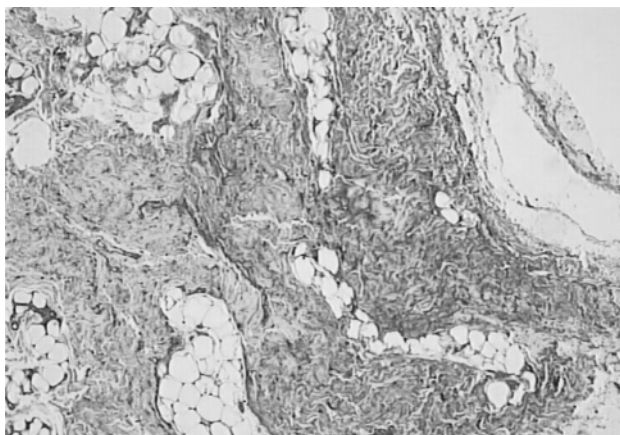
The patient was affected by AA amyloidosis secondary to chronic schistosomiasis.

A subcutaneous abdominal fat biopsy was performed and it was positive for amyloid, as shown by Congo red staining with green birefringence under polarized light; type AA was identified by immunohistochemistry (Figure 1). Taking into consideration this diagnosis and the patient's origin, other parasitary infections were evaluated by searching for eggs, cysts and parasites in stools and urine, and by serology. Despite other parasitary infections being excluded, the immunoenzymatic assay (1/10 240) and the immunoblot were both positive for *Schistosoma*. To investigate active infection, a rectal biopsy was then performed and showed viable *Schistosoma mansoni* ova (Figure 2); thus, the patient was treated with praziquantel (40 mg/kg/day) for 2 days. The patient was discharged in a stable condition, but she remained dialysis dependent.

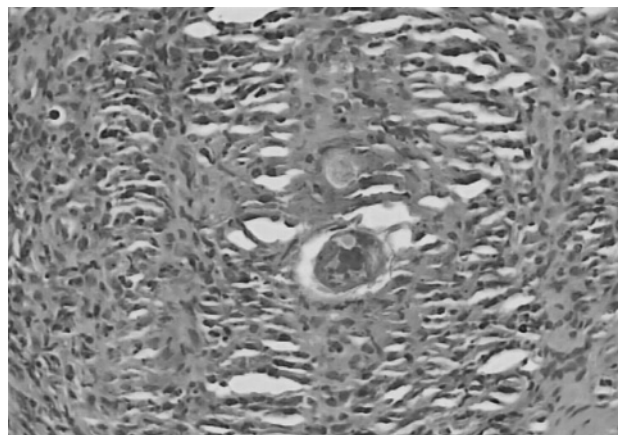
Schistosomiasis was firstly described by Theodor Bilharz in 1852 and it is caused by infection with parasitic blood flukes known as *schistosomes*. There are three major species (*S. mansoni*, *S. japonicum* and *S. haematobium*) that produce infection in humans, and tend to occur in restricted geographic patterns; for example, *Schistosoma mansoni* is more prevalent in sub-Saharan Africa, the Middle East, South America and the Caribbean. In the endemic areas, the infection is usually acquired in childhood and the chronic complications (intestinal, hepatic, urinary neurologic and pulmonary) are more common [1,2]. Various glomerulopathies (mesangioproliferative, diffuse proliferative, membranoproliferative, focal segmental glomerulosclerosis, amyloid and cryoglobulinemic) have been described in patients with *Schistosomiasis*, and *Schistosoma mansoni* accounts for the most clinically significant cases [3,4]. Amyloidosis is the predominant lesion in <5% of patients with clinically overt schistosomal glomerulopathy,

A 17-year-old black African female from Saint Thomas and Prince with growth failure and a 5-year history of frothy urine and periorbital oedema was referred to our department for evaluation of renal insufficiency. At admission, the patient was hypertensive and malnourished, and presented with jugular engorgement, pulmonary rales, liver enlarged to 9 cm below the right costal margin and lower leg oedema. Laboratory tests revealed ferropenic anaemia (haemoglobin: 7.4 g/dL; ferritin 24.2 ng/mL, transferrin saturation 4%), eosinophilia (10.5%), renal dysfunction (urea 280 mg/dL, creatinine 7.0 mg/dL), hypoalbuminaemia (2.8 g/dL) and hyperfibrinogenaemia (550 mg/dL). Transaminases and C-reactive protein were on the normal range, and there was no hyperlipidaemia. Urinalysis showed proteinuria (>300 mg/dL) and haematuria (80 erythrocytes/ $\mu$ L), and daily protein excretion was 3.5 g/1.73 m<sup>2</sup>. Ultrasonography revealed normal renal size and increased cortical echogenicity of the kidneys, hepatosplenomegaly and celiac adenopathies. Chest X-ray revealed cardiomegaly, and ecocardiography showed dilation of left ventricle, low ejection fraction (<10%) and restrictive diastolic filling pattern. The patient started haemodialysis. Further studies were negative for dysproteinemias, vasculitis, systemic lupus erythematosus and viral infections, including human immunodeficiency virus infection, hepatitis B and hepatitis C. Evaluation of *Plasmodium* infection and tuberculosis was also negative.

Correspondence and offprint requests to: José António Lopes, Department of Nephrology and Renal Transplantation, Hospital de Santa Maria, 1649-035 Lisboa, Portugal. Tel: +351-961203912; Fax: +351-217805679; E-mail: jalopes93@hotmail.com



**Fig. 1.** Deposits of type AA amyloid in subcutaneous abdominal fat (immunohistochemistry).



**Fig. 2.** Viable *Schistosoma mansoni* egg (rectal biopsy).

and hepatosplenomegaly, nephrotic syndrome and renal failure are the most common clinical findings [3,4].

Our case highlights that Schistosomiasis must always be considered in the differential diagnosis of the nephrotic syndrome and chronic kidney disease in patients from endemic areas for this infection.

*Conflict of interest statement.* None declared.

## References

1. Gryseels B, Polman K, Clerinx J *et al.* Human schistosomiasis. *Lancet* 2006; 368: 1106
2. Lucey DR, Maguire JH. Schistosomiasis. *Infect Dis Clin North Am* 1993; 7: 635
3. Barsoum RS. Schistosomal glomerulopathies. *Kidney Int* 1993; 44: 1–12
4. Barsoum R. The changing face of schistosomal glomerulopathy. *Kidney Int* 2004; 66: 2472–2484

*Received for publication:* 2.12.07

*Accepted in revised form:* 3.1.08