



Contents lists available at ScienceDirect

International Journal of Surgery Case Reports

journal homepage: www.casereports.com

True left-sided gallbladder: A case report and comparison with the literature for the different techniques of laparoscopic cholecystectomy for such anomalies

Tamer Saafan^{a,*}, James Yi Hu^b, Ahmed-Emad Mahfouz^c, Abdelrahman Abdelaal^a

^a General Surgery Department, Hamad General Hospital, Hamad Medical Corporation, P.O. Box 3050, Doha, Qatar

^b Weill Cornell Medicine - Qatar, Qatar Foundation - Education City, P.O. Box 24144, Doha, Qatar

^c Radiology Department, Hamad General Hospital, Hamad Medical Corporation, P.O. Box 3050, Doha, Qatar

ARTICLE INFO

Article history:

Received 13 November 2017

Received in revised form 8 December 2017

Accepted 12 December 2017

Available online 27 December 2017

Keywords:

Left-sided gallbladder

Gallbladder

Laparoscopic cholecystectomy

Ligamentum teres

Situs inversus

Biliary anomalies

ABSTRACT

INTRODUCTION: True left-sided gallbladder (LSG) is a rare finding that may present with symptoms similar to those of a normally positioned gallbladder. Moreover, it may be missed by preoperative imaging studies such as ultrasound, computed tomography (CT), magnetic resonance imaging (MRI), or endoscopic ultrasound. True left-sided gallbladder is a surgical challenge and surgical technique may need to be modified for the completion of laparoscopic cholecystectomy.

PRESENTATION OF CASE: In this case report, we present a case of true left-sided gallbladder that produced right-sided abdominal symptoms. Ultrasound of the abdomen failed to show the left-sided position of the gallbladder. MRI showed the gallbladder located to the left of the ligamentum teres underneath segment III of the liver. Intraoperatively, the gallbladder was grasped and retracted to the right under the falciform ligament and it was removed using classical right-sided ports with no modification to the technique. No complications were encountered intraoperatively or postoperatively.

DISCUSSION: True LSG is a rare anomaly that may present with right-sided symptoms like normally positioned gallbladder. It may be missed in preoperative imaging studies and can be discovered only intraoperatively. Modification of laparoscopic ports, change in patient's position and/or surgeon's position, or conversion to open cholecystectomy may be needed for safe removal of the gallbladder.

CONCLUSION: Classical technique of laparoscopic cholecystectomy is feasible for left-sided gallbladder. However, if the anatomy is not clear, modifications of the surgical technique may be necessary for the safe dissection of the gallbladder.

© 2018 The Authors. Published by Elsevier Ltd on behalf of IJS Publishing Group Ltd. This is an open access article under the CC BY-NC-ND license (<http://creativecommons.org/licenses/by-nc-nd/4.0/>).

1. Introduction

Left-sided gallbladder (LSG) is a rare anomaly; the reported incidence ranges from 0.2% to 1.1 [1]. Normally, the gallbladder resides in the gallbladder fossa between hepatic segments IV and V. LSG is defined as a gallbladder located on the left side of the round ligament or ligamentum teres [2]. There are three recognized variants of LSG: LSG associated with situs viscerum inversus (SVI), true LSG (T-LSG), and gallbladder located to the left of abnormally located right-sided round ligament/ligamentum teres (R-LSG) [3]. LSG without SVI (LSG-woSVI), which comprises T-LSG and R-LSG, is a rare anomaly and is typically discovered incidentally during surgery [2]. T-LSG should be differentiated from R-LSG; it is positioned to the left of the ligamentum teres and falciform ligament and is located under the surface of the left liver lobe segment III

[3–5]. On the other hand, LSG due to abnormally located round ligament/ligamentum teres is normally located at segment IVb. It is important to recognize the R-LSG anomaly, particularly in patients scheduled for hepatectomy, because the condition is typically associated with other anomalies of intrahepatic portal veins and intrahepatic biliary branches [3].

T-LSG is the most common type of LSG-woSVI [2]. There are several theories pertaining to the embryological origin of T-LSG. According to one theory, the gallbladder develops from the hepatic diverticulum at its normal site; however, its attachment to the developing left lobe results in the migration of the gallbladder to the left lobe [5,6], which results in a long cystic duct that crosses the common hepatic duct from left to right and joins the common hepatic duct at its right side. According to another theory, the gallbladder develops directly from the left hepatic duct with regression of the main gallbladder [5,6]. In such cases, a cystic duct either drains into the left hepatic duct or joins the common bile duct from the left side [5–7]. Here, we present the case of a patient with true LSG that was laparoscopically removed using the same

* Corresponding author.

E-mail address: tsaafan@gmail.com (T. Saafan).

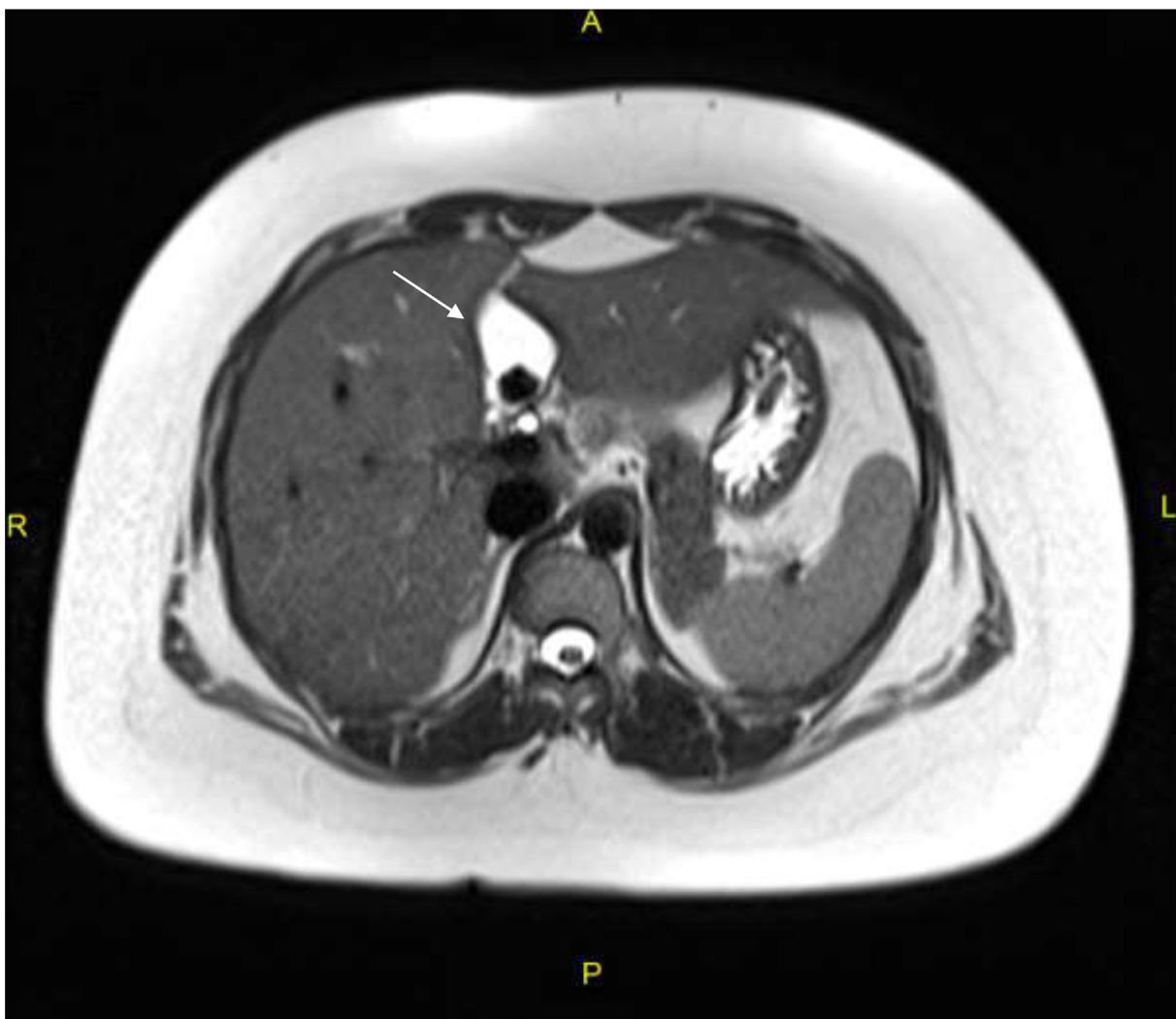


Fig. 1. Transverse T2-weighted magnetic resonance image showing the gallbladder (arrow) with a stone inside, located to the left of the fissure for ligamentum teres under segment III.

classical ports that are routinely used for normally positioned gallbladder. This work has been reported in line with the SCARE criteria [7].

2. Case report

A 26-year-old Pakistani woman presented to our clinic with chief complaints of recurrent right upper quadrant (RUQ) colicky pain associated with nausea and vomiting since the last few months. She has a history of polycystic ovarian disease with irregular menstruation. There was no other relevant medical history or history of prior surgery. On clinical examination, the abdomen was soft; there was no tenderness in any of the four quadrants of the abdomen. Laboratory investigations including complete blood count and liver and renal function tests were normal. Abdominal ultrasound showed a contracted gallbladder with large stones measuring 1.8 cm and a well-defined hypoechoic lesion (2.6×1.4 cm) in the right liver lobe. Magnetic resonance imaging (MRI) revealed that the gallbladder was located to the left of fissure for ligamentum teres underneath segment III (Fig. 1); a focal fat-sparing lesion was observed in segment VI. The patient was booked for elective laparoscopic cholecystectomy. Surgery was performed using the conventional four-port technique; a 10-mm supraumbilical port and three 5-mm ports (in the epigastrium, right midclavicular line,

and right anterior axillary line, respectively). Upon insertion of the camera, the gallbladder was immediately visualized to the left of the falciform ligament (Fig. 2), attached to segment III of the liver with a long mesentery (Fig. 2). The gallbladder was grasped and retracted to the right side under the falciform ligament (Fig. 2). Careful dissection was performed at the Calot's triangle and, two cystic arteries (right and left) were found. After identification, both the right and left cystic arteries were clipped and divided. A cystic duct was found joining the common hepatic duct on the right side. It was also clipped and divided. The rest of the operation was performed as per the standard protocol and with meticulous dissection of the gallbladder border. The postoperative period was uneventful and she was discharged on the second day. Histopathological examination of the gallbladder revealed chronic cholecystitis.

3. Discussion

True LSG is a rare and unusual, albeit a well-recognized, anomaly; it may present with right-sided symptoms and exhibit a clinical picture similar to that associated with a normally positioned gallbladder. This makes its preoperative diagnosis a clinical challenge [2]. Abongwa *et al.* [2] reviewed 55 patients with LSG-woSVI, of which 83% of patients had T-LSG; a vast majority (75%) of these patients presented with RUQ pain. It is suggested that

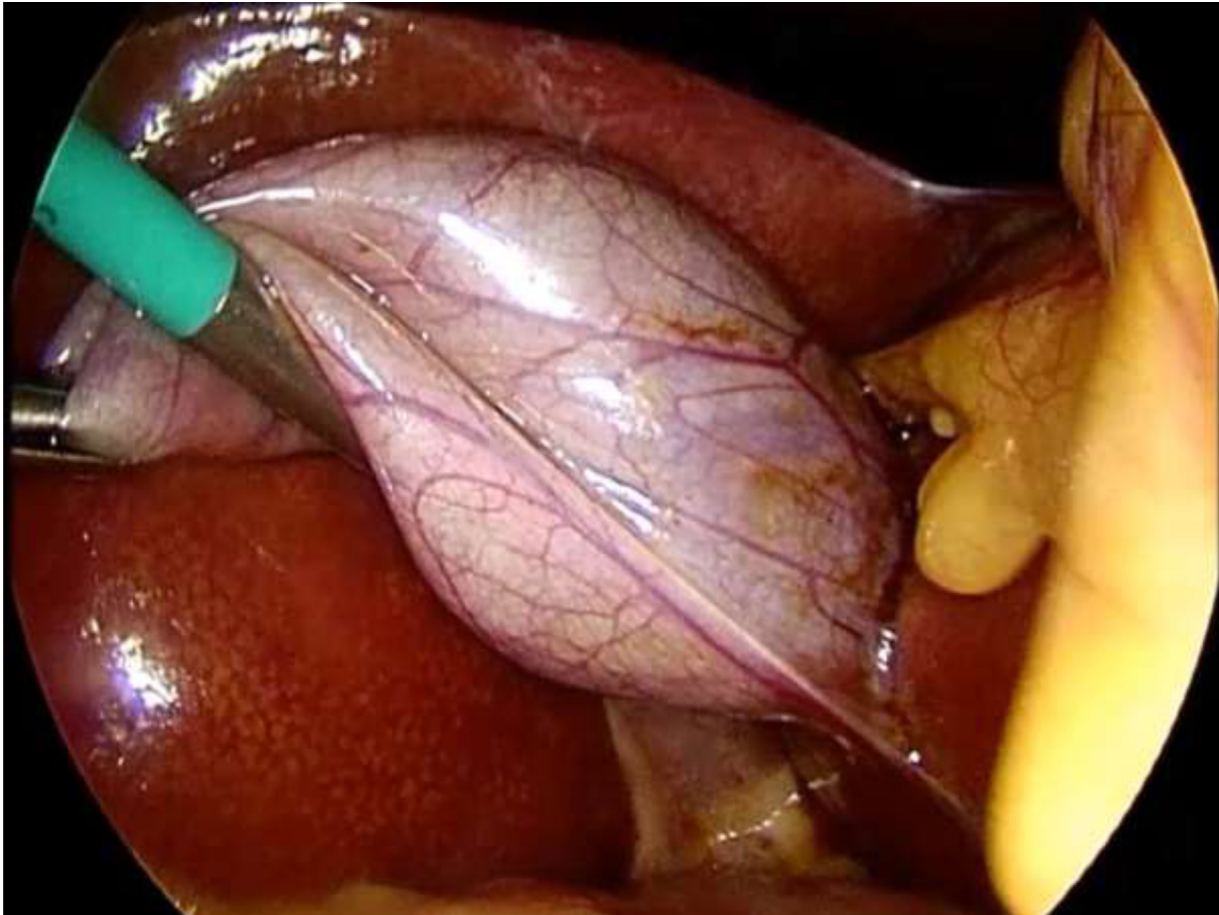


Fig. 2. Operative photograph showing gallbladder attached to the left liver lobe to the left of the falciform ligament. The gallbladder was retracted to the right side under the falciform ligament.

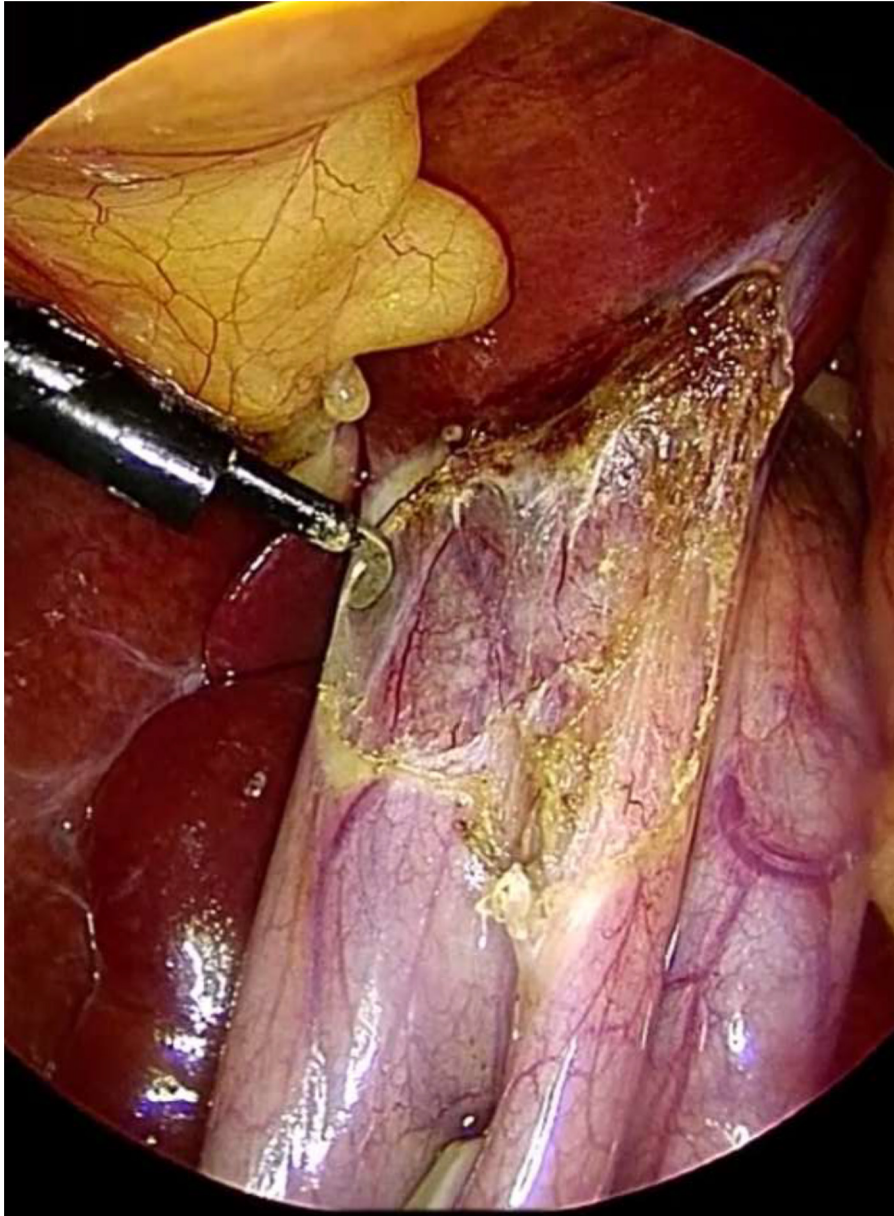


Fig. 3. Operative photograph showing the meticulous dissection over the gallbladder border.

Table 1

Summary of previously reported cases of left-sided gallbladder along with relevant operative details.

| Study | Year | Country | Number of cases | Type of LSG | Procedure type L/L-O/O/ | Classical or modified ports for L | Modification done to ports/patient's position | Bile duct injury |
|------------------------|------|---------|-----------------|-------------|-------------------------|-----------------------------------|---|--------------------|
| Idu et al. [8]. | 1996 | UK | 5 | T | 4L | -- | -- | -- |
| Nagai et al. [3]. | 1997 | Japan | 3 | R | 1 L-O | -- | -- | -- |
| Donthi et al. [11]. | 2001 | USA | 2 | 1 S | L | Modified | Left anterior axillary and left midclavicular ports | none |
| Wong et al. [5]. | 2001 | UK | 1 | 1 T | O | -- | -- | Yes |
| Dhulkotia et al. [12]. | 2002 | India | 1 | T | O | -- | -- | none |
| Reddy et al. [13]. | 2005 | India | 1 | T | L | Modified | Left subcostal port Lithotomy position | none |
| Chrungoo et al. [14]. | 2007 | India | 2 | -- | L | Classical | -- | none |
| Zografos et al. [15]. | 2009 | Greece | 1 | T | | | 10-mm trocar between umbilicus and xiphoid left midclavicular and left anterior axillary Patient left side up | none |
| Qureshi et al. [16]. | 2009 | USA | 1 | T | L | Modified | Left upper quadrant port | none |
| Sadhu et al. [17]. | 2012 | India | 1 | T | L | Modified | Left upper quadrant port and right subcostal port | none |
| Kawai et al. [18]. | 2012 | Japan | 1 | T | L | classical | -- | none |
| Makni et al. [19]. | 2012 | Tunisia | 1 | T | L | classical | -- | none |
| Iskandar et al. [9]. | 2013 | USA | 1 | T | L | -- | -- | none |
| Nastos et al. [20]. | 2014 | Greece | 2 | -- | L | classical | Subxiphoid trocar introduced to the left of the round ligament, right midclavicular and anterior axillary passed under the round ligament | none |
| Velimezis et al. [10]. | 2015 | Germany | 7 | T | 5L 2L-O | -- | Regular trocars in three patients Left subcostal port and left side up position in four patients | Yes in one patient |
| Our Study | | Qatar | 1 | T | L | Classical | -- | none |

T, true LSG; S, situs viscerum inversus; R, gallbladder to the left of abnormally located right-sided gallbladder; L, laparoscopic cholecystectomy; L-O, laparoscopic cholecystectomy converted to open; O, open cholecystectomy; -- data not mentioned or not applicable.

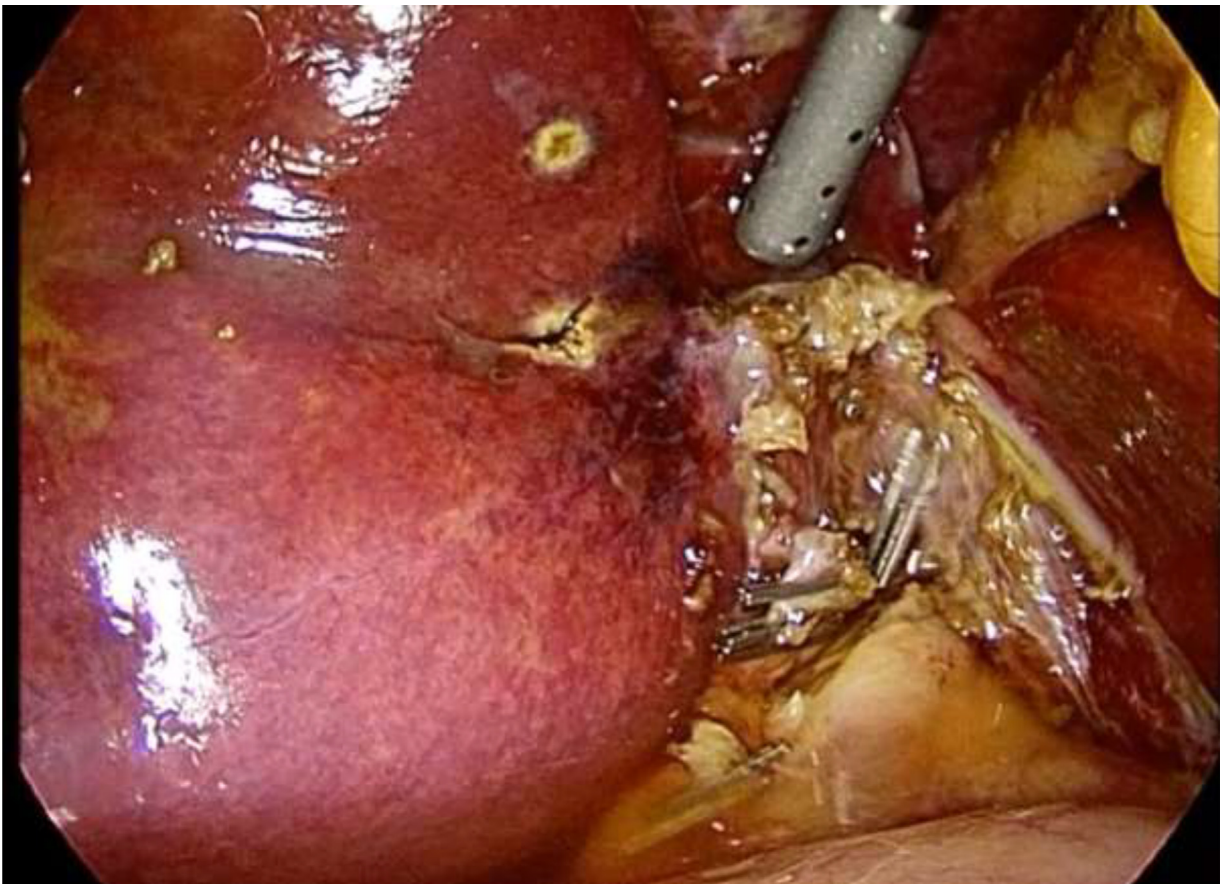


Fig. 4. Operative photograph showing the gallbladder's bed to the left of falciform ligament after the gallbladder was removed.

visceral nerve fibers do not transpose along with the gallbladder, thereby causing right-sided symptoms [2]. Although preoperative ultrasound or computed tomography (CT) may help in the diagnosis of LSG, some cases may not be detected by ultrasound, CT, or even MRI and endoscopic ultrasound; such cases may only be discovered intraoperatively [3,5,8,9]. Our patient presented with colicky RUQ pain and abdominal ultrasound failed to show the left-sided position of the gallbladder; the anomaly was discovered on MRI, which was performed to evaluate a lesion in the right liver lobe detected on ultrasound. The right hepatic lesion turned out to be a benign focal fat-sparing lesion.

According to the literature, LSG is associated with a higher risk of operative injury to the bile duct (up to 7.3%) owing to the associated anomalies of the biliary duct, portal vein, and other structures [2]. Several studies have shown that modification of laparoscopic ports such as changes in the position of the subxiphoid trocar to the left of round ligament, use of left subcostal and left anterior axillary line ports, or change in patient's position (left side up position) during surgery may facilitate laparoscopic removal of LSG (Table 1). In our case report, laparoscopic cholecystectomy was performed with the use of regular four-port technique (trocars placed in the right side of the abdomen), and LSG was safely removed using the classical technique of laparoscopic cholecystectomy which was facilitated by retracting the gallbladder to the right side under the falciform ligament (Figs. 2–4,). Our experience is consistent with previous reports of safe laparoscopic removal of LSG with the use of classical ports and laparoscopic cholecystectomy technique (Table 1). However, conversion to open surgery may be required as a last resort in case of failure of the laparoscopic method. In a case series by Velimezis et al. [10], two out of seven patients with T-LSG undergoing laparoscopic cholecystectomy required conversion to open

surgery due to dense adhesions and bleeding from the cystic artery [10].

In conclusion, true LSG is a rare anomaly which may only be discovered intraoperatively. Appropriate identification of anatomy and key landmarks along with meticulous dissection over the gallbladder border will allow safe removal of LSG through the laparoscopic approach. Classical ports and the standard patient position may be used; however, modification of the technique may be required for the safe identification of vascular and biliary structures and removal of gallbladder. There should be strong tendency to convert to open surgery, in case of difficult anatomy and inability to safely dissect the gallbladder using laparoscopic approach, to avoid bile duct injuries.

Conflict of interest

We wish to confirm that there are no known conflicts of interest associated with this publication.

Sources of funding

Nothing to declare.

Ethical approval

This case report was approved by Hamad Medical Corporation Medical Research Center. Case report approval number is #17257/17.

Consent

Written informed consent was obtained from the patient for publication of this case report and accompanying images. A copy of the written consent is available for review by the Editor-in-Chief of this journal on request.

Author contribution

Tamer Saafan: manuscript writing, revision and manuscript submission.

James Yi Hu: data collection and manuscript writing

Ahmed-Emad Mahfouz: data collection and data analysis.

Abdelrahman Abdelaal: performed the surgery, manuscript revision.

All authors have approved the final article for submission.

Registration of research studies

Not applicable.

Guarantor

Tamer Saafan, Abdelrahman Abdelaal.

Acknowledgement

The authors would like to thank Enago (www.enago.com) for the English language review.

References

- [1] E. Savier, J. Taboury, O. Lucidarme, et al., Fusion of the planes of the liver: an anatomic entity merging the midplane and the left intersectional plane, *J. Am. Coll. Surg.* 200 (2005) 711–719, <http://dx.doi.org/10.1016/j.jamcollsurg.2004.12.017> (PMID: 15848361).
- [2] H.K. Abongwa, B. De Simone, L. Alberici, M. Iaria, G. Perrone, A. Tarasconi, G. Baiocchi, N. Portolani, S. Di Saverio, M. Sartelli, F. Coccolini, J.E. Manegold, L. Ansaloni, F. Catena, Implications of left-sided gallbladder in the emergency setting: retrospective review and top tips for safe laparoscopic cholecystectomy, *Surg. Laparosc. Endosc. Percutan. Tech.* 27 (4) (2017) 220–227, <http://dx.doi.org/10.1097/SLE.0000000000000417> (PMID: 28614170).
- [3] M. Nagai, K. Kubota, S. Kawasaki, T. Takayama, M. BandaiY, Are left-sided gallbladders really located on the left side? *Ann. Surg.* 225 (1997) 274–280, <http://dx.doi.org/10.1097/00000658-199703000-00006> (PMID:9060583).
- [4] S. Hwang, S.G. Lee, K.M. Park, Y.J. Lee, C.S. Ahn, K.H. Kim, D.B. Moon, T.Y. Ha, S.H. Cho, K.B. Oh, Hepatectomy of living donors with a left sided gallbladder and multiple combined anomalies for adult-to-adult living donor liver transplantation, *Liver Transpl.* 10 (2004) 141–146, <http://dx.doi.org/10.1002/lt.20007> (PMID:14755792).
- [5] L.S. Wong, J. Rusby, T. Ismail, Left-sided gall bladder: a diagnostic and surgical challenge, *ANZ J. Surg.* 71 (2001) 557–558, <http://dx.doi.org/10.1046/j.1440-1622.2001.02195.x> (PMid:11527272).
- [6] T.C. Wu, R.C. Lee, J.H. Chiang, C.Y. Chang, Reappraisal of left-sided gallbladder and its accompanying anomalies: a report of two cases and literature review, *Acta Radiol.* 46 (2005) 233–236, <http://dx.doi.org/10.1080/02841850510012706>.
- [7] R.A. Agha, A.J. Fowler, A. Saeta, I. Barai, S. Rajmohan, D.P. Orgill, The SCARE Statement: consensus-based surgical case report guidelines, *Int. J. Surg.* 34 (2016) 180–186.
- [8] M. Idu, J. Jakimowicz, A. Iuppa, A. Cuschieri, Hepatobiliary anatomy in patients with transposition of the gallbladder: implications for safe laparoscopic cholecystectomy, *Br. J. Surg.* 83 (1996) 1442–1443, <http://dx.doi.org/10.1002/bjs.1800831037> (PMid:8944467).
- [9] M.E. Iskandar, A. Radzio, M. Krikkhely, I.M. Leitman, Laparoscopic cholecystectomy for a left-sided gallbladder, *World J. Gastroenterol.* 19 (35) (2013) 5925–5928 (PMid:24124340 0.3748/wjg.v19.i35.5925).
- [10] G. Velimezis, N. Vassos, G. Kapogiannatos, D. Koronakis, C. Salpiggidis, E. Perrakis, A. Perrakis, Left-sided gallbladder in the era of laparoscopic cholecystectomy: a single-center experience, *Am. Surg.* 81 (12) (2015) 1249–1252 (PMid:26736163).
- [11] R. Donthi, D.J. Thomas, D. Sanders, S.P. Schmidt, Report of laparoscopic cholecystectomy in two patients with left-sided gallbladders, *JLS* 5 (2001) 53–56 (PMid:11303995).
- [12] A. Dhulkotia, S. Kumar, V. Kabra, H.S. Shukla, Aberrant gallbladder situated beneath the left lobe of liver, *HPB (Oxford)* 4 (1) (2002) 39–42, <http://dx.doi.org/10.1080/136518202753598726> (PMid:18333151).
- [13] P.K. Reddy, R.V. Subramanian, S. Yuvaraja, Laparoscopic cholecystectomy for left-sided gallbladder (sinistroposition), *JLS* 9 (3) (2005) 356–357 (PMid:16121888).
- [14] R.K. Chungoo, S.L. Kachroo, A.K. Sharma, A.B. Khan, A.S. Nadim, Left-sided gallbladder: Report of two cases, *J. Min. Access. Surg.* 3 (3) (2007) 108–110, <http://dx.doi.org/10.4103/0972-9941.37194> (PMid:19789667).
- [15] G.C. Zografos, E.E. Lagoudianakis, D. Grosomanidis, N. Koronakis, D. Tsekouras, J. Chrysikos, K. Filiis, A. Manouras, Management of incidental left-sided gallbladder, *JLS* 13 (April–June (2)) (2009) 273–275 (PMid:19660232).
- [16] I. Qureshi, Z. Awad, Aberrant presentation of the gallbladder during laparoscopic cholecystectomy, *JLS* 13 (4) (2009) 605–607, <http://dx.doi.org/10.4293/108680809X12589999538075> (PMid:20042126).
- [17] S. Sadhu, T.A. Jahangir, M.K. Roy, Left-sided gallbladder discovered during laparoscopic cholecystectomy in a patient with dextrocardia, *Indian. J. Surg.* 74 (April (2)) (2012) 186–188, <http://dx.doi.org/10.1007/s12262-011-0261-2> (PMid:23542707).
- [18] R. Kawai, K. Miyata, N. Yuasa, E. Takeuchi, Y. Goto, H. Miyake, H. Nagai, M. Hattori, J. Imura, Y. Hayashi, J. Kawakami, Y. Kobayashi, True left-sided gallbladder with a portal anomaly: report of a case, *Surg. Today* (2012), <http://dx.doi.org/10.1007/s00595-011-0093-5> (PMid:22160358).
- [19] A. Makni, H. Magherbi, R. Ksantini, W. Rebai, Z.B. Safta, Left-sided gallbladder: an incidental finding on laparoscopic cholecystectomy, *Asian J. Surg.* 35 (2) (2012) 93–95, <http://dx.doi.org/10.1016/j.asjsur.2012.04.011> (PMid:22720865).
- [20] C. Nastos, A. Vezakis, I. Papaconstantinou, T. Theodosopoulos, V. Koutoulidis, G. Polymeneas, Methods of safe laparoscopic cholecystectomy for left-sided (sinistroposition) gallbladder: a report of two cases and a review of safe techniques, *Int. J. Surg. Case Rep.* 5 (10) (2014) 769–773, <http://dx.doi.org/10.1016/j.ijscr.2014.08.018> (PMid:25262322).

Open Access

This article is published Open Access at sciencedirect.com. It is distributed under the [IJSCR Supplemental terms and conditions](#), which permits unrestricted non commercial use, distribution, and reproduction in any medium, provided the original authors and source are credited.