



Since January 2020 Elsevier has created a COVID-19 resource centre with free information in English and Mandarin on the novel coronavirus COVID-19. The COVID-19 resource centre is hosted on Elsevier Connect, the company's public news and information website.

Elsevier hereby grants permission to make all its COVID-19-related research that is available on the COVID-19 resource centre - including this research content - immediately available in PubMed Central and other publicly funded repositories, such as the WHO COVID database with rights for unrestricted research re-use and analyses in any form or by any means with acknowledgement of the original source. These permissions are granted for free by Elsevier for as long as the COVID-19 resource centre remains active.



Contents lists available at ScienceDirect

Journal of Clinical Neuroscience

journal homepage: www.elsevier.com/locate/jocn

Case report

Guillain Barre Syndrome following delivery in a pregnant woman infected with SARS-CoV-2

Arzu Bilge Tekin^{a,*}, Umit Zanapalioglu^b, Selcen Gulmez^c, Ilkyaz Akarsu^c, Murat Yassa^a, Niyazi Tug^d^a Department of Obstetrics and Gynecology, Sehit Prof. Dr. Ilhan Varank Training and Research Hospital, Istanbul, Turkey^b Department of Neurology, Sehit Prof Dr Ilhan Varank Sancaktepe Training and Research Hospital, Health Sciences University, Istanbul, Turkey^c Department of Obstetrics and Gynecology, Sehit Prof. Dr. Ilhan Varank Training and Research Hospital, Istanbul, Turkey^d Department of Obstetrics and Gynecology, Sehit Prof. Dr. Ilhan Varank Training and Research Hospital, Istanbul, Turkey

ARTICLE INFO

Article history:

Received 20 December 2020

Accepted 16 January 2021

Keywords:

SARS-CoV-2

Guillain-Barre Syndrome

Pregnancy

Postpartum

ABSTRACT

Effects of SARS-CoV-2 on the neurological system have been investigated. Evidence of Guillain-Barre Syndrome (GBS) cases associated with SARS-CoV-2 infection have recently been reported. A 34-year-old multiparous woman with COVID-19 infection at her 37th (4/7) gestational week was presented here. She was diagnosed with Guillain Barre Syndrome at postpartum. As we know recently this was the first case mentioned in the literature. The clinical course of GBS with COVID-19 after childbirth may be similar to GBS patients not infected with COVID-19.

© 2021 Elsevier Ltd. All rights reserved.

1. Introduction

The current SARS-CoV-2 pandemic mainly involves the respiratory system. However, data about the potential neurotropism of SARS-CoV-2 is emerging and currently, several epidemiologic clinical studies, case series and reports worldwide have demonstrated that a considerable number of patients with COVID-19 may develop neurological symptoms and complications affecting both central and peripheral nervous system and skeletal muscles [1].

GBS is a rare neurological disease that is characterized by progressive weakness in legs and arms, areflexia or decreased tendon reflexes in weak limbs [2]. Evidence of GBS cases associated with SARS-CoV-2 infection have recently been reported [3]. To the best of our knowledge, GBS in a pregnant woman infected with SARS-CoV-2 is not yet reported in the literature. Herein, the first case in the literature of a woman infected with COVID-19 diagnosed with GBS following delivery by cesarean section was discussed.

2. Case

A 34-year-old multiparous woman at her 37th (4/7) gestational week was admitted to our clinic dedicated for COVID-19 pandemic with mild cough and close contact history. She had no comorbidity,

was afebrile and her physical examination was unremarkable with blood pressure 110/70 mmHg, heart rate 78 bpm, respiratory rate 17/minute, and oxygen saturation of 97% on room air. Her obstetrical assessment was found to be normal. Her low-dose chest computed tomography (CT) scan was consistent with COVID-19 pneumonia (Fig. 1). Maternal lung ultrasonography revealed broken pleura line, multiple B-lines and small subpleural consolidations. Her RT-PCR test for SARS-CoV-2 was later reported to be positive. An uneventful cesarean section under general anesthesia was performed due to fetal distress on the following day. A 2920-gram male baby was delivered with a 1st and 5th minutes APGAR scores of 8 and 9 respectively. The newborn was admitted to the neonatal intensive care unit (ICU) upon transient tachypnea of the newborn. She was initiated on a medical treatment according to the national guidelines with hydroxychloroquine 400 mg/day, azithromycin 250 mg/day. She was discharged on postoperative 5th day following a negative RT-PCR testing for SARS-CoV-2.

On the 16th day she was admitted to ER with a one week history of low back pain, ascending weakness and numbness that started in lower extremities, difficulty by walking. Her neurological examination revealed muscle weakness which was more prominent in lower extremities with a muscle strength of 1/5 in lower and 4/5 in upper extremities; right sided facial paresis, decreased sensation in extremities. Deep tendon reflexes were absent in upper and lower extremities. Serum biochemical investigations were unremarkable. Cerebrospinal fluid (CSF) analysis revealed an increased level of protein (62.34 g/L), glucose level was normal

* Corresponding author at: Emek Mahallesi, Namik Kemal Caddesi, No: 54, 34785 Sancaktepe, Istanbul, Turkey.

E-mail address: arzubilgetekin@gmail.com (A.B. Tekin).

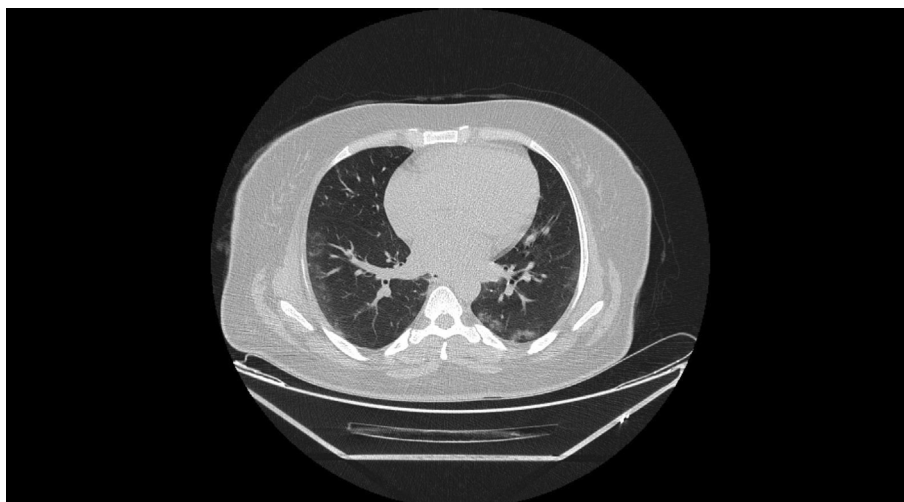


Fig. 1. Chest computed tomography.

and there were no white blood cells. RT-PCR testing was found negative in CSF fluid at that time. This testing was made with the same procedure like nasopharyngeal In addition RT-PCR. The CSF culture result was viewed as negative. Nerve conduction studies revealed decreased amplitude of compound muscle action potentials and no response of sensory action potentials except right sural nerve. F responses could not be recorded (Table 1). According to these findings acute motor-sensory axonal neuropathy variant of GBS was considered. On the following day she was started on 0.4 mg/kg/day intravenous immunoglobulin (IVIG) treatment for 5 days, Enoxaparin sodium 6000 anti-Xa IU/0.6 ml and pregabalin 300 mg/day. After an initial worsening of the motor symptoms and development of shortness of breath and dysphagia; her symptoms had begun to improve after completion of IVIG therapy. Her muscle strength was gradually recovered and oral fluid intake was initiated on the completion of IVIG therapy. She was discharged on the 12th day of the admission following substantial progress with muscle strength of 5/5 in upper limbs and 3/5 in lower limbs. She is currently under enhanced physiotherapy and her clinical condition

is improving gradually. The timeline of the case between the first admission and the discharge is summarized in Fig. 2. Written consent form was signed by the patient and institutional permission was taken.

3. Discussion

To the best of our knowledge this is the first reported case of a pregnant woman diagnosed with GBS attributed to the COVID-19 infection after a childbirth.

GBS is a rare condition in pregnancy and the risk for GBS increases following childbirth [4]. GBS has a very low incidence during pregnancy with an estimated incidence of 1.2 to 1.6/100,000 population [5]. GBS occurs in all trimesters of pregnancy and during the postpartum period but particularly more common during the third trimester and first 2 week postpartum [6,7]. GBS worsens in the postpartum period due to restoration of cellular immunity, with an increase in delayed type of hypersensitivity which was adaptively depressed during pregnancy [8]. Gupta

Table 1
Nerve conduction study parameters of the patient.

Motor nerve conduction studies				
Nerve	Latency (ms)	Amplitude (mV)	CV m/s	F Latency ms
Right median-APB				
Wrist	14.1	0.6		
Elbow	22.9	0.5	28	NR
Right Ulnar-ADM				
Wrist	5.42	1.6	51	
B. Elbow	9.9	1.2	53	
A. Elbow	11.4	1.0		NR
Right peroneal-EDB				
Ankle	5.8	0.9		
Fib head	13.6	0.3	37	
Pop fossa	19.4	0.1	15	
Right tibial-AH				
Ankle	9.6	0.5	44	
Pop fossa	17.8	0.5		NR
R.Facial-M.Nasalis	5.1	0.8		
Sensory nerve conduction studies				
Nerve	Latency (ms)	Amplitude (mV)	CV m/s	
Right median	NR			
Right ulnar	NR			
Right sural	2.5	22.9	58	

*NR: not responsive; APB: abductor pollicis brevis; ADM: abductor digiti minimi; ADB: extensor digitorum brevis; AH: abductor hallucis.

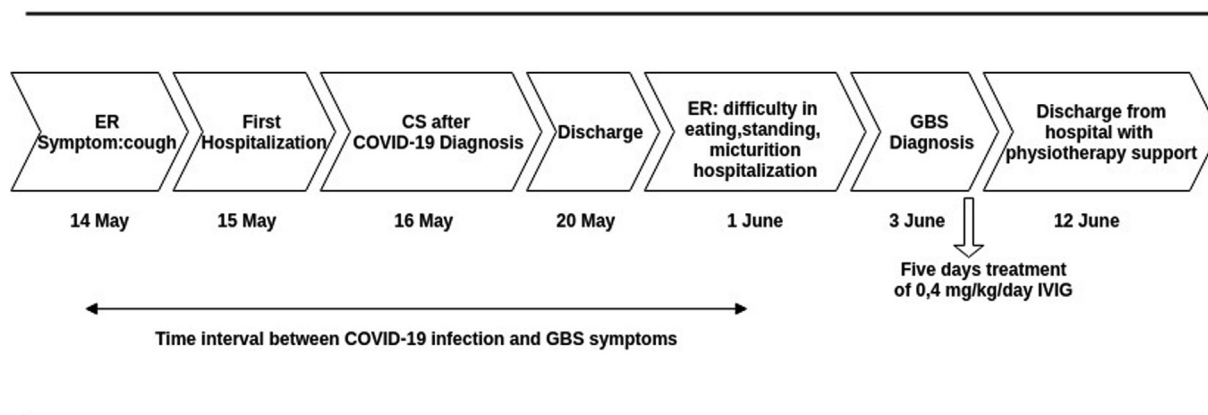


Fig. 2. The timeline of the case.

et al reported 3 cases of GBS, one appeared immediately after cesarean section and other two occurred between the 5th and 6th week postpartum [9]. In a study which analyzed the records of 47 patients with pregnancy and GBS, one patient presented in first trimester, seven patients (14.89%) were in second trimester, 15 (31.2%) were in third trimester and remaining 24 (51%) were presented in postpartum especially within 2 weeks (sharma). Pregnant women with GBS have a mild clinical course and response well to immunomodulation therapy [5]. Similarly, the clinical severity of the current case was mild to moderate and responded to the treatment. Sixtytwo cases diagnosed as GBS associated with COVID-19 were reported so far in the literature during this pandemic [10]. However, eighteen patients required artificial ventilation and two patients died (10). In an observational multicentre study from Italy which included thirty GBS associated with COVID-19 stated that COVID-19-associated GBS is predominantly demyelinating and seems more severe than non-COVID-19 GBS [11].

It was previously proposed that the neuropathological effects of coronavirus infections were caused from immune-mediated processes, either by the direct invasion of virus or due to the molecular changes resulting from the systemic inflammatory response [12]. Since the virus has not been demonstrated in CSF and pathological evidence of peripheral nerve invasion is currently unavailable, a direct role of SARS-CoV-2 in nerve damage remains uncertain [13]. In the present case, RT-PCR testing was found negative in the CSF fluid as reported in the literature previously [14] that excludes the direct invasion of SARS-CoV-2 virus and supporting the role of immunological mechanisms.

The pregnancy seems not to change the interval between the diagnosis of COVID-19 and the onset of GBS symptoms as it was about ten to seventeen days similar to the literature. Latency between onset of COVID-19 and GBS ranged from 3 to 33 days at last review [10]. On the other hand, delay in diagnosis is common in pregnancy or early postpartum period because the initial non-specific symptoms may resemble changes in the pregnancy [15].

4. Conclusion

The clinical course of GBS following childbirth in pregnant women diagnosed with COVID-19 may be similar to GBS patients not infected with COVID-19. Early diagnosis and multidisciplinary approach are essential.

References

- [1] Keyhanian K, Umeton RP, Mohit B, Davoudi V, Hajighasemi F, Ghasemi M. SARS-CoV-2 and nervous system: from pathogenesis to clinical manifestation. *J Neuroimmunol* 2020;577436. <https://doi.org/10.1016/j.jneuroim.2020.577436>.
- [2] Sejvar JJ, Baughman AL, Wise M, Morgan OW. Population incidence of Guillain-Barré syndrome: a systematic review and meta-analysis. *Neuroepidemiology* 2011;36(2):123–33. <https://doi.org/10.1159/000324710>.
- [3] Ellul M, Benjamin L, Singh B, et al. Neurological Associations of COVID-19. Available at SSRN 3589350; 2020. 10.2139/ssrn.3589350
- [4] Jiang GX, Pedro-Cuesta J, Strigård K, et al. Pregnancy and Guillain-Barré syndrome: a nationwide register cohort study. *Neuroepidemiology* 1996;15(4):192–200. <https://doi.org/10.1159/000109907>.
- [5] Jayaharan N, Samivel B, Ranganathan L, et al. Profile of patients with Guillain-Barré syndrome during pregnancy in a tertiary care hospital in South India. (4370). *AAN Enterprises* 2020;94(15).
- [6] Zeeman GG. A case of acute inflammatory demyelinating polyradiculoneuropathy in early pregnancy. *Am J Perinatol* 2001;18:213–6. <https://doi.org/10.1055/s-2001-15506>.
- [7] Sharma SR, Sharma N, Masaraf H, Singh SA. Guillain-Barré syndrome complicating pregnancy and correlation with maternal and fetal outcome in North Eastern India: a retrospective study. *Ann Indian Acad Neurol* 2015;18:215–8. 10.4103%2F0972-2327.150608.
- [8] Meenakshi-Sundaram S, Swaminathan K, Karthik S, et al. Relapsing Guillain-Barre syndrome in pregnancy and postpartum. *Ann Indian Acad Neurol* 2014;17(3):352. 10.4103%2F0972-2327.138527.
- [9] Gupta A, Patil M, Khanna M, Krishnan R, Taly AB. Guillain-Barre syndrome in postpartum period: Rehabilitation issues and outcome—Three case reports. *J Neurosci Rural Pract* 2017;8(3):475. 10.4103%2Fjnnp.jnnp.474_16.
- [10] Finsterer J, Scorza FA, Fiorini AC. SARS-CoV-2-associated Guillain-Barre syndrome in 62 patients. *Eur J Neurol* 2020. <https://doi.org/10.1111/ene.14544>.
- [11] Filosto M, Cotti Piccinelli S, Gazzina S, et al. Guillain-Barré syndrome and COVID-19: an observational multicentre study from two Italian hotspot regions. *J Neurol Neurosurg Psychiatry* Published Online First November 2020;06. <https://doi.org/10.1136/jnnp-2020-324837>.
- [12] Kim JE, Heo JH, Kim HO, Song SH, Park SS, Park TH, Choi JP. Neurological complications during treatment of middle east respiratory syndrome. *J Clin Neurol* 2017;13(3):227–33. 10.3988%2Fjcn.2017.13.3.227.
- [13] Uncini A, Vallat JM, Jacobs BC. Guillain-Barré syndrome in SARS-CoV-2 infection: an instant systematic review of the first six months of pandemic. *J Neurol Neurosurg Psychiatry* 2020;91:1105–10. <https://doi.org/10.1136/jnnp-2020-324491>.
- [14] Manganotti P, Bellavita G, D'Acunto L, Tommasini V, Fabris M, Sartori A, et al. Clinical neurophysiology and cerebrospinal liquor analysis to detect Guillain-Barré syndrome and polyneuritis cranialis in COVID-19 patients: a case series. *J Med Virol* 2020. <https://doi.org/10.1002/jmv.26289>.
- [15] Zafar MS, Naqash MM, Bhat TA, Malik GM. Guillain Barre syndrome in pregnancy: an unusual case. *J Family Med Prim Care* 2013;2:90–1. 10.4103%2F2249-4863.109965.