

Perianeurysmal cyst formation in the brainstem after coil embolization: illustrative case

Hiroki Kobayashi, MD, Yukiko Enomoto, MD, PhD, Tetsuya Yamada, MD, PhD, Yusuke Egashira, MD, PhD, Noriyuki Nakayama, MD, PhD, Naoyuki Ohe, MD, PhD, and Toru Iwama, MD, PhD

Department of Neurosurgery, Gifu University Hospital, Gifu, Japan

BACKGROUND Perianeurysmal cysts in the brainstem after endovascular coil embolization are rare, and their underlying mechanism remains unclear. The authors reported a case of a postcoiling perianeurysmal cyst that developed 6 years after endovascular coil embolization for a ruptured aneurysm and reviewed the related literature.

OBSERVATIONS A 77-year-old woman had a history of subarachnoid hemorrhage 6 years earlier. The ruptured large left vertebral artery–posterior inferior cerebellar artery aneurysm was treated with endovascular coil embolization. Two years later, the aneurysm regrew and perianeurysmal brainstem edema was detected on magnetic resonance imaging (MRI); stent-assisted coil embolization combined with low-flow bypass was performed. Follow-up MRI showed that the perianeurysmal edema gradually transformed into a perianeurysmal cyst over the next 3 years. Finally, the perianeurysmal cyst caused gait disturbance with ataxia, and the patient received cyst puncture. After surgery, the symptom was immediately improved.

LESSONS The authors reported, for the first time, postcoiling of perianeurysmal cyst formation treated by cyst puncture. If perianeurysmal edema is detected after endovascular coil embolization, especially for large aneurysms, it is necessary to consider progression to cyst formation and follow up over time. In addition, cyst puncture is effective, depending on the symptoms and the lesion.

<https://thejns.org/doi/abs/10.3171/CASE21690>

KEYWORDS perianeurysmal cyst formation; perianeurysmal edema; vertebral artery-posterior inferior cerebellar artery aneurysm; coil embolization; brainstem

Cyst formation in the perianeurysmal brain tissue after endovascular coil embolization is a rare complication and is termed a “perianeurysmal cyst.” Only 19 cases of perianeurysmal cyst have been reported.¹ We present a case of symptomatic perianeurysmal cyst in the brainstem that developed 6 years after endovascular coil embolization for a ruptured left vertebral artery–posterior inferior cerebellar artery (VA-PICA) aneurysm.

Illustrative Case

A 77-year-old woman had a history of subarachnoid hemorrhage (Hunt and Kosnik grade I) 6 years earlier. Initial digital subtraction angiography (DSA) revealed a ruptured left VA-PICA aneurysm 11.5 × 12 mm; Fig. 1). The aneurysm was treated with endovascular

balloon-assisted coil embolization using bare platinum and hydrogel-coated coils. The aneurysmal neck was intentionally left to maintain patency of the PICA; thus, postembolization DSA demonstrated a residual neck. The patient’s clinical course after treatment was good, without any neurological symptoms. The patient was discharged with a modified Rankin Scale score of 0 and was followed up with magnetic resonance imaging (MRI) every 6 months. After discharge, she could do everything independently in her daily life.

However, her 2-year follow-up MRI showed recurrence of the aneurysm and perianeurysmal edema in the left medulla oblongata on fluid-attenuated inversion recovery sequence. She had no symptoms at the time. The recurrent aneurysm was treated using a prophylactic occipital artery–PICA (OA-PICA) bypass and subsequent

ABBREVIATIONS CT = computed tomography; DSA = digital subtraction angiography; MRI = magnetic resonance imaging; OA-PICA = occipital artery–posterior inferior cerebellar artery; VA-PICA = vertebral artery–posterior inferior cerebellar artery.

INCLUDE WHEN CITING Published May 30, 2022; DOI: 10.3171/CASE21690.

SUBMITTED December 8, 2021. **ACCEPTED** March 29, 2022.

© 2022 The authors, CC BY-NC-ND 4.0 (<http://creativecommons.org/licenses/by-nc-nd/4.0/>).

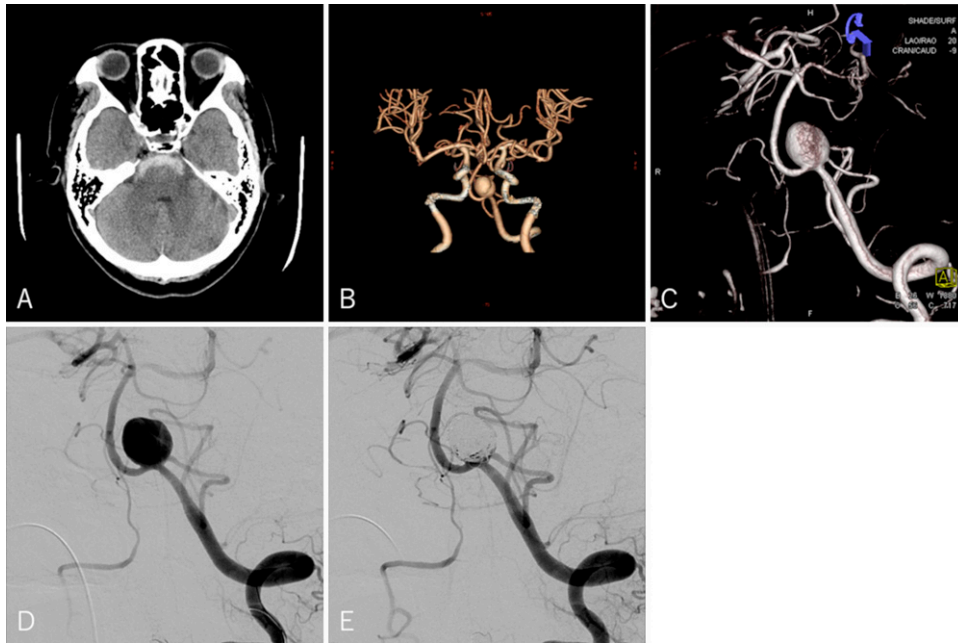


FIG. 1. CT, CT angiography (CTA), and DSA on the patient's first admission to our hospital. **A:** CT showing subarachnoid hemorrhage in the prepontine cistern. **B:** CTA showing the VA-PICA aneurysm (11.5 × 12 mm). **C:** Three-dimensional (3D) DSA demonstrated a wide aneurysm neck and the PICA branched off from the neck of the aneurysm. **D:** DSA before endovascular coil embolization. **E:** DSA after endovascular coil embolization. We used bare platinum coils and hydrogel-coated coils (Axium coil, Medtronic; Galaxy CF, Johnson & Johnson; HydroSoft, TERUMO Microvention).

additional stent-assisted coil embolization (Fig. 2). PICA-sacrificed complete embolization was attempted, but at the final stage of embolization, the jailed microcatheter was kicked out from the aneurysm before occlusion of the PICA orifice. Therefore, the PICA was preserved, and the flow signal of the OA-PICA bypass was gradually diminished and finally disappeared on 1-year follow-up MR angiography. The perianeurysmal edema gradually changed into a perianeurysmal cyst over the next 3 years. The size of the cyst increased every year, and the cyst extended upward to the pons level (Fig. 3). When it reached 25 mm, the patient presented gait disturbance with ataxia and was readmitted to our hospital.

Her Glasgow Coma Scale score was 15. The manual muscle testing score was grade 5 in both the upper and lower limbs. The patient was able to walk with a cane but wobbled significantly. She could not maintain her trunk in the sitting position, and a backward fall was observed. The patient's laboratory results were unremarkable. Computed tomography (CT)-guided cyst puncture through the right cerebellar peduncle and percutaneous aspiration via the Ommaya reservoir system were planned to shrink the cyst and reduce the mass effect on the brainstem (Fig. 4). Anatomical orientations such as the venous sinus, the fourth ventricle, and the aneurysm were confirmed before the operation, and the puncture point and route were planned with Navigation Application (Brain-Lab). The Ommaya reservoir (5.7 cm long) was placed along the path of the puncture needle. A viscous liquid was drawn from the cyst. The number of cells and protein in the liquid were 5/μL and 47 mg/dL, respectively. Approximately 2 mL of aspiration was obtained during the surgery. On postoperative day (POD) 3 and POD 5, approximately 1 mL of percutaneous aspiration was obtained via

the Ommaya reservoir system. The number of proteins was high (418 mg/dL) on POD 3. Postural instability improved on POD 5. After these intermittent aspirations, the cyst had shrunk a little and had not expanded anymore, so the Ommaya reservoir was removed 1 month after surgery (Fig. 5).

The patient was discharged after rehabilitation, and we followed up at the outpatient department. No significant cyst recurrence has been observed during the 1-year follow-up period, and no additional treatment was required.

Discussion

We present a rare case of a perianeurysmal cyst in the brainstem that developed 6 years after endovascular coil embolization for a ruptured VA-PICA aneurysm. The mechanism of perianeurysmal cyst formation is not well known because only 19 cases of perianeurysmal cyst formation after endovascular coil embolization have been reported.¹

Hydrogel-coated coils, which reduce aneurysm recurrence by allowing for increased packing density,² were used in this case. The hydrogel-coated coils versus bare platinum coils for the endovascular treatment of intracranial aneurysms (HELPS) trial showed that using hydrogel-coated coils reduces aneurysm rupture after endovascular coil embolization.³ However, the frequency of hydrocephalus was high, in the range of 15.2% to 18.7%.¹ Perianeurysmal edema and aseptic meningitis are rare but have also been reported in cases of hydrogel-coated coils in other reports.^{4–6} Perianeurysmal edema and hydrocephalus were also reported after the use of bare platinum coils;⁷ therefore, it is not considered to be due to the hydrogel itself. After endovascular coil embolization, aneurysmal

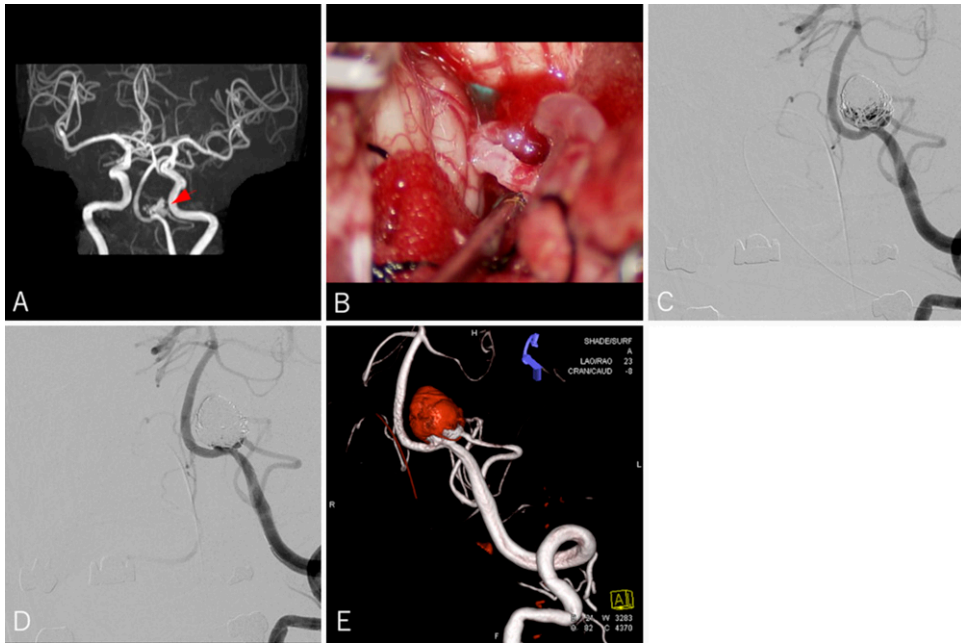


FIG. 2. MR angiography (MRA) showing recurrence 2 years after the first endovascular coil embolization. OA-PICA bypass and endovascular coil embolization were performed. **A:** MRA showing recurrence (*arrow*). **B:** OA-PICA bypass was performed to maintain PICA patency. **C:** DSA before endovascular coil embolization. Coil compaction was detected. **D:** DSA after endovascular coil embolization. We used bare platinum coils (Axium coil, Medtronic; Galaxy CF, Johnson & Johnson; Galaxy, Johnson & Johnson), an ED coil (Kaneka Medical Products), and a stent (LVIS Jr, TERUMO Microvention). **E:** 3D DSA after endovascular coil embolization.

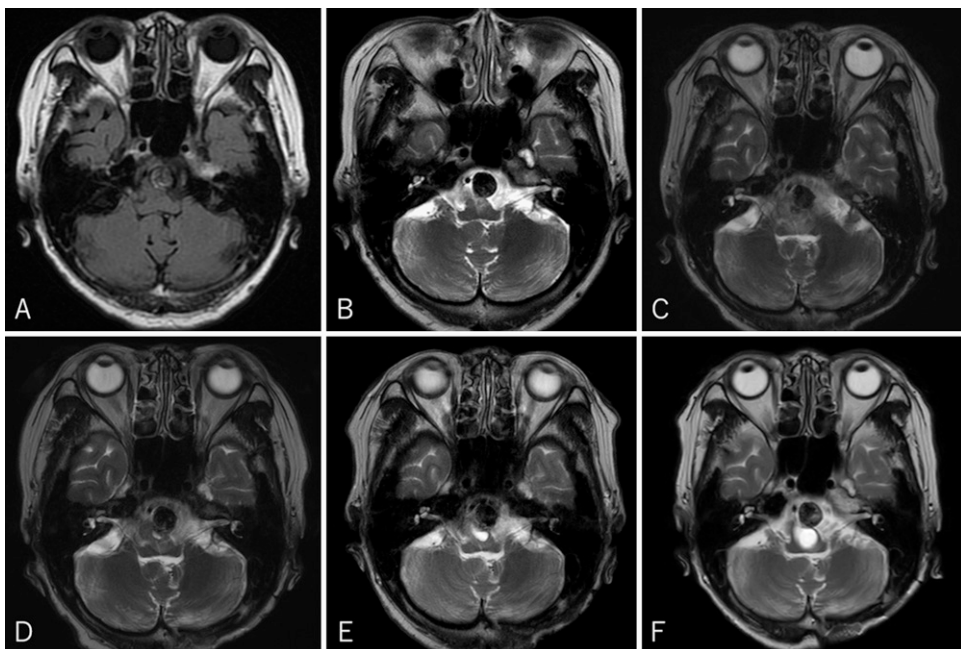


FIG. 3. The perianeurysmal edema had changed to a perianeurysmal cyst during MRI follow-up. **A:** MRI on the patient's first admission to our hospital. **B:** MRI 2 years after the first endovascular coil embolization. The asymptomatic perianeurysmal edema appeared in the left medulla oblongata. **C:** The perianeurysmal edema had deteriorated. **D:** MRI 4 years after the first endovascular coil embolization. The perianeurysmal edema changed to a perianeurysmal cyst formation. **E:** MRI 5 years after the first endovascular coil embolization. The perianeurysmal cyst had enlarged. **F:** MRI 6 years after the first endovascular coil embolization. The perianeurysmal cyst progressed to the pons.

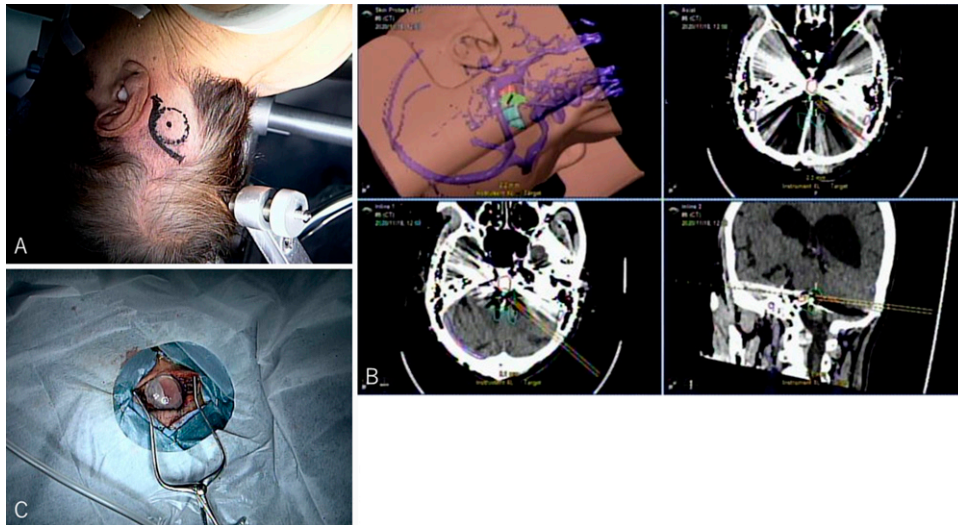


FIG. 4. Transcerebellar peduncle cyst puncture via CT guidance and percutaneous aspiration via the Ommaya reservoir system. **A:** The patient was in a lateral position and her head was fixed with headpins. We made the arcuate skin incision. **B:** The puncture point and the puncture route were planned with Navigation Application (BrainLab). **C:** The Ommaya reservoir was placed.

wall enhancement and progressive thickening of the wall enhancement are known to be significantly associated with perianeurysmal edema,⁸ and they are attributed to inflammatory reactions. Endovascular coil embolization causes thrombus formation within aneurysms, and activated platelets release different cytokines, which may lead to inflammatory reactions.⁹ Perianeurysmal edema is related to

not only aneurysm recanalization or regrowth¹⁰ but also other factors, such as the size of aneurysms, increase in the volume of aneurysms due to the coil-thrombus complex, effect of hemodynamic stress, and progressive enlargement of aneurysms.¹¹

The mechanism of perianeurysmal cysts has been reported to be related to previous hemorrhage, ischemic encephalomalacia,

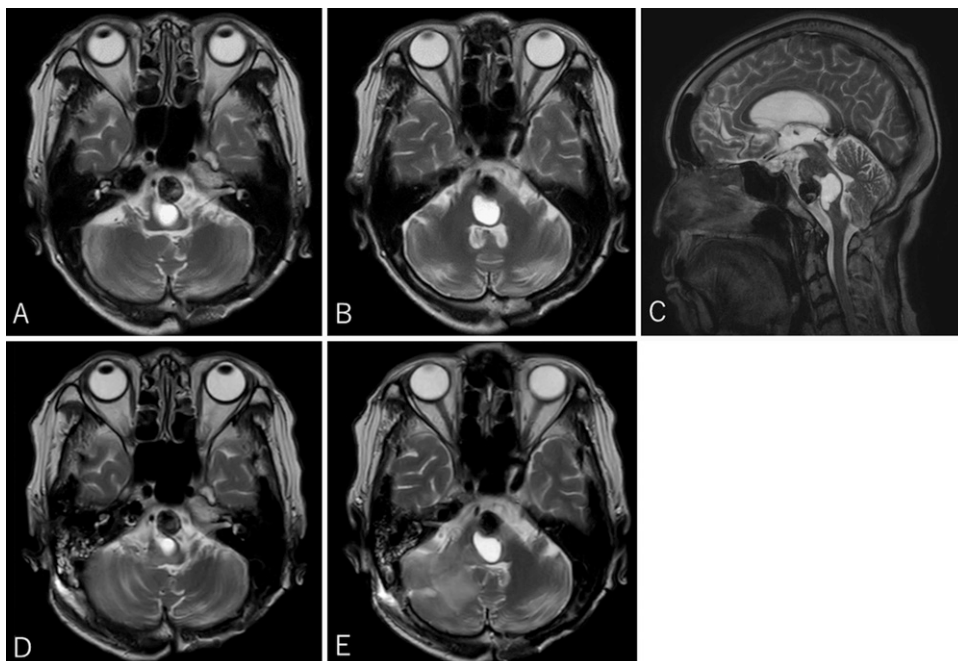


FIG. 5. **A–C:** MRI 6 years after the first endovascular coil embolization. The perianeurysmal cyst in the pons and the medulla oblongata. The size of the perianeurysmal cyst formation was ~25 mm. **D and E:** MRI on POD 38. The perianeurysmal cyst has shrunk.

inflammation associated with thrombus formation and cytokines, and angiogenic factors.^{1,12–16} Based on these considerations, perianeurysmal edema and perianeurysmal cysts have similar mechanisms and may be related phenomena.

In this case, the aneurysm was large; therefore, hydrogel-coated and bare platinum coils were used. The coil–thrombus complex and inflammatory reaction after embolization may be related to the perianeurysmal edema and perianeurysmal cyst. Because the perianeurysmal cyst became symptomatic, we performed transcerebellar peduncle cyst puncture via CT guidance and percutaneous aspiration via the Ommaya reservoir system, and the patient's symptoms improved.

Although perianeurysmal cyst formation after endovascular coil embolization is rare, the possibility of perianeurysmal edema progressing to a perianeurysmal cyst cannot be ignored. Therefore, long-term follow-up is necessary.

Observations

The perianeurysmal edema after endovascular coil embolization progressed to a perianeurysmal cyst, which was well treated using CT-guided cyst placement of the Ommaya reservoir system through the right cerebellar peduncle. This treatment has not been previously reported.

Lessons

We encountered a rare case of perianeurysmal cyst formation in the pons and medulla oblongata 6 years after endovascular coil embolization for a ruptured VA-PICA aneurysm. Although the mechanism of perianeurysmal cyst formation remains unclear, it is considered that the perianeurysmal edema progressed due to aneurysmal wall inflammatory response and was transformed into a perianeurysmal cyst. If perianeurysmal edema is detected after endovascular coil embolization, it is necessary to consider the progression to cyst formation and follow up over time.

Acknowledgments

We thank the individuals who contributed to the article preparation but did not fulfill all authorship criteria.

References

1. Liang ES, Efendy M, Winter C, Coulthard A. Intracranial perianeurysmal cysts: case series and review of the literature. *J Neurointerv Surg*. Published online August 11, 2021. doi:<https://doi.org/10.1136/neurintsurg-2021-017807>.
2. Cloft HJ, Kallmes DF. Aneurysm packing with HydroCoil Embolic System versus platinum coils: initial clinical experience. *AJNR Am J Neuroradiol*. 2004;25(1):60–62.
3. White PM, Lewis SC, Gholkar A, et al. Hydrogel-coated coils versus bare platinum coils for the endovascular treatment of intracranial aneurysms (HELPS): a randomised controlled trial. *Lancet*. 2011;377(9778):1655–1662.
4. Deshaies EM, Adamo MA, Boulos AS. A prospective single-center analysis of the safety and efficacy of the hydrocoil embolization system for the treatment of intracranial aneurysms. *J Neurosurg*. 2007;106(2):226–233.
5. Im SH, Han MH, Kwon BJ, Jung C, Kim JE, Han DH. Aseptic meningitis after embolization of cerebral aneurysms using hydrogel-coated coils: report of three cases. *AJNR Am J Neuroradiol*. 2007;28(3):511–512.
6. Horie N, Kitagawa N, Morikawa M, Tsutsumi K, Kaminogo M, Nagata I. Progressive perianeurysmal edema induced after endovascular coil embolization. Report of three cases and review of the literature. *J Neurosurg*. 2007;106(5):916–920.
7. White JB, Cloft HJ, Kallmes DF. But did you use HydroCoil? Perianeurysmal edema and hydrocephalus with bare platinum coils. *AJNR Am J Neuroradiol*. 2008;29(2):299–300.
8. Su IC, Willinsky RA, Fanning NF, Agid R. Aneurysmal wall enhancement and perianeurysmal edema after endovascular treatment of unruptured cerebral aneurysms. *Neuroradiology*. 2014;56(6):487–495.
9. Stracke CP, Krings T, Möller-Hartmann W, Mahdavi A, Klug N. Severe inflammatory reaction of the optic system after endovascular treatment of a supraophthalmic aneurysm with bioactive coils. *AJNR Am J Neuroradiol*. 2007;28(7):1401–1402.
10. Takeshita T, Horie N, Fukuda Y, et al. A ruptured basilar tip aneurysm showing repeated perianeurysmal edema after endovascular coil embolization: case report. *Neurol Med Chir (Tokyo)*. 2015;55(6):519–523.
11. Tomokiyo M, Kazekawa K, Onizuka M, et al. Mechanisms of perianeurysmal edema following endovascular embolization of aneurysms. *Interv Neuroradiol*. 2007;13(suppl 1):145–150.
12. Barber SM, Al-Zubidi N, Diaz OM, Zhang YJ, Lee AG. Delayed hydrocephalus and perianeurysmal cyst formation after stent-assisted coil embolization of a large, unruptured basilar apex aneurysm: a case report and literature review. *Asia Pac J Ophthalmol (Phila)*. 2014;3(6):354–360.
13. Kulwin CG, Gandhi RH, Patel NB, Payner TD. Symptomatic perianeurysmal parenchymal cyst: case illustration. *J Neurosurg*. 2015;123(2):470–471.
14. Benvenuti L, Gagliardi R, Scazzari F, Gaglianone S. Parenchymal perianeurysmal cyst in the brain: case report. *Neurosurgery*. 2006;58(4):E788.
15. Sato N, Sze G, Awad IA, Putman CM, Shibasaki T, Endo K. Parenchymal perianeurysmal cystic changes in the brain: report of five cases. *Radiology*. 2000;215(1):229–233.
16. Jayakumar N, Ughratdar I, White E. Obstructive hydrocephalus secondary to a perianeurysmal cyst: a case report. *Br J Neurosurg*. Published online January 27, 2019. doi:<https://doi.org/10.1080/02688697.2018.1559277>.

Disclosures

Dr. Enomoto reported grants from Sysmex Japan and personal fees from Stryker Japan outside the submitted work. Dr. Iwama reported grants from Ohgaki Tokusuyukai Hospital outside the submitted work. No other disclosures were reported.

Author Contributions

Conception and design: Enomoto, Kobayashi, Yamada, Nakayama, Ohe, Iwama. Acquisition of data: all authors. Analysis and interpretation of data: Enomoto, Kobayashi, Egashira, Ohe, Iwama. Drafting the article: Kobayashi, Yamada, Ohe. Critically revising the article: Enomoto, Kobayashi, Yamada, Egashira, Ohe, Iwama. Reviewed submitted version of manuscript: Enomoto, Kobayashi, Egashira, Nakayama, Ohe, Iwama. Approved the final version of the manuscript on behalf of all authors: Enomoto. Statistical analysis: Kobayashi, Ohe. Administrative/technical/material support: Kobayashi, Ohe, Iwama. Study supervision: Enomoto, Kobayashi, Ohe, Iwama. Planning and execution of stereotactic drainage surgery: Nakayama.

Correspondence

Yukiko Enomoto: Gifu University Graduate School of Medicine, Gifu, Japan. enomoto@gifu-u.ac.jp.