

Treatment of type IV Pipkin fracture in patients with a high BMI via hip arthroscopy-assisted surgery: a case report

Shan-Ling Hsu ^{1,2*}, Chung-Yang Chen¹ and Chi-Hsiang Hsu¹

¹Department of Orthopaedic Surgery, Kaohsiung Chang Gung Memorial Hospital and Chang Gung University College of Medicine, 123, Ta Pei Road, Niao Sung Dist., Kaohsiung, Taiwan and

²Department of Nursing, Fooyin University, 151 Jinxue Rd, Daliao Dist., Kaohsiung, Taiwan.

*Correspondence to: S.-L. Hsu. E-mail: shanlin@adm.cgmh.org.tw; hsishanlin@yahoo.com.tw
Submitted 11 August 2020; Revised 21 September 2020

ABSTRACT

Pipkin type IV femoral head (FH) fracture–dislocations are usually treated via open surgery. There are many surgical approaches for the treatment of this difficult fracture depending on the fracture pattern. Obesity presents another challenging problem in surgical treatment and sometimes leads to a poorer outcome. We discuss herein a patient of a high body mass index (BMI) with a Pipkin type IV FH fracture who underwent open reduction internal fixation (ORIF) of acetabular fracture with reconstruction plates and hip arthroscopy-assisted fixation of the FH fracture with two Herbert screws via the posterior approach. The intra-articular osteochondral loose bodies were excised by hip arthroscopy simultaneously. The joint congruency and screw positions were checked during surgery by arthroscopy. After 6 months, clinical and computed tomography (CT) follow-ups showed excellent results. The patient of a high BMI recovered immediately and had a satisfactory short-term outcome after hip arthroscopy-assisted surgery. We concluded that hip arthroscopy-assisted surgery is a viable option for the treatment of Pipkin type IV FH fracture–dislocations.

INTRODUCTION

Femoral head (FH) fractures are severe and uncommon high-energy injuries and may be associated with hip dislocation and fracture of the acetabulum. Such injuries have been reported to be related to poor functional outcomes and a high rate of complications [1–5]. Early reduction, stabilization and rigid fixation are well-established methods by which to achieve stable and congruent articulation, minimizing potential complications. Although Matsuda has demonstrated the techniques and feasibility of safe arthroscopic reduction and internal fixation of femoral head fractures, there are no published reports on arthroscopic femoral head fracture fixation in the setting of acetabular fractures (i.e. Pipkin 4) [6–8].

There are various surgical approaches by which to manage FH fractures associated with acetabular fractures [9–12]. However, there remains controversy with regards to the

best treatment method with limited exposure of the femoral head.

Body mass index (BMI) is used to classify overweight and obese adults. A high BMI (>35) presents a challenging problem and results in poorer post-operative outcomes in a variety of surgical procedures for the treatment of acetabular fractures [13–16]. Hip arthroscopy-assisted surgery for hip trauma provides a less-invasive procedure for diagnosis and treatment [17–20]. However, some studies that evaluated the short-term results in the setting of obesity demonstrated inferior outcomes and higher rates of reoperation after hip arthroscopy [13, 21, 22]. It has been hypothesized that hip arthroscopy-assisted surgery may become a viable method for the treatment of FH fracture dislocation associated with fracture of the acetabulum in patients of a high BMI. Appropriate use of arthroscopic techniques may also decrease morbidity. Herein, we

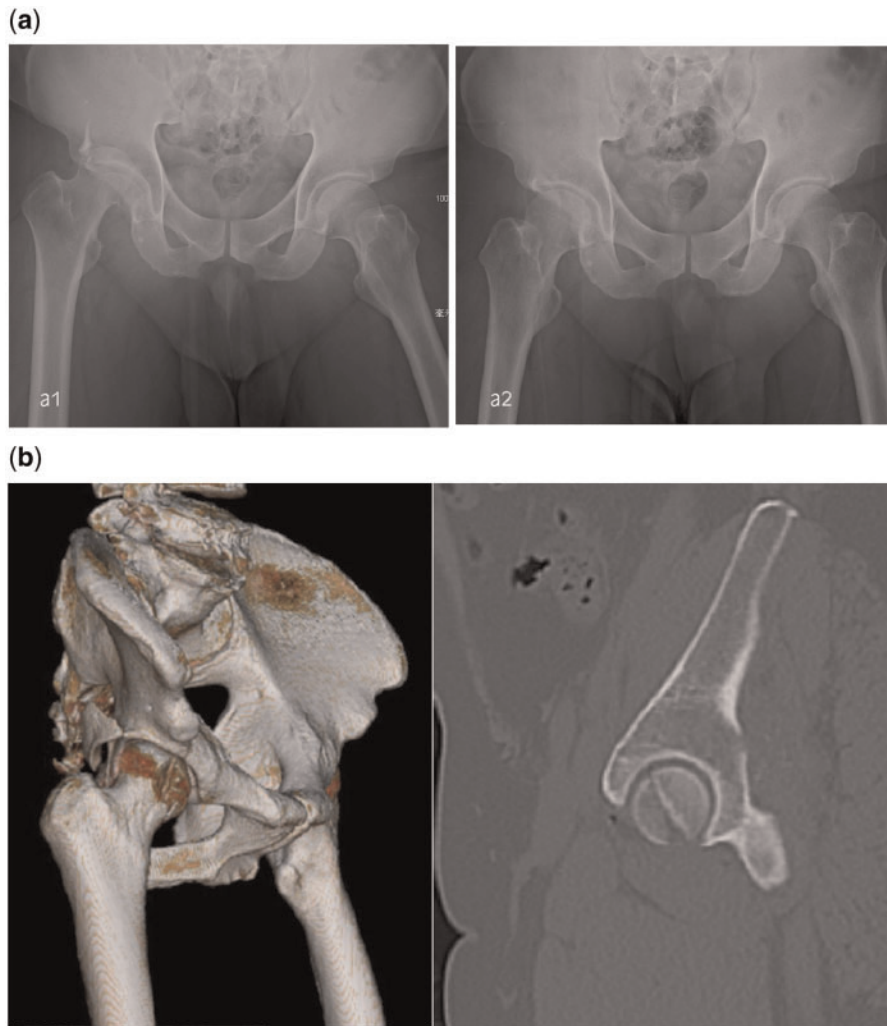


Fig. 1. (a and b). (a1–2) A 36-year-old man with a right hip fracture–dislocation after motorcycle accident at initial plain radiographs and was reduced by closed manipulation promptly. (b1–2) Preoperative radiography of three-dimensional computed tomography image showing the right femoral head fracture–dislocation and acetabular posterior wall fracture.

discuss the clinical case of a patient of a high BMI with a type IV Pipkin FH fracture treated using a posterior approach and hip arthroscopy-assisted surgery with a successful outcome.

CASE REPORT

A 36-year-old man (BMI: 44, body weight: 135 kg, body length: 175 cm) was transferred to our emergency department after a motorcycle accident. He sustained a right hip posterior fracture–dislocation according to initial plain radiographs, which was reduced by closed manipulation promptly. There was no neurovascular damage of the lower extremity. Follow-up plain radiographs confirmed the reduced hip joint with a displaced posterior acetabular fracture and intra-articular osteochondral loose bodies. A

3D-computed tomography (CT) scan showed that the FH fracture was associated with a posterior acetabular fracture, Pipkin type IV (Fig. 1). After in-depth discussion with the patient, it was agreed that the open reduction internal fixation (ORIF) procedure combined with hip arthroscopy-assisted surgery via the posterior approach would be performed. The patient underwent ORIF 6 days' post-injury with reconstruction plates for the posterior acetabular wall fracture and combined hip arthroscopy-assisted surgery using two Herbert screws for internal fixation of the FH fracture, with removal of intra-articular osteochondral loose bodies through a single-incision. Post-operative plain radiographs showed anatomic reduction of the FH and posterior wall fractures. The patient was able to walk under non-weight-bearing conditions for 2 months after surgery

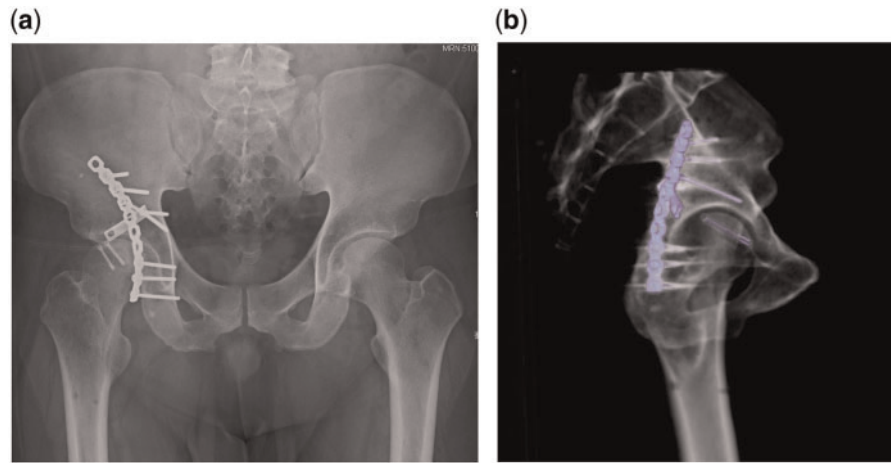


Fig. 2. (a) Post-operative plain radiograph after 3 months showing Pipkin type IV femoral head fracture–dislocation with reconstruction plates and screws fixation. (b) Post-operative 3D computed tomography scan after 3 months verified reduced fracture, femoral head congruency, fracture sites healing and no screw migration.

using crutches. Three-month post-operative CT scans with 3D reconstruction verified healing of the fracture sites and femoral head congruency with no screw migration (Fig. 2). The patient is able to walk without any support or pain at 3 months' post-operation follow-up.

SURGICAL TECHNIQUE

Under general anesthesia, the patient was treated in the lateral decubitus position with the injured hip facing upwards. The injured leg was prepared in an aseptic field for manual traction and manipulation during the surgery. It was noted that the anterior approach may also be prepared in an aseptic field if needed during the surgery. The 20 cm curvilinear incision was made through one-inch posterior to the posterior edge of the greater trochanter and down to the femur shaft using the posterior approach. The subcutaneous tissue and fat were divided sharply, and the fascia and tensor fascia lata along the fascia of the gluteus maximus were incised proximally to dissect the deep short external rotators. The short external rotators were detached after tagging and the posterior acetabular fracture was approached. The injured leg was kept under hip extension and knee flexion to protect the sciatic nerve during the procedure. We did not open the joint capsule, and the capsule attachments to the posterior wall fragments were maintained as much as possible to prevent devascularization. After anatomic reduction of the fracture site with manual traction, Kirchner wires were used for temporary fixation. Two reconstruction plates were applied to restore the congruency and stability of the hip. A mini-incision was then made over the anterior–superior capsule to allow

arthroscopic portals into the hip joint. A monolateral external distractor with Schanz screws fixed at the superior acetabulum and proximal femur was applied to distract and maintain the distention of hip joint with the lower leg in the external rotation position. We used two standard anterior and antero-lateral portals to visualize the hip joint with a 70° arthroscope, which allowed for visualization of the infrafoveal FH fracture site under hip external rotation [23]. The intra-articular soft-tissue lesion with ruptured labrum, ligament teres and small osteochondral fragments were found. Joint irrigation was maintained, in which a sufficient positive intra-articular pressure and a sufficient flow was provided using an automated control pump of 40–45 mmHg. After reduction of the fracture site, percutaneous guide-wires were inserted into the femoral head under fluoroscopic guidance. The fracture fragments were fixed with two 2-mm Herbert screws under arthroscopic guidance, and the screws were engaged into the subchondral bone below the articular surface under arthroscopic guidance. Dynamic fluoroscopic examination confirmed the successful and secure fixation of the FH and acetabular fractures without intra-articular violation by any screws. Some small osteochondral fragments in the hip joint were excised during the surgery (Fig. 3). Owing to the detachment of complex rupture of the labrum or ligament teres, all were excised by partial resection. The posterior capsule and external rotators were sutured in layers after completing the hip arthroscopy-assisted surgery to minimize the potential risk of iatrogenic fluid extravasation and abdominal compartment syndrome. The wound was closed and no suction drains were placed in the joint.

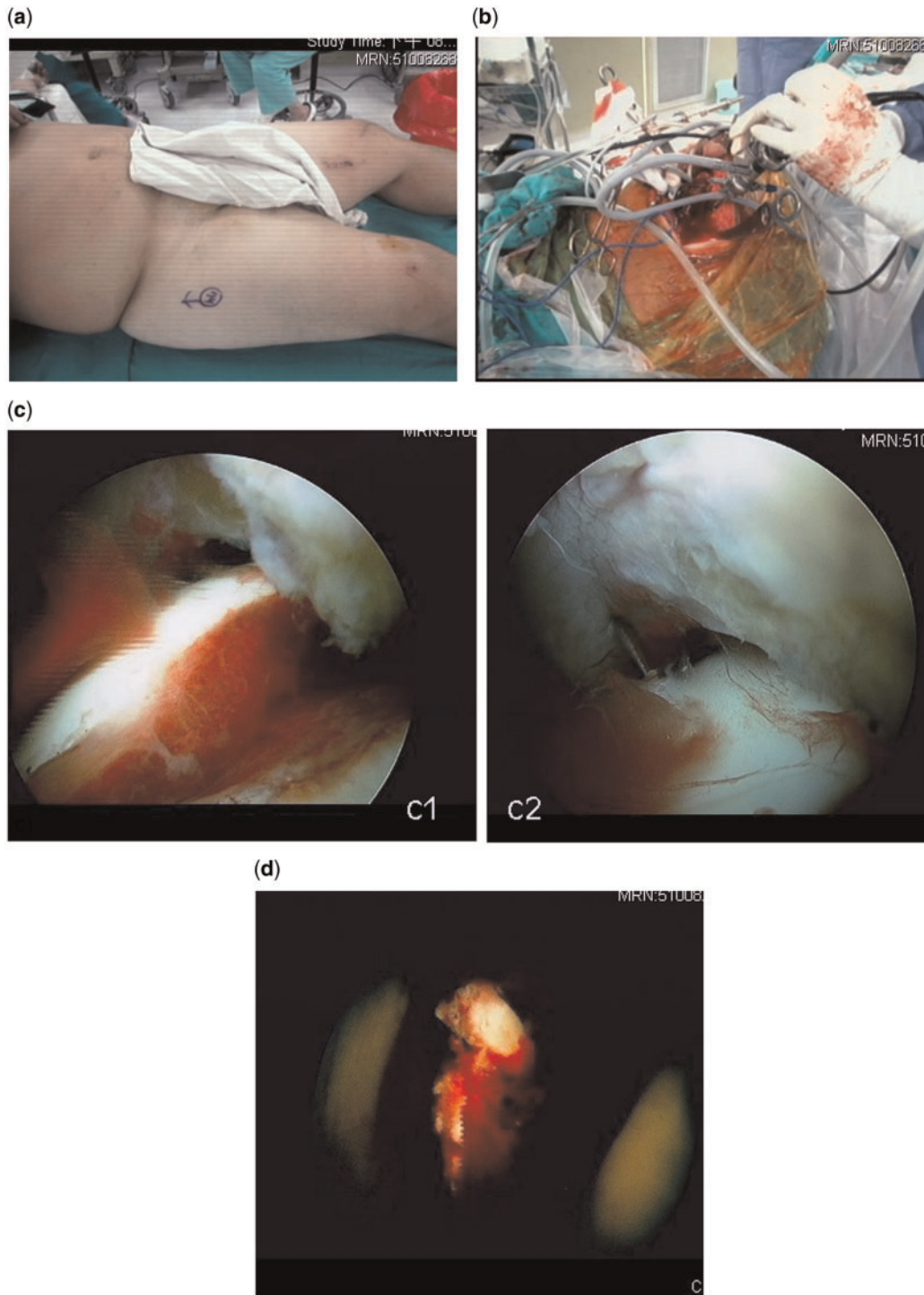


Fig 3. (a) A 36-year-old man (BMI: 44, body weight: 135 kg, body length: 175 cm) with high BMI (>40) sustained right hip femoral head fracture–dislocation, Pipkin type IV. (b) The patient was placed in lateral decubitus position. After ORIF of posterior acetabular fracture through posterior approach, we used two standard portals to visualize the hip joint with a 70° arthroscope via the same incision wound, which allowed for visualization of the infrafoveal femoral head fracture site after application of the monolateral external distractor with Schanz screws to distract and maintain the distention of the hip joint with lower leg in external rotation position. (c1–2) Two cannulated Herbert screws were used to fixate the ovoid portion of fracture fragments after reduction under arthroscopy. Two guide pins could support anti-rotational force when inserting the screws. Each screw was engaged in the subchondral bone at least 2 mm below the articular surface. (d) Some small osteochondral fragments in the hip joint were excised during the surgery simultaneously.

First-generation cephalosporin was administered as antibiotic prophylaxis prior to anesthesia and for 24 h after surgery. The patient was able to walk under non-weight-bearing conditions using crutches and was discharged when the wound condition was stable on post-operative day 6.

DISCUSSION

There are many surgical interventions for the treatment of FH fracture–dislocations. For Pipkin type IV fractures that involve the infrafoveal part of the FH with a non-congruent hip jointor displaced large posterior wall fragment, surgery is needed to manage both fractures [4, 12, 24]. Because the fractured part of the FH is always located anteromedially that in contrast to Brumbeck 4b femoral head fractures associated with anterior dislocations that involve the critical antero-lateral weight-bearing region, there is more controversy as whether to retain and fixate the non-weight-bearing fragment seen in Pipkin type IV fractures. It is difficult to fix the FH using the posterior approach and posterior dislocation of the hip. Therefore, reduction and fixation of the FH must be performed through the anterior approach. If a single-incision or the transtrochanteric approach with trochanteric osteotomy were employed, the capsule would still need to be incised and the FH dislocated [10, 11, 25, 26]. All these procedures may potentially further disrupt the vascular arcade comorbidity due to extensive soft-tissue damage, which will lead to the occurrence of the osteonecrosis of femoral head (ONFH) or heterotopic ossification (HO) [12, 27, 28].

In this case, we adopted the single-incision technique via the posterior approach to perform open reduction of the acetabular fracture and hip arthroscopy-assisted internal fixation of the FH fracture. There are some advantages of this procedure, such as no requirement for an anterior approach or posterior dislocation of the hip joint, which can further avoid disrupting the posterior capsule, acetabulum and surrounding soft tissue. This technique prevents further destruction violation of the soft tissue of the anterior hip, preserving the blood supply of the anterior capsule, which is beneficial for preservation of the blood supply to the femoral head. This approach enabled good exposure of the posterior wall fracture during reduction and fixation under direct visualization.

The open surgical management of Pipkin type IV FH fractures in patients of a high BMI is technically demanding. Surgical incisions must typically be extended to improve visualization. In addition, most instruments for hip arthroscopy are poorly adapted for large soft-tissue envelopes. In this case, we successfully used hip arthroscopy-

assisted internal fixation of the femoral head through a posterior approach. In addition, concomitant intra-articular hip lesions, such as ruptured labrum, ligament teres and small osteochondral fragments secondary to traumatic hip dislocation can be treated simultaneously. Hip arthroscopy-assisted internal fixation may allow for promising short-term outcomes and a good range of motion of the hip joint. Appropriate use of hip arthroscopy can reduce the rate of morbidity by avoiding soft-tissue dissection and preserving the blood supply to the femoral head.

There are many advantages to the use of hip arthroscopy for the treatment of hip trauma. However, there are still some concerns in relation to inadequate reduction or fixation by hip arthroscopy and the requirement for a further open procedure, especially in high-BMI patients. The potential difficulty of visualizing the fracture fragment given the location of the fracture was possible. Screw fixation of the femoral head is not at the central site of the fragment due to a limited field of arthroscopy. In addition, it is difficult to reduce the fragment and insert the guide-wires via two portals, particularly in the setting of obesity. So it may need further arthroscopic portals. The appropriate irrigation pressure is difficult to maintain in the setting of recent hip distraction. It has the potential risk of iatrogenic fluid extravasation and abdominal compartment syndrome and need to minimize pressures. The last, there are no large series or long-term results with respect to applying this technique for the treatment of Pipkin type IV FH fractures. This was the first reported case of Pipkin type IV femoral head fracture with a high BMI treated with hip arthroscopy-assisted surgery. However, we believe that hip arthroscopy-assisted surgery will become a viable treatment method in cases of FH fracture–dislocation in the future owing to limiting arthrotomy to decrease the risk of further damage to the already-compromised blood supply of the dislocated femoral head in the future.

CONFLICT OF INTEREST STATEMENT

The authors declared that they did not receive any honoraria or consultancy fees in writing this manuscript. No benefits in any form have been received or will be received from a commercial party related directly or indirectly to the subject of this article.

AUTHOR CONTRIBUTION

All authors made substantive intellectual contributions to this study to qualify as authors. One surgeon, S-L H performed the hip scope surgery and design and study. S-L H collected data of patients. C-Y C performed the analysis of radiography and clinical data. An initial draft of the manuscript was written by S-L H and C-H H redrafted the

manuscript parts of the manuscript and provided helpful advice on the final revision. All authors were involved writing the manuscript. All authors read and approved the final manuscript.

REFERENCES

- Asghar FA, Karunakar MA. Femoral head fractures: diagnosis, management, and complications. *Orthop Clin North Am* 2004; **35**: 463–72.
- Mostafa MM. Femoral head fractures. *Int Orthop* 2001; **25**: 51–4.
- Stannard JP, Harris HW, Volgas DA *et al*. Functional outcome of patients with femoral head fractures associated with hip dislocations. *Clin Orthop Relat Res* 2000; **377**: 44–56.
- Swionkowski MF, Thorpe M, Seiler JG *et al*. Operative management of displaced femoral head fractures: case-matched comparison of anterior versus posterior approaches for Pipkin I and Pipkin II fractures. *J Orthop Trauma* 1992; **6**: 437–42.
- Gaudiani MA, Samuel LT, Mahmood B *et al*. Subchondral insufficiency fractures of the femoral head: systematic review of diagnosis, treatment and outcomes. *J Hip Preserv Surg* 2020; **7**: 85–94.
- Matsuda DK. Arthroscopic osteosynthesis of femoral head malunion. *Arthrosc Tech* 2014; **3**: e31–4.
- Matsuda DK. The clamshell fracture and adjunctive acetabuloplasty in the arthroscopic osteosynthesis of femoral head fractures with femoroacetabular impingement. *Arthrosc Tech* 2012; **1**: e5–10.
- Matsuda DK. A rare fracture, an even rarer treatment: the arthroscopic reduction and internal fixation of an isolated femoral head fracture. *Arthroscopy* 2009; **25**: 408–12.
- Marchetti ME, Steinberg GG, Coumas JM. Intermediate-term experience of Pipkin fracture-dislocations of the hip. *J Orthop Trauma* 1996; **10**: 455–61.
- Ganz R, Gill TJ, Gautier E *et al*. Surgical dislocation of the adult hip a technique with full access to the femoral head and acetabulum without the risk of avascular necrosis. *J Bone Joint Surg Br* 2001; **83-B**: 1119–24.
- Gardner MJ, Suk M, Pearle A *et al*. Surgical dislocation of the hip for fractures of the femoral head. *J Orthop Trauma* 2005; **19**: 334–42.
- Yu YH, Hsu YH, Chou YC *et al*. Surgical treatment for Pipkin type IV femoral head fracture. *J Orthop Surg (Hong Kong)* 2017; **25**: 230949901668497.
- Gupta A, Redmond JM, Hammarstedt JE *et al*. Does obesity affect outcomes after hip arthroscopy? A cohort analysis. *J Bone Joint Surg Am* 2015; **97**: 16–23.
- Morris BJ, Richards JE, Guillaumondegui OD *et al*. Obesity increases early complications after high-energy pelvic and acetabular fractures. *Orthopedics* 2015; **38**: e881–7.
- Porter SE, Graves ML, Maples RA *et al*. Acetabular fracture reductions in the obese patient. *J Orthop Trauma* 2011; **25**: 371–7.
- Porter SE, Russell GV, Dews RC *et al*. Complications of acetabular fracture surgery in morbidly obese patients. *J Orthop Trauma* 2008; **22**: 589–94.
- Hsu SL, Chen CY, Ko JY *et al*. Hip arthroscopy-assisted reduction and fixation for femoral head fracture dislocations: clinical and radiographic short-term results of seven cases. *J Orthop Surg (Hong Kong)* 2019; **27**: 230949901988186.
- Ilizaliturri VM Jr., Gonzalez-Gutierrez B, Gonzalez-Ugalde H *et al*. Hip arthroscopy after traumatic hip dislocation. *Am J Sports Med* 2011; **39**: 50–7S.
- Lansford T, Munns SW. Arthroscopic treatment of Pipkin type I femoral head fractures: a report of 2 cases. *J Orthop Trauma* 2012; **26**: e94–6.
- Philippon MJ, Kuppersmith DA, Wolff AB *et al*. Arthroscopic findings following traumatic hip dislocation in 14 professional athletes. *Arthroscopy* 2009; **25**: 169–74.
- Collins JA, Beutel BG, Garofolo G *et al*. Correlation of obesity with patient-reported outcomes and complications after hip arthroscopy. *Arthroscopy* 2015; **31**: 57–62.
- Gupta A, Redmond JM, Hammarstedt JE *et al*. Does obesity affect outcomes in hip arthroscopy? A matched-pair controlled study with minimum 2-year follow-up. *Am J Sports Med* 2015; **43**: 965–71.
- Salas AP. Radiographic and anatomic landmarks to approach the anterior capsule in hip arthroscopy. *J Hip Preserv Surg* 2015; **2**: 431–7.
- Xiao B, Cao Z, He A. [Clinical efficacy of surgical treatment for Pipkin fracture in 17 cases. *Zhong Nan Da Xue Xue Bao Yi Xue Ban* 2019; **44**: 1391–6.].
- Henriques R, Ramalho D, Soares do Brito J *et al*. Management of Pipkin fractures using a safe surgical hip dislocation. *Case Rep Orthop* 2019; **2019**: 1–6.
- Aprato A, Bonani A, Giachino M *et al*. Can we predict femoral head vitality during surgical hip dislocation? *J Hip Preserv Surg* 2014; **1**: 77–81.
- Glassman AH. Complications of trochanteric osteotomy. *Orthop Clin North Am* 1992; **23**: 321–33.
- Wang SX, Li BH, Li J *et al*. Middle-term follow-up results of Pipkin type IV femoral head fracture patients treated by reconstruction plate and bioabsorbable screws. *Chin J Traumatol* 2018; **21**: 170–5.