

A rare occurrence of supplementary maxillary lateral incisors and a detailed review on supernumerary teeth

Paul Chalakkal, Ramesh Krishnan¹, Neil De Souza, Godwin Clovis Da Costa²

Departments of Pedodontics and Preventive Dentistry and ²Prosthodontics, Goa Dental College and Hospital, Bambolim, Goa,
¹Department of Pedodontics and Preventive Dentistry, Vinayaka Missions Sankarachariyar Dental College, Salem, Tamil Nadu, India

Abstract

This article highlights a rare occurrence of nonsyndromic supplemental maxillary lateral incisors in a 11-year-old boy. It also includes a detailed literature review of supernumerary teeth.

Keywords: Lateral incisors, nonsyndromic, supernumerary teeth, supplemental teeth

Address for correspondence: Dr. Paul Chalakkal, Department of Pedodontics and Preventive Dentistry, Goa Dental College and Hospital, Bambolim - 403 202, Goa, India.
 E-mail: atomheartpaul@yahoo.com
Received: 29.08.2017, **Accepted:** 31.08.2017

INTRODUCTION

Supernumerary teeth/tooth (ST) which are well aligned in the arch and resemble the normal anatomy of adjacent teeth are called supplementary teeth.^[1] They have also been defined as ST that bear resemblance with the teeth they are associated with.^[2] According to the Darwin's theory of evolution, as human evolved, organs that were minimally used became vestigial, such as the appendix, tail bone and fourth molar. However, in rare cases, there are still occurrences of supplementary molars and premolars.^[1,3] Only six cases of supplemental central incisors have been reported in literature till date.^[4-9] Supplemental lateral incisors are rare, and bilateral cases are even rarer. To the best of our knowledge, only three cases have been reported in literature till date.^[10-12]

CASE REPORT

A 11-year-old boy visited the Department of Pedodontics and Preventive Dentistry with the complaint of anterior

crowding [Figure 1]. On intraoral examination, the teeth present in the upper arch were: 16, 15, 14, 53, 12, 11, 21, 22, 63, 24, 65, 26 and two supplemental incisors, bilaterally. Anterior crowding was evident and amalgam restorations were present on the first permanent molars [Figure 2]. The following teeth were unerupted: 17, 27, 13, 23 and 25 [Figure 3]. The lower arch contained the following teeth: 36, 35, 34, 33, 32, 31, 41, 42, 43, 44, 85 and 46. Dental caries (distoproximal) was present on 85; however, no treatment was carried out since it was nearing exfoliation (root resorption was completed). The 37, 47 and 45 were unerupted [Figure 4]. The OPG confirmed the absence of any congenitally missing teeth, additional ST or malformations [Figure 3]. There were no orofacial deformities, mental retardation or any other medical conditions.

DISCUSSION

Unerupted supplemental teeth have been associated with several pathological conditions such as widened follicular

This is an open access journal, and articles are distributed under the terms of the Creative Commons Attribution-NonCommercial-ShareAlike 4.0 License, which allows others to remix, tweak, and build upon the work non-commercially, as long as appropriate credit is given and the new creations are licensed under the identical terms.

For reprints contact: reprints@medknow.com

How to cite this article: Chalakkal P, Krishnan R, De Souza N, Da Costa GC. A rare occurrence of supplementary maxillary lateral incisors and a detailed review on supernumerary teeth. *J Oral Maxillofac Pathol* 2018;22:149.

Access this article online

Quick Response Code:



Website:

www.jomfp.in

DOI:

10.4103/jomfp.JOMFP_213_15

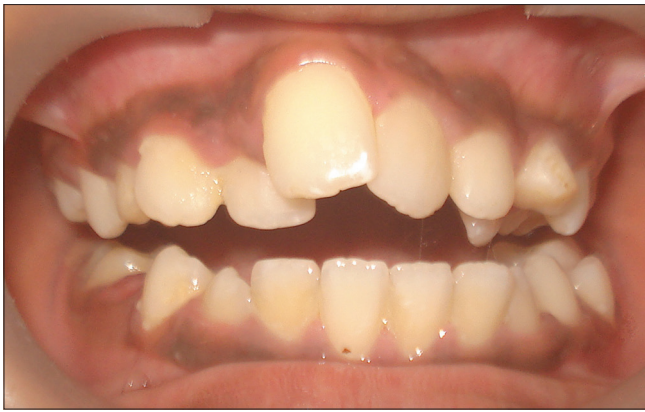

Figure 1: Anterior view of both arches

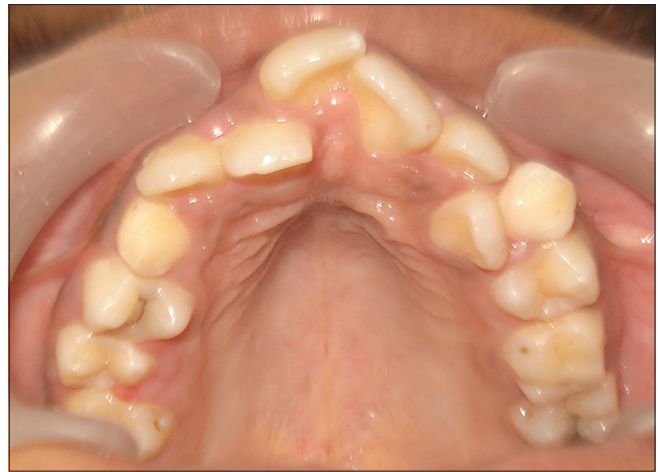

Figure 2: Maxillary arch

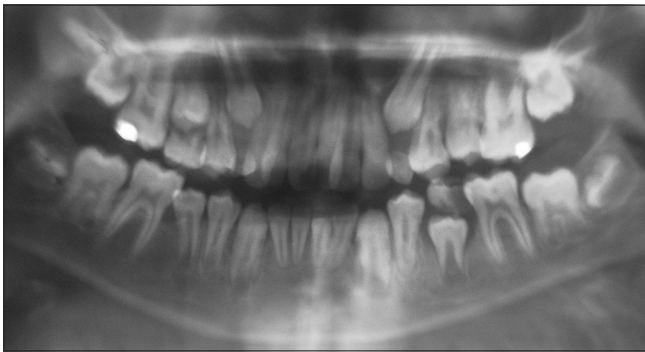


Figure 3: Orthopantomograph

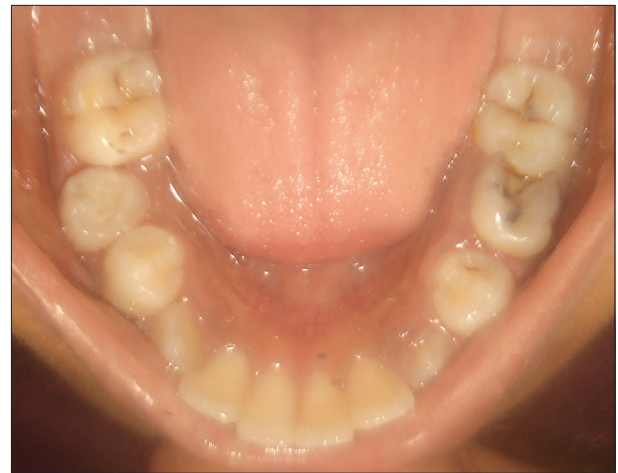

Figure 4: Mandibular arch

space, dentigerous cyst formation, and disturbances in adjacent permanent teeth such as ectopic eruption, diastema formation, pulp necrosis, pulp canal obliteration, root resorption, ankylosis and rotations.^[4,6] Most supplemental teeth remain unerupted.^[6] However, in the present case, the supplemental lateral incisors were erupted and had only resulted in ectopic eruption and rotations among the adjacent incisors. They did not cause any symptoms in the individual, which supports the fact that 75% of supernumerary lateral incisors located on both maxillary bones in the same position do not cause any symptoms.^[13,14] If a supplemental tooth is present and erupted, it may be difficult to determine which tooth is supplemental and which are constituents of the normal dentition.^[9] However, in the present case, they were categorized as supplemental lateral incisors, since their coronal dimensions closely matched with those of the lateral incisors. Supernumerary canines and lateral incisors are rare with low frequency of occurrence (2.8%) in comparison with other ST.^[15] Multiple ST not associated with syndromes are found in rare conditions.^[3,16-19] The patient in the present case did not have any mental retardation, abnormal facial appearance or any skeletal abnormalities suggestive of any syndrome, suggesting an autosomal dominant pattern of inheritance. Similar cases have been documented by many authors.^[16,19-23] Nonsyndromic ST in the permanent dentition,

as in the present case, are mostly found in the maxilla^[16,24-28] in the anterior region.^[25] However, there have been reports of cases involving all maxillary dental series.^[13,17,27,29,30] A predilection for such ST in the mandibular premolar series had also been reported.^[18,19,31-33] The patient had reported with the chief complaint of anterior crowding and was unaware of the extra teeth he had. The supplemental maxillary lateral incisors were discovered on intraoral examination and were confirmed on the orthopantomograph. However, fixed orthodontic treatment has been planned to be undertaken after the eruption of all premolars and permanent canines. Selective removal of lateral incisors (normal or supplementary) may be required. In such circumstances, when both teeth are healthy, it has been suggested to extract the tooth/teeth that is most displaced from the line of the arch, so as to relieve crowding.^[9]

Definitions

ST have been defined in various ways by authors:

- Definition 1: ST (or hyperdontia) are teeth that exceed

the normal dental formula (or complement), regardless of their location and form (or morphology)^[11,13,16,20,27,34-44]

- Definition 2: Hyperdontia or ST are terms referred to any excess number of teeth or odontogenic structures^[14,45]
- Definition 3: ST may be defined as any teeth or tooth substance in excess of the usual configuration of 20 deciduous and 32 permanent teeth.^[46]
- Definition 4: ST (or hyperdontia) are defined as the existence of an excessive number of teeth in relation to the normal dental formula^[47]
- Definition 5: ST are defined as those that appear in addition to the normal series^[9]
- Definition 6: ST are defined as “supplementary,” if they present a normal morphology, and as “supernumerary,” if they present morphologic and volumetric anomalies.^[43]

Classifications

Based on position

The classification of ST may be done on the basis of their position.^[2,48] ST with positional variations include mesiodens, paramolars, distomolars and parapremolars.^[2,17,41,48,49] There are variations in the frequency of occurrence of various ST based on the studies conducted. However, mesiodens has been found to be the most common ST with a prevalence between 0.15% and 1.9%.^[13,36,37,50] According to Türkkahraman *et al.*, the frequency of ST in the descending order of occurrence had been suggested as maxillary midline supernumeraries (mesiodens), maxillary fourth molars, maxillary paramolars, mandibular premolars, maxillary lateral incisors, mandibular fourth molars and maxillary premolars.^[51] Many authors have reported the mesiodens as being the most common ST, followed by supernumerary premolars and supernumerary fourth molars.^[14,15,31,52,53] However, Yagüe-García *et al.* found paramolars to be more frequently occurring than parapremolars.^[16] According to a few authors, the order was mesiodens, distomolars or fourth supernumerary molars, paramolars and supernumerary premolars.^[13,36,37,50] According to Fernández-Montenegro *et al.*, the frequency of occurrence of ST were mesiodens (46.9%), supernumerary premolars (24.1%) and distomolars (18%).^[15] Many authors have reported an increased presence of supernumerary premolars.^[18,19,25,26,32,33,54] Parapremolars, that are known to constitute about 8%–9% of all ST,^[55,56] may occur as single (76%–86%), double (12%–23%) or multiple (<1%) teeth.^[34] However, a paramolar is a supernumerary molar, usually rudimentary, situated buccally or lingually/palatally to a molar, or may occur in the interproximal space buccal to the second and third molar.^[57] Some authors had found supernumerary molars to be the most prevalent ST.^[13,58,59]

Supernumerary canines and supernumerary lateral incisors are rare with low frequency of occurrence (2.8%) among ST.^[15]

Based on morphology

ST have been classified on the basis of morphology.^[2,48] Primosch classified ST into two types: ST with normal shapes and sizes (eumorphic) were termed as “supplemental” or “incisiform,” whereas ST with abnormal shapes and smaller sizes (dysmorphic) were termed as “rudimentary.”^[60] Dysmorphic/heteromorphic/rudimentary ST show distinct forms such as conical or pin, tuberculate, infundibular and molariform.^[2,13,14,17,41,48,49,60,61] Fernández-Montenegro *et al.* found most supernumerary premolars to be eumorphic (81.8%).^[15]

Etiology

ST result from any disturbance in the initiation and proliferation stages of odontogenesis.^[62,63] There are several theories regarding the development of a ST – trauma, environmental factors, phylogenetic theory (regression to the anthropoids whose dental formula had more teeth), atavism (reversion to a more primitive type of dentition), dichotomy of the tooth germ, hyperactivity of the dental lamina and autonomic recessive inheritance linked to the X chromosome have been suggested.^[13,14,16,18,19,27,64-66]

Dichotomy

Dichotomy of the dental lamina (primary or successional) or tooth buds at the stage of histodifferentiation may occur during the 6th week of fetal life.^[67,68] The tooth bud splits into two parts of equal or unequal sizes, resulting in ST.^[11,13,14,18,30,69] This hypothesis is supported by animal experiments in which the split germs have been cultivated *in vitro*.^[70,71] Gemination, which is assumed to be a similar incomplete process, also supports this theory.^[69]

Hyperactive dental lamina

Hyperactive dental lamina continues to proliferate because of failure in programmed cell death, due to defects in signaling between epithelium and mesenchyme. The excessive proliferation of cells results in the formation of extra tooth buds.^[13,14,18,19,60,72]

Genetics

The role of genetics has been considered in the formation of ST, since they have been found in twins, siblings and sequential generations of a family.^[16,19,28,73,74] Several families have been documented in which at least two individuals presented with multiple ST, not associated with any syndrome.^[19,26,54,75-78] However, the pattern of inheritance does not follow Mendelian principles.^[17,19] A dominant autosomal trait characterized by low penetrance has also been suggested.^[11,16,27,66]

Syndromes and anomalies

The involvement of any syndrome must be carefully examined in any case exhibiting multiple ST.^[79] The various syndromes or anomalies associated with ST are cleft lip and palate, cleidocranial dysostosis, Gardner's syndrome, Fabry–Anderson's syndrome, chondroectodermal dysplasia (Ellis–Van Creveld syndrome), Ehlers–Danlos syndrome, incontinentia pigmenti and trichorhinophalangeal syndrome.^[3,13,14,16,18,20,23,24,27,34,35,37,38,40,42,60,61,66,69,80-83] Dental anomalies such as hypodontia, taurodontism, gemination or macrodontia have also been associated with ST.^[84,85]

Prevalence

Permanent dentition

ST had been first reported between 23 AD and 79 AD^[29] The prevalence of ST in the general population had been reported by various authors to be between 0.09 and 0.29%,^[13,36-40,83,86] 0.5%–5.3%,^[16] 0.5%–3.8%,^[20,41,13,34,36,37,39,86,87] 1%–4%,^[60] 0.5%–5.3%,^[88] 0.3%–1.7%,^[71] 0.1%–3.9%^[9,14,45,89-91] and 0.15%–3.800%.^[31,53] Their prevalence had been reported to be higher in Mongoloids and African-Americans.^[14,45,89-91] A similar observation had been made in the Asian and Native American populations.^[71] Their prevalence in the Caucasian population had been found to be between 0.1% and 3.9%.^[14,45,89,92-94] Their prevalence in countries between the Caspian sea, and the Black sea were found to be between 0.1% and 3.8%.^[14,89,92,93] Their prevalence was found to be between 0.4% and 3.4% in Arabs and Asians,^[14,89,92,93] and 1.24% in South Indians.^[95] ST were also found to have a prevalence between 2.7% and 3.4% in Sub-Saharan and Asian populations.^[37,96] These variations in global prevalence, especially for the Asian population, might stem from diversities in ethnicity, methodological differences, age groups examined and sample size.^[37,63,97]

Primary dentition

The prevalence of ST in the primary dentition had been found to vary according to authors. It had been found to be between 0.3%–1.7%,^[71] 0.2%–0.8%,^[16,88] 0.2%–1.9%,^[60] 0.3%–0.8%^[9] and 0.3%–0.6%.^[13,20,34,36,37,39,86,87]

Gender variation

ST had been found to occur more in males.^[14,50,89,93,95,97] However, male-to-female ratios of 2:1,^[13-15,18,26,34-36,40,44,61,82,83] 9:2^[13,18] and 1.4:1^[15] had been reported.

Site of occurrence

ST had been found to occur more, unilaterally than bilaterally.^[98] They had been found to occur in the maxilla 8.2–10 times more frequently than in the mandible, commonly affecting the premaxillary region,^[11,14,16,27,30,57] in a palatine position.^[15,50,99-102] About 90%–98% of ST

are found in the premaxillary region,^[35,37,60] followed by the mandibular premolar region (supernumerary premolars).^[15,18,20,89,103,104] Supernumerary premolars are mostly located in the mandible, in a lingual position,^[15] while paramolars and distomolars are mostly found in the maxilla.^[105-107]

Multiple supernumerary teeth

The prevalence of multiple ST had been found to be 0.06%.^[31] Multiple ST had been reported in 8%–27%^[60,101] or 1.5%^[14] of the individuals with at least one ST. The presence of one, two and three or more ST occur in 76%–86%, 12%–23% and 1% of the individuals with ST, respectively.^[14,15,108] Three or more ST in the same individual were found in 2%–8% of cases with ST.^[14,15] However, five or more ST in the same individual were found in <1% of individuals with ST.^[14,18]

Complications

ST teeth can erupt normally, remain impacted, invert, reach heterotopic positions or show abnormal eruptive patterns.^[18,49,59] There are various complications related to ST according to authors:^[13,14,26,31,42-45,48,52,56,60,74,77,97,109-127]

- Eruption disturbances: Delayed eruption or noneruption of permanent teeth (30%–60% of cases)
- Malpositions: Discrepancy in the Bolton's arch perimeter resulting in severe crowding and malpositioning; displacement or rotation of adjacent teeth
- Root related: Absorption of roots and root malformations (dilacerations) secondary to the pressure exerted by ST
- Pathologic: Development of follicular cysts
- Endodontic: Caries and loss of vitality of adjacent teeth
- Periodontal: Gingivitis, periodontitis and abscess formation
- Functional: Occlusal interferences and masticatory difficulties
- Others: Neuralgic manifestations and dysodontiasis of permanent teeth.

Treatment options

Since the majority of ST (80%–93%) cause clinical complications, early diagnosis and treatment planning are important in preventing complications related to ST and adjacent teeth.^[89,118] Orthodontists, pediatric dentists, and general practitioners who usually visit children at lower ages can contribute to early diagnosis and planning more effective long-term interdisciplinary therapies.^[128] There are two treatment options for delayed eruption of adjacent teeth due to the presence of ST. The first option being, removal of the ST if adequate space is available for the

adjacent tooth to erupt or removal of the ST followed by a surgical-orthodontic treatment to re-establish space for the unerupted tooth.^[17] The timing of surgical removal of ST is contentious and two alternatives exist. First, to remove the ST as soon as it has been diagnosed and second, to leave the ST as such till the root development of adjacent teeth is complete, to prevent damage to their root apices. However, no evidence of root resorption, loss of vitality, or any disturbance to root development in adjacent permanent teeth had been reported by Hogstrom and Andersson.^[113] The underlying permanent teeth usually erupt spontaneously following the removal of unerupted ST.^[14]

Declaration of patient consent

The authors certify that they have obtained all appropriate patient consent forms. In the form the patient(s) has/have given his/her/their consent for his/her/their images and other clinical information to be reported in the journal. The patients understand that their names and initials will not be published and due efforts will be made to conceal their identity, but anonymity cannot be guaranteed.

Financial support and sponsorship

Nil.

Conflicts of interest

There are no conflicts of interest.

REFERENCES

- Tommasi AF. Diagnostico em Patologia Bucal. Sao Paulo: Artes Medicas; 1988. p. 85-97.
- Yassin OM, Hamori E. Characteristics, clinical features and treatment of supernumerary teeth. *J Clin Pediatr Dent* 2009;33:247-50.
- Mali S, Karjodkar FR, Sontakke S, Sansare K. Supernumerary teeth in non-syndromic patients. *Imaging Sci Dent* 2012;42:41-5.
- Rock WP. A case of bilateral supplemental maxillary central incisors. *Int J Paediatr Dent* 1991;1:155-8.
- Camilleri S. A case of bilateral supplemental maxillary central incisors. *Int J Paediatr Dent* 2003;13:57-61.
- Stafne EC. Supernumerary upper central incisors. *Dent Cosmos* 1931;73:976-98.
- Trotman CA, McNamara T. Four maxillary incisors: A case report. *Spec Care Dentist* 1994;14:112-5.
- Steelman R, Wilson C, Nelson S. Maxillary incisor duplication. *Oral Surg Oral Med Oral Pathol* 1991;71:523.
- Hans MK, Shetty S, Shekhar R, Sirohi S. Bilateral supplemental maxillary central incisors: A case report. *J Oral Sci* 2011;53:403-5.
- Townsend BR. Two cases of duplication of deciduous lateral incisors followed by permanent lateral incisors. *Br Dent J* 1953;95:47-8.
- Nagpal A, Hans MK, Shetty S, Kaur N, Kumar S. Non-syndromic bilateral supplemental maxillary lateral incisors: A rare case. *J Clin Diagn Res* 2013;7:1812-3.
- Yildirim G, Bayrak S. Early diagnosis of bilateral supplemental primary and permanent maxillary lateral incisors: A case report. *Eur J Dent* 2011;5:215-9.
- Gay Escoda C, Mateos Micas M, España Tost A, Gargallo Albiol J. Otras inclusiones dentarias. Mesiodens y otros dientes supernumerarios. Dientes temporales supernumerarios. Dientes temporales incluidos. In: Gay Escoda C, Aytés Berini L, editors. *Tratado de Cirugía Bucal*. 1ª ed., Tomo I. Madrid: Ergon; 2004. p. 497-534.
- Rajab LD, Hamdan MA. Supernumerary teeth: Review of the literature and a survey of 152 cases. *Int J Paediatr Dent* 2002;12:244-54.
- Fernández Montenegro P, Valmaseda Castellón E, Berini Aytés L, Gay Escoda C. Retrospective study of 145 supernumerary teeth. *Med Oral Patol Oral Cir Bucal* 2006;11:E339-44.
- Yagüe-García J, Berini-Aytés L, Gay-Escoda C. Multiple supernumerary teeth not associated with complex syndromes: A retrospective study. *Med Oral Patol Oral Cir Bucal* 2009;14:E331-6.
- Scheiner MA, Sampson WJ. Supernumerary teeth: A review of the literature and four case reports. *Aust Dent J* 1997;42:160-5.
- Yusuf WZ. Non-syndrome multiple supernumerary teeth: Literature review. *J Can Dent Assoc* 1990;56:147-9.
- Batra P, Duggal R, Parkash H. Non-syndromic multiple supernumerary teeth transmitted as an autosomal dominant trait. *J Oral Pathol Med* 2005;34:621-5.
- Indira M, Dhull KS, RS, Kumar Ps P, Devi Bm G. Molariform mesiodens in primary dentition: A case report. *J Clin Diagn Res* 2014;8:ZD33-5.
- Yadav RK, Rao J, Yadav L, Hasija M. Non-syndromic multiple supernumerary teeth in permanent dentition: A rare phenomenon. *BMJ Case Rep* 2013. doi: 10.1136/bcr-2013-009026.
- Baccetti T. A controlled study of associated dental anomalies. *Angle Orthod* 1998;68:267-74.
- Inchingolo F, Tatullo M, Abenavoli FM, Marrelli M, Inchingolo AD, Gentile M, et al. Non-syndromic multiple supernumerary teeth in a family unit with a normal karyotype: Case report. *Int J Med Sci* 2010;7:378-84.
- Garvey MT, Barry HJ, Blake M. Supernumerary teeth – An overview of classification, diagnosis and management. *J Can Dent Assoc* 1999;65:612-6.
- Gündüz K, Muğlali M. Non-syndrome multiple supernumerary teeth: A case report. *J Contemp Dent Pract* 2007;8:81-7.
- Desai RS, Shah NP. Multiple supernumerary teeth in two brothers: A case report. *J Oral Pathol Med* 1998;27:411-3.
- Trull Gimbernat JM, Banchilleria Balaguer E, Vall-Llosera Riera J, Gay Escoda C. Supernumerarios múltiples no síndrómicos: Descripción de un caso. *Av Odontostomatol* 1994;10:89-93.
- Nayak UA, Mathian VM, Veerakumar. Non-syndrome associated multiple supernumerary teeth: A report of two cases. *J Indian Soc Pedod Prev Dent* 2006;24 Suppl 1:S11-4.
- Saraswathi FK, Toran SS, Kuma P. Supplemental rudimentary tuberculates with unusual morphology: A case report. *Int J Dent Clin* 2010;2:47-52.
- Sasaki H, Funao J, Morinaga H, Nakano K, Ooshima T. Multiple supernumerary teeth in the maxillary canine and mandibular premolar regions: A case in the postpermanent dentition. *Int J Paediatr Dent* 2007;17:304-8.
- Açikgöz A, Açikgöz G, Tunga U, Otan F. Characteristics and prevalence of non-syndrome multiple supernumerary teeth: A retrospective study. *Dentomaxillofac Radiol* 2006;35:185-90.
- Orhan AI, Ozer L, Orhan K. Familial occurrence of nonsyndromal multiple supernumerary teeth. A rare condition. *Angle Orthod* 2006;76:891-7.
- Kalra N, Chaudhary S, Sanghi S. Non-syndrome multiple supplemental supernumerary teeth. *J Indian Soc Pedod Prev Dent* 2005;23:46-8.
- So LL. Unusual supernumerary teeth. *Angle Orthod* 1990;60:289-92.
- Hattab FN, Yassin OM, Rawashdeh MA. Supernumerary teeth: Report of three cases and review of the literature. *ASDC J Dent Child* 1994;61:382-93.
- Valmaseda-Castellón E, Berini-Aytés L, Gay-Escoda C. Supernumerary premolars. Report of 10 cases. *Bull Group Int Rech Sci Stomatol Odontol* 2001;43:19-25.
- Zhu JF, Marcushamer M, King DL, Henry RJ. Supernumerary and congenitally absent teeth: A literature review. *J Clin Pediatr Dent* 1996;20:87-95.
- Rodríguez-Armijo Sánchez A, Romero Álvarez M, Infante Cossío P,

- Rodríguez-Armijo Sánchez L, Gallardo García P. Premolares múltiples supernumerarios no sindrómicos: Revisión de la literatura y presentación de un caso. *Arch Odontoestomatol* 1996;12:266-70.
39. Gibson N. A late developing mandibular premolar supernumerary tooth. *Aust Dent J* 2001;46:51-2.
 40. McNamara CM, Foley TF, Wright GZ, Sandy JR. The management of premolar supernumeraries in three orthodontic cases. *J Clin Pediatr Dent* 1997;22:15-8.
 41. Dhull KS, Dhull RS, Panda S, Acharya S, Yadav S, Mohanty G, et al. Bilateral mandibular paramolars. *Int J Clin Pediatr Dent* 2014;7:40-2.
 42. Capozzi L, Gombos F, Masi P, Modica R, Valletta G. *Patologia speciale odontostomatologica*. Firenze, Italy: USES Publisher; 1987.
 43. Orlando S, Bernardini UD. Sulle anomalie dentali numeriche per eccesso. *Riv Ital Stomatol* 1966;21:1267-322.
 44. Cassetta M, Russomanno MR. L'iperdontia nei settori latero-posteriori; indagine epidemiologica su 20398 pazienti. *Riv Ital Stomatol* 1994;63:565-73.
 45. Meighani G, Pakdaman A. Diagnosis and management of supernumerary (mesiodens): A review of the literature. *J Dent (Tehran)* 2010;7:41-9.
 46. Schulze C. Developmental abnormalities of teeth and jaws. In: Gorlin RJ, Goldman HM, editors. *Thoma's Oral Pathology*. St. Louis: CV Mosby; 1970. p. 112-22.
 47. Shafer WG, Hine MK, Levy BM. *Textbook of Oral Pathology*. 6th ed. London, UK: Elsevier Publication; 2009. p. 46.
 48. Mitchell L. Supernumerary teeth. *Dent Update* 1989;16:65-6, 68-9.
 49. Ramsaran AS, Barclay S, Scipio E, Ogunsalu C. Non-syndromal multiple buried supernumerary teeth: Report of two cases from the english-speaking caribbean and a review of the literature. *West Indian Med J* 2005;54:334-6.
 50. Giacotti A, Grazzini F, De Dominicis F, Romanini G, Arcuri C. Multidisciplinary evaluation and clinical management of mesiodens. *J Clin Pediatr Dent* 2002;26:233-7.
 51. Türkkahraman H, Yilmaz HH, Cetin E. A non-syndrome case with bilateral supernumerary canines: Report of a rare case. *Dentomaxillofac Radiol* 2005;34:319-21.
 52. Mason C, Rule DC, Hopper C. Multiple supernumeraries: The importance of clinical and radiographic follow-up. *Dentomaxillofac Radiol* 1996;25:109-13.
 53. Salcido-García JF, Ledesma-Montes C, Hernández-Flores F, Pérez D, Garcés-Ortiz M. Frequency of supernumerary teeth in Mexican population. *Med Oral Patol Oral Cir Bucal* 2004;9:407-9.
 54. Wang XX, Zhang J, Wei FC. Autosomal dominant inheritance of multiple supernumerary teeth. *Int J Oral Maxillofac Surg* 2007;36:756-8.
 55. Hegde SV, Munshi AK. Late development of supernumerary teeth in the premolar region: A case report. *Quintessence Int* 1996;27:479-81.
 56. Rubenstein LK, Lindauer SJ, Isaacson RJ, Germane N. Development of supernumerary premolars in an orthodontic population. *Oral Surg Oral Med Oral Pathol* 1991;71:392-5.
 57. Shah A, Gill DS, Tredwin C, Naini FB. Diagnosis and management of supernumerary teeth. *Dent Update* 2008;35:510-2, 514-6, 519-20.
 58. Nazif MM, Ruffalo RC, Zullo T. Impacted supernumerary teeth: A survey of 50 cases. *J Am Dent Assoc* 1983;106:201-4.
 59. Menardía-Pejuán V, Berini-Aytés L, Gay-Escoda C. Supernumerary molars. A review of 53 cases. *Bull Group Int Rech Sci Stomatol Odontol* 2000;42:101-5.
 60. Primosch RE. Anterior supernumerary teeth – Assessment and surgical intervention in children. *Pediatr Dent* 1981;3:204-15.
 61. Alaejos Algarrá C, Contreras Martínez M, Buenechea Imaz R, Berini Aytés L, Gay Escoda C. Mesiodens: Revisión retrospectiva de una serie de 44 pacientes. *Med Oral* 2000;5:81-8.
 62. Bergström K. An orthopantomographic study of hypodontia, supernumeraries and other anomalies in school children between the ages of 8-9 years. An epidemiological study. *Swed Dent J* 1977;1:145-57.
 63. Luten JR Jr. The prevalence of supernumerary teeth in primary and mixed dentitions. *J Dent Child* 1967;34:346-53.
 64. Rao PV, Chidzonga MM. Supernumerary teeth: Literature review. *Cent Afr J Med* 2001;47:22-6.
 65. Sedano HO, Gorlin RJ. Familial occurrence of mesiodens. *Oral Surg Oral Med Oral Pathol* 1969;27:360-1.
 66. Kokten G, Balcioğlu H, Buyukertan M. Supernumerary fourth and fifth molars: A report of two cases. *J Contemp Dent Pract* 2003;4:67-76.
 67. da Silva AP, Costa B, de Carvalho Carrara CF. Dental anomalies of number in the permanent dentition of patients with bilateral cleft lip: Radiographic study. *Cleft Palate Craniofac J* 2008;45:473-6.
 68. Tereza GP, Carrara CF, Costa B. Tooth abnormalities of number and position in the permanent dentition of patients with complete bilateral cleft lip and palate. *Cleft Palate Craniofac J* 2010;47:247-52.
 69. Stellzig A, Basdra EK, Komposch G. Mesiodentes: Incidence, morphology, etiology. *J Orofac Orthop* 1997;58:144-53.
 70. Liu JF. Characteristics of premaxillary supernumerary teeth: A survey of 112 cases. *ASDC J Dent Child* 1995;62:262-5.
 71. Taylor GS. Characteristics of supernumerary teeth in the primary and permanent dentition. *Dent Pract Dent Rec* 1972;22:203-8.
 72. Levine N. The clinical management of supernumerary teeth. *J Can Dent Assoc* 1961;28:297-303.
 73. Jafri SA, Pannu PK, Galhotra V, Dogra G. Management of an inverted impacted mesiodens, associated with a partially erupted supplemental tooth-A case report. *Indian J Dent* 2011;2:40-3.
 74. Mason C, Rule DC. Midline supernumeraries: A family affair. *Dent Update* 1995;22:34-5.
 75. Mercuri LG, O'Neill R. Multiple impacted and supernumerary teeth in sisters. *Oral Surg Oral Med Oral Pathol* 1980;50:293.
 76. Umweni AA, Osunbor GE. Non-syndrome multiple supernumerary teeth in Nigerians. *Odontostomatol Trop* 2002;25:43-8.
 77. Becker A, Bimstein E, Shteyer A. Interdisciplinary treatment of multiple unerupted supernumerary teeth. Report of a case. *Am J Orthod* 1982;81:417-22.
 78. Marya CM, Kumar BR. Familial occurrence of mesiodentes with unusual findings: Case reports. *Quintessence Int* 1998;29:49-51.
 79. Acton CH. Multiple supernumerary teeth and possible implications. *Aust Dent J* 1987;32:48-9.
 80. McNamara CM, O'Riordan BC, Blake M, Sandy JR. Cleidocranial dysplasia: Radiological appearances on dental panoramic radiography. *Dentomaxillofac Radiol* 1999;28:89-97.
 81. Moore SR, Wilson DF, Kibble J. Sequential development of multiple supernumerary teeth in the mandibular premolar region-A radiographic case report. *Int J Paediatr Dent* 2002;12:143-5.
 82. Mason C, Azam N, Holt RD, Rule DC. A retrospective study of unerupted maxillary incisors associated with supernumerary teeth. *Br J Oral Maxillofac Surg* 2000;38:62-5.
 83. Breckon JJ, Jones SP. Late forming supernumeraries in the mandibular premolar region. *Br J Orthod* 1991;18:329-31.
 84. Manrique Morá MC, Bolaños Carmona MV, Briones Luján MT. Molarization and development of multiple supernumerary teeth in the premolar region. *J Dent Child (Chic)* 2004;71:171-4.
 85. Sharma A. A rare non-syndrome case of concomitant multiple supernumerary teeth and partial anodontia. *J Clin Pediatr Dent* 2001;25:167-9.
 86. Williams P. An unusual case of hyperdontia [corrected]. *Br Dent J* 1998;184:371-2.
 87. Ehsan D, Tu HK, Camarata J. Mandibular supernumerary tooth causing neurosensory changes: A case report. *J Oral Maxillofac Surg* 2000;58:1450-1.
 88. Singhvi V, Nambiar S, Shetty S. Orthodontic management of non-syndromic multiple supernumerary teeth. *Contemp Clin Dent* 2013;4:540-2.
 89. Neville B, Damm D, Allen C, Bouquot J. *Oral and Maxillofacial Pathology*. Philadelphia: Saunders; 2002. p. 69-73.
 90. Harris EF, Clark LL. An epidemiological study of hyperdontia in American blacks and whites. *Angle Orthod* 2008;78:460-5.
 91. Anthonappa RP, Omer RS, King NM. Characteristics of 283

- supernumerary teeth in Southern Chinese children. *Oral Surg Oral Med Oral Pathol Oral Radiol Endod* 2008;105:e48-54.
92. Esenlik E, Sayin MO, Atilla AO, Ozen T, Altun C, Başak F, et al. Supernumerary teeth in a Turkish population. *Am J Orthod Dentofacial Orthop* 2009;136:848-52.
 93. Ghaznawi HI, Daas H, Salako NO. A clinical and radiographic survey of selected dental anomalies and conditions in a Saudi Arabian population. *Saudi Dent J* 1999;11:8-13.
 94. Amini F, Rakhshan V, Jamalzadeh S. Prevalence and pattern of accessory teeth (Hyperdontia) in permanent dentition of Iranian orthodontic patients. *Iran J Public Health* 2013;42:1259-65.
 95. Aneundi RT, Tegginmani VS, Battepati P, Tavargeri A, Patil S, Trasad V, et al. Prevalence and characteristics of supernumerary teeth in a non-syndromic South Indian pediatric population. *J Indian Soc Pedod Prev Dent* 2014;32:9-12.
 96. Brown A. 'Supplemental and congenitally absent premolar teeth'. *Br Dent J* 1990;169:150.
 97. Leco Berrocal MI, Martín Morales JF, Martínez González JM. An observational study of the frequency of supernumerary teeth in a population of 2000 patients. *Med Oral Patol Oral Cir Bucal* 2007;12:E134-8.
 98. Mishra MB. Types of hyperodontic anomalies in permanent dentition: Report of 5 cases. *Int J Clin Dent Sci* 2011;2:15-21.
 99. Kim SG, Lee SH. Mesiodens: A clinical and radiographic study. *J Dent Child* 2003;70:58-60.
 100. Seddon RP, Johnstone SC, Smith PB. Mesiodentes in twins: A case report and a review of the literature. *Int J Paediatr Dent* 1997;7:177-84.
 101. Grimanis GA, Kyriakides AT, Spyropoulos ND. A survey on supernumerary molars. *Quintessence Int* 1991;22:989-95.
 102. Hurlen B, Humerfelt D. Characteristics of premaxillary hyperodontia. A radiographic study. *Aust Dent J* 1992;37:189-95.
 103. Fardi A, Kondylidou-Sidira A, Bachour Z, Parisi N, Tsirlis A. Incidence of impacted and supernumerary teeth-a radiographic study in a North Greek population. *Med Oral Patol Oral Cir Bucal* 2011;16:e56-61.
 104. Nagaveni NB, Umashankara KV, Radhika NB, Reddy PB, Manjunath S. Maxillary paramolar: Report of a case and literature review. *Arch Orofac Sci* 2010;5:24-8.
 105. Sugimura M, Tsuji Y, Yamaguchi K, Yoshida Y, Tanioka H. Mandibular distomolars. A review of the Japanese literature and a report of three additional cases. *Oral Surg Oral Med Oral Pathol* 1975;40:341-5.
 106. Martínez González JM, Alobera Gracia MA, Baca Pérez Bryan R, Trobo Muñoz P. Patología y diagnóstico de los molares supernumerarios. *Av Odontoestomatol* 1992;8:661-6.
 107. Fleury JE, Deboets D, Assaad C, Maffre N. Molaires surnuméraires. *Rev Stomatol Chir Maxillofac* 1984;85:136-41.
 108. Neville BW, Damm DD, Allen CM, Buoquot JE. Abnormalities of teeth. In: Neville BW, Damm DD, Allen CM, Buoquot JE, editors. *Oral and Maxillofacial Pathology*. 2nd ed. Pennsylvania: Saunders; 2002. p. 49-106.
 109. Arathi R, Ashwini R. Supernumerary teeth: A case report. *J Indian Soc Pedod Prev Dent* 2005;23:103-5.
 110. Shah A, Hirani S. A late-forming mandibular supernumerary: A complication of space closure. *J Orthod* 2007;34:168-72.
 111. Khalaf K, Robinson DL, Elcock C, Smith RN, Brook AH. Tooth size in patients with supernumerary teeth and a control group measured by image analysis system. *Arch Oral Biol* 2005;50:243-8.
 112. Zmener O. Root resorption associated with an impacted mesiodens: A surgical and endodontic approach to treatment. *Dent Traumatol* 2006;22:279-82.
 113. Högstöm A, Andersson L. Complications related to surgical removal of anterior supernumerary teeth in children. *ASDC J Dent Child* 1987;54:341-3.
 114. Tay F, Pang A, Yuen S. Unerupted maxillary anterior supernumerary teeth: Report of 204 cases. *ASDC J Dent Child* 1984;51:289-94.
 115. Hurlen B, Humerfelt D. Characteristics of premaxillary hyperodontia. A radiographic study. *Acta Odontol Scand* 1985;43:75-81.
 116. Shetty R, Sandler PJ. Keeping your eye on the ball. *Dent Update* 2004;31:398-402.
 117. Rallan M, Rallan NS, Goswami M, Rawat K. Surgical management of multiple supernumerary teeth and an impacted maxillary permanent central incisor. *BMJ Case Rep* 2013;2013:???
 118. Celikoglu M, Kamak H, Oktay H. Prevalence and characteristics of supernumerary teeth in a non-syndrome Turkish population: Associated pathologies and proposed treatment. *Med Oral Patol Oral Cir Bucal* 2010;15:e575-8.
 119. von Arx T. Anterior maxillary supernumerary teeth: A clinical and radiographic study. *Aust Dent J* 1992;37:189-95.
 120. Saeed NR, Mackay FA. The oral surgery/orthodontic interface: 2. Local causes of malocclusion. *Am J Orthod* 1982;81:417-22.
 121. Prabhu NT, Munshi AK. Surgical management of a labially placed permanent maxillary central incisor after supernumerary tooth extraction: Report of a case. *J Clin Pediatr Dent* 1997;21:201-3.
 122. Gregg TA, Kinirons MJ. The effect of the position and orientation of unerupted premaxillary supernumerary teeth on eruption and displacement of permanent incisors. *Int J Paediatr Dent* 1991;1:3-7.
 123. Rasmussen P, Kotsaki A. Inherited retarded eruption in the permanent dentition. *J Clin Pediatr Dent* 1997;21:205-11.
 124. Mitchell L, Bennett TG. Supernumerary teeth causing delayed eruption – A retrospective study. *Br J Orthod* 1992;19:41-6.
 125. Silling G, Keller JG, Feingold M. Retained primary teeth: Their effect on developing occlusions. *ASDC J Dent Child* 1979;46:296-9.
 126. Dubuk AN, Selvig KA, Tellefsen G, Wikesjö UM. Atypically located paramolar. Report of a rare case. *Eur J Oral Sci* 1996;104:138-40.
 127. Popovich F, Thompson GW. Maxillary diastema: Indications for treatment. *Am J Orthod* 1979;75:399-404.
 128. De Oliveira Gomes C, Drummond SN, Jham BC, Abdo EN, Mesquita RA. A survey of 460 supernumerary teeth in Brazilian children and adolescents. *Int J Paediatr Dent* 2008;18:98-106.