

## CASE STUDY

# Positron Emission Tomography Scan (PET/CT) During the COVID-19 Pandemic: a Case Series

Renata Milardovic<sup>1</sup>, Nermina Beslic<sup>1</sup>, Sejla Ceric<sup>1</sup>, Amera Sadija<sup>1</sup>, Spomenka Kristic<sup>2</sup>, Berisa Hasanbegovic<sup>3</sup>

<sup>1</sup>Clinic of Nuclear Medicine and Endocrinology, Clinical Center of Sarajevo University, Sarajevo, Bosnia and Herzegovina

<sup>2</sup>Clinic of Radiology, Clinical Center of Sarajevo University, Sarajevo, Bosnia and Herzegovina

<sup>3</sup>Clinic of Oncology, Clinical Center of Sarajevo University, Sarajevo, Bosnia and Herzegovina

Corresponding author: Renata Milardovic, MD, Clinic of Nuclear Medicine and Endocrinology, Clinical Center of Sarajevo University, Sarajevo, Bosnia and Herzegovina. E-mail: milardovic2001@yahoo.com. ORCID ID: <http://www.orcid.org/0000-0002-3240-5630>.

doi: 10.5455/aim.2020.28.292-297

ACTA INFORM MED. 2020 DEC 28(4): 292-297

Received: Nov 11, 2020

Accepted: Dec 14, 2020

© 2020 Renata Milardovic, Nermina Beslic, Sejla Ceric, Amera Sadija, Spomenka Kristic, Berisa Hasanbegovic

This is an Open Access article distributed under the terms of the Creative Commons Attribution Non-Commercial License (<http://creativecommons.org/licenses/by-nc/4.0/>) which permits unrestricted non-commercial use, distribution, and reproduction in any medium, provided the original work is properly cited.

## ABSTRACT

**Introduction:** A number of nuclear medicine procedures significantly dropped worldwide during the COVID-19 pandemic. Every nuclear medicine department has faced changed working environment in terms of the type of requested procedures, number of requests and personal protection issues. Also, some specificities emerged that affect standard operating procedures. **Aim:** The aim here is to present different clinical scenarios related to RT PCR molecular testing and COVID-19-associated pulmonary findings on PET/CT in oncologic patients. **Methods:** A case series of four patients imaged on oncologic PET/CT is presented. Short clinical history followed by description of significant PET/CT findings and their importance from the perspective of COVID-19 pandemic and interpretation of PET/CT findings is presented. **Conclusion:** PET/CT imaging remains of paramount importance for oncologic patients during the pandemic. Under the unprecedented circumstances, interpretation of PET/CT findings has become more complex having some specificities that must be kept in mind.

**Keywords:** PET/CT, COVID-19, pneumonia, RT PCR, SARS- CoV-2.

## 1. INTRODUCTION

A number of both diagnostic and therapeutic nuclear medicine procedures significantly dropped throughout the departments worldwide during the COVID-19 pandemic. Over that time, all health systems have been forced to shift to SARS-CoV-2-related clinical and epidemiological issues and urgent procedures, mostly leaving diagnostic imaging to be available only for such purposes, at least in the beginning.

According to the survey performed by the International Atomic Energy Agency (IAEA) in 72 countries, the total number of diagnostic procedures in nuclear medicine decreased 54%. Out of all nuclear diagnostic procedures, Positron Emission Tomography (PET/CT) was the least affected and displayed a decrease of 36%. This can be attributed to the fact that most of PET/CT studies are oncologic, and the diagnostics and treatment of oncologic patients remain of paramount importance.

## 2. AIM

The aim here is to present different clinical scenarios related to RT PCR molecular testing and COVID-19-associated pulmonary findings on PET/CT in oncologic patients.

## 3. METHODS

We present a case series of four oncologic patients referred to <sup>18</sup>F-FDG PET/CT imaging for evaluation of the primary oncologic disease, follow-up or evaluation of treatment response. For each oncologic patient, a different and unexpected clinical scenario is presented.

All patients were imaged in accordance with the institutional protocol upon the application of 370 MBq of <sup>18</sup>F-fluodeoxyglucose (<sup>18</sup>F-FDG) intravenously. Low-dose whole body PET/CT acquisition was performed with a 16-slice CT scanner without IV contrast. The results were interpreted visually and semi-quantitatively by a nuclear medicine physician and a radiologist together.

Three patients got RT PCR

SARS-CoV-2 tested and proved negative within 48 hours prior to the imaging. The fourth patient was not tested within 48 hours before the imaging, and also never had any symptoms suggestive of SARS-CoV-2 infection. Molecular RT-PCR SARS-CoV-2 testing was performed at our Institution. Clinical signs suggestive of COVID-19 disease were also observed during history taking.

#### **CASE 1**

#### **INCIDENTAL FINDINGS OF COVID-19 PULMONARY LESIONS ON PET/CT FOR BREAST CANCER CASE STUDY**

A fifty-year-old patient with breast cancer was referred to a follow-up PET/CT exam in order to evaluate for the treatment response. The patient was diagnosed with HER-2 positive invasive ductal breast cancer after the radical right mastectomy in 2015. Post-surgery she was treated with chemotherapy, hormonal therapy and radiotherapy of the pelvis for the metastatic disease in the lymph nodes. In 2019, she was diagnosed with metastatic disease in the liver when the combined HER 2 targeted therapy (Perjeta+Herceptin) was prescribed. Before the study, the patient was asymptomatic and tested negative on RT-PCR SARS CoV-2 performed with 48 hours from the imaging. A low-dose whole-body PET/CT was performed after the injection of 368,5 MBq of 18F-fluodeoxyglucose intravenously and peroral contrast agent was applied. Acquisition parameters were determined in accordance with the institutional protocol. PET/CT images demonstrated in both lungs multiple ground glass opacities that were located peripherally in the parenchyma. All lesions accumulated 18-F fluodeoxyglucose with the low to moderate intensity, SUVmax 3,8. Described lung lesions were very highly suggestive of the COVID-19 disease, and the patient was isolated and referred for re-testing immediately. PET/CT also demonstrated multiple hypermetabolic lesions in the liver, bones and the local and distant lymph nodes consistent with the metastatic disease. Repeated RT-PCR SARS-CoV2 testing performed hours from PET/CT imaging proved positive. Continued isolation was recommended and the oncology visit was postponed.

#### **Conclusion**

A fifty-six-year-old man with Mantle cell lymphoma was referred to a follow-up PET/CT exam due to suspected relapse of the disease. The patient was diagnosed with Mantle cell lymphoma after neck lymph node biopsy in 2016. He was treated with systemic therapy (chemotherapy) and the last chemotherapy cycle was in 2018. During follow-up period he noticed neck lymph node enlargement. Before the study, the patient was asymptomatic and tested negative on RT-PCR SARS CoV-2 performed with 48 hours from the imaging. A low-dose whole-body PET/CT was performed after the injection of 362,5 MBq of 18F- fluodeoxyglucose intravenously and peroral contrast agent was applied. Acquisition parameters were determined in accordance with the institutional protocol. PET/CT images demonstrated peripheral lung consolidation in both lungs. All lesions accumulated 18-F fluodeoxyglucose with high intensity, SUVmax 7.8. Described lung lesions were very highly suggestive

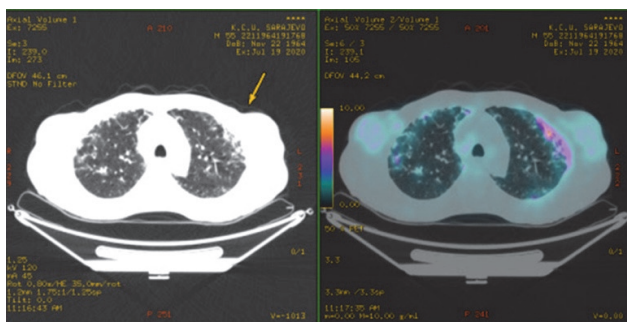
of the COVID-19 disease, and the patient was isolated and referred for retesting immediately. PET/CT also demonstrated extensive hypermetabolic lymphadenopathy (neck, axillary, mediastinal, hilar, retroperitoneal, abdominal, pelvic lymph nodes involvement). Repeated RT-PCR SARS-CoV2 testing performed hours from PET/CT imaging proved negative.

#### **INCIDENTAL FINDINGS OF COVID-19 PULMONARY LESIONS ON PET/CT FOR BREAST CANCER CASE STUDY**

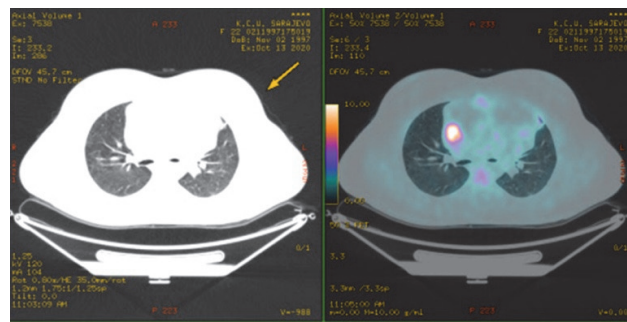
A fifty-year-old patient with breast cancer was referred to a follow-up PET/CT exam in order to evaluate for the treatment response. The patient was diagnosed with HER-2 positive invasive ductal breast cancer after the radical right mastectomy in 2015. Post-surgery she was treated with chemotherapy, hormonal therapy and radiotherapy of the pelvis for the metastatic disease in the lymph nodes. In 2019, she was diagnosed with metastatic disease in the liver when the combined HER 2 targeted therapy (Perjeta+Herceptin) was prescribed. Before the study, the patient was asymptomatic and tested negative on RT-PCR SARS CoV-2 performed with 48 hours from the imaging. A low-dose whole-body PET/CT was performed after the injection of 368,5 MBq of 18F-fluodeoxyglucose intravenously and peroral contrast agent was applied. Acquisition parameters were determined in accordance with the institutional protocol. PET/CT images demonstrated in both lungs multiple ground glass opacities that were located peripherally in the parenchyma. All lesions accumulated 18-F fluodeoxyglucose with the low to moderate intensity, SUVmax 3,8. Described lung lesions were very highly suggestive of the COVID-19 disease, and the patient was isolated and referred for re-testing immediately. PET/CT also demonstrated multiple hypermetabolic lesions in the liver, bones and the local and distant lymph nodes consistent with the metastatic disease. Repeated RT-PCR SARS-CoV2 testing performed hours from PET/CT imaging proved positive. Continued isolation was recommended and the oncology visit was postponed.

#### **Conclusion**

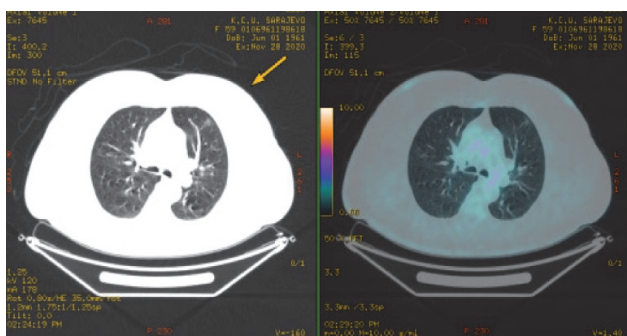
A fifty-six-year-old man with Mantle cell lymphoma was referred to a follow-up PET/CT exam due to suspected relapse of the disease. The patient was diagnosed with Mantle cell lymphoma after neck lymph node biopsy in 2016. He was treated with systemic therapy (chemotherapy) and the last chemotherapy cycle was in 2018. During follow-up period he noticed neck lymph node enlargement. Before the study, the patient was asymptomatic and tested negative on RT-PCR SARS CoV-2 performed with 48 hours from the imaging. A low-dose whole-body PET/CT was performed after the injection of 362,5 MBq of 18F- fluodeoxyglucose intravenously and peroral contrast agent was applied. Acquisition parameters were determined in accordance with the institutional protocol. PET/CT images demonstrated peripheral lung consolidation in both lungs. All lesions accumulated 18-F fluodeoxyglucose with high intensity, SUVmax 7.8. Described lung lesions were very highly suggestive of the COVID-19 disease, and the patient was isolated



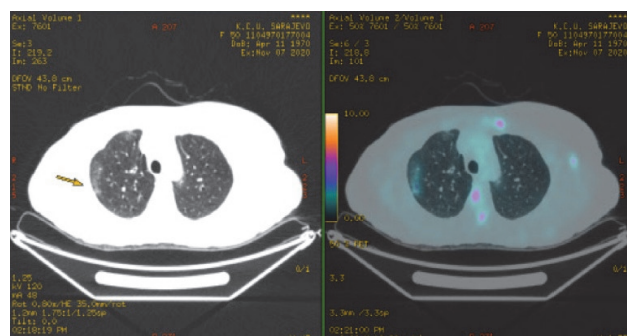
**Figure 1.** Axial CT and fused PET/CT images demonstrate in an otherwise asymptomatic patient 18F-FDG-positive peripheral lung consolidations (arrow) in both lungs suspicious of COVID-19, SUVmax 7,8. Negative RT PCR and lack of clinical symptoms attributed them to lymphoma.



**Figure 2.** Axial CT of a Hodgkin lymphoma patient who was positive for SARS-CoV-2 on the following day demonstrates only a clinically insignificant FDG-negative mild atelectasis (arrow) in the left lower lobe. Note FDG-positive right hilar adenopathy on a fused PET/CT image.



**Figure 3.** Both axial CT and fused PET/CT image of a patient with ovarian cancer and COVID-19 disease resolved a month ago demonstrate multiple GGO (arrow) bilaterally. Lack of FDG uptake on PET/CT indicates non-active COVID-19 pneumonia consistent with regression of disease.



**Figure 4.** RT PCR negative breast cancer patient with ground-glass opacities (GGO) in both lungs (arrow) on CT that were FDG-positive on PET/CT, SUVmax 3,8. Such finding was consistent with active COVID-19 pneumonia. Repeated RT PCR in two days was positive. Note multiple FDG-positive bone lesions on PET/CT.

and referred for retesting immediately. PET/CT also demonstrated extensive hypermetabolic lymphadenopathy (neck, axillary, mediastinal, hilar, retroperitoneal, abdominal, pelvic lymph nodes involvement). Repeated RT-PCR SARS-CoV2 testing performed hours from PET/CT imaging proved negative. A fifty-six-year-old male with Mantle cell lymphoma was referred to a follow-up PET/CT exam due to a suspected relapse of disease. The patient was diagnosed with Mantle cell lymphoma four years ago after the neck lymph node biopsy. He was treated with chemotherapy until two years ago. In a follow-up he noticed neck lymph node enlargement. Patient also has hepatitis B under treatment.

The patient was asymptomatic and RT-PCR negative within 48 hours from the imaging. PET/CT images demonstrated peripheral lung consolidation in both lungs. All lesions accumulated 18F-FDG with high intensity, SUVmax 7,8 (Figure 1). Described lung lesions were very highly suggestive of the COVID-19 disease, and the patient was isolated and referred for retesting immediately. PET/CT also demonstrated extensive 18F-FDG-positive lymphadenopathy (neck, axillary, mediastinal, hilar, retroperitoneal, abdominal and pelvic lymph nodes involvement) confirming the relapse of Mantle cell lymphoma.

In order to rule out COVID-19 disease, repeated RT PCR testing was performed only hours from PET/CT imaging. It was negative, and the patient proceeded to chemotherapy.

In this case, in RT PCR negative patient, PET/CT detected 18F-FDG positive lung consolidations that were very suspicious of active COVID-19 pneumonia in the absence of respiratory symptoms and fever. After repeatedly negative RT PCR SARS-CoV-2 test and X-rays confirming the presence of pulmonary opacities, described lung consolidations were concluded to be lymphoma-related. Five months later the patient became symptomatic and tested RT PCR positive with a quick resolution of fever and cough. Follow-up PET/CT is planned.

**CASE 2**

A twenty-three-year-old female patient with a newly diagnosed Hodgkin lymphoma was referred to PET/CT for staging purposes. History and clinical examination revealed neck lymphadenopathy with no signs of respiratory distress. Diagnostic CT of the thorax revealed extensive neck and mediastinal lymphadenopathy with no signs of lobar or interstitial pneumonia.

PET/CT confirmed the presence of the lymphoma-related active disease in the neck and mediastinal lymph nodes as well as diffuse hypermetabolism of the bone marrow. Lung analysis revealed only mild atelectasis in the left lung that was considered clinically non-significant (Figure 2).

A day later and upon the hematologist’s referral, the patient was re-tested and confirmed RT PCR positive. She still had no symptoms and was followed-up by a hematologist.

In this case, the patient tested RT PCR positive one day after PET/CT imaging. In the course of her disease, the patient had always been symptom-free. PET/CT was also negative for COVID-19 disease. Noteworthy is the absence of B symptoms including fever that might be lymphoma-related but also might be caused by an infection. The patient was isolated at home, retested in a couple of weeks time and then proceeded to treatment. Normal PET/CT not suggestive of COVID-19 pneumonia in a RT PCR positive patient may be a result of the timing of imaging that was performed early in the course of disease without lung lesions developed yet. Another reason might be unaffected lungs in general in the course of COVID-19. Mild atelectasis detected on PET/CT, however, might be attributed to earlier COVID-19 pneumonia especially given the patient's young age.

### CASE 3

A fifty-year-old patient with the history of breast cancer was referred to a follow-up PET/CT in order to evaluate treatment response. Radical mastectomy was performed five years earlier revealing HER-2 positive invasive ductal cancer. She was treated with chemotherapy, hormonal therapy and radiotherapy. A year ago a metastatic disease was diagnosed in the liver when the combined immune targeted therapy was initiated.

On imaging, the patient was asymptomatic. PET/CT images demonstrated in both lungs multiple ground glass opacities (GGO) located peripherally in the lung parenchyma. All lung lesions accumulated 18F-FDG with low intensity, SUVmax 3,8 (Figure 3). Detected lung lesions were very highly suggestive of the COVID-19 disease, and the patient was isolated and referred for retesting immediately. PET/CT also demonstrated multiple 18F-FDG positive lesions in the liver, bones and the local and distant lymph nodes consistent with the metastatic disease.

Repeated RT PCR SARS-CoV-2 testing performed hours from PET/CT imaging was positive. Continued isolation was recommended and the oncology visit was postponed.

In this case, PET/CT demonstrated typical findings for COVID-19 pneumonia in the otherwise asymptomatic patient who tested RT PCR negative within 48 hours before the imaging. When she was contacted, the patient was at work and referred only to a mild cold that had spontaneously resolved before the imaging. In this case, PET/CT helped in identifying and isolating a potential source of the spread of disease in the community. The patient's RT PCR false negative test might be attributed to the time elapsed from the infection to testing, which was insufficient for the required viral load to be formed. Another cause might be an inherent sensitivity of the test itself.

### INCIDENTAL FINDINGS OF COVID-19 PULMONARY LESIONS ON PET/CT FOR BREAST CANCER CASE STUDY

A fifty-year-old patient with breast cancer was referred to a follow-up PET/CT exam in order to evaluate for the treatment response. The patient was diagnosed with HER-2 positive invasive ductal breast cancer after

the radical right mastectomy in 2015. Post-surgery she was treated with chemotherapy, hormonal therapy and radiotherapy of the pelvis for the metastatic disease in the lymph nodes. In 2019, she was diagnosed with metastatic disease in the liver when the combined HER 2 targeted therapy (Perjeta+Herceptin) was prescribed. Before the study, the patient was asymptomatic and tested negative on RT-PCR SARS CoV-2 performed with 48 hours from the imaging. A low-dose whole-body PET/CT was performed after the injection of 368,5 MBq of 18F-fluodeoxyglucose intravenously and peroral contrast agent was applied. Acquisition parameters were determined in accordance with the institutional protocol. PET/CT images demonstrated in both lungs multiple ground glass opacities that were located peripherally in the parenchyma. All lesions accumulated 18-F fluodeoxyglucose with the low to moderate intensity, SUVmax 3,8. Described lung lesions were very highly suggestive of the COVID-19 disease, and the patient was isolated and referred for retesting immediately. PET/CT also demonstrated multiple hypermetabolic lesions in the liver, bones and the local and distant lymph nodes consistent with the metastatic disease. Repeated RT-PCR SARS-CoV2 testing performed hours from PET/CT imaging proved positive. Continued isolation was recommended and the oncology visit was postponed.

### Conclusion

A fifty-six-year-old man with Mantle cell lymphoma was referred to a follow-up PET/CT exam due to suspected relapse of the disease. The patient was diagnosed with Mantle cell lymphoma after neck lymph node biopsy in 2016. He was treated with systemic therapy (chemotherapy) and the last chemotherapy cycle was in 2018. During follow-up period he noticed neck lymph node enlargement. Before the study, the patient was asymptomatic and tested negative on RT-PCR SARS CoV-2 performed with 48 hours from the imaging. A low-dose whole-body PET/CT was performed after the injection of 362,5 MBq of 18F-fluodeoxyglucose intravenously and peroral contrast agent was applied. Acquisition parameters were determined in accordance with the institutional protocol. PET/CT images demonstrated peripheral lung consolidation in both lungs. All lesions accumulated 18-F fluodeoxyglucose with high intensity, SUVmax 7.8. Described lung lesions were very highly suggestive of the COVID-19 disease, and the patient was isolated and referred for retesting immediately. PET/CT also demonstrated extensive hypermetabolic lymphadenopathy (neck, axillary, mediastinal, hilar, retroperitoneal, abdominal, pelvic lymph nodes involvement). Repeated RT-PCR SARS-CoV2 testing performed hours from PET/CT imaging proved negative.

### CASE 4

A fifty-nine-year-old female patient with metastatic ovarian cancer was referred to PET/CT exam for restaging of disease. The patient was diagnosed with ovarian cystadenocarcinoma after hysterectomy and adnexectomy in 2016. In 2019, she underwent surgery because of suspected local recurrence when metastatic disease in the colon and paraurethral region was diagnosed

and chemotherapy was initiated.

One month before PET/CT imaging the patient had asymptomatic RT PCR SARS-CoV-2 positive infection.

PET/CT images demonstrated bilateral ground glass opacities (GGO) in the superior pulmonary lobes that were located peripherally. There was no 18F-FDG accumulation in those lesions (Figure 4). Also, 18F-FDG positive metastatic lymph node in the pelvis was noted.

This is the case in which PET/CT findings were in accordance with both clinical stage of COVID-19 disease and RT PCR molecular testing result. Described eumetabolic pulmonary opacities are characteristic of COVID-19 pulmonary infection which is not in the active phase.

#### 4. DISCUSSION

COVID-19 seems to be a versatile disease with different clinical presentations and severity of symptoms, if any. To establish a diagnosis of COVID-19 disease, molecular and serological testings for viral RNA or antibodies, clinical findings and diagnostic imaging results are correlated.

RT PCR tests are considered the gold standard for detecting COVID-19 disease. In the UK, RT PCR tests have sensitivity and specificity of more than 95%. Reports in systematic review hold false negative rates of tests between 2% and 33% in repeat sample testing. Both false-negative and false-positive tests impose burden on health systems, and that for different reasons. False-negative tests cause unimpeded spread of disease, especially by asymptomatic and mildly symptomatic patients. False-positive results are mostly caused by contamination and cross-reactions with other viruses or genetic material. They affect the healthcare system through the unnecessary workload on its workers and financial burdens. That is why any diagnostic test should be interpreted in the context of pretest probability of disease which is an estimate, before testing, of the person's symptoms and chance of being infected.

Radiological modalities chest radiography and chest CT remain the mainstay of COVID-19 imaging. Typical radiological presentations most commonly include ground-glass opacities (GGO), coarse horizontal linear opacities and consolidations of the lung parenchyma. They are most likely to be found on the lung periphery and in the lower zones, most often bilaterally.

A hybrid diagnostic modality PET/CT is not indicated in making a diagnosis or follow-up of COVID-19 disease. Also, it is not recommended in the emergency setting. However, different clinical scenarios position PET/CT in the diagnostic algorithm of COVID-19. Described in our case series are only some scenarios that might be encountered in a PET/CT office. In the oncologic clinical setting, PET/CT remains one of the most commonly indicated diagnostic procedure for staging, restaging and evaluation of therapeutic response purpose. Estimates are that about 80% of PET/CT is oncologic.

When performed and interpreted in the COVID-19 pandemic, necessary is for PET/CT interpreting physicians to be aware of two issues. First, the clinical presentation of SARS-CoV-2 infection varies from asymptomatic

to multi-organ involvement and failure of organs and systems in severe forms of disease. Secondly, but not less important, laboratory, clinical and diagnostic findings are different in different stages of COVID-19.

18F-FDG PET/CT is considered a sensitive but not specific imaging method given the fact that apart from the tumors, infection and inflammation sites also accumulate 18F-FDG due to their cellular metabolism. For this reason, active sites of viral pneumonitis caused by SARS-CoV-2 present as 18F-FDG positive on PET and fused PET/CT images, increasing the specificity of the study. Besides, other types of pneumonitis also present as 18F-FDG positive when in active phase.

PET/CT findings may also be helpful in diagnosing the stage of COVID-19 pneumonia using semi-quantification of metabolism of 18F-FDG, and differing active vs. non-active or earlier disease. Our cases indicate different values of SUVmax, which reflect different stages of COVID-19 pneumonia.

Another diagnostic dilemma appears when a primary disease which may affect the lungs, such as lymphoma causes pulmonary changes that raise suspicion of COVID-19 pneumonia. In such cases, additional testing, therapeutic regimes and a follow-up imaging yield a necessary resolution. In every clinical setting, signs and symptoms of disease are to be closely monitored and relied upon.

In asymptomatic patients, whole-body or total-body acquisitions on PET/CT may detect COVID-19 incidentally. Such incidental findings are to be reported and immediately addressed to the referring physicians in order to adjust or change the treatment plans and carry out personal protection measures.

In COVID-19 pandemic, nuclear medicine departments are obliged to follow personal protection measures and protect their staff. Such measures are to combine with radiation safety measures already in place without contradicting any.

When performing PET/CT, nuclear medicine staff must be aware of the laboratory, clinical and diagnostic variations related to COVID-19.

Although at present PET/CT does not play an established part in making a diagnosis of COVID-19 or follow-up of the disease, in some cases it aids both of them.

#### 5. CONCLUSION

PET/CT imaging remains of paramount importance for oncologic patients during the pandemic. Under the unprecedented circumstances, interpretation of PET/CT findings has become more complex having some specificities that must be kept in mind.

- **Author's contribution:** All authors were involved in all steps of preparation this article. Final proof reading was made by the first author.
- **Conflict of interest:** None declared.
- **Financial support and sponsorship:** Nil.

#### REFERENCES

1. Freudenberg LS. et al. Global Impact of COVID-19 on Nuclear Medicine Departments: An International Survey in April 2020.

- J Nucl Med July 24, 2020. jnumed.120.249821
2. Surkova E, Nikolayevskyy V, Drobniowski F. False positive COVID 19 results: hidden problems and costs. The Lancet Respiratory Medicine. 2020 Dec; 8(12): P1167-1168.
  3. European Centre for Disease Prevention and Control; Transmission of COVID-19. <https://www.ecdc.europa.eu/en/covid-19/latest-evidence/transmission>. Accessed on: June 30, 2020.
  4. Watson J, Whiting PF, Brush SE. Interpreting a COVID-19 test result. BMJ. 2020; 369:m1808.
  5. Woloshin S, Patel N, Keselheim AS. False negative tests for SARS COV-2 infection- challenges and implications. N Engl J Med. 2020 Aug; 383: e38.
  6. Cleverley J, Piper J, Jones M. The role of chest radiography in confirming covid-19 pneumonia. BMJ. 2020; 370: m2426.
  7. Chunxia Qin, Fang Liu, Tzu-Chen Yen, Xiaoli Lan. 18F-FDG PET/CT findings of COVID-19: a series of four highly suspected cases. Eur J Nucl Med Mol Imaging. 2020 May; 47(5): 1282-1286.
  8. Olivari L, Riccardi N, Rodari P, Buonfrate D, Diodato S, Formenti F, Angheben A, Salgarello M. Accidental Diagnosis of COVID-19 Pneumonia after 18F FDG PET/CT: a case series. Clin Transl Imaging. 2020 Sep 24: 1-8
  9. Larici AR. et al. Multimodality imaging of COVID-19 pneumonia: from diagnosis to follow-up. A comprehensive review. Eur J Radiol. 2020 Oct; 131: 109217. Published online 2020 Aug 17. doi: 10.1016/j.ejrad.2020.109217.
  10. Ali SA, Abdelkawi MM. Incidentally recognized COVID-19 pneumonia in routine oncologic 18F-FDG PET/CT examinations: a local experience during pandemic era. Egypt J Radiol Nucl Med. 2020; 51: 220.
  11. Joob B., Wiwanitkit V. 18F-FDG PET/CT and COVID-19. Eur J Nucl Med Mol Imaging. 2020; 47:1348.

**International Medical Informatics Association**

About Us | IMIA Members | Publications | MedInfo | IMIA WGs & SIGs | IMIA NI | IAHSI

## Welcome to IMIA

**CSO – WHO DG dialogue “Digital Health during COVID-19: Opportunities and Challenges”**  
December 16, 3:00 PM – 4:30 PM CET (Central Eastern Time)

IMIA invites their members to participate in an interactive civil society dialogue with WHO Director General Dr Tedros Adhanom Ghebreyesus, on the theme “Digital Health during COVID-19: Opportunities and Challenges”, the invitation is open to all members of civil society organizations (CSOs), so please share this invitation with your networks.

Organized by the International Medical Informatics Association (IMIA) and IMIA’s International Academy for Health Sciences Informatics (IAHSI), this dialogue is part of the series of CSO – WHO DG dialogues selected by CSOs to be organized on different topics of interest for the civil society related to COVID-19 response.

IMIA’s panel will be moderated by Dr. Najeeb Al-Shorbaji, and the IMIA panelists are:  
 Professor Sabine Koch, Sweden – IMIA, President  
 Professor William (Bill) Hersh, U.S.A., IMIA’s Academy, IAHSI President  
 Professor Tze Yun Leong, Singapore  
 Professor Riccardo Bellazzi, Italy  
 Mr. Moctar Yedaly, Ethiopia

[Read more...](#)

---

**IMIA update – MedInfo’s**

MedInfo 2021 submission deadline will be announced soon. Due to COVID IMIA will be hosting an online/virtual version of MedInfo for 2021. We will also provide you with the update on MedInfo 2023 and MedInfo 2025 at that same time.

---

**THE IMPACT OF COVID-19 ON HEALTH INFORMATICS: Supporting Health Information Technology Innovation through Timely Knowledge Synthesis and Exchange Survey**

IMIA’s Students and Emerging Professionals Special Interest Group, IMIA SEP, is pleased to support a research study concerning the health information technology response to the COVID-19 pandemic. The research study is also supported by the Canadian Nursing Informatics Association and is being conducted by Charlene Ronquillo, Assistant Professor of the Daphne Cockwell School of Nursing at Ryerson University in Toronto, Ontario, Canada.

**Login**


Log In

Username

Password

Remember Me

Log In



**IMIA – Latest News**

**INVITATION TO JOIN IMIA IN A “DIGITAL HEALTH DURING COVID-19: OPPORTUNITIES AND CHALLENGES” DIALOGUE WITH WHO DIRECTOR GENERAL, DECEMBER 16TH**  
December 10, 2020

**NURSES AND MIDWIVES LEAD HEALTHCARE DIGITAL TRANSFORMATION**  
October 20, 2020

**CAREER OPPORTUNITIES – OCTOBER 2020**  
October 11, 2020

**IAHSI FELLOWS IN THE NEWS...**  
September 29, 2020

**CAREER OPPORTUNITY – THE UNIVERSITY OF TEXAS AT ARLINGTON COLLEGE OF ENGINEERING PROFESSOR/NOOYI ENDOWED CHAIR**  
September 28, 2020

**2020 CALL FOR PROPOSALS FOR...**