

## Endoscopic closure of the ulcer bed after endoscopic resection using the “mucosal adaptive ring to close an endoscopic artificial ulcer” (MARCEAU) procedure

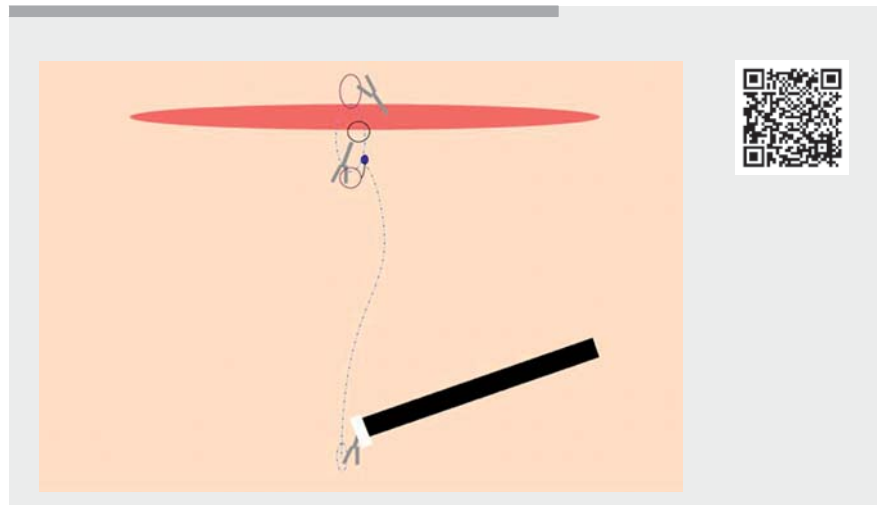
OPEN  
ACCESS

Endoscopic submucosal dissection (ESD) allows for wide resection of mucosal neoplasms, and closure of the subsequent artificial mucosal defects has been proven to diminish the rate of adverse events. Nevertheless, the technical success rate of such closure is low, around 57 % in large dedicated series [1]. Therefore, several tools and techniques have been described to facilitate the sealing of such ulcers, but none seems to be sufficiently user friendly to be widely used in real-life practice.

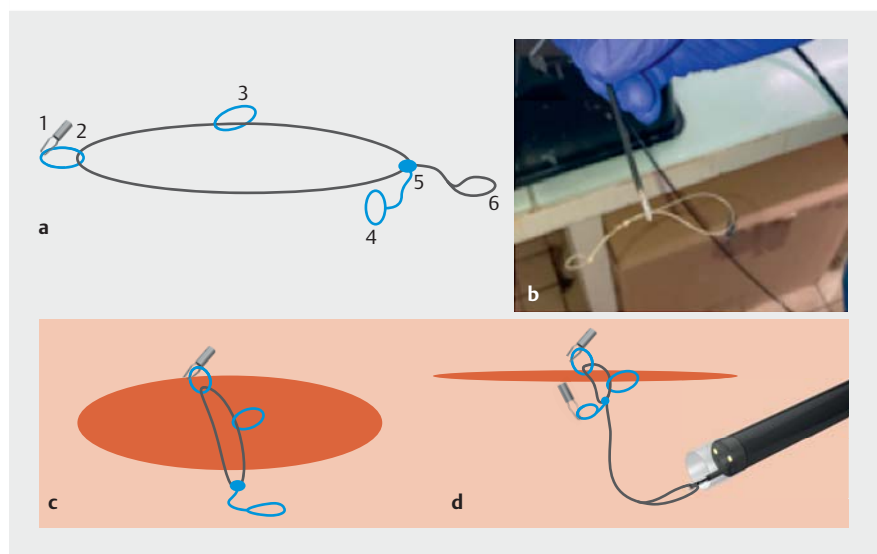
We describe the use of a new closure device known as the “mucosal adaptive ring to close an endoscopic artificial ulcer” (MARCEAU) that is both easy to use and fully internalized through the endoscope channel, providing an easy way to meet the objective of sealing an ulcer when required (► **Video 1**). This device is made from anti-return sutures (VLOC; Medtronic, USA) with a loop that can be grasped and pulled, thereby closing the loop progressively. In our case, it was introduced through the operating channel of a pediatric colonoscope.

We report here the case of a 70-year-old patient with a 3.5-cm nongranular laterally spreading tumor in the right colon. We have previously described the traction device (A-TRACT-2) that was used here to perform ESD resection. Resection was curative and R0. Afterwards, we dropped the MARCEAU device onto the operating site, and fixed it to two edges of the ulcer with clips (► **Fig. 1**; ► **Video 1**). A third clip was placed at the middle of the resection capturing the sealing device. We then used a forceps to tighten the device, bringing all the clips closer together, leading to prompt ulcer closure. No delayed bleeding was reported. The patient was discharged from the hospital on the following day.

This technique seems attractive and easy to use, especially when the ulcer size is



► **Video 1** Endoscopic closure of an ulcer bed following endoscopic resection using the “mucosal adaptive ring to close an endoscopic artificial ulcer” (MARCEAU) procedure.



► **Fig. 1** Illustration of the closure of an ulcer using the “mucosal adaptive ring to close an endoscopic artificial ulcer” (MARCEAU) device showing: **a** a drawing of the MARCEAU device (1, edge loop; 2, hemoclip; 3, additional fixation loop; 4, fixed point for one edge; 5, 6, tightening wire with the loop to grasp and pull); **b** photograph of the device; **c** schematic view of the fixation; **d** schematic view of the closure with the loop tightened.

too large for the use of clips alone. Further studies are needed to confirm its effectiveness.

Endoscopy\_UCTN\_Code\_TTT\_1AQ\_2AI

## Competing interests

The authors declare that they have no conflict of interest.

## The authors

**Louis-Jean Masgnaux<sup>1</sup>, Clara Yzet<sup>1</sup>, Jean Grimaldi<sup>1</sup>, Timothée Wallenhorst<sup>2</sup>, Jérémie Jacques<sup>3</sup>, Jérôme Rivory<sup>1</sup>, Mathieu Pioche<sup>1</sup>**

- 1 Gastroenterology and Endoscopy Unit, Edouard Herriot Hospital, Hospices Civils de Lyon, Lyon, France
- 2 Gastroenterology and Endoscopy Unit, Pontchaillou University Hospital, Rennes, France
- 3 Gastroenterology and Endoscopy Unit, Dupuytren University Hospital, Limoges, France

## Corresponding author

**Mathieu Pioche, MD**

Endoscopy Unit, Department of Digestive Diseases, Pavillon L – Edouard Herriot Hospital, 69437 Lyon, France  
mathieu.pioche@chu-lyon.fr

## Reference

- [1] Albéniz E, Álvarez MA, Espinós JC et al. Clip closure after resection of large colorectal lesions with substantial risk of bleeding. *Gastroenterology* 2019; 157: 1213–1221.e4

## Bibliography

*Endoscopy* 2022; 54: E1076–E1077

DOI 10.1055/a-1913-7733

ISSN 0013-726X

published online 1.9.2022

© 2022. The Author(s).

This is an open access article published by Thieme under the terms of the Creative Commons Attribution-NonDerivative-NonCommercial License, permitting copying and reproduction so long as the original work is given appropriate credit. Contents may not be used for commercial purposes, or adapted, remixed, transformed or built upon. (<https://creativecommons.org/licenses/by-nc-nd/4.0/>)

Georg Thieme Verlag KG, Rüdigerstraße 14, 70469 Stuttgart, Germany



## ENDOSCOPY E-VIDEOS

<https://eref.thieme.de/e-videos>



*Endoscopy E-Videos* is an open access online section, reporting on interesting cases and new techniques in gastroenterological endoscopy. All papers include a high quality video and all contributions are freely accessible online. Processing charges apply (currently EUR 375), discounts and waivers acc. to HINARI are available.

This section has its own submission website at  
<https://mc.manuscriptcentral.com/e-videos>