

Access this article online

Quick Response Code:



Website:

http://www.braincirculation.org

DOI:

10.4103/bc.bc\_61\_21

# Recurrent vertebrobasilar strokes and transient-ischemic attacks with challenging workup: Case report

Sibylle Wilfling, Mustafa Kilic, Blagovesta Tsoneva, Martin Freyer<sup>1</sup>, David Olmes, Christina Wendl<sup>2</sup>, Ralf A. Linker, Felix Schlachetzki

## Abstract:

Detecting the stroke etiology in young patients can be challenging. Among others, determining causality between ischemic stroke and patent foramen ovale (PFO) remains a complicated task for stroke neurologists, given the relatively high prevalence of PFOs. Thorough diagnostic workup to identify incidental vascular risk factors and rare embolic sources is crucial to avoid premature PFO closure suggesting successful secondary stroke prevention. In this paper, we report on a 38-year-old patient with recurrent vertebrobasilar territory, especially right posterior inferior cerebellar artery (PICA) territory strokes. After the initial suspicion of a left vertebral artery (VA) dissection was not confirmed by ultrasound and magnetic resonance imaging (MRI) and other major risk factors were excluded, a PFO was detected and closed. Successful PFO closure was confirmed by transesophageal echocardiography, yet recurrent transient-ischemic attacks and vertebrobasilar strokes, especially during nighttime and in the early morning, occurred despite various antiplatelet and antithrombotic regimes and a persistent right-to-left shunt was detected by bubble transcranial Doppler. Finally, MRI after another vertebrobasilar infarction detected a transient left VA occlusion that finally led to the diagnosis of a left VA pseudoaneurysm from an incident emboligenic dissection in the atlas segment. This pseudoaneurysm together with an anatomical variant of the right PICA originating with the right anterior inferior cerebellar artery from the basilar artery finally explained the recurrent ischemic events of the patient. After successful treatment with coil occlusion, the patient suffered no further stroke and recovered completely. In summary, stroke in the young remains a diagnostic challenge. The incidental finding of a PFO should not deter from thorough stroke workup and the follow-up of these patients including PFO closure verification should be performed under the guidance of vascular neurologists.

## Keywords:

Embolic stroke of undetermined source, etiology, patent foramen ovale, pseudoaneurysm, risk of paradoxical embolism, stroke, vertebral artery dissection, young

## Introduction

Ischemic stroke incidence in young patients is increasing and accounts for about 15% of all strokes.<sup>[1,2]</sup> In particular, stroke etiology differs significantly from elderly patients in whom classical vascular risk factors predominate.<sup>[1-4]</sup> In patients younger than 45 years, risk factors leading to

atherosclerosis and microangiopathy are less common and arterial dissections and other specific stroke causes (genetic disorders, coagulopathies, and vasculitis) prevail.<sup>[1-5]</sup> Nevertheless, the prevalence of such risk factors is increasing even among the younger population.<sup>[1]</sup> In some cases, several different risk factors and pathologies may be found, resulting in a difficult diagnostic workup.

Overall, in over 30% of all cases of young stroke patients, the etiology remains

This is an open access journal, and articles are distributed under the terms of the Creative Commons Attribution-NonCommercial-ShareAlike 4.0 License, which allows others to remix, tweak, and build upon the work non-commercially, as long as appropriate credit is given and the new creations are licensed under the identical terms.

For reprints contact: WKHLRPMedknow\_reprints@wolterskluwer.com

**How to cite this article:** Wilfling S, Kilic M, Tsoneva B, Freyer M, Olmes D, Wendl C, *et al.* Recurrent vertebrobasilar strokes and transient-ischemic attacks with challenging workup: Case report. *Brain Circ* 2022;8:50-6.

Department of Neurology,  
University of Regensburg,  
Medbo Bezirksklinikum  
Regensburg, <sup>2</sup>Center  
for Neuroradiology,  
Medbo Bezirksklinikum  
and University Clinic  
Regensburg, Regensburg,  
<sup>1</sup>Department of Neurology,  
Municipal Hospital, Robert  
Koch Str. 1, Landshut  
84034, Germany

### Address for correspondence:

Ms. Sibylle Wilfling,  
Department of Neurology,  
Station 22B, University  
of Regensburg, Medbo  
Bezirksklinikum  
Regensburg,  
Universitätsstr. 84, 93053  
Regensburg, Germany.  
E-mail: sibylle.wilfling@  
medbo.de

Submission: 16-08-2021

Revised: 06-10-2021

Accepted: 01-11-2021

Published: 21-03-2022

cryptogenic.<sup>[3]</sup> In almost half of young stroke patients with cryptogenic stroke, a patent foramen ovale (PFO) can be detected.<sup>[6]</sup> However, the overall PFO prevalence is 25%, thus rendering the establishment of a causal connection between PFO and stroke difficult.<sup>[7]</sup>

Yet, proper and complete diagnostic workup is crucial to prevent further ischemic events. Based on the proven pathology, therapy of dissections usually consists of oral anticoagulation or antiplatelet therapy (AP).<sup>[8,9]</sup> In concordance with recent studies, PFO closure is usually performed based on the risk of paradoxical embolism (RoPE) score or the embolic stroke of undetermined source (ESUS) criteria.<sup>[10-14]</sup>

### Case Report

We report on a 38-year-old patient [timeline and medication: Figure 1] without relevant prior illnesses who initially suffered from transient ataxia lasting a few hours. The following day, he developed dysarthria, hemiataxia of the right side as well as hemiparesis right and hypesthesia of the right foot leading to hospital admission (National Institutes of Health

Stroke Scale [NIHSS] at presentation 6). Intravenous thrombolysis was performed and the symptoms resolved. After diagnostic workup, the patient was dismissed from the hospital without symptoms (NIHSS 0, modified Rankin Scale 0).

At that time, the diagnostic workup revealed several pathologies:

Cerebral imaging with native computed tomography (CT) before thrombolysis did not show any anomalies. A dissection of the left vertebral artery (VA) in the V3 segment was suspected on CT angiography, but this finding was not confirmed in time-of-flight magnetic resonance (MR) angiography, fat-saturated MR imaging (MRI), and duplex ultrasound the following days. cMRI and CT image at the initial presentation are shown in Figure 2. Unfortunately, the standard protocol for fat-saturated MRI only reaches as far as C1 and thus did not reach the dissection site. Another reason why the suspected dissection was discarded was that it was contralateral to parts of the infarction that were located in the right posterior inferior cerebellar artery (PICA) territory and could (initially) not be explained by a left VA dissection. Furthermore, neither trauma nor neck pain or coughing/sneezing were reported by the patient. Yet, MRI studies revealed disseminated ischemic strokes within the right PICA, left superior cerebellar artery, and basilar artery territories confirming the diagnosis of stroke as cause for the symptoms.

Extracranial and intracranial duplex ultrasound revealed neither any hemodynamically relevant stenoses of any vessel nor any plaques, solely an increased blood flow velocity could be seen in the left middle cerebral artery. Duplex sonography did not show any thrombosis on the leg or pelvic veins.

Furthermore, transthoracic echocardiography and transesophageal echocardiography (TEE) showed a hypermobile atrial septum and a mid-sized PFO with

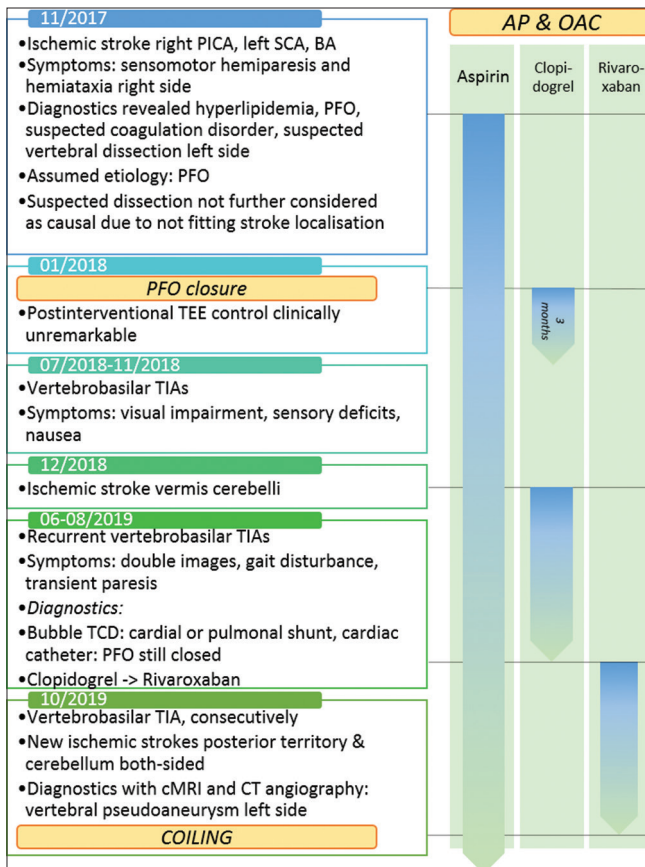


Figure 1: Timeline of events (left) and antiplatelet/antithrombotic medication (right). AP: Antiplatelet therapy, BA: Basilar artery, OAC: Oral anticoagulation, PFO: Patent foramen ovale, PICA: Posterior inferior cerebellar artery, SCA: Superior cerebellar artery, TIA: Transient-ischemic attack, TEE: Transesophageal echocardiography

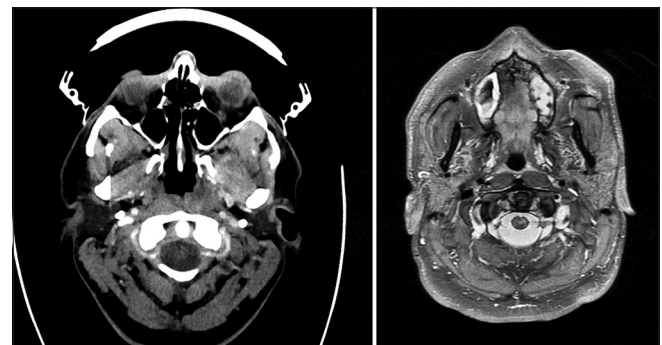
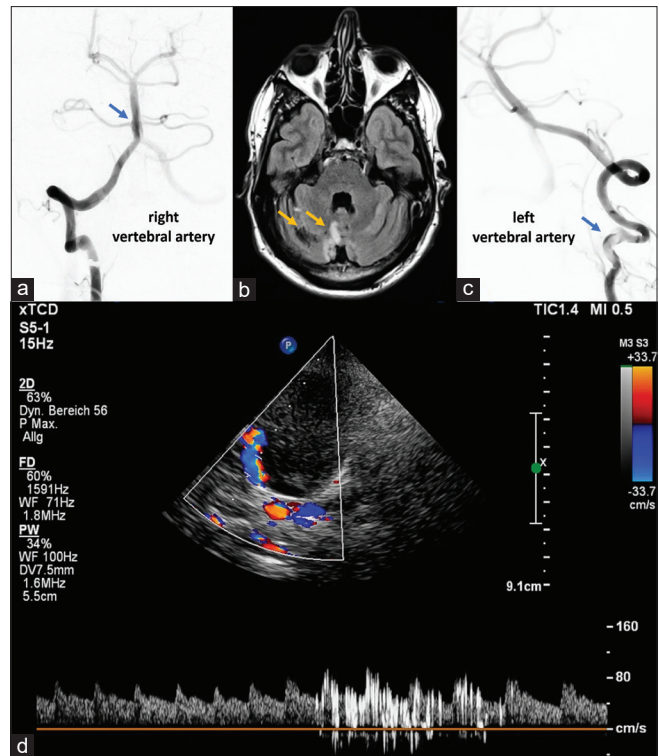


Figure 2: Images of the first presentation. The left side shows the CT with a slightly irregular left VA. The right image shows the corresponding MRI. Though a dissection could not be completely excluded, the possibility was discarded as it seemingly did not fit the lesion pattern

contrast agent passage during Valsalva maneuver. Monitor observation for 72 h revealed arterial hypertension and laboratory parameters (including autoimmune serology and extended coagulation laboratory) showed hyperlipidemia and increased activity of factors II and V. Overall, several of those abnormalities can be risk factors for stroke. The patient did not fulfill any clinical criteria for Fabry disease. The PFO was thought to be causal for the ischemic stroke. Based on a high RoPE score of 6 and the ESUS criteria,<sup>[10]</sup> PFO closure using an Amplatzer™ Atrial Septal Occluder (ASO; Abbott, Illinois, U. S. A.) was performed and its success verified by follow-up TEE. Consecutively, dual platelet aggregation with aspirin 100 mg and clopidogrel 75 mg daily was initiated for 3 months. Platelet activation assay ruled out nonresponsiveness to aspirin and clopidogrel treatment.

Despite successful PFO closure that was confirmed twice by TEE, several other transient-ischemic attacks (TIAs) occurred after switching the dual antiplatelet treatment to monotherapy with aspirin. Symptoms included visual impairment, tinnitus, vertigo, and sensory deficits. Almost 1 year after PFO closure, another ischemic stroke in the right PICA territory occurred and dual platelet aggregation was re-initiated. Again, control of the PFO via TEE confirmed successful closure. Several further ischemic events and TIAs, despite dual anti-AP, occurred again in the vertebrobasilar territory during the following months – mainly at nighttime or in the early morning. Symptoms included double vision, gait disturbances, and transient paresis on the right side. For this, the patient presented at our neurovascular clinics for further diagnostics and reevaluation.

Here, a massive bubble shower in bubble transcranial Doppler (TCD) after intravenous injection of agitated blood-saline mixture was detected, suggestive of a persistent right-to-left shunt [Figure 3d]. Yet, neither TEE nor right-heart catheter revealed any cardiac abnormalities other than the closed PFO. In order to change the therapeutic regimen and according to the COMPASS trial,<sup>[15,16]</sup> dual platelet inhibition was switched to an off-label combined therapy of aspirin (100 mg/d) and rivaroxaban (2 × 2.5 mg/d) to additionally cover the plasmatic coagulation. However, even under the combined antiplatelet and antithrombotic therapy, another stroke in the thalamus, left mesencephalon, and both sides of the cerebellum occurred [Figure 3b]. Symptoms were severe dysarthria, diplopia, hemiparesis right, and hemiataxia right (NIHSS at presentation: 4). Again, this stroke occurred at nighttime/in a wake-up situation. Finally, MR angiography revealed a distal occlusion of the left VA. This finding led to the diagnosis of an embolic



**Figure 3:** Right vertebral artery with dominant right anterior inferior cerebellar artery: upper left/blue arrow (a), cerebellar, right-sided ischemias: upper middle, orange arrows (b), left vertebral artery with dissection and thrombus: Upper right (c), bubble transcranial Doppler with right-to-left shunt: lower image (d)

pseudoaneurysm (a pseudoaneurysm being the reason for embolic events), probably based on a previous dissection, in the V3 segment of the left VA [Figure 3c]. In the presence of a dominant right VA, the left VA was occluded therapeutically with coils in crossover technique (access with microcatheter via right VA due to a present embolus) with successful stasis in the left V2 segment. Spontaneous recanalization occurred a couple of days later and another coil occlusion with addition of a vascular plug (Amplatzer vascular plug 6 mm) had to be performed to protect the patient from further embolic events. Images of these interventions are shown in Figure 4.

CT angiography finally showed an anatomical variant with a dominant right anterior inferior cerebellar artery (AICA) supplying most of the right PICA territory (AICA-PICA) and a hypoplastic PICA from the right V4 segment [Figure 3a]. This finding explained the seemingly contradiction of the lesion pattern with defects in the right PICA territory due to the pathology being in the left VA [Figure 3a]. The patient was dismissed with an NIHSS of 2 and a modified Rankin Scale of 2. After neurorehabilitation and upon 1 year follow-up under aspirin 100 mg daily, the patient showed no neurological deficits apart from a left skew deviation undistinguishable from facial asymmetry.



## Discussion

Delayed embolic stroke from VA dissections and residual pseudoaneurysms are rare entities and in combination with variations of the cerebellar blood supply, they pose a diagnostic challenge. The restriction of the embolic pattern to the vertebrobasilar system and anatomical variants should be considered before initiating PFO closure, which, in our case, detracted from the final diagnosis of an embolic dissection pseudoaneurysm and thereby delayed the therapeutic intervention.

VA dissections occur in less than 1 in 100,000 people.<sup>[17]</sup> When only considering spontaneous dissections, they even represent the majority of cerebral artery dissections.<sup>[18]</sup> They can lead to dissection pseudoaneurysms of which about one-quarter is located in the VA with about 45% of those being located in the V2 segment followed by about 28% in the V3 segment.<sup>[19]</sup> Clinically, such patients are usually asymptomatic or suffer ischemic events like stroke or TIAs, while intracranial bleeding due to distal and intradural vertebral dissection is a rare but life-threatening event.<sup>[20]</sup>

By contrast, variations within the vertebrobasilar system, especially the AICA and PICA, are very common-hypoplastic PICAs with a dominant AICA are described in 15.6%–22.1% of all individuals (AICA-PICA cases/isolated agenesis<sup>[21-23]</sup>).

Data on the frequency of delayed (>30 days) embolization from pseudoaneurysms and residual stenosis are rare. Nally *et al.* and other groups reported an extremely low incidence of stroke in patients with (traumatic) VA dissection, rendering follow-up investigations unnecessary.<sup>[24,25]</sup> However, few case reports – including recently from our group – describe late stroke even months to years after the initial event.<sup>[26-28]</sup>

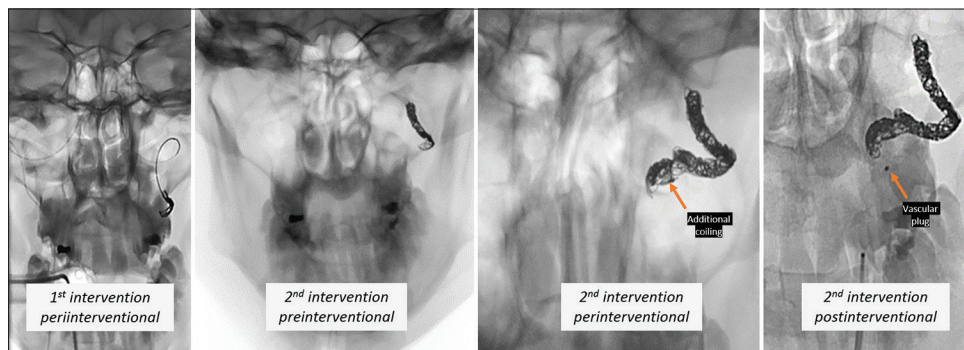
Common methods for the treatment of symptomatic pseudoaneurysms in the VA include minimally invasive

endovascular techniques as (balloon-assisted) coil embolization/parent vessel occlusion or flow-diverting stents with low complication rates.<sup>[18,29-33]</sup> However, case reports of affected patients, especially with aneurysms within the V2/V3 segment, mainly used flow diverters for treatment.<sup>[34-38]</sup> Therapeutic vessel occlusion of the affected VA is a less common approach<sup>[39-41]</sup> but shows a favorable outcome overall comparable to that of endovascular treatment with parent vessel preservation (63%–70%).<sup>[18]</sup> Data on the prevalence of recurrent ischemic events after VA dissection are sparse – overall, recurrent events are rare and occur with a frequency of <5%.<sup>[25,42,43]</sup>

In the case of our patient, we decided to occlude the left, affected VA as the right VA showed to be the dominant one with good perfusion.

In general, controlled trials on the short- and long-term outcome of medical versus any interventional treatment in dissection pseudoaneurysm appear warranted.

A right-to-left shunt after successful PFO closure was seen in bubble TCD, but neither in TEE nor in right heart catheterization. Various studies revealed a considerable percentage of patients being positive on bubble TCD and negative on echocardiography, for example, 10 out of 30 patients with residual shunt as reported by Droste *et al.*<sup>[44]</sup> or 63 out of 207 patients in an analysis by Goutman *et al.*<sup>[45]</sup> This is often attributed to the superior Valsalva maneuver. Gevorgyan Fleming *et al.* showed a PFO closure rate with different devices of about 85%–100% after intervention.<sup>[46]</sup> Our patient received an Amplatzer ASO ranging at a closure rate of 88%–97%.<sup>[46,47]</sup> Secondary causes for a residual right-to-left shunt are not uncommon (e.g., 17 out of 84 analyzed cases as reported by Jesurum *et al.*<sup>[48]</sup>) and might be attributed to noncardiac causes such as pulmonary arteriovenous fistulas.<sup>[49]</sup> Another analysis even showed that in 39 out of 322 patients, a residual right-to-left shunt could be seen, but in one-third of these patients (13/39), no residual passage could be crossed – which is about one-third of



**Figure 4:** Images of the two interventions in the patient– from left to right: (1) periinterventional image of coiling of left VA in crossover technique via the right VA with a microcatheter; (2) state after first coiling, preinterventional image before second intervention necessary because of revascularization; (3) periinterventional image of additional coiling during second intervention; (4) postinterventional image after second intervention with additional coils and vascular plug

all patients with a residual right-to-left shunt after PFO closure that is not attributable to any cardiac cause and thus does not necessarily represent a significant risk for recurrent ischemic events.<sup>[50]</sup>

## Conclusions

Anatomical variants in the vertebrobasilar territory, especially regarding the AICA/PICA balance, often cause diagnostic difficulties. In the case of our patient, this resulted in a rejection of the primary hypothesis of a vertebral dissection as etiology. As a conclusion, variants and pathologies within the vertebrobasilar vessels should be considered as possible causes when searching for the etiology of strokes, especially when they occur recurrently and in the same territory.

Recurrent embolizations from dissecting aneurysms are very rare under sufficient platelet inhibition or novel antithrombotic/antiplatelet regimens such as COMPASS. The accumulation of embolization at nighttime or in wake-up situations strongly suggests compression effects during sleep.

The finding of a PFO should not lead to the assumption that this PFO is automatically associated with or even the source of stroke. With a frequency of 20%–25%, PFOs are a frequent finding in the general population. Hence, it may be an incidental finding also in younger stroke patients and thorough workup by CT and CT angiography as well as ultrasound is crucial before performing intervention.

PFO closure in young patients should only be performed after exclusion of other etiologies of stroke. Even in patients with a high RoPE score, the indication should be placed very strictly and not solely be based upon the ESUS criteria that were primarily designed for embolic sources amenable for anticoagulation. Furthermore, many PFOs are incidental findings which results in a high number needed to treat. PFO closure might be associated with severe long-term complications such as atrial fibrillation which may – especially in young patients – lead to further strokes in the future.<sup>[12,51]</sup> In addition, intervention always bears a baseline risk of severe adverse events (among other periprocedural strokes, impaired wound healing, and vessel injuries).<sup>[51]</sup> Thus, further criteria need to be assessed complementary to the ESUS criteria (e.g., RoPE score, but also extensive diagnostics to exclude alternative etiologies) to filter for those patients having the most benefit from a potential PFO closure.

In the case of our patient, it seems possible that the presence of other multiple risk factors might have contributed to the formation of embolisms in addition to the causal dissecting aneurysm. This may at least

partly explain the recurrence of TIAs even under aggressive medical treatment. Last but not least, the right-to-left shunt shown by bubble TCD despite previous PFO closure should encourage neurologists to perform controls, i.e., using bubble TCD of such patients – independent from cardiac interventionalists.

This case report highlights the necessity for a thorough diagnostic workup, especially prior to PFO intervention to confirm the cryptogenic etiology of embolic stroke. Overall, ischemic stroke is a multifactorial disease with complex mechanisms. It is not uncommon that patients have many concurrent or coincidental (low) risk factors such as PFO, and this possibility should always be kept in mind during the diagnostic workup.

A limitation of this case report is the fact that only a single patient is described. Ideally, even if seemingly not fitting the side of the ischemia, a fat-saturated MRI that includes the suspected dissection site should have been performed earlier.

## Declaration of patient consent

The authors certify that they have obtained all appropriate patient consent forms. In the form, the legal guardian has given his consent for images and other clinical information to be reported in the journal. The guardian understands that names and initials will not be published and due efforts will be made to conceal identity, but anonymity cannot be guaranteed.

## Financial support and sponsorship

Nil.

## Conflicts of interest

There are no conflicts of interest.

## References

1. Putaala J. Ischemic stroke in young adults. *Continuum (Minneapolis)* 2020;26:386-414.
2. Singhal AB, Biller J, Elkind MS, Fullerton HJ, Jauch EC, Kittner SJ, *et al.* Recognition and management of stroke in young adults and adolescents. *Neurology* 2013;81:1089-97.
3. van Alebeek ME, Arntz RM, Ekker MS, Synhaeve NE, Maaijwee NA, Schoonderwaldt H, *et al.* Risk factors and mechanisms of stroke in young adults: The FUTURE study. *J Cereb Blood Flow Metab* 2018;38:1631-41.
4. Renna R, Pilato F, Profice P, Della Marca G, Broccolini A, Morosetti R, *et al.* Risk factor and etiology analysis of ischemic stroke in young adult patients. *J Stroke Cerebrovasc Dis* 2014;23:e221-7.
5. Ferro JM, Massaro AR, Mas JL. Aetiological diagnosis of ischaemic stroke in young adults. *Lancet Neurol* 2010;9:1085-96.
6. Mojadidi MK, Zaman MO, Elgendy IY, Mahmoud AN, Patel NK, Agarwal N, *et al.* Cryptogenic stroke and patent foramen ovale. *J Am Coll Cardiol* 2018;71:1035-43.
7. Homma S, Messé SR, Rundek T, Sun YP, Franke J, Davidson K, *et al.* Patent foramen ovale. *Nat Rev Dis Primers* 2016;2:15086.

8. Markus HS, Levi C, King A, Madigan J, Norris J; Cervical Artery Dissection in Stroke Study (CADISS) Investigators. Antiplatelet therapy vs. anticoagulation therapy in cervical artery dissection: The cervical artery dissection in stroke study (CADISS) randomized clinical trial final results. *JAMA Neurol* 2019;76:657-64.
9. Liebeskind DS, Kasner SE, Dashe JF. Spontaneous Cerebral and Cervical Artery Dissection: Treatment and Prognosis. Available from: <https://www.uptodate.com/contents/spontaneous-cerebral-and-cervical-artery-dissection-treatment-and-prognosis>. [Last accessed on 2021 Jul 28].
10. Diener HC, Grau A, Baldus S. Kryptogener Schlaganfall und Offenes Foramen ovale, S2e Leitlinie. Deutsche Gesellschaft für Neurologie (Hrsg), Leitlinien für Diagnostik und Therapie; 2018. Available from: <https://www.dgn.org/leitlinien>. [Last accessed on 2021 Jan 25].
11. Ghanem A, Liebetrau C, Diener HC, Elsässer A, Grau A, Gröschel K, *et al.* Interventional PFO closure – Consensus paper of the task force Interventional Cardiology of the German Cardiac Society – Cardiovascular Research together with the German Neurological Society and the German Stroke Society. *Kardiologie* 2018;12:415-23. [doi: 10.1007/s12181-018-0277-y].
12. Chatterjee A, Hillegass WB. Embolic stroke of undetermined source and patent foramen ovale closure: Practice insights from meta-analysis? *Catheter Cardiovasc Interv* 2018;92:1161-2.
13. Messé SR, Gronseth GS, Kent DM, Kizer JR, Homma S, Rosterman L, *et al.* Practice advisory update summary: Patent foramen ovale and secondary stroke prevention: Report of the Guideline Subcommittee of the American Academy of Neurology. *Neurology* 2020;94:876-85.
14. Messé SR, Brecker SJ. Treatment of Patent Foramen Ovale (PFO) for Secondary Stroke Prevention. Available from: <https://www.uptodate.com/contents/treatment-of-patent-foramen-ovale-pfo-for-secondary-stroke-prevention>. [Last accessed on 2021 Jul 28].
15. Eikelboom JW, Connolly SJ, Bosch J, Dagenais GR, Hart RG, Shestakovska O, *et al.* Rivaroxaban with or without aspirin in stable cardiovascular disease. *N Engl J Med* 2017;377:1319-30.
16. Steffel J, Eikelboom JW, Anand SS, Shestakovska O, Yusuf S, Fox KA. The COMPASS trial: Net clinical benefit of low-dose rivaroxaban plus aspirin as compared with aspirin in patients with chronic vascular disease. *Circulation* 2020;142:40-8.
17. Lee VH, Brown RD Jr., Mandrekar JN, Mokri B. Incidence and outcome of cervical artery dissection: A population-based study. *Neurology* 2006;67:1809-12.
18. Urasyanandana K, Songsang D, Aurboonyawat T, Chankaew E, Withayasuk P, Churojana A. Treatment outcomes in cerebral artery dissection and literature review. *Interv Neuroradiol* 2018;24:254-62.
19. Daou B, Hammer C, Chalouhi N, Starke RM, Jabbour P, Rosenwasser RH, *et al.* Dissecting pseudoaneurysms: Predictors of symptom occurrence, enlargement, clinical outcome, and treatment. *J Neurosurg* 2016;125:936-42.
20. Mitra A, Shlobin NA, Azad HA, Prasad N, Potts MB, Dahdaleh NS. Vertebral artery dissections with concurrent intracranial hemorrhage: A case series of 13 patients among a cohort of 301. *World Neurosurg* 2021;149:e1128-33.
21. Akgun V, Battal B, Bozkurt Y, Oz O, Hamcan S, Sari S, *et al.* Normal anatomical features and variations of the vertebrobasilar circulation and its branches: An analysis with 64-detector row CT and 3T MR angiographies. *ScientificWorldJournal* 2013;2013:620162.
22. Hou K, Li G, Luan T, Xu K, Xu B, Yu J. Anatomical study of anterior inferior cerebellar artery and its reciprocal relationship with posterior inferior cerebellar artery based on angiographic data. *World Neurosurg* 2020;133:e459-72.
23. Mazighi M, Porter PJ, Rodesch G, Alvarez H, Aghakhani N, Lasjaunias P. Vascular anomalies and the risk of multiple aneurysms development and bleeding. *Interv Neuroradiol* 2002;8:15-20.
24. Nally MC, Kling C, Hocking KM, Lillemoe H, Boll JM, Curci JA, *et al.* Follow-up imaging of traumatic vertebral artery dissections is unnecessary in asymptomatic patients. *J Vasc Surg* 2019;69:1704-9.
25. Scott WW, Sharp S, Figueroa SA, Madden CJ, Rickert KL. Clinical and radiological outcomes following traumatic Grade 1 and 2 vertebral artery injuries: A 10-year retrospective analysis from a Level 1 trauma center. *J Neurosurg* 2014;121:450-6.
26. Marschner-Preuth N, Warnecke T, Niederstadt TU, Dittrich R, Schäbitz WR. Juvenile stroke: cervical artery dissection in a patient after a polytrauma. *Case Rep Neurol* 2013;5:21-5.
27. Wurm G, Löffler W, Wegenschimmel W, Fischer J. Traumatic injury of the internal carotid artery in the extracranial segment. Description of a severe late complication. *Chirurg* 1995;66:916-9.
28. Schlachetzki F, Kerta S, Olmes D, Linker R. Paresis recurrent headache, dizziness, impaired vision and leg paresis for 8 weeks. *DGNeurologie* 2020;3:473-4.
29. Iihara K, Sakai N, Murao K, Sakai H, Higashi T, Kogure S, *et al.* Dissecting aneurysms of the vertebral artery: A management strategy. *J Neurosurg* 2002;97:259-67.
30. Moon K, Albuquerque FC, Cole T, Gross BA, McDougall CG. Stroke prevention by endovascular treatment of carotid and vertebral artery dissections. *J Neurointerv Surg* 2017;9:952-7.
31. Li H, Li XF, Zhang X, He XY, Duan CZ, Liu YC. Treatment of unruptured vertebral dissecting aneurysms: Internal trapping or stent-assisted coiling. *Int J Neurosci* 2016;126:243-8.
32. Shin GW, Jeong HW. Endovascular treatment of intracranial vertebral artery dissecting aneurysms: Follow up angiographic and clinical results of endovascular treatment in serial cases. *Neurointervention* 2015;10:14-21.
33. Krishna C, Sonig A, Natarajan SK, Siddiqui AH. The expanding realm of endovascular neurosurgery: Flow diversion for cerebral aneurysm management. *Methodist Debaque Cardiovasc J* 2014;10:214-9.
34. Shakir HJ, Rooney PJ, Rangel-Castilla L, Yashar P, Levy EI. Treatment of iatrogenic V2 segment vertebral artery pseudoaneurysm using pipeline flow-diverting stent. *Surg Neurol Int* 2016;7:104.
35. Wu H, Wang M, Li K, Wang F. Treatment of extracranial vertebral artery aneurysm with flow diversion. *World Neurosurg* 2020;138:328-31.
36. Plou P, Landriel F, Beltrame S, Hem S, Peralta O, García-Mónaco R, *et al.* Flow diverter for the treatment of pseudoaneurysms of the extracranial vertebral artery: Report of two cases and review of the literature. *World Neurosurg* 2019;127:72-8.
37. Ambekar S, Sharma M, Smith D, Cuellar H. Successful treatment of iatrogenic vertebral pseudoaneurysm using pipeline embolization device. *Case Rep Vasc Med* 2014;2014:341748.
38. Dolati P, Eichberg DG, Thomas A, Ogilvy CS. Application of pipeline embolization device for iatrogenic pseudoaneurysms of the extracranial vertebral artery: A case report and systematic review of the literature. *Cureus* 2015;7:e356.
39. Banfield JC, Shankar JJ. Amplatzer vascular plug for rapid vessel occlusion in interventional neuroradiology. *Interv Neuroradiol* 2016;22:116-21.
40. Yıldız AE, Peynircioğlu B, Cil BE. Applications of the amplatzer vascular plug 4. *Diagn Interv Radiol* 2012;18:225-30.
41. Mihlon F, Agrawal A, Nimjee SM, Ferrell A, Zomorodi AR, Smith TP, *et al.* Enhanced, rapid occlusion of carotid and vertebral arteries using the AMPLATZER Vascular Plug II device: The Duke Cerebrovascular Center experience in 8 patients with 22 AMPLATZER Vascular Plug II devices. *World Neurosurg* 2015;83:62-8.
42. CADISS Trial Investigators; Markus HS, Hayter E, Levi C, Feldman A, Venables G, *et al.* Antiplatelet treatment compared with

- anticoagulation treatment for cervical artery dissection (CADISS): A randomised trial. *Lancet Neurol* 2015;14:361-7.
43. Wessels T, Mosso M, Krings T, Klötzsch C, Harrer JU. Extracranial and intracranial vertebral artery dissection: Long-term clinical and duplex sonographic follow-up. *J Clin Ultrasound* 2008;36:472-9.
  44. Droste DW, Kriete JU, Stypmann J, Castrucci M, Wichter T, Tietje R, *et al.* Contrast transcranial Doppler ultrasound in the detection of right-to-left shunts: Comparison of different procedures and different contrast agents. *Stroke* 1999;30:1827-32.
  45. Goutman SA, Katzan IL, Gupta R. Transcranial Doppler with bubble study as a method to detect extracardiac right-to-left shunts in patients with ischemic stroke. *J Neuroimaging* 2013;23:523-5.
  46. Gevorgyan Fleming R, Kumar P, West B, Nouredin N, Rusheen J, Aboulhosn J, *et al.* Comparison of residual shunt rate and complications across 6 different closure devices for patent foramen ovale. *Catheter Cardiovasc Interv* 2020;95:365-72.
  47. Taggart NW, Reeder GS, Lennon RJ, Slusser JP, Freund MA, Cabalka AK, *et al.* Long-term follow-up after PFO device closure: Outcomes and complications in a single-center experience. *Catheter Cardiovasc Interv* 2017;89:124-33.
  48. Jesurum JT, Fuller CJ, Renz J, Krabill KA, Spencer MP, Reisman M. Diagnosis of secondary source of right-to-left shunt with balloon occlusion of patent foramen ovale and power M-mode transcranial Doppler. *JACC Cardiovasc Interv* 2009;2:561-7.
  49. Balbi M, Canepa M, Cheli M, Bezante GP, Brunelli C. Sometimes they come back: Recurrent noncardiac right-to-left shunt after percutaneous patent foramen ovale closure. *J Cardiovasc Med (Hagerstown)* 2017;18:443-6.
  50. Rovera C, Biasco L, Orzan F, Belli R, Omedè P, Gaita F. Percutaneous implantation of a second device in patients with residual right-to-left shunt after patent foramen ovale closure. *J Interv Cardiol* 2014;27:548-54.
  51. Safouris A, Kargiotis O, Psychogios K, Kalyvas P, Ikonomidis I, Drakopoulou M, *et al.* A narrative and critical review of randomized-controlled clinical trials on patent foramen ovale closure for reducing the risk of stroke recurrence. *Front Neurol* 2020;11:434.