

## Original Article

## Adverse events of emergency surgical front of neck airway access: an observational descriptive study

Asami Okada,<sup>1</sup> Yohei Okada,<sup>2,3</sup> Kenji Kandori,<sup>1</sup> Wataru Ishii,<sup>1</sup> Hiromichi Narumiya,<sup>1</sup> and Ryoji Iizuka<sup>1</sup><sup>1</sup>Department of Emergency Medicine and Critical Care, Japanese Red Cross Society Kyoto Daini Hospital, Kyoto, Japan, <sup>2</sup>Preventive Services, School of Public Health, Kyoto University, Japan, and <sup>3</sup>Department of Primary Care and Emergency Medicine, Graduate School of Medicine, Kyoto University, Kyoto, Japan

**Aim:** Emergency front of neck access (eFONA), such as scalpel cricothyroidotomy, is a rescue technique used to open the airway during “cannot intubate, cannot oxygenate” situations. However, little is known about the adverse events associated with the procedure. This study aimed to describe the adverse events that occur in patients who undergo eFONA and their management.

**Methods:** This retrospective observational cohort study included emergency patients who underwent eFONA between April 2012 and August 2020. We described the patients’ characteristics and the adverse events during or immediately after the procedure.

**Results:** Among 75,529 emergency patients during the study period, 31 (0.04%) underwent an eFONA. The median (interquartile range) age was 53 (39–67) years, and 23 patients (74.2%) were men. Of all cases, 13 (41.9%) experienced adverse events. Of these, three cases (23.2%) were cephalad misplacement of the intubation tube, one case (7.7%) was cuff injury, one case (7.7%) was tube obstruction due to vomiting, and one case (7.7%) was tube kink. In cases with these adverse events, the initial attempt of eFONA failed, and alternative immediate action was necessary to secure the airway.

**Conclusion:** This single-center retrospective observational study described several adverse events of eFONA. In particular, it is important to understand the possible life-threatening adverse events that lead to failure of securing airways such as cephalad displacement, tube obstruction, and tube kink and respond promptly to ensure a secure definitive airway for patients’ safety.

**Key words:** Airway complication, airway management, CICO, cricothyroidotomy, difficult airway, eFONA

## BACKGROUND

AIRWAY MANAGEMENT IS an essential procedure for critically ill emergency patients.<sup>1,2</sup> Management failure, such as failure of tracheal intubation due to facial trauma, edema, or anatomical abnormality, can result in “cannot intubate, cannot oxygenate” (CICO), which is a life-threatening situation due to hypoxic brain injury and cardiac arrest.<sup>1,2</sup> Although rare, if it occurs, it should be resolved within a few minutes to save a life.<sup>3</sup> Emergency front-of-neck airway access (eFONA), including scalpel cricothyroidotomy or needle cricothyroidotomy, is the last resort to open the airway during CICO.<sup>1,2</sup> It is one of the most

important skills for physicians involved in anesthesia, intensive care, and emergency medicine, and it is valuable to share the knowledge and experience of performing eFONA.

Guidelines, several studies, and educational courses have shared helpful information such as airway management strategy for CICO cases, team management, preparation, and how to perform eFONA, and the patients’ characteristics who required the eFONA.<sup>1–8</sup> However, to carry out eFONA safely, it is also necessary to understand what adverse events of eFONA could happen and how to deal with it if it happens. Previous studies only reported adverse events such as bleeding or infection of the eFONA site<sup>9,10</sup>; however, there are few reports about life-threatening adverse events that lead to airway management failure and require emergent action. We experienced several cases with adverse events of eFONA, which had not been previously reported. This information is necessary to ensure reliable airway management. In this study, we aimed to describe the adverse events that occur among patients who undergo eFONA and their management.

**Corresponding:** Yohei Okada, MD, PhD, Preventive Services, School of Public Health, Kyoto University, Japan and Department of Primary Care and Emergency Medicine, Graduate School of Medicine, Kyoto University, Shogoin Kawaramachi 54, Sakyo, 606-8507 Kyoto, Japan. E-mail: yokada-kyf@umin.ac.jp  
Received 14 Dec, 2021; accepted 29 Mar, 2022

## METHODS

THE CLINICAL RESEARCH Ethics Committee of Kyoto Daini Red Cross Hospital approved this study (approval ID: No. S2020-29). It conforms to the provisions of the Declaration of Helsinki. The ethics committee waived the requirement of informed consent because of the retrospective nature of the study.

### Study design, data source, and settings

This was a retrospective, observational cohort study. Clinical data were obtained by electrical chart review from the Japanese Red Cross Society Kyoto Daini Hospital Tertiary Critical Care Center in Kyoto City, Japan. Kyoto City is an urban area with a population of approximately 1.5 million. The total number of ambulance requests per year is approximately 80,000 cases in the entire city.<sup>11</sup> There are four tertiary critical care centers in Kyoto City, one of which is located in the center of Kyoto City. This hospital, which has 672 beds, provides primary to tertiary emergency care for any type of emergency, such as severe trauma, cardiac arrest, and stroke.

### Study cohort

This study included patients who underwent eFONA from the database of emergency patients between April 2012 and August 2020. Emergency front of neck access was defined as securing a patent airway through the anterior neck, including scalpel cricothyrotomy, needle cricothyroidotomy, or emergency tracheotomy. The electronic medical chart was implemented in 2012; therefore, this study included the patients thereafter.

### Data collection and patient outcomes

We collected the following clinical information: age, sex, body mass index (BMI), primary diagnosis, time of incidence (day shift, or night and holiday shift), type of procedure (scalpel cricothyrotomy, needle cricothyroidotomy, or emergency tracheotomy), use of muscle relaxants, the background of the attending physician (specialty, years since graduation, and whether a certified emergency physician), presence or absence of supervision by experienced staff, time from arrival at the hospital till the procedure, patient outcome, adverse events due to procedure, whether the airway was finally available, and outcome (mortality in the emergency department, survival, and functional status at discharge). A certified emergency physician specializes in

emergency medicine with at least 3 years of experience in a certified teaching hospital after the junior residency and is certified by the Japanese Association of Acute Medicine.

An adverse event was defined as an unintended and unfavorable problem that occurred during or immediately after the procedure and required some response based on the definition.<sup>12</sup> The incidence time was defined as a day shift from 9:00 a.m. to 5:00 p.m. on weekdays, and the night and holiday shift from 5:00 p.m. to 9:00 a.m. on the next day and holidays.

### Statistical analyses

We describe patient characteristics and the details of adverse events. Continuous variables are shown as the median and interquartile range (IQR), and categorical variables are as numbers and proportions (%). This study focused on describing the epidemiologic data of adverse events because we assumed that the number of included patients was not adequate for a statistical test to explore the factors associated with adverse events. All statistical analyses were undertaken using JMP Pro 14 (SAS Institute Inc., Cary, NC, USA).

## RESULTS

### Patient characteristics

AMONG 75,529 EMERGENCY patients, 31 (0.04%) underwent eFONA. In this study period, 2,196 patients underwent tracheal intubation in the emergency department, and the prevalence of eFONA among the patients who needed advance airway management was 1.4% (31/2,196). Among included patients, the median age was 53 (IQR 39–67) years, and 23 patients (74.2%) were men. The median BMI was 24.3 (IQR 23.6–26.7). Regarding the primary disease, 26 cases (83.9%) had external causes such as trauma, and five (16.1%) had internal medical causes. Regarding external causes, cardiac arrest due to external cause was the most common, in 18 cases (58.1%); among them, 10 cases (32.3%) were cardiac arrest due to blunt trauma, and all of them had mandibular or facial trauma. Thirty cases (96.8%) were treated in the emergency department and 26 (83.9%) during night and holiday shifts. Thirty cases (96.8%) were treated by emergency physicians, with a median of 6 (IQR 4–8) years since graduation and 9 (29%) by a certified emergency physician. The median time from arrival at the hospital to the procedure was 7 (IQR 2.5–20.2) min. Three cases (9.7%) secured the airway by oral tracheal intubation concurrently performed with eFONA and were ventilated by it;

otherwise, the other cases were ventilated by eFONA. In-hospital mortality was observed in 26 cases (82.9%) (Table 1), and all the mortality cases were judged as death due to primary causes.

## Adverse events

Adverse events occurred in 13 patients (41.9%). Details of the adverse events are shown in Table 2. Of these, six cases

**Table 1.** Characteristics of 31 patients who underwent emergency surgical front of neck airway access (eFONA)

	Total (n = 31)	With adverse event (n = 13)	Without adverse event (n = 18)
Male gender	23 (74.2)	11 (84.6)	12 (66.7)
Age	53 (39–67)	43 (32–59)	62 (47–74)
BMI	24.3 (23.6–26.7)	24.3 (21.8–29.2)	24.9 (23.8–26.4)
Causes			
Internal disease	5 (16.1)	2 (15.4)	3 (16.7)
Cardiac arrest due to internal cause	3 (9.7)	1 (7.7)	2 (11.1)
Heart disease	1 (3.2)	0 (0.0)	1 (5.6)
Stroke	1 (3.2)	1 (7.7)	0 (0.0)
External disease <sup>†</sup>	5 (16.1)	2 (15.4)	3 (16.7)
Cardiac arrest due to external cause	18 (58.1)	7 (53.8)	11 (61.1)
Trauma	6 (19.4)	4 (30.8)	2 (11.13)
Burn	1 (3.2)	0 (0.0)	1 (5.6)
Toxin	1 (3.2)	0 (0.0)	1 (5.6)
Mandible or facial Injury	10 (32.3)	5 (38.5)	5 (27.8)
Site of incident			
Emergency room	30 (96.8)	12 (92.3)	18 (100)
Operation room	1 (3.2)	1 (7.7)	0 (0.0)
Time of incident			
Day shift	5 (16.1)	2 (15.4)	3 (16.7)
Night and holiday shift	26 (83.9)	11 (84.6)	15 (83.3)
Details of eFONA			
Scalpel cricothyrotomy	25 (80.6)	12 (92.3)	13 (72.2)
Needle cricothyrotomy	5 (16.1)	1 (7.7)	4 (22.2)
Emergency tracheotomy	1 (3.2)	0 (0.0)	1 (5.6)
Use of muscle relaxants	3 (9.7)	2 (15.4)	1 (5.6)
Specialty of the physician			
Emergency physician	30 (96.8)	13 (100.0)	17 (94.4)
Not emergency physician	1 (3.2)	0 (0.0)	1 (5.6)
Time since graduation of physician (years)	6 (4–8)	7 (4.5–8.5)	5 (4–7)
<6 years	14 (45.2)	5 (38.5)	9 (50)
6–9	13 (41.9)	7 (53.8)	6 (33.3)
≥10	3 (9.7)	1 (7.7)	2 (11.1)
Unknown	1 (3.2)	0 (0.0)	1 (5.6)
Certification of emergency physician	9 (29)	4 (30.8)	5 (27.8)
Time to procedure (min)	7 (2.5–20.2)	6 (2–21)	7 (4.5–18)
Patient outcome			
Mortality at ED	18 (58.1)	7 (53.8) <sup>‡</sup>	11 (61.1)
In-hospital mortality	26 (83.9)	10 (76.9)	16 (88.9)

Note: Data are shown as median (interquartile range) or n (%).

Abbreviations: BMI, body mass image; ED, emergency department.

<sup>†</sup>Cardiac arrest due to external cause included 10 cases of cardiac arrest due to blunt trauma.

<sup>‡</sup>All seven cases who died in the ED with adverse events were cardiac arrest patients (six cases were external cause and one case was internal cause).

**Table 2.** Detailed information about adverse events in patients who underwent emergency surgical front of neck airway access

Adverse event	<i>n</i>	How to detect adverse events	Solution to adverse events
One lung intubation	6	X-ray	Resecured the appropriate position
Cephalad misplacement of intubation tube	3	X-ray Droplets from the oral cavity Resistance to ventilation by the BVM	Re-insertion of the tube using gum-elastic bougie guide ( <i>n</i> = 2) Concurrent oral tracheal intubation ( <i>n</i> = 1)
Hemorrhage	3	Visual observation	Ligation or compression hemostasis
Pneumothorax	1	X-ray	Chest tube drainage
Tube kink	1	Resistance to ventilation by the BVM and	Convert to emergent tracheostomy
Tube obstruction	1	visual observation	Re-insertion of larger size new tube
Cuff injury	1	Cuff leak sound	Re-insertion of the new tube

Abbreviation: BVM, bag valve mask.

(46.2%) were one-lung intubation, three cases (23.2%) were cephalad misplacement of the intubation tube, three (23.2%) were hemorrhage at the incision site that required hemostasis, one case (7.7%) was a pneumothorax, one case (7.7%) was cuff injury, one case (7.7%) was tube obstruction due to vomiting, and one case (7.7%) was tube kink (some of these cases included more than one adverse event).

## Details of adverse events

### One-lung intubation

Six of the 31 patients underwent one-lung intubation. All cases were identified by X-ray and resecured in an appropriate position. To consider appropriate tube placement to avoid one-lung ventilation, anatomical measurement indicated that the median distance from the cricothyroid ligament to the tracheal bifurcation was 105 (IQR 90–110) mm among the 15 patients who underwent computed tomography imaging.

### Cephalad misplacement of intubation tube

Three patients had misplacement of the intubation tube cephalad. In one case, there was resistance to ventilation by the bag valve mask (BVM), and the tip of the tube was found in the oral cavity by laryngoscopy. In the second case, droplets were observed in the oral cavity during BVM ventilation. In the third case, no tube was seen in the trachea on radiography. Two of three cases were resolved by reinserting the tube using a gum-elastic bougie guide. The other case collapsed due to cardiac arrest during correction of the cephalad misplacement. While the reattempt to insert the tube was unsuccessful, a concurrent reattempt of oral tracheal intubation was successfully carried out, and the patient obtained the return of spontaneous circulation.

### Hemorrhage

Hemorrhage requiring hemostasis was observed in three of the 31 patients. In one case, damage to the superior thyroid artery was observed and ligated to stop the bleeding. We could not identify any vascular injury in the other cases, and pressure was applied to stop the bleeding.

### Others

Pneumothorax, mediastinal emphysema, and subcutaneous emphysema were observed on chest radiography in one case in which needle cricothyrotomy was carried out. There was also one case of cuff injury, one case of tube obstruction due to vomiting, and one of poor ventilation due to tube kink. In the case of cuff injury, the tube was replaced with a new one, and in case of tube obstruction, successful ventilation was achieved by replacing larger diameter tubes. The case of tube kink occurred in a pediatric patient with airway obstruction due to oral edema, and the tube of cricothyroidotomy was kinked because the space of the cricothyroid membrane was so small. Thus, in addition to the cricothyroidotomy, emergent tracheostomy was performed, and finally, the patient was ventilated.

## DISCUSSION

### Key observations

THIS single-center retrospective observational study described adverse events of eFONA, which included one-lung intubation, cephalad misplacement of the intubation tube, hemorrhage, pneumothorax, tube obstruction, and tube kink. Especially in the case of cephalad misplacement, tube obstruction, and tube kink, appropriate ventilation and

oxygenation could not be achieved in the initial attempt of eFONA, and immediate alternative action was necessary. We believe that it is clinically important to detect these adverse events at the earliest to ensure a definitive airway.

### Previous reports and strengths of this study

Compared with previous studies, our study has several strengths. First, this study summarized the adverse events of eFONA and reported the incidence of one-lung intubation, cephalad misplacement of the tube tip, tube obstruction, or tube kink, which had not been previously reported.

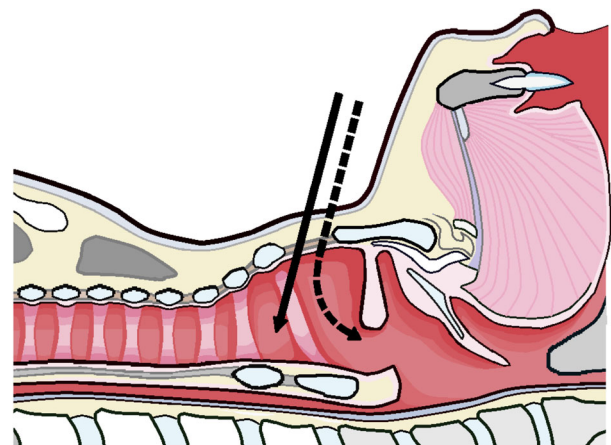
In a previous retrospective review of a level 1 single trauma center, including 50 cricothyroidotomies over 5 years, the prevalence of complications, such as incision errors, tube misplacement into the pretracheal space, and hemorrhage, was 14%.<sup>10</sup> In another retrospective review of the past 10 years at two level 1 trauma centers, including 54 cases of cricothyroidotomy, there were two cases of wound infection and three of bleeding requiring hemostasis.<sup>9</sup> Although some adverse events have been reported in previous studies, we did not find any reporting one-lung intubation, cephalad misplacement of the intubation tube tip, tube obstruction, or tube kink. These adverse events can occur immediately after tube insertion and should be rectified immediately because the patient's condition remains unstable at this time. Therefore, we believe that this study is clinically important for identifying these adverse events. Second, most previous studies on CICO situations were animal, simulation, or cadaver studies for eFONA management training<sup>4</sup>; however, this observational study was based on actual clinical practice. Generally, CICO occurs suddenly and unexpectedly, and the patient's condition is critical. Therefore, physicians are exposed to psychologically stressful situations. Furthermore, unexpected abnormalities, such as mandible injury due to trauma or airway obstruction due to vomiting, could be additional challenges for physicians. Unlike animal or simulation studies, this study could show the actual adverse events in a critical situation, which is helpful to physicians.

### Interpretation and clinical implications

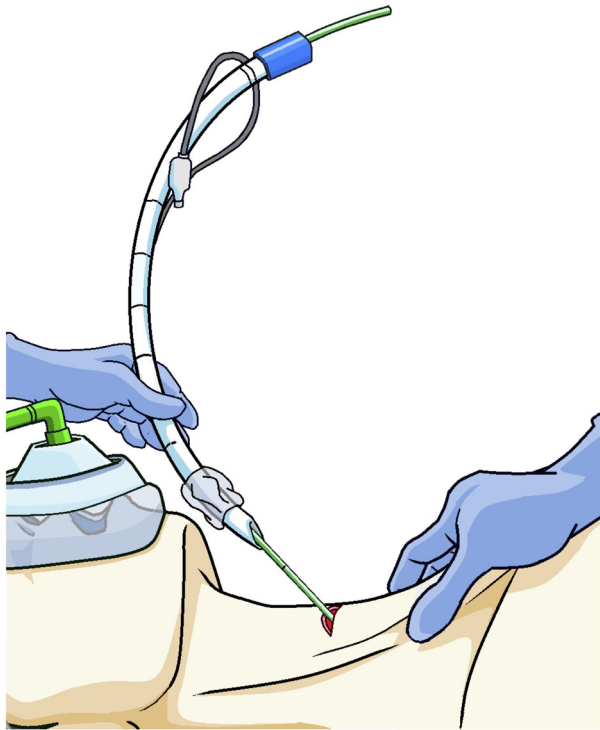
Among the adverse events observed in this study, we suggest that one of the most important to be aware of is cephalad misplacement. If it happens, securing the airway and appropriate oxygenation are not achieved; thus, it should be immediately addressed by re-insertion. If the reattempt fails, the patient's condition with deteriorate further, and cardiac arrest could occur. In this study, one of the three cases of cephalad misplacement resulted in cardiac arrest.

Furthermore, unlike one-lung ventilation, this adverse event does not happen during general oral tracheal intubation or other airway management procedures; therefore, physicians without experience of eFONA could be delayed detecting it. Accordingly, for emergency physicians or anesthesiologists, it is essential to recognize that cephalad misplacement could happen in eFONA for performing safely. To avoid cephalad misplacement of the intubation tube, we believe that the direction of tube insertion is technically important. If the direction or angle of tube insertion is inappropriate, there is a risk that the tip of the tube will be placed toward the cephalad (Fig. 1). Cephalad misplacement of the tube is suspected when there is resistance during ventilation by BVM or when air gushes from the mouth during ventilation, as in the cases in this study. If such an abnormality is observed, the tracheal tube should be removed and re-inserted immediately. When re-inserting a tracheal tube, we suggest that gum-elastic bougie should be considered to ensure that the tube is inserted appropriately (Fig. 2).

Moreover, we believe that the other most important adverse events were tube obstruction or tube kink, which required immediate re-insertion or change in the strategy. In the clinical situation, if resistance is observed in manual ventilation just after performing eFONA, tube obstruction or kink should be suspected. When tube obstruction due to vomiting or hemorrhage occurs, we suggest that it might be better to exchange the larger tube immediately, as was the case in this study. Furthermore, it should be noted that tube kink could be influenced by the space of the cricothyroid membrane where the tube is inserted. In this study, a tube



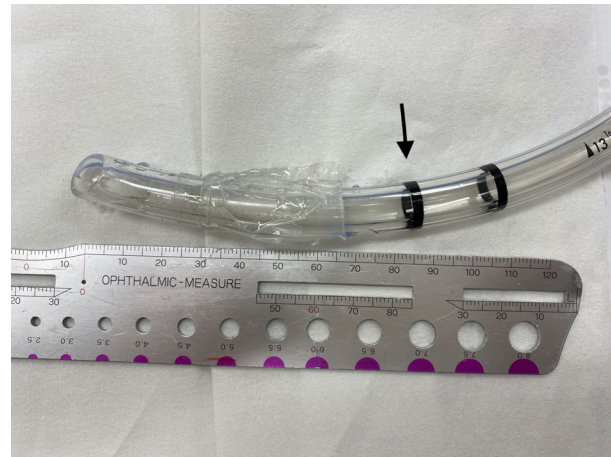**Fig. 1.** Schema of sagittal view of the neck. The solid arrow indicates the proper angle and direction of the tube insertion during emergency surgical front of neck airway access. If you approach in the wrong direction, as shown by the dotted arrow, the tip of the tube could point toward the head.



**Fig. 2.** Schema for inserting an intubation tube using a bougie during emergency surgical front of neck airway access. To avoid cephalad misplacement of the intubation tube, insert the tube in the correct direction using a gum-elastic bougie guide.

kink was observed in a pediatric case. For this case, we previously reported the detail that it was difficult to perform appropriate ventilation because the space of the cricothyroid membrane was so small that the tube was kinked, and it was required to convert the emergent tracheostomy.<sup>5</sup> Through these cases, we suggest that emergency physicians should be aware that tube obstruction or kink could occur after eFONA, and it should be corrected.

In this study, the most frequent adverse event was one-lung intubation. Although one-lung intubation can oxygenate the patient to some extent, it can cause pneumothorax due to excessive pressure on one lung. When a tube for general tracheal intubation is used in eFONA, one-lung intubation could be caused by inserting the tube too deeply.<sup>13</sup> This might also be caused by dislocation during patient transfer. X-ray is a simple method of detection and should be performed immediately after insertion. However, in some situations, portable X-rays are not immediately available, or the tube position might change even after imaging. Therefore, physicians managing the airway should always pay attention to the left–right difference in thorax elevation and auscultation. In particular, it should be carefully observed after tube



**Fig. 3.** Length of the end of the intubation tube for emergency surgical front of neck airway access. This picture shows the tip of a 6 mm intubation tube. It has a marker, 85 mm from the tip (arrow). The median distance from the cricothyroid ligament to the tracheal bifurcation was 105 (interquartile range, 90–110) mm among the 15 patients who underwent computed tomography imaging in this study. Thus, to prevent one-lung intubation, the intubation tube should be placed so as not to exceed this marker.

insertion and before and after patient transfer. If one-lung intubation is observed, it is necessary to pull the tube out to the appropriate position. If X-ray or other images are available, measuring the length of the tube to be pulled out may be valuable. In previous studies, the straight-line distance from the skin to the cricothyroid membrane was reported to be approximately 10 mm,<sup>14,15</sup> and the median distance from the cricothyroid ligament to the tracheal bifurcation in this study was 102 mm. The distance from the tip of the 6 mm tracheal tube to the glottis marker was 85 mm (Fig. 3). Thus, if a 6 mm endotracheal tube is used, one-lung intubation can be avoided by fixing the tracheal tube at the point where the glottis marker crosses the skin.

### Limitations

Our study had several limitations. First, although emergency physicians in our hospital had learned the indications for eFONA and choice of procedure (e.g., scalpel or needle) through the educational course, a strict protocol was not defined. Second, the sample size was limited; hence, it was inadequate to investigate the factors associated with adverse events using multivariable analysis. Third, because this was a retrospective study based on a medical chart review, the validity of the data was limited. Finally, data on adverse events in the late period, such as tracheal stenosis, were

limited. Multicenter prospective studies are necessary to resolve these limitations and investigate the factors associated with adverse events.

## CONCLUSIONS

**T**HIS single-center retrospective observational study described several adverse events of eFONA. In particular, it is important to understand the possible life-threatening adverse events that lead to failure of securing airway, such as cephalad misplacement, tube obstruction, and tube kink, and respond promptly to ensure a secure definitive airway for patients' safety.

## ACKNOWLEDGMENTS

**T**HIS RESEARCH DID not receive any specific grant from funding agencies in the public, commercial, or not-for-profit sectors.

## DISCLOSURE

**A**PPROVAL OF THE research protocol: The protocol for this research project has been approved by a suitably constituted Ethics Committee of Kyoto Daini Red Cross Hospital, Approval No. S2020-29.

Informed consent: The ethics committee waived the requirement for informed consent because of the retrospective nature of the study.

Registry and the registration no. of the study/trial: N/A.

Animal studies: N/A.

Conflict of interest: None.

## DATA AVAILABILITY STATEMENT

**D**ATA SHARING IS not applicable to this article because the ethics committee has not approved it.

## REFERENCES

- Higgs A, McGrath BA, Goddard C *et al.* Guidelines for the management of tracheal intubation in critically ill adults. *Br J Anaesth.* 2018; 120: 323–52.
- Frerk C, Mitchell VS, McNarry AF *et al.* Difficult Airway Society 2015 guidelines for management of unanticipated difficult intubation in adults. *Br J Anaesth.* 2015; 115: 827–48.
- Wong DT, Lai K, Chung FF, Ho RY. Cannot intubate-cannot ventilate and difficult intubation strategies: results of a Canadian national survey. *Anesth. Analg.* 2005; 100: 1439–46 table of contents.
- Pandian V, Leeper WR, Jones C *et al.* Comparison of surgical cricothyroidotomy training: a randomized controlled trial of a swine model versus an animated robotic manikin model. *Trauma Surg. Acute Care Open* 2020; 5: e000431.
- Okada Y, Ishii W, Sato N, Kotani H, Iiduka R. Management of pediatric 'cannot intubate, cannot oxygenate'. *Acute Med Surg* 2017; 4: 462–6.
- Okada Y, Hashimoto K, Ishii W, Iiduka R, Koike K. Development and validation of a model to predict the need for emergency front-of-neck airway procedures in trauma patients. *Anaesthesia* 2020; 75: 591–8.
- Wang HE, Donnelly JP, Barton D, Jarvis JL. Assessing advanced airway management performance in a national cohort of emergency medical services agencies. *Ann. Emerg. Med.* 2018; 71: 597, e593–607.
- Lockey D, Crewdson K, Weaver A, Davies G. Observational study of the success rates of intubation and failed intubation airway rescue techniques in 7256 attempted intubations of trauma patients by pre-hospital physicians. *Br J Anaesth.* 2014; 113: 220–5.
- King D, Ogilvie M, Michailidou M *et al.* Fifty-four emergent cricothyroidotomies: are surgeons reluctant teachers? *Scand. J. Surg.* 2012; 101: 13–5.
- Bair AE, Panacek EA, Wisner DH, Bales R, Sakles JC. Cricothyrotomy: a 5-year experience at one institution. *J. Emerg. Med.* 2003; 24: 151–6.
- Kyoto City Fire Department: Emergency statistics Available from: <https://www.city.kyoto.lg.jp/shobo/page/0000224446.html>.
- Guideline IHT. Clinical safety data management: definitions and standards for expedited reporting E2A. In: International Conference on Harmonisation of Technical Requirements for Registration of Pharmaceuticals for human use: 1994, 1994.
- Melchioris J, Todsén T, Konge L, Charabi B, von Buchwald C. Cricothyroidotomy - the emergency surgical airway. *Head Neck* 2016; 38: 1129–31.
- Boon JM, Abrahams PH, Meiring JH, Welch T. Cricothyroidotomy: a clinical anatomy review. *Clin. Anat.* 2004; 17: 478–86.
- Long N, Ng S, Donnelly G *et al.* Anatomical characterisation of the cricothyroid membrane in females of childbearing age using computed tomography. *Int. J. Obstet. Anesth.* 2014; 23: 29–34.