



Tattoo Granulomas With Uveitis

Journal of Investigative Medicine High
Impact Case Reports
Volume 8: 1–4
© 2020 American Federation for
Medical Research
DOI: 10.1177/2324709620975968
journals.sagepub.com/home/hic



Guiset Carvajal Bedoya, MD¹ , Liron Caplan, MD, PhD^{1,2},
Karen L. Christopher, MD¹, Amit K. Reddy, MD¹ ,
and Cristos Ifantides, MD^{1,3}

Abstract

Bilateral intraocular inflammation and simultaneous development of tattoo granulomas has been described in several case reports. The pathophysiology of this process is poorly understood, and it has been hypothesized that it could be a similar mechanism to systemic sarcoidosis versus a delayed hypersensitivity response. Granulomatous tattoo reaction with associated uveitis can manifest with or without evidence of systemic sarcoidosis, and it is usually responsive to immunosuppression and/or tattoo removal. We present a patient with no prior diagnosis of sarcoidosis who developed bilateral panuveitis and tattoo changes suggestive of tattoo granulomas with uveitis (TAGU). The patient was initially managed with intraocular steroids and systemic steroids with minimal improvement of symptoms. The patient later required steroid sparing therapy with a tumor factor inhibitor to achieve remission. There is a growing prevalence of tattooing among the general population and a low reported rate of tattooing complications. Granulomatous tattoo reaction with associated uveitis should be a consideration in patients with tattoos presenting with “idiopathic” uveitis.

Keywords

uveitis, granuloma, tumor necrosis factor- α , tattooing, panuveitis

Introduction

Surveys across multiple countries revealed that the prevalence of tattoos in the general population is approximately 24%. While tattoos are common, adverse reactions after tattooing are fairly infrequent, though these incidents are likely to be underreported.¹ Granulomatous tattoo reaction with associated uveitis represents one such rare adverse reaction. The overall prevalence of this complication is unknown. A recent review of the medical literature reported only 39 patients over a period of 66 years (1952–2018) suffered from granulomatous tattoo reaction with associated uveitis.² We report the case of a young adult who developed a granulomatous reaction after the application of a large tattoo.

Case Report

A 32-year-old Caucasian male presented to the Ophthalmology Service at the Rocky Mountain Regional Veterans Affairs Medical Center for evaluation of several months of bilateral eye redness and blurry vision. Review of systems was notable for simultaneous onset of diffuse erythema, tenderness, induration, and pruritus of a large black ink tattoo over the right arm and chest (Figure 1). This tattoo was inked 1 year prior to presentation. He had 2 other tattoos completed 10 years before, which were unaffected (Figure 2).

At the time of initial presentation, ophthalmological examination with slit lamp revealed anterior chamber inflammation and iris synechiae. On optical coherence tomography, there was evidence of macular edema (Figure 3). Skin examination was significant for inflammation, induration, and scant desquamation in a pattern that closely matched the borders of the tattoo. Lungs were clear to auscultation. The rest of the history and physical examination was unremarkable.

No clinical or serological evidence for other uveitis-associated diseases was elicited, including infections, sarcoidosis, or spondylarthritis. Comprehensive metabolic panel, complete blood count, urinalysis, thyroid stimulating hormone, free T4, ferritin, creatine phosphokinase, and aldolase tests were within normal limits. Erythrocyte sedimentation

¹University of Colorado, Denver, CO, USA

²Rocky Mountain Regional Veterans Affairs Medical Center, Denver, CO, USA

³Denver Health Medical Center, Denver, CO, USA

Received September 18, 2020. Revised October 26, 2020. Accepted October 31, 2020.

Corresponding Author:

Guiset Carvajal Bedoya, MD, University of Colorado School of Medicine, Barbara Davis Building—Rheumatology, 1775 Aurora Ct, B115, Aurora, CO 80045, USA.

Email: guiset.carvajalbedoya@cuanschutz.edu



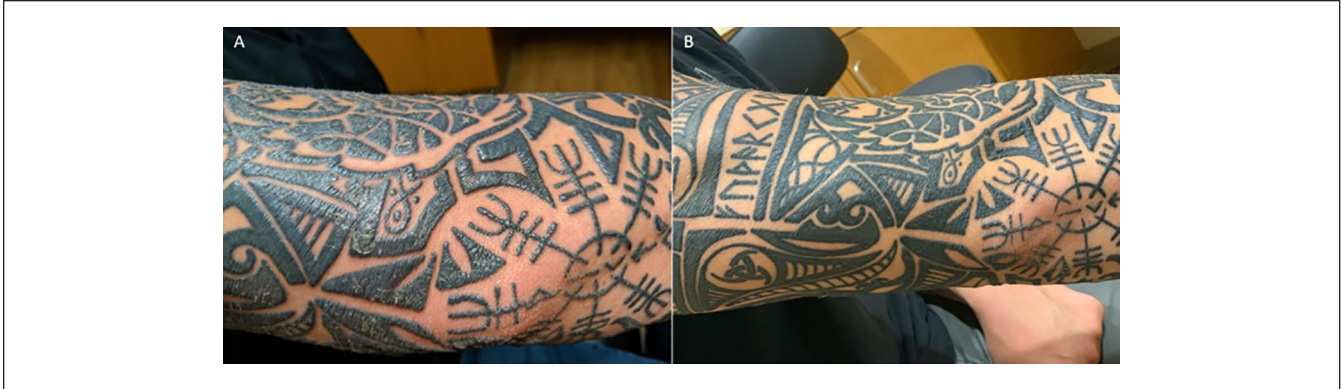

Figure 1. (A) Inflammation and induration of a large black ink tattoo over right arm and chest; tattoo was inked 1 year prior to presentation. (B) Resolution of inflammation after systemic steroid use.

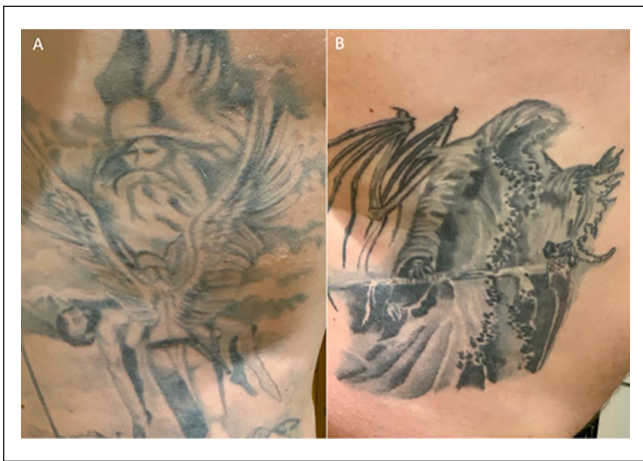

Figure 2. (A/B) Unaffected tattoos performed 10 years prior to presentation.

rate was 13 mm/h, and serum angiotensin-converting enzyme concentration was 86 U/L (14-82). C-reactive protein, HLA-B27, antinuclear antibody, antineutrophil cytoplasmic antibody (including cytoplasmic, perinuclear, and atypical ANCA), lysozyme, QuantiFERON, HIV, hepatitis B and C serologies, rheumatoid factor, anticyclic citrullinated peptide antibodies, and computed tomography of the chest were all within normal limits. Punch biopsies of the affected skin were obtained. Histological examination revealed granulomatous inflammation with associated tattoo ink deposition consistent with foreign body-type granulomatous reaction (Figure 4). Melan A immunostain highlighted scattered single junctional benign melanocytes with control samples staining appropriately.

The patient was initially treated with topical ocular glucocorticoids without significant improvement. He then required oral methylprednisolone 24 mg daily, tapered to 4 mg daily over 6 days. This agent led to rapid resolution of the inflammatory tattoo changes, but not of the macular and optic disc edema. A sub-tenon's triamcinolone injection to both eyes

resolved his ocular manifestation; however, tapering of his systemic glucocorticoids caused his tattoo manifestations to reappear. Adalimumab at 40 mg subcutaneously every other week satisfactorily terminated all of his symptoms. Unfortunately, after 3 months of therapy, patient developed an injection site reaction. Certolizumab 200 mg SQ every 2 weeks was instituted. A follow-up examination 4 months later revealed minimal, if any, subtle inflammation in both eyes, mild worsening of the macular edema in his left eye, and visual acuity of 20/20 by Snellen chart.

Discussion

Tattoo granulomas with uveitis is an exclusion diagnosis. Sarcoidosis should always be ruled out, even after histologic diagnosis. The histopathological diagnosis of sarcoidosis is challenging and drawing a definitive conclusion between sarcoidosis and foreign body reaction is not always possible. Granulomatous tattoo reaction with associated uveitis physiopathology is not well understood, but multiple hypotheses have been suggested. A delayed hypersensitivity reaction to ink given its toxic, mutagenic, and carcinogenic compounds has been proposed.³ This large antigenic load may trigger this condition in susceptible individuals.¹ A second hypothesis proposes a chronic mild antigenic stimulation from the tattoo ink leading to systemic granulomatous reaction consistent with sarcoidosis in susceptible individuals.⁴

Generally, all patients with TAGU undergo investigation for sarcoidosis. Patients found to have underlying sarcoidosis usually do not have pulmonary involvement, raising the question as to whether this represents a different subset of sarcoidosis with a specific environmental antigen exposure. Patients with TAGU occurring without concurrent sarcoidosis are usually younger, and more likely to have black ink used for tattooing. Uveitis occurs almost simultaneously with tattoo reaction, and symptoms present within the first year after tattooing.² TAGU is usually responsive to immunosuppression or tattoo removal.⁵

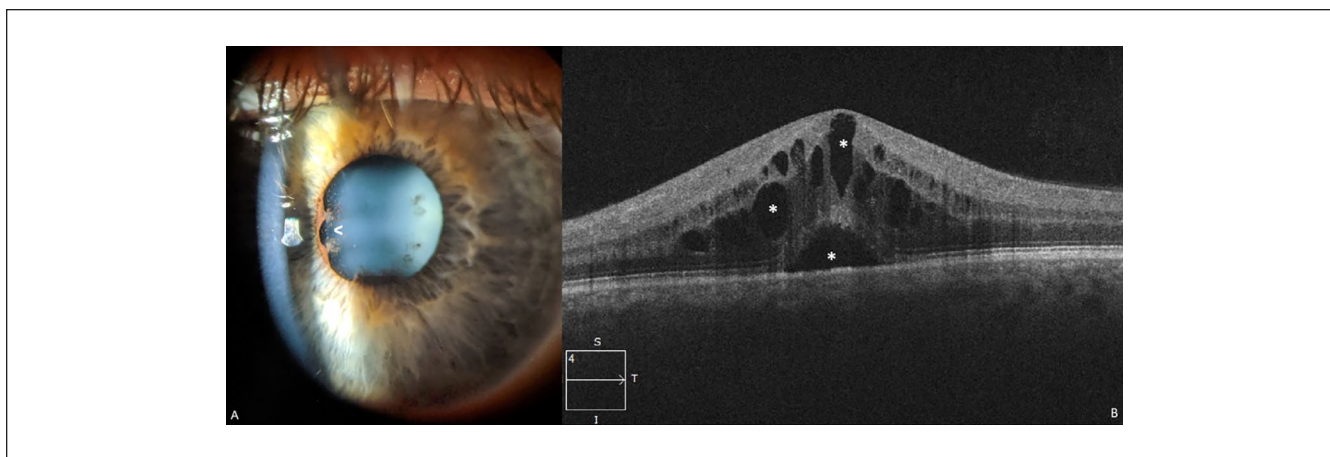


Figure 3. (A) Slit lamp examination of the left eye revealing iris synechia (head arrow). (B) Optical coherence tomography of the left eye macula showing macular edema (asterisks).

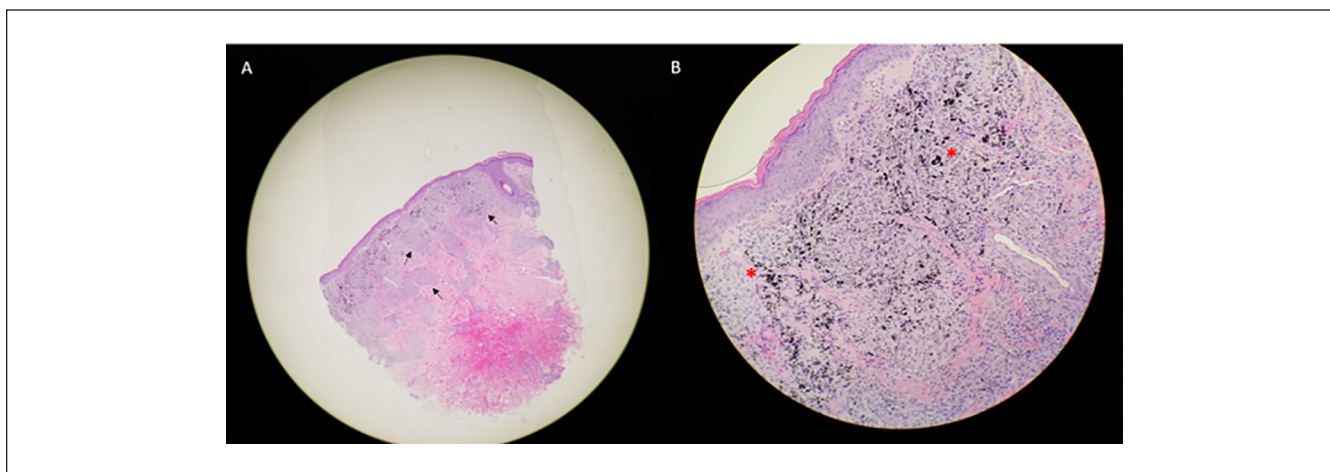


Figure 4. Histology from punch biopsies of the affected skin (hematoxylin and eosin stain at $\times 4$ [A] and $\times 20$ [B] power) showing evidence of granulomatous inflammation (arrows) with associated tattoo ink deposition (asterisks) consistent with foreign body-type granulomatous reaction.

This case resembles previous reports in that the patient presented with bilateral uveitis with simultaneous cutaneous and ocular manifestations. Also, his tattoo reaction occurred after using black ink. To the best of our knowledge, this is only the second reported case in which adalimumab was demonstrated to resolve the patient's signs and symptoms. Our patient also presented with panuveitis, which differs from previous reports in which anterior uveitis prevails.

Conclusion

Granulomatous tattoo reaction with associated uveitis is a rare clinical entity and likely to be underdiagnosed. It should be a consideration in all patients presenting with uveitis of undetermined cause. Patients should be screened for tattoos, and if present, the tattoos should be examined. Also, patients

with tattoo changes must be actively asked for ocular symptoms. With the increasing popularity of art tattooing or permanent makeup tattooing, more cases of TAGU would be expected.

Declaration of Conflicting Interests

The author(s) declared no potential conflicts of interest with respect to the research, authorship, and/or publication of this article.

Funding

The author(s) disclosed receipt of the following financial support for the research, authorship, and/or publication of this article: This work was supported in part by the Rocky Mountain Regional Veterans Affairs Medical Center. The sponsor was not involved in the design and conduct of the study; collection, management, analysis, and interpretation of data; preparation, review, or approval of

the manuscript; and the decision to submit the manuscript for publication.

Ethics Approval

Our institution does not require ethical approval for reporting individual cases or case series.

Informed Consent

Written informed consent was obtained from the patient(s) for their anonymized information to be published in this article.

ORCID iDs

Guiset Carvajal Bedoya  <https://orcid.org/0000-0002-3152-7855>

Amit K. Reddy  <https://orcid.org/0000-0002-5097-823X>

References

1. Wenzel S, Rittmann I, Landthaler M, Bäuml W. Adverse reactions after tattooing: review of the literature and comparison to results of a survey. *Dermatology*. 2013;226:138-147.
2. Kluger N. Tattoo-associated uveitis with or without systemic sarcoidosis: a comparative review of the literature. *J Eur Acad Dermatol Venereol*. 2018;32:1852-1861.
3. Rorsman H, Brehmer-Andersson E, Dahlquist I, et al. Tattoo granuloma and uveitis. *Lancet*. 1969;2:27-28.
4. Sepehri M, Hutton Carlsen K, Serup J. Papulo-nodular reactions in black tattoos as markers of sarcoidosis; study of 92 tattoo reactions from a hospital material. *Dermatology*. 2016;232:679-686.
5. Ostheimer TA, Burkholder BM, Leung TG, Butler NJ, Dunn JP, Thorne JE. Tattoo-associated uveitis. *Am J Ophthalmol*. 2014;158:637-643.e1.