

An Idea of Hemi-abdominal Free Flap for Breast Reconstruction: A Case Report

Yuki Tsuruta, MD
Hiroki Miyashita, MD
Yukiko Kuramoto, MD
Ryo Karakawa, MD
Nobuko Suesada, MD
Tomoyoshi Shibata, MD
Hidehiko Yoshimatsu, MD
Tomoyuki Yano, MD, PhD

Summary: A deep inferior epigastric perforator (DIEP) flap is one of the gold standards for autologous breast reconstructions. However, this flap cannot be chosen again if asynchronous contralateral breast cancer occurs in the future. To solve this problem, we propose an idea and design for a hemi-abdominal DIEP flap. The patient was a 50-year-old woman who was suffering from right invasive ductal carcinoma. In using a hemi-abdominal DIEP flap, the poor postoperative appearance of the donor site might be a problem. To obtain a good donor site shape, we use a specific design to make the appearance of the donor site as good as possible. Specifically, we make an oblique spindle-shaped flap that can cover the deep inferior epigastric perforators, the superficial circumflex iliac artery, and the superficial inferior epigastric artery and avoid dog-ears, without passing over the median line. The flap weight was 800g, the operating time was 6 hours and 22 minutes, and the bleeding amount was 110ml. The patient had a minor wound infection in the donor site, and it was treated with a local wound treatment. The patient is satisfied with the result. We believe our flap design could minimize the unfavorable appearance of the donor site. This method might be suited to cases where the patients present with excess skin and fat on the abdomen, and half the abdominal tissue is enough to create the necessary volume of the breast. Although more cases and studies will be required to justify our technique, this case may show the possibility of a new option for breast reconstructions. (*Plast Reconstr Surg Glob Open* 2020;8:e3168; doi: 10.1097/GOX.0000000000003168; Published online 27 October 2020.)

A deep inferior epigastric perforator (DIEP) flap is one of the gold standards for autologous breast reconstructions because it gives satisfactory outcomes to patients with a relatively little donor site morbidity.¹⁻⁴ However, one of its drawbacks is that it is supposed to be used only once in the patient's lifetime. In other words, a DIEP flap cannot be chosen again in the case of asynchronous contralateral breast cancer in the future.

To solve this problem, we propose the idea and design for a hemi-abdominal DIEP flap. In this article, we present our flap design, clinical experience, and indications for this technique.

PATIENT AND METHOD

At our institution, in the last 3 years, 286 patients underwent a unilateral breast reconstruction and 23

From the Department of Plastic and Reconstructive Surgery, Cancer Institute Hospital of Japanese Foundation for Cancer Research, Tokyo, Japan.

Received for publication June 3, 2020; accepted August 13, 2020.

Copyright © 2020 The Authors. Published by Wolters Kluwer Health, Inc. on behalf of The American Society of Plastic Surgeons. This is an open-access article distributed under the terms of the Creative Commons Attribution-Non Commercial-No Derivatives License 4.0 (CCBY-NC-ND), where it is permissible to download and share the work provided it is properly cited. The work cannot be changed in any way or used commercially without permission from the journal.

DOI: 10.1097/GOX.0000000000003168

patients underwent a simultaneous bilateral breast reconstruction. In these cases, 2 cases underwent autologous breast reconstruction for the asynchronous bilateral breast reconstruction.

In this case, the patient was a 50-year-old woman with the combination of right invasive ductal carcinoma, cTisN0M0, stage 0, and extensive ductal carcinoma in situ (DCIS). This patient underwent right breast mastectomy, and immediate subpectoral tissue expander placement. Thirteen months after the operation, she chose to undergo an autologous breast reconstruction. She preferred to use her abdominal tissue for the reconstruction because she complained that she had a lot of fat tissue on her abdomen. Her breast dimensions were: width of 150mm, projection of 68mm, and ptosis of 3cm. The patient was also concerned about future asynchronous contralateral breast cancer. Considering the patient's background and demands, a hemi-abdominal DIEP flap was planned for the surgery. Because she had a medical history of asthma, computed tomography angiography of the abdomen was not carried out before the operation.

CASE REPORT

The day before the operation, 70 MHz ultrasound was used⁵ to detect and observe the running pattern of the

Disclosure: The authors have no financial interest to declare in relation to the content of this article.

superficial circumflex iliac artery (SCIA),^{6,7} and the superficial inferior epigastric artery (SIEA).^{8,9} Then, Doppler flowmetry was used to identify the deep inferior epigastric perforators. The flap was designed to have an oblique elliptical shape with the size of $13 \times 20 \text{ cm}^2$, including these 2 vessels and DIEP perforators, ensuring enough volume for the planned breast reconstruction. This particular flap was designed on the one side of the abdomen. Finally, additional lines were marked to correct the dog-ear on each end of the design, but no part of the flap went over the mid-line (Figs. 1 and 2). The final flap size was $13 \times 28 \text{ cm}^2$.

During dissection, the SIEA and the deep and superficial branches of the SCIA were found, but they were too thin to harvest as a flap pedicle. Therefore, we harvested the hemi-abdominal DIEP flap as we had planned. Indocyanine green angiography showed that the right perforator was enough to allow perfusion of the contrast liquid to almost the entire area of the flap except for a small part of zone III. The flap weight was 800 g. The deep inferior epigastric artery and vein were anastomosed to the right internal mammary artery and vein at the fourth intercostal space. The operating time was 6 hours and 22 minutes, and the bleeding amount was 110 ml.

The patient had a minor wound infection in the donor site on the ninth day after surgery, and it was treated with a local wound treatment and antibiotics. She was discharged on the 15th day after the surgery.

There have been no signs of recurrence or distant metastasis for the past 2 months, and the patient is satisfied with the result (Fig. 3). The contralateral side of her abdomen still has adequate volume without any operation scar, which means a contralateral hemi-abdominal DIEP flap could be harvested from this patient in the future.

DISCUSSION

In 1989, when the first clinical use of a cutaneous-adipose flap from the lower abdomen with complete sparing

of the transverse rectus abdominis muscle was presented by Koshima and Soeda,¹⁰ the DIEP flap has been widely used in breast reconstruction. Compared with musculocutaneous flaps such as the free transverse rectus abdominis myocutaneous flap, this flap has advantages of decreasing the possibility of ventral hernia and muscle weakness.¹¹ However, a disadvantage of the DIEP flap is that it is supposed to be used only once for the same patient.

When a patient has asynchronous contralateral breast cancer, there are some options for autologous breast reconstruction such as: profunda artery perforator flaps,¹² latissimus dorsi flaps,¹³ superior gluteal artery perforator flaps,¹⁴ and lumbar artery perforator flaps.¹⁵ Colebunders et al¹⁶ reported the usage of a dog-ear flap supplied by perforators of the deep circumflex iliac artery for a patient who had a previous DIEP flap breast reconstruction. This flap could be a good alternative for a patient with asynchronous contralateral breast cancer, but Asian people do not have so much fat at the dog-ear site; so this technique has limited indications for Asian patients. The other option is to use stacked flaps. This method is useful for patients with a discrepancy between the amount of required tissue for adequate breast reconstruction and volume from a single donor site, but in this case, the volume of the tissue at only half abdominal was adequate.

In our case, the patient had several complaints concerning her breast: stiff shoulders caused by the weight of her breasts, and dermatitis in the inframammary folds caused by the ptosis of her breasts. Therefore, she wanted to make her breasts smaller and less ptotic than previously.

For the purpose of satisfying the patient's request to use the abdominal tissue to make a breast that was not so large, while preserving the tissue in case of contralateral breast cancer in the future, a hemi-abdominal DIEP flap was chosen. Although using a hemi-abdominal DIEP flap would allow for use of the other side in the future, the poor postoperative appearance of the donor site, such as asymmetry in the abdominal shape

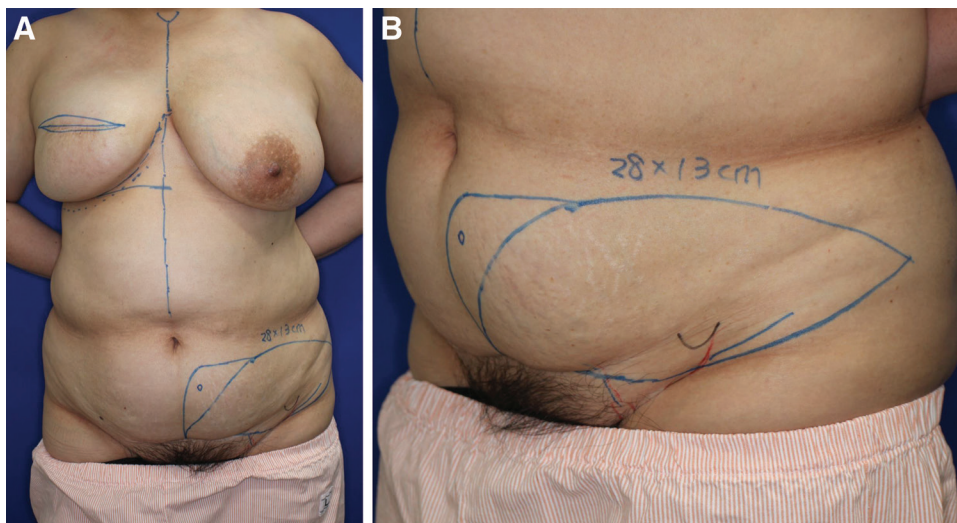


Fig. 1. Preoperative design. The hemi-abdominal DIEP flap with the size of $13 \times 28 \text{ cm}^2$. The blue circle in the middle shows the umbilicus, and the red line means the SCIA.

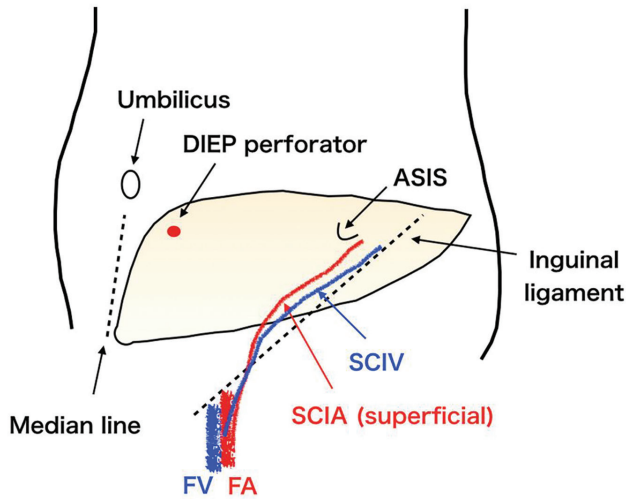


Fig. 2. The schema of the flap design. ASIS, anterior superior iliac spine; FA, femoral artery; FV, femoral vein; SCIA, superficial circumflex iliac artery; SCIV, superficial circumflex iliac vein.

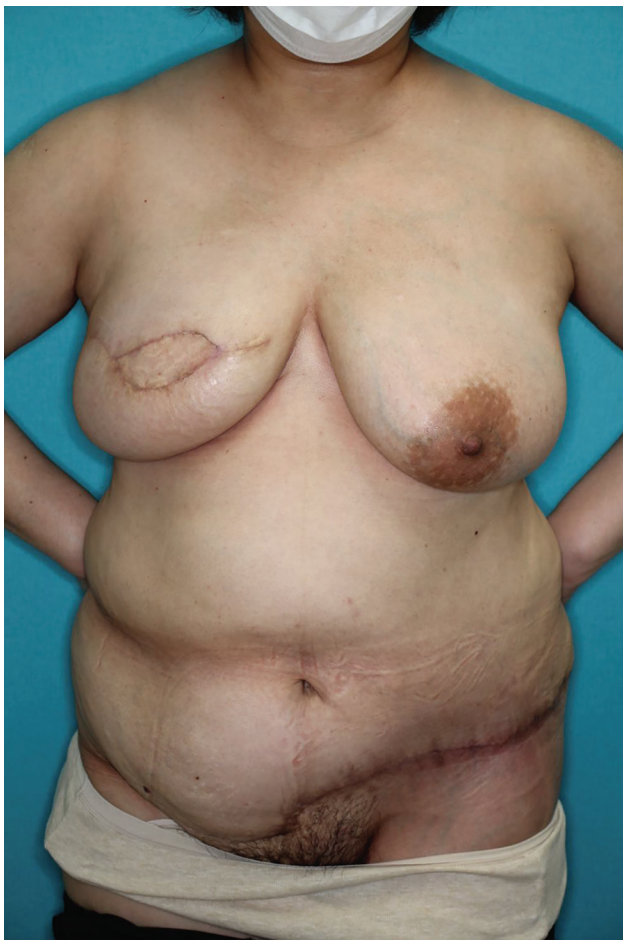

Fig. 3. Two months postoperative view of the patient after the surgery.

and deviation of the umbilicus, might be a problem. To obtain a good donor site shape, we use a specific design to make the appearance of donor site as good

as possible. Specifically, we make an oblique spindle-shaped flap that can cover the deep inferior epigastric perforators, SCIA, SIEA, and avoid dog-ears, without passing over the median line. We believe our flap design could minimize the unfavorable results on the donor site appearance.

In 2009, Shridharani et al¹⁷ reported the method of banking a hemi-abdominal DIEP flap, where they mentioned the utility of banking the contralateral hemi-abdominal DIEP flap under the abdominal closure in patients undergoing a unilateral autologous breast reconstruction. It means that the contralateral hemi-abdominal adipocutaneous flap is kept attached by all its major perforators after a microvascular transfer of the index hemi-abdominal flap, and the buried flap is used at reoperation. However, it was not for the asynchronous contralateral breast cancer in the future.

Not every patient is suited to this method. The necessary conditions for this method will be that the patient presents with excess skin and fat on the abdomen, and that half the abdominal tissue is enough to create the necessary volume of the breast. In some cases, the patient does not want the reconstructed breast to be of the same size as that of the other side; so the method should be chosen according to the patient's needs. Although more cases and studies will be required to justify our technique, this case may show the possibility of a new option for breast reconstruction.

Hiroki Miyashita, MD

Department of Plastic and Reconstructive Surgery
Cancer Institute Hospital of
Japanese Foundation for Cancer Research
3-8-31, Ariake, Koto-ku
Tokyo 135-8550, Japan
E-mail; hiroki.miyashita@jfcr.or.jp

REFERENCES

1. Erdmann-Sager J, Wilkins EG, Pusic AL, et al. Complications and patient-reported outcomes after abdominally based breast reconstruction: results of the Mastectomy Reconstruction Outcomes Consortium Study. *Plast Reconstr Surg.* 2018;141:271–281.
2. Futter CM, Webster MH, Hagen S, et al. A retrospective comparison of abdominal muscle strength following breast reconstruction with a free TRAM or DIEP flap. *Br J Plast Surg.* 2000;53:578–583.
3. Granzow JW, Levine JL, Chiu ES, et al. Breast reconstruction with the deep inferior epigastric perforator flap: history and an update on current technique. *J Plast Reconstr Aesthet Surg.* 2006;59:571–579.
4. Jessica ES, Edwin GW, Andrea LP, et al. Complications and patient-reported outcomes after abdominally based breast reconstruction: results of the Mastectomy Reconstruction Outcomes Consortium Study. *Plast Reconstr Surg.* 2018;141:271–281.
5. Tashiro K, Harima M, Kato M, et al. Preoperative color Doppler ultrasound assessment in planning of SCIP flaps. *J Plast Reconstr Aesthet Surg.* 2015;68:979–983.
6. Goh TL, Park SW, Cho JY, et al. The search for the ideal thin skin flap: superficial circumflex iliac artery perforator flap—a review of 210 cases. *Plast Reconstr Surg.* 2018;135:592–601.
7. Yoshimatsu H, Hayashi A, Karakawa R, et al. Combining the superficial circumflex iliac artery perforator flap with the superficial inferior epigastric artery flap or the deep inferior epigastric

- artery perforator flap for coverage of large soft tissue defects in the extremities and the trunk. *Microsurgery*. Published online June 15, 2020.
8. Chevray PM. Breast reconstruction with superficial inferior epigastric artery flaps: a prospective comparison with TRAM and DIEP flaps. *Plast Reconstr Surg*. 2004;114:1077–1083; discussion 1084.
 9. Yukihiro K, Yutaka F, Masaki A, et al. Anatomy of the arterial and venous systems of the superficial inferior epigastric artery flap: a retrospective study based on computed tomographic angiography. *J Plast Reconstr Aesthet Surg*. 2020;73:870–875.
 10. Koshima I, Soeda S. Inferior epigastric artery skin flaps without rectus abdominis muscle. *Br J Plast Surg*. 1989;42:645–648.
 11. Allen RJ, Treece P. Deep inferior epigastric perforator flap for breast reconstruction. *Ann Plast Surg*. 1994;32:32–38.
 12. Allen RJ Jr, Lee ZH, Mayo JL, et al. The profunda artery perforator flap experience for breast reconstruction. *Plast Reconstr Surg*. 2016;138:968–975.
 13. Sood R, Easow JM, Konopka G, et al. Latissimus dorsi flap in breast reconstruction. *Cancer Control*. 2018;25:1073274817744638.
 14. LoTempio MM, Allen RJ. Breast reconstruction with SGAP and IGAP flaps. *Plast Reconstr Surg*. 2010;126:393–401.
 15. de Weerd L, Elvenes OP, Strandenes E, et al. Autologous breast reconstruction with a free lumbar artery perforator flap. *Br J Plast Surg*. 2003;56:180–183.
 16. Colebunders B, Depypere B, Van Landuyt K. The dog-ear flap as an alternative for breast reconstruction in patients who have already undergone a DIEAP flap. *J Plast Reconstr Aesthet Surg*. 2016;69:594–597.
 17. Shridharani SM, Singh NK, Taylor JA, et al. Banking a hemi-abdominal DIEP flap: a pilot report of indications, technique, and utility. *Microsurgery*. 2009;29:265–269.