

Received: 2017.05.10
Accepted: 2017.07.21
Published: 2017.10.12

Bone Marrow Mononuclear Cells Transplantation in Treatment of Established Bronchopulmonary Dysplasia: A Case Report

Authors' Contribution:
Study Design A
Data Collection B
Statistical Analysis C
Data Interpretation D
Manuscript Preparation E
Literature Search F
Funds Collection G

ACDEF 1 **Nguyen Thanh Liem**
BCDEF 2 **Tran Lien Anh**
BCDE 2 **Trieu T. Hong Thai**
CD 1 **Bui Viet Anh**

1 Department of Stem Cell and Immune Cell, Vinmec Research Institute of Stem Cells and Gene Technology, Hanoi, Vietnam
2 Department of Neonatology, Vinmec International Hospital, Hanoi, Vietnam

Corresponding Author: Nguyen Thanh Liem, e-mail: v.liemnt-ceo@vinmec.com
Conflict of interest: None declared

Patient: Male, newborn
Final Diagnosis: Bronchopulmonary dysplasia
Symptoms: Difficult to breath • patient could not wean from oxygen/premature
Medication: —
Clinical Procedure: Bone marrow mononuclear cells transplantation
Specialty: Pulmonology

Objective: Management of emergency car

Background: Bronchopulmonary dysplasia (BDP) is an incurable disease. This study reports the successful treatment of a 30-week-old neonate with established bronchopulmonary dysplasia by bone marrow mononuclear cells (BM MNCs) transplantation.





Case Report: The preterm infant with BPD requiring continuous oxygen administration for 4 months post-delivery underwent BM MNCs. Bone marrow was obtained from the patient's iliac crests and mononuclear cells were isolated by density gradient centrifugation method. BM MNCs were delivered via endotracheal and intravenous routes. After BM MNCs transplantation, remarkable improvements were observed in oxygen saturation and lung CT as the infant was gradually weaned off oxygen supply.

Conclusions: BM MNCs transplantation offers promising treatment of BPD.

MeSH Keywords: Bone Marrow Cells • Bronchopulmonary Dysplasia • Stem Cell Transplantation

Abbreviations: BM MNCs – bone marrow mononuclear cells; BPD – bronchopulmonary dysplasia; MSCs – mesenchymal stem cells

Full-text PDF: <https://www.amjcaserep.com/abstract/index/idArt/905244>

 1401  —  4  13



Background

Bronchopulmonary dysplasia (BPD), first described by Northway in 1967, is becoming more common in newborns with low birth weight and those who receive prolonged mechanical ventilation [1,2]. Despite great advances in perinatal care, the prognosis of BPD is still poor [3,4]. To date, there are few effective treatments to improve outcomes of BPD. Recently, stem cell (STC) transplantation has been tested in the management of BPD in animals. In hyperoxia-induced mice, STC transplantation reduced alveolar loss and lung inflammation, and prevented pulmonary hypertension. STC transplantation has been reported to attenuate alveolar and vascular injury, and decrease fibrosis [5–10].

Before 2014, there was no evidence available for using STC transplantation to treat established BPD in humans. In 2014, Chang published a report of 9 infants at high risk of developing BPD who received stem cells to prevent BPD [11,12].

This case study reports a preterm infant with established BPD who was successfully treated by autologous bone marrow mononuclear cell transplantation.

Case Report

A boy was born at 30-week gestation by vaginal delivery with a birth weight of 1500 gr.

Respiratory distress syndrome occurred immediately post-delivery. A chest X-ray indicated grade 2 hyaline membrane disease. The patient was supported with nasal CPAP (pressure of 5 cm H₂O and 40% O₂) for 1 week, then oxygen was delivered via nasal cannulas for the next 28 days. Failure to improve respiratory function resulted in a transfer to the National Children's Hospital, where a diagnosis of BPD was made based on chest X-rays.

On admission at the National Children's Hospital (February 12, 2016), the body weight was 1600 gr and heart rate was 140–155 beats/min. Respiratory rate was 63 breaths/min; there was cyanosis and poor air entry to both lungs. SpO₂ was 80% without oxygen supply and 92% with oxygen supply at FiO₂ 24% through nasal cannulas. Arterial blood gas with FiO₂ of 24%: pH: 7.41; PaCO₂: 54 mmHg; Pa O₂: 51 mmHg; BE: 8.4; HCO₃⁻: 34.2; mmol/l. Chest X-rays showed fibrosis in both lungs (Figure 1).

The patient underwent 3 cycles of treatment including dexamethasone, furosemide, and bronchodilator, 10 days for each cycle and an interval of 7 days between 2 cycles. However, the patient's condition worsened, with hypercapnia and hypoxia

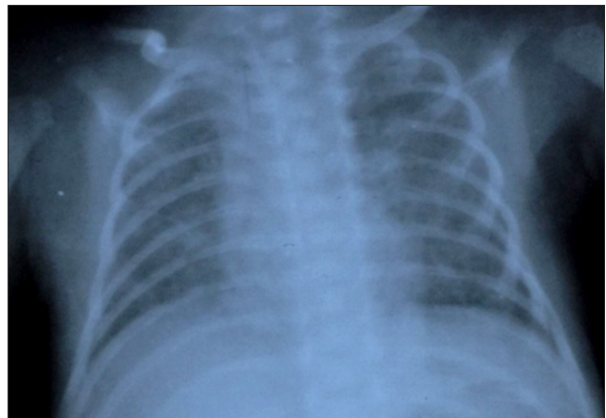


Figure 1. Chest X-ray at 35 days after delivery.

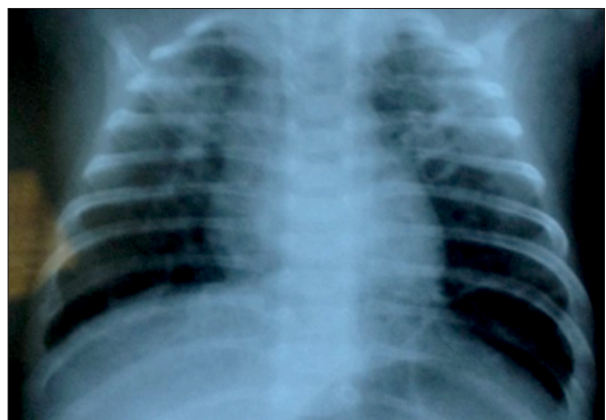

Figure 2. Chest X-ray after 3 cycles of treatment with Dexamethasone.

(pH: 7.37; PaCO₂: 54mmHg; PaO₂: 37 mmHg; HCO₃⁻: 31.2 mmol/l, BE: 4.9, FiO₂ of 24%). The chest X-ray revealed more diffused atelectasis and air trapping in both lungs (Figure 2).

After 88 days of treatment in the National Children's Hospital, the patient was transferred to Vinmec International Hospital for consideration of stem cell transplantation to improve his respiratory function.

On admission (May 11, 2016), body weight of the infant was 3.300 gr. He was alert and had good reflexes. Heart rate was 150–160 beats/min. Respiratory rate was 65–70 breaths/min. There was evidence of chest retraction and severe cyanosis. There was poor air entry to both lungs, and moist rales were recognized on auscultation. SpO₂ was 70% without oxygen supply and 92–95% with oxygen supply at FiO₂ of 24% by nasal cannula.

Investigations on admission

Arterial blood gases with the FiO₂ of 24%; pH 7.39, PaCO₂: 43.7 mmHg, PaO₂: 56 mmHg, BE: ±2, HCO₃⁻: 26.2, lactate: 1.99 mmol/l.

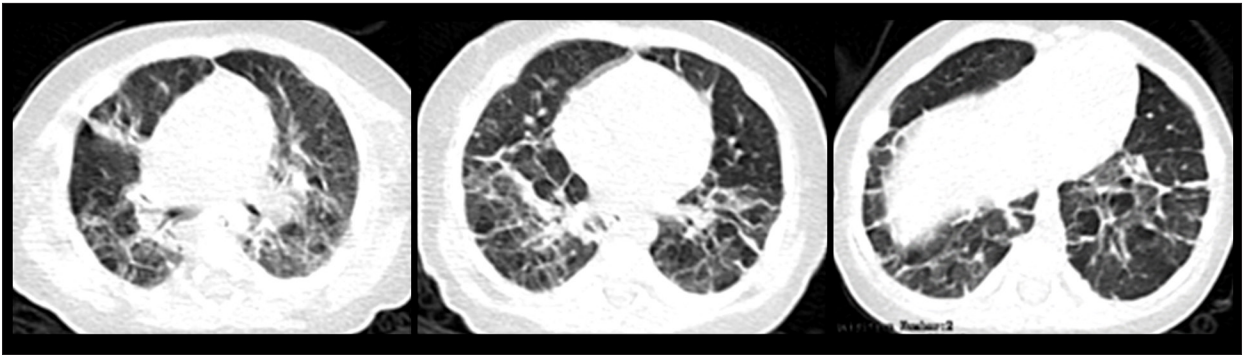

Figure 3. Chest CT before mononuclear cells transplantation.

Total blood cell count was WBC: 12 G/l; neutrophils: 12.3%; lymphocytes: 73.8% platelets: 344 G/l; and Hb: 10.1 g/dl.

On hospital day 4, a chest CT demonstrated diffuse fibrosis in both lungs, atelectasis in the upper lobes of both lungs, and significant air trapping in both lower lobes (Figure 3). BM MNC transplantation was indicated because, after long-term treatment, he could not be weaned from the oxygen supply after intensive treatment with corticosteroids.

After approval from the Hospital Scientific Committee and written informed consent from patient's parents, the infant underwent BM MNCs transplantation on hospital day 22, at 4000 gr weight. The patient was anesthetized and 32 ml of bone marrow was extracted from the iliac crests. Our previous experience showed that 8 ml of bone marrow per kg body weight can be harvested safely in children [13].

BM MNCs were extracted from 32 ml bone marrow by density gradient centrifugation using Ficoll-Paque (GE Healthcare, Sweden). The final product contained 620×10^6 of MNCs, which were supplemented by autologous plasma up to a total of 9 ml.

The BM MNCs were characterized by flow cytometry with monoclonal antibodies specific for CD45, and CD34, conjugated with R Phycoerythrin (PE) and fluorescein isothiocyanate (FITC), respectively (Beckman Coulter, CA, USA). Cells were analyzed by Navios Cytometer (Beckman Coulter, USA). The final product contained 43.85×10^6 of hHSC, which had CD45 dim CD34+ phenotype. Data were collected and recorded using Navios software, version 3.2.

A volume of 0.5 ml of the extracted liquid diluted with 0.5 ml NaCl 0.9% was instilled 4 times via the endotracheal tube every 30 min.

Results

Manifestations of tracheal obstruction occurred after the 2nd and the 4th injection with decreased SpO_2 , cyanosis, and bradycardia. These episodes required intratracheal suction, during which the patient was supported by mechanical ventilation.

On hospital day 23, 0.75 ml fluid of BM MNCs plus 0.75 ml NaCl 0.9% was infused through the endotracheal tube at 2 ml/h. The manifestations of tracheal obstruction reoccurred for 30 min after the infusion, requiring endotracheal suction. After 4 h, 1.25 ml of mononuclear cells diluted in 3 ml NaCl 0.9% was delivered via nebulization.

On hospital day 24 (June 3, 2016), pulmonary arterial hypertension was manifested by tachycardia, cyanosis, and arterial hypotension. Immediate treatment with high-frequency oscillator ventilation and medication (milrinone and Ilomedin) was applied.

On hospital day 31, the patient was stable with no sign of pulmonary artery hypertension. CMV mode was supported with PIP. 4.5 ml of mononuclear cell plus 5 ml NaCl 0.9% was delivered through a central venous catheter in 60 min.

On hospital day 32, the patient was weaned from the mechanical ventilator and was supported with oxygen by mask at 3 L/min for 1 week. Thereafter, intermittent oxygen supply was required via nasal cannulas at 0.3–0.5 L/min for 1.5 months and then oxygen supply was weaned completely. SpO_2 was at 94–100% without oxygen supply. The patient sucked well and gained weight.

On hospital day 41, the patient was discharged in stable condition.

Milestones and follow up:

- 2.5 months after discharge:
 - The child developed well, body weight was 5.500 gr, and respiratory rate was 45 breaths/min.

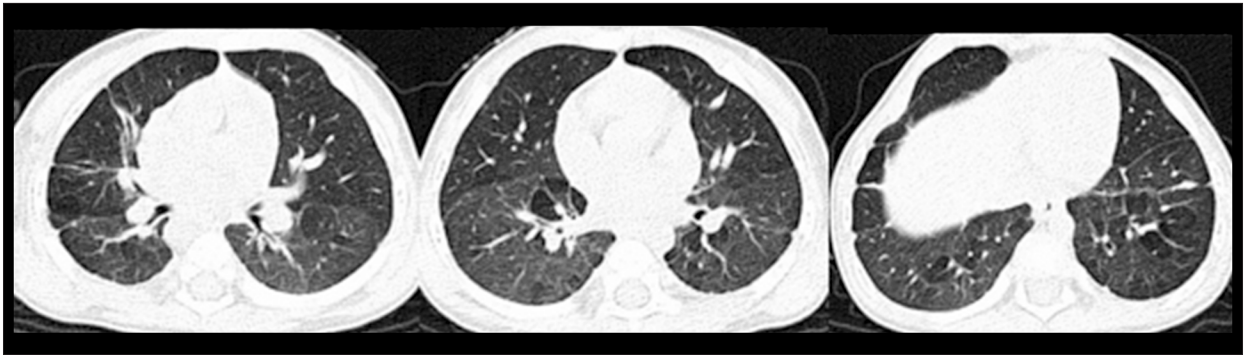

Figure 4. Chest CT after mononuclear cells transplantation.

- Arterial blood gas (FiO₂ of 21%): pH: 7.4; PaCO₂: 36.2 mmHg; PaO₂: 64 mmHg; BE: -2; HCO₃⁻: 22.4.
- SpO₂ ranged from 95–96% without oxygen support.
- 5 months after discharge:
 - Body weight was 6.400 gr.
 - SpO₂ was 96–98%.
- Arterial blood gas (FiO₂ of 21%): pH: 7.36; PaO₂: 71mmHg; PaCO₂: 40.7. mmHg; BE: -2; HCO₃⁻: 23 mmol/l).
- 10 months after discharge:
 - Body weight was 8 kg; height: 76 cm.
 - Respiratory rate was 35 breaths/min; good air entry to both lungs.
 - SpO₂ was 98–100%.
 - Arterial blood gas (FiO₂ of 21%): pH: 7.47, PaCO₂: 25.7mmHg, PaO₂: 80 mmHg, BE: -5, HCO₃⁻ 18.9 mmol/l.
- Chest X-ray (Figure 4) revealed that both lungs had mostly normal manifestations.

Discussion

This is the first trial using autologous BM MNCs to treat an infant with established BPD. Clinical and chest CT improvements were observed and demonstrated in our patient.

Over time, different sources of MNCs have been used to treat BPD in animals [5–10]. In humans, in 2014 and 2017, Chang et al. used cord blood mononuclear cell transplantation for preterm infants at risk of BPD, without severe adverse effects [11,12]. In this case, we demonstrated the use of autologous BM MNCs

References:

1. Stoll BJ, Hansen NI, Bell EF et al: Trends in care practices, morbidity, and mortality of extremely preterm neonates, 1993–2012. *JAMA*, 2015; 314(10): 1039–51
2. Northway WH Jr., Rosan RC, Porter DY: Pulmonary disease following respirator therapy of hyaline-membrane disease. Bronchopulmonary dysplasia. *N Engl J Med*, 1967; 276(7): 357–68
3. Jain D, Bancalari E: Bronchopulmonary dysplasia: Clinical perspective. *Birth Defects Res A Clin Mol Teratol*, 2014; 100(3): 134–44
4. Bhandari A, McGrath-Morrow S: Long-term pulmonary outcomes of patients with bronchopulmonary dysplasia. *Semin Perinatol*, 2013; 37(2): 132–37
5. Aslam M, Baveja R, Liang OD et al: Bone marrow stromal cells attenuate lung injury in a murine model of neonatal chronic lung disease. *Am J Respir Crit Care Med*, 2009; 180(11): 1122–30
6. Van Haften T, Byrne R, Bonnet S et al: Airway delivery of mesenchymal stem cells prevents arrested alveolar growth in neonatal lung injury in rats. *Am J Respir Crit Care Med*, 2009; 180(11): 1131–42

to treat established BPD. The extraction of bone marrow from the infant iliac was practical and suggests this is an alternative stem cell source when cord blood is not available.

The route of STC transplantation is still under consideration. Chang reported that intratracheal injection is safe in preterm infants [11]. However, in this case, intratracheal injection of STC resulted in bronchial obstruction and new-onset pulmonary arterial hypertension. These complications should be recognized early and managed expediently. As a result, the remaining MNCs were delivered intravenously. We conclude that the combined intratracheal and intravenous approach is a good alternative, depending on patient response.

Conclusions

The results of this study suggest that BM MNCs reduces lungs fibrosis and improves respiratory function of BPD. This approach offers promising treatment of BPD.

Conflict of interests

None.

Acknowledgements

The authors acknowledge Yvonne Osborne, PhD, Vinmec International Hospital, Vietnam for editing English for the manuscript.

7. Zhang H, Fang J, Su H et al: Bone marrow mesenchymal stem cells attenuate lung inflammation of hyperoxic newborn rats. *Pediatr Transplant*, 2012; 16(6): 589–98
8. Zhang X, Wang H, Shi Y et al: Role of bone marrow-derived mesenchymal stem cells in the prevention of hyperoxia-induced lung injury in newborn mice. *Cell Biol Int*, 2012; 36(6): 589–94
9. Chang YS, Oh W, Choi SJ et al: Human umbilical cord blood-derived mesenchymal stem cells attenuate hyperoxia-induced lung injury in neonatal rats. *Cell Transplant*, 2009; 18(8): 869–86
10. Sung DK, Chang YS, Ahn SY et al: Optimal route for human umbilical cord blood-derived mesenchymal stem cell transplantation to protect against neonatal hyperoxic lung injury: Gene expression profiles and histopathology. *PLoS One*, 2015; 10(8): e0135574
11. Chang YS, Ahn SY, Yoo HS et al: Mesenchymal stem cells for bronchopulmonary dysplasia: phase 1 dose-escalation clinical trial. *J Pediatr*, 2014; 164(5): 966–72
12. Ahn SY, Chang YS, Kim JH et al: Two-year follow-up outcomes of premature infants enrolled in the phase I trial of mesenchymal stem cells transplantation for bronchopulmonary dysplasia. *J Pediatr*, 2017; 185: 49–54.e2
13. Nguyen LT, Nguyen AT, Vu CD et al: Outcomes of autologous bone marrow mononuclear cells for cerebral palsy: An open label uncontrolled clinical trial. *BMC Pediatrics*, 2017; 17(1): 104