

Case Report



Delayed Massive Expansion of Subgaleal Hematoma Complicated with Proptosis in Hemophilia B

Seon-Yeop Kim ¹, Han Gyu Cha ², Sun Young Jang ³, and Sun-Chul Hwang ¹

¹Department of Neurosurgery, Soonchunhyang University Bucheon Hospital, Bucheon, Korea

²Department of Plastic Surgery, Soonchunhyang University Bucheon Hospital, Bucheon, Korea

³Department of Ophthalmology, Soonchunhyang University Bucheon Hospital, Bucheon, Korea

OPEN ACCESS

Received: Mar 4, 2021

Revised: May 26, 2021

Accepted: May 28, 2021

Address for correspondence:

Sun-Chul Hwang

Department of Neurosurgery, Soonchunhyang University Bucheon Hospital, 170 Jomaru-ro, Wonmi-gu, Bucheon 14584, Korea.
E-mail: sunchulh@schmc.ac.kr

Copyright © 2021 Korean Neurotraumatology Society

This is an Open Access article distributed under the terms of the Creative Commons Attribution Non-Commercial License (<https://creativecommons.org/licenses/by-nc/4.0/>) which permits unrestricted non-commercial use, distribution, and reproduction in any medium, provided the original work is properly cited.

ORCID iDs

Seon-Yeop Kim

<https://orcid.org/0000-0002-7498-188X>

Han Gyu Cha

<https://orcid.org/0000-0003-3059-1334>

Sun Young Jang

<https://orcid.org/0000-0002-4723-3712>

Sun-Chul Hwang

<https://orcid.org/0000-0001-8008-0749>

Conflict of Interest

The authors have no financial conflicts of interest.

ABSTRACT

Proptosis after a subgaleal hematoma (SGH) is a rare condition that may require immediate intervention to prevent visual loss. A 12-year-old boy presented with localized SGH in the left parietal area after hair-pulling. The SGH was massively expanded on the entire scalp on the 3rd day of the trauma. On the next day after the massive expansion, proptosis of the right eye occurred suddenly. Emergent needle aspiration of the SGH was performed, and the proptosis improved slightly. Fortunately, his vision did not deteriorate. After all, he was diagnosed with coagulation factor IX deficiency (hemophilia B). The supraorbital notch could be a passage of the SGH to extend into the subperiosteal space of the orbit.

Keywords: Subgaleal hematoma; Exophthalmos; Hemophilia B; Orbit

INTRODUCTION

The subgaleal space, which is between the galea aponeurotica and the pericranium, contains loose connective tissue and small emissary veins. Subgaleal hematomas (SGHs) result from the accumulation of blood in the subgaleal space after a minor head trauma; radial or tangential forces applied to the scalp during minor trauma can cause hemorrhage in the subgaleal space.^{5,19)} The hematoma is usually resolved without any intervention.

SGH can be expanded and rarely accompanied with an intraorbital hematoma (IOH).^{3,6,11,18)} Intra-orbital hematoma causes proptosis, diplopia, and vision loss. It can resolve spontaneously without any complications^{3,11)} or result in blindness.^{12,18)} We report a child with delayed massive SGH and subsequent IOH with proptosis after a trivial trauma, and discuss possible mechanisms.

CASE REPORT

A 12-year-old boy presented to the emergency department with headache and scalp swelling. His left parietal scalp had swelled immediately after his elder brother pulled his hair during

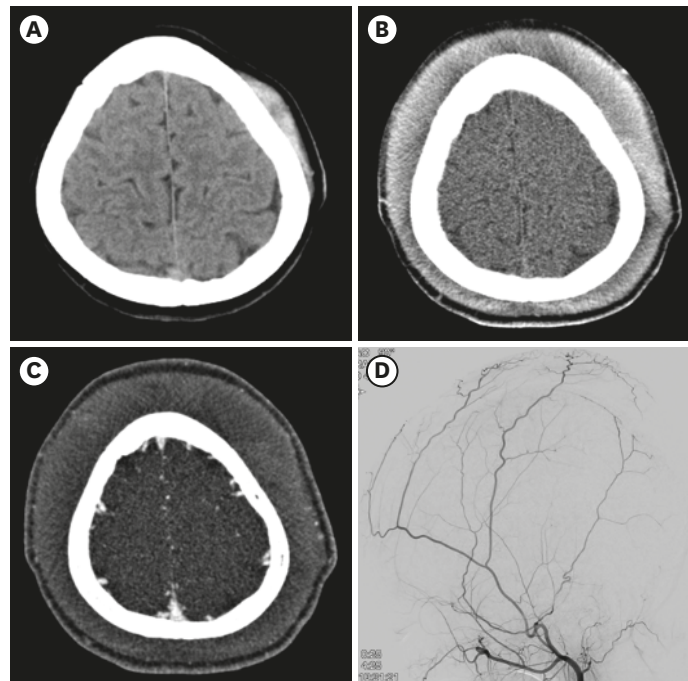


FIGURE 1. CT scans and external carotid angiogram of a 12-year-old boy. A localized SGH on the left parietal developed after hair pulling (A). In the 3rd day after the minor trauma, diffuse SGH suddenly developed (B). No leaks of the contrast dye are noted in the CT angiogram (C). In the external carotid angiogram, no vascular fistula or abnormality can be found (D).
CT: computed tomography, SGH: subgaleal hematoma.

a quarrel. He denied any direct impact on his scalp. No medical illness was found in the patient's personal history. Scalp swelling on the left parietal region was observed on brain computed tomography (CT) without any intracranial lesions (**FIGURE 1A**). He returned home without any medical intervention.

He visited the neurosurgery clinic 2 days after the trauma. The scalp swelling did not change, and his headache subsided. He did not have a history of easy bruising or bleeding. He and his mother were encouraged that the course of SGH would be benign and resolved spontaneously in a couple of weeks, and they returned home. He visited the emergency department again in the evening of the next day (trauma day 3). His scalp swelling expanded throughout the scalp (**FIGURE 1B**). The CT angiography on the head was taken for detecting any associated vascular abnormalities in the scalp. No pathological findings were revealed (**FIGURE 1C**). His mother denied any further trauma, known coagulopathy, or history of taking aspirin or other anticoagulants. The patient was transferred to the general ward. No further maneuvers, such as an elastic bandage, were applied.

In the next morning, he did not complain of aggravation of the scalp swelling or headache. Catheter cerebral angiography was performed, and no blood leakage was noted (**FIGURE 1D**). He suddenly complained of severe headache and right eye pain in the evening. Proptosis of the right eye was observed, and the eye did not close completely. He complained of blurred vision in the right eye and diplopia. It deviated downward and was limited for the upward gaze. His left eye was normal. There was no relative afferent pupil defect (RAPD) in either eye. Needle aspiration for the SGH from the frontal scalp (250 mL) and supraorbital region above the medial eyebrow (110 mL) was urgently performed. His proptosis improved slightly,

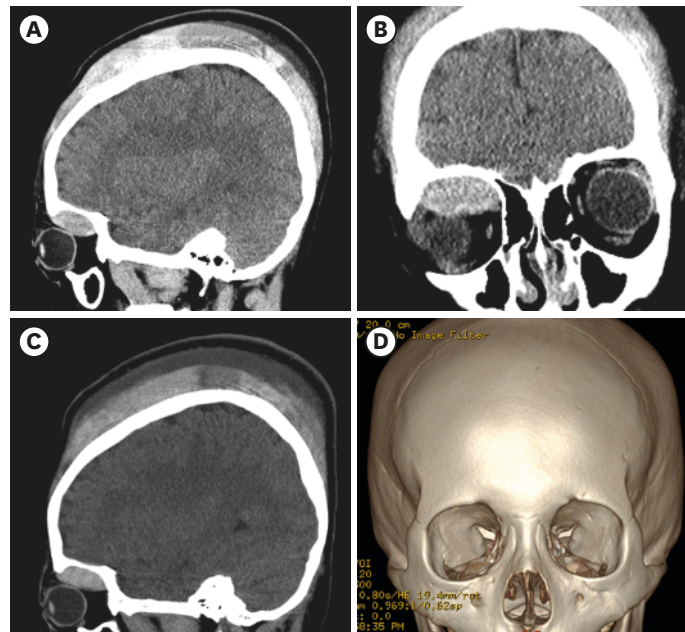


FIGURE 2. CT scans after the development of proptosis in the right eye. The CT scan was taken after an emergent needle aspiration on the forehead and a compressive bandage application. An IOH can be noted in the sagittal (A) and coronal (B) view. The hematoma was located in the superior medial aspect inside the right orbit and convex in shape. It happened in the subperiosteal space of the orbit. The relative less hematoma in the frontal area compared with the vertex may have resulted from hematoma aspiration and bandage compression (C). The IOH was not increased 3 days after the proptosis occurred. The 3-dimensional skull rendering image shows the larger supraorbital notch/foramen in the right orbit compared with the left (D).
CT: computed tomography, IOH: intraorbital hematoma.

and complete eye closure was achieved. An elastic bandage was wrapped around the head. An oval hematoma in the right superior orbit was found on the sagittal CT image (**FIGURE 2**).

In the laboratory test at admission, the blood hemoglobin was 14.0 gm/dL, hematocrit 40.3%, and platelet 289,000 /uL. The prothrombin time (PT_INR) was 1.02, and activated partial thromboplastin time was mildly prolonged at 57.6 seconds (27.7–44.2 seconds). Laboratory workups for coagulation abnormalities were also performed. And then, 10 mg of vitamin K was injected intramuscularly, and 2 pints of fresh frozen plasma were transfused. The blood hemoglobin level decreased to 12.0 mg/dL 1 day after the aspiration.

The aPPT was corrected to 43.8 seconds in the plasma mixing test. This meant that the deficiency of coagulation factors existed. For the coagulation factor assay, factor IX was 7% (60–140), and factor VIII was 51% (60–140). A marked deficiency of factor IX was revealed, and hemophilia B was diagnosed. His eye was protected with an ointment and an artificial tear. The intraocular pressure of the right eye was 13 mmHg, and proptosis was 7 mm compared to the left eye on exophthalmometry. His mother informed us that his male cousin on the mother's side was recently diagnosed with hemophilia. The cousin was not receiving any special medical treatment until now. A total of 850 mL of hematoma was aspirated during the following 3 days, and the blood hemoglobin dropped to 10.2 gm/dL. The boy was transferred to a specialized center for pediatric hematologic diseases after hemophilia was confirmed in the laboratory test. He underwent surgical evacuation for IOH at another hospital. The patient recovered completely from SGH and IOH without any complications.

DISCUSSION

SGHs result from accumulation of blood in the subgaleal space and usually occur in children. The diagnosis is generally made clinically, with a fluctuating mass developing gradually over the scalp after head trauma. Cases of SGH secondary vigorous hair bombing and braiding,^{9,13)} hair pulling,^{4,12,19)} and child abuse¹⁵⁾ have been reported. It is spontaneously resolved in most cases, even though it sometimes expands during resolution. It is rarely complicated with IOH^{3,6,11,18)} or airway obstruction.⁸⁾ When an unusual clinical profile is present, coagulation disorders should be evaluated.^{2,4,10)}

IOHs following SGH cause proptosis, diplopia, and vision loss. Vision loss may be followed by corneal erosion due to incomplete eye closure¹⁰⁾ or orbital compartment syndrome.²⁾ Orbital compartment syndrome is a potentially blinding condition characterized by a rapid increase in intraorbital pressure.⁷⁾ It is most commonly seen in the context of intraorbital hemorrhage secondary to trauma or surgery. Emergency lateral canthotomy should be performed to improve visual outcomes. In our case, we did not attempt emergency surgery because the intraocular pressure of his right eye was stable and the RAPD test was negative. Moreover, the coagulation disorder was not clearly diagnosed before IOH occurred.

The mechanism of intraorbital involvement of the SGH has not been clearly established.^{4,6)} The galea aponeurotica is a dense fibrotic band attached in the interval between the frontalis and occipitalis muscles. The frontalis is continuous with facial muscles including the procerus and orbicularis oculi without any bony attachment.¹⁴⁾ Hence, bleeding in the subgaleal space tracks down beneath the frontalis muscle, accumulates between the orbicularis oculi and the orbital septum, and produces ubiquitous periorbital hematoma or “black eye.”¹⁴⁾ To explain the intraorbital involvement from the SGH, the other passage should be considered. The pressure of accumulated hemorrhage in the subgaleal space may push the attachments of the arcus marginalis to the orbital rim and extend subperiosteally.¹²⁾ The potential gap between the orbital septa and the lateral horn of the levator palpebral aponeurosis could permit orbital extension of the SGH.⁶⁾ However, if this extension occurs, the hematoma will be located in the periocular and not in the subperiosteal area because the orbital septum attaches to the periosteum on the orbital rim. The area posterior to the orbital septum is filled with orbital contents, including eyeball, fat, and muscles; it is difficult to accumulate isolated hematomas.

The other passage should be involved in the development of subperiosteal IOH following SGH. We believe that the supraorbital notch may be a possible route. The supraorbital nerve exits the orbit through the supraorbital notch or foramen and penetrates the frontalis muscle for sensory innervation in the forehead. It remains in the subgaleal plane until the penetration of the frontalis and the corrugator muscles.¹⁾ Therefore, the hemorrhage in the subgaleal space may follow the pathway of the supraorbital nerve and accumulate around the supraorbital notch or foramen, which runs through it and becomes an IOH. According to an anatomical study, the supraorbital notch has a relatively larger diameter (3.8–3.9 mm) compared to the foramen (2.3 mm), and more than 5 times of people have a notch rather than a foramen.¹⁷⁾ However, the supraorbital foramen has a tight bony passage where gaps hardly exist for blood to permeate. The appearance of IOH on CT or magnetic resonance image from previous reports also shows accumulation of blood mainly in the superior and medial side of the orbit.²⁾ When neurosurgeons perform the subperiosteal dissection to expose the orbital rim, the bare supraorbital nerve, which is not located underneath

the pericranium or the periorbita around the supraorbital notch/foramen, is frequently noted. This void of periosteal tissue plays the role of connecting from the subgaleal space to the subperiosteal area in the orbit. Thus, the supraorbital notch would be the route for IOH following SGH (**FIGURE 3**). In addition, the wide supraorbital notch of the right side compared to the left in our case provides additional evidence for this passage (**FIGURE 2D**). In addition, the loose adhesion of the periosteum to the skull in the childhood would be one potential factor for the hematoma extension.

The drainage or evacuation of SGH depends on the patient's symptoms. Asymptomatic SGHs restricted to the scalp may not be evacuated. Minimal needle drainage would be better if hematoma reduction is required.¹⁶⁾ Elastic bandage around the scalp may increase the risk of IOH.⁶⁾ The SGHs complicated with proptosis should be managed on the basis of vision and intraocular pressure. Needle aspiration from SGH may reduce IOH and help relieve proptosis in an urgent situation. After reducing SGH on the forehead, an elastic bandage may help prevent more extension of the IOH. This was also noted in the present case.

In addition to symptomatic control of the hematoma, bleeding disorders should always be considered in delayed massive SGHs. The hematologic evaluation should include a complete blood count, prothrombin time, and partial thromboplastin time.¹³⁾ Most common congenital bleeding disorders include von Willebrand disease, hemophilia A (factor VIII deficiency), and hemophilia B (factor IX deficiency). Coagulation factor deficiency was diagnosed based on the factor level, the mixing study, and a Bethesda assay (to quantify the factor inhibitors).²⁰⁾ In our patient, mild prolongation of the PTT was found, whereas the PT was normal. Factor IX was very low (7, normal=60%–140%), and the PTT was normalized in the mixing study. Factor IX deficiency (hemophilia B) occurs in 1:30,000 male births and is an X-linked recessive trait. Even though mild prolongation of the PTT is noted, as in our case, further study of a coagulation disorder should be considered.

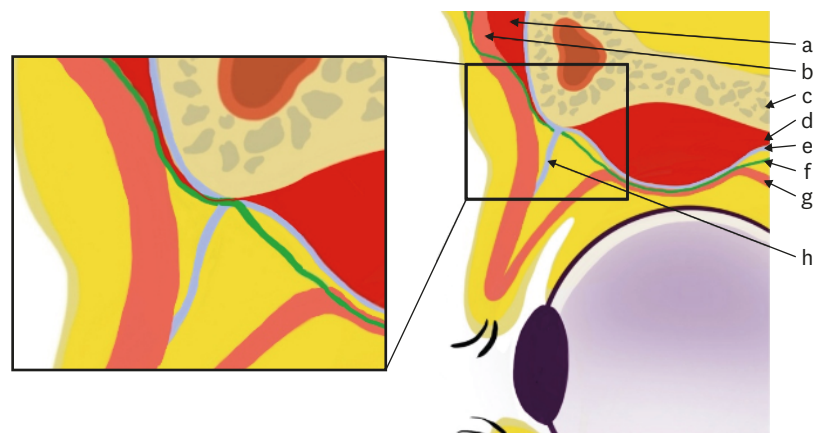


FIGURE 3. Anatomic illustration of IOH development from SGH. The SGH and IOH are located in different plane. To develop IOH from SGH, anatomic passage of the hematoma should be required. The anatomic variation around the supraorbital notch may be a possible route. The supraorbital nerve exits the orbit through the supraorbital notch and remains in the subgaleal plane until the penetration of the frontalis and the corrugator muscles. The loose connection or dehiscence of supraorbital nerve and periosteum around the supraorbital notch may be a possible route of the hematoma egress. (a) SGH, (b) frontalis muscle, (c) skull, (d) IOH, (e) periosteum, (f) supraorbital nerve, (g) levator palpebrae superioris muscle, (h) orbital septum. IOH: intraorbital hematoma, SGH: subgaleal hematoma.

CONCLUSION

The supraorbital notch may be a possible passage in cases of orbital involvement of the SGH. Immediate needle aspiration near the medial eyebrow should be considered to lower intraocular pressure in such conditions. Coagulation deficiency should also be investigated in the unusual delayed massive expansion of SGH.

REFERENCES

- Christensen KN, Lachman N, Pawlina W, Baum CL. Cutaneous depth of the supraorbital nerve: a cadaveric anatomic study with clinical applications to dermatology. *Dermatol Surg* 40:1342-1348, 2014
[PUBMED](#) | [CROSSREF](#)
- Jenkins TL, Zheng CX, Murchison AP, Bilyk JR. Orbital compartment syndrome following post-traumatic subgaleal hematoma. *Ophthal Plast Reconstr Surg* 33:e33-e36, 2017
[PUBMED](#) | [CROSSREF](#)
- Jeong BH, Moon JG, Kim CH, Lee HK, Hwang DY. Subperiosteal orbital extension of subgaleal hematoma: a case report. *J Korean Neurosurg Soc* 29:1255-1257, 2000
- Kim D, Taragin B. Subgaleal hematoma presenting as a manifestation of Factor XIII deficiency. *Pediatr Radiol* 39:622-624, 2009
[PUBMED](#) | [CROSSREF](#)
- Kuban K, Winston K, Bresnan M. Childhood subgaleal hematoma following minor head trauma. *Am J Dis Child* 137:637-640, 1983
[PUBMED](#) | [CROSSREF](#)
- Lee KS, Bae HG, Yun IG. Bilateral proptosis from a subgaleal hematoma. Case report. *J Neurosurg* 69:770-771, 1988
[PUBMED](#) | [CROSSREF](#)
- McCallum E, Keren S, Lapira M, Norris JH. Orbital compartment syndrome: an update with review of the literature. *Clin Ophthalmol* 13:2189-2194, 2019
[PUBMED](#) | [CROSSREF](#)
- Nichter LS, Bolton LL, Reinisch JF, Sloan GM. Massive subgaleal hematoma resulting in skin compromise and airway obstruction. *J Trauma* 28:1681-1683, 1988
[PUBMED](#) | [CROSSREF](#)
- Onyeama CO, Lotke M, Edelman B. Subgaleal hematoma secondary to hair braiding in a 31-month-old child. *Pediatr Emerg Care* 25:40-41, 2009
[PUBMED](#) | [CROSSREF](#)
- Pomeranz AJ, Ruttum MS, Harris GJ. Subgaleal hematoma with delayed proptosis and corneal ulceration. *Ann Emerg Med* 26:752-754, 1995
[PUBMED](#) | [CROSSREF](#)
- Pope-Pegram LD, Hamill MB. Post-traumatic subgaleal hematoma with subperiosteal orbital extension. *Surv Ophthalmol* 30:258-262, 1986
[PUBMED](#) | [CROSSREF](#)
- Puri S, Duff SM, Mueller B, Prendes M, Clark J. Hairpulling causing vision loss: a case report. *Orbit* 38:162-165, 2019
[PUBMED](#) | [CROSSREF](#)
- Raffini L, Tsarouhas N. Subgaleal hematoma from hair braiding leads to the diagnosis of von Willebrand disease. *Pediatr Emerg Care* 20:316-318, 2004
[PUBMED](#) | [CROSSREF](#)
- Seery GE. Surgical anatomy of the scalp. *Dermatol Surg* 28:581-587, 2002
[PUBMED](#) | [CROSSREF](#)
- Shamji S, Jacoby JL. Massive subgaleal hematoma and clinical suspicion of child abuse. *J Am Osteopath Assoc* 115:58, 2015
[PUBMED](#) | [CROSSREF](#)
- Suh DS, Kim BT, Cho SJ, Shin WH, Choi SK, Byun BJ. Using blood donating set for the treatment of subgaleal hematoma: technical note. *J Korean Neurosurg Soc* 29:1519-1522, 2000

17. Turhan-Haktanir N, Ayçiçek A, Haktanir A, Demir Y. Variations of supraorbital foramina in living subjects evaluated with multidetector computed tomography. *Head Neck* 30:1211-1215, 2008
[PUBMED](#) | [CROSSREF](#)
18. Wolter JR, Vanderveen GJ, Wacksman RL. Posttraumatic subgaleal hematoma extending into the orbit as a cause of permanent blindness. *J Pediatr Ophthalmol Strabismus* 15:151-153, 1978
[PUBMED](#) | [CROSSREF](#)
19. Yip CC, McCulley TJ, Kersten RC, Kulwin DR. Proptosis after hair pulling. *Ophthal Plast Reconstr Surg* 19:154-155, 2003
[PUBMED](#) | [CROSSREF](#)
20. Zimmerman B, Valentino LA. Hemophilia: in review. *Pediatr Rev* 34:289-294, 2013
[PUBMED](#) | [CROSSREF](#)