

Available online at www.sciencedirect.com

ScienceDirect

journal homepage: www.elsevier.com/locate/radcr

Case Report

Diagnosis of an unusual case of idiopathic mediastinal fibrosis by ^{18}F -FDG PET/CT

Roberto G. Carbone, MD^a, Giuseppe Murdaca, MD, PhD^a, Simone Negrini, MD, PhD^a, Daniele Penna, MD^b, Francesco Puppo, MD^{a,*}

^aDepartment on Internal Medicine, University of Genoa, Genoa, Italy

^bAffidea IRMET, Turin, Italy

ARTICLE INFO

Article history:

Received 4 November 2019

Revised 15 January 2020

Accepted 18 January 2020

Keywords:

Positron-emission tomography/computed tomography (PET/CT)
Idiopathic mediastinal fibrosis

ABSTRACT

Diagnosis of idiopathic mediastinal fibrosis was done by exclusion in a 54-year-old woman with dyspnoea, chest pain, cough and fatigue showing positivity of 2-deoxy-2- ^{18}F fluoro-D-glucose positron-emission tomography/computed tomography total body imaging which turned out to normal after six and eighteen months of prednisone and pirfermidone treatment.

© 2020 The Authors. Published by Elsevier Inc. on behalf of University of Washington.

This is an open access article under the CC BY-NC-ND license.

(<http://creativecommons.org/licenses/by-nc-nd/4.0/>)

Introduction

Idiopathic mediastinal fibrosis (IMF) is a rare disease, characterized by abnormal proliferation of inflammatory and fibrous tissue within the mediastinum, usually affecting young patients with signs and symptoms of obstruction of the superior vena cava, pulmonary veins or arteries, central airways, or esophagus. IMF may be focal or diffuse, typically manifesting on computed tomographic (CT) and magnetic resonance (MR) images as a calcified or as a diffusely infiltrating mediastinal mass, respectively [1].

Case presentation

We report a 54-year-old woman admitted with dyspnoea, chest pain, cough, and fatigue with chest x-rays showing a mediastinal and hilar right lung region mass. Tuberculosis, histoplasmosis and fungal infection, as well as drug induced reaction and autoimmunity were all excluded. 2-deoxy-2- ^{18}F fluoro-D-glucose positron-emission tomography/computed tomography (^{18}F -FDG-PET/CT) total body imaging [2] revealed hypermetabolic activity within the mediastinum (Fig. 1A) suggesting, by exclusion [1,3], the diagnosis

* Corresponding author.

E-mail address: puppof@unige.it (F. Puppo).

<https://doi.org/10.1016/j.radcr.2020.01.022>

1930-0433/© 2020 The Authors. Published by Elsevier Inc. on behalf of University of Washington. This is an open access article under the CC BY-NC-ND license. (<http://creativecommons.org/licenses/by-nc-nd/4.0/>)

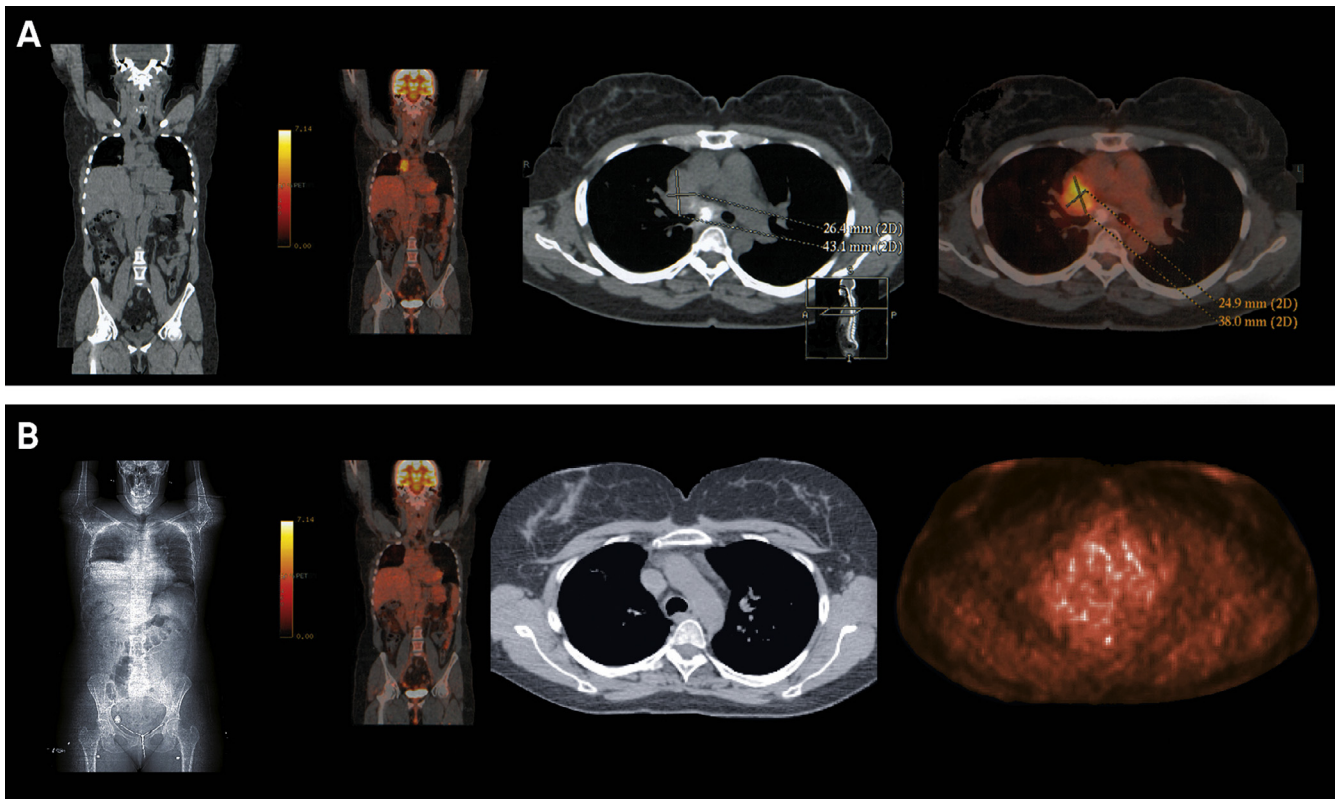


Fig. 1 – (A) ^{18}F -FDG-PET/CT (axial and MIP images) shows abnormal uptake of radiotracer in a region of interest (ROI) for maximum standardized uptake value (SUV_{max}) 2.01 at the level of mediastinum and hilar right lung region. **(B)** Normal ^{18}F -FDG-PET/CT after 18 months of treatment.

of IMF without involvement of the superior vena cava [4]. Patient was treated with prednisone for 1 month (70 mg daily tapered over six months to 10 mg daily) then, due to persistent chest pain and fatigue, pirfenidone 2403 mg daily was added. After 18 months, patient reported total resolution of symptoms and a ^{18}F -FDG-PET/CT scan was normal (Fig. 1 B).

Discussion

^{18}F -FDG-PET/CT is a noninvasive diagnostic imaging test widely used in oncology and based on the distribution of the radiotracer dependent on cellular glucose metabolism. The assumption of this tool is based in the greater avidity of glucose by the cancer cells compared to the surrounding healthy tissues. However, many infection / inflammation sites were identified by FDG-PET during routine ^{18}F -FDG imaging of cancer patients. Indeed, further studies have shown that also the cells involved in these processes (neutrophils and monocytes/macrophages) are avid of glucose expressing high levels of GLUT1 and GLUT3 transporters and exocinase activity. In 2013 the American and European Nuclear Medicine societies (SNMMI/EANM) produced the first guidelines for the potential use of FDG-PET in inflammatory and infectious diseases [5,6]. Since then many others articles are adding evidence of numerous nononcological pathologies identifiable by this thec-

nique and difficult to study with the traditional diagnostic procedures. In this report ^{18}F -FDG-PET/CT imaging seems to be an accurate tool for the diagnosis of IMF and is useful for evaluating and monitoring the metabolic activity of the mediastinal mass.

REFERENCES

- [1] Rossi SE, McAdams HP, Rosado de Christenson ML, Franks TJ, Galvin JR. Fibrosing mediastinitis. *RadioGraphics* 2001;21:737–57.
- [2] Flechsig P, Hural O, Kreuter K, et al. Impact of FDG-PET on the detection of patients with lung cancer at high risk for ILD. *In Vivo* 2018;32:1457–62.
- [3] Devaraj A, Griffin N, Nicholson AG, Padley SPG. Computed tomography findings in fibrosing mediastinitis. *Clin Radiol* 2007;62:781–6.
- [4] Novella Sánchez L, Sanz Herrero F, Berraondo Fraile J, Fernández Fabrellas E. Mediastinal fibrosis and superior vena cava syndrome. *Arch Broncopneumol* 2013;49:340–2.
- [5] Jamar F, Buscombe J, Chiti A, Christian PE, Delbeke D, Donohoe KJ, et al. EANM/SNMMI guideline for ^{18}F -FDG use in inflammation and infection. *J Nucl Med* 2013 Apr;54:647–58.
- [6] Fernández-López R, Lojo JA, Acevedo-Báñez I, González-León R, Borrego-Dorado I. ^{18}F -FDG PET/CT in patients with idiopathic retroperitoneal and mediastinal fibrosis. *Eur J Nucl Med Mol Imaging* 2016;43:1739–40.