

# Unusual Presentation of Gallbladder Fossa Abscess Following Open Cholecystectomy in a Patient With Cholecystitis: A Case Report

Review began 05/15/2022  
Review ended 05/22/2022  
Published 05/24/2022

© Copyright 2022

Vyas et al. This is an open access article distributed under the terms of the Creative Commons Attribution License CC-BY 4.0., which permits unrestricted use, distribution, and reproduction in any medium, provided the original author and source are credited.

Hirva Vyas <sup>1</sup>, Ethan Burg <sup>2</sup>, Ramtin Moradi <sup>5</sup>, Alan Chu <sup>1</sup>, Davood K. Hosseini <sup>1</sup>

1. Internal Medicine, Hackensack University Medical Center, Hackensack, USA 2. Medicine, Hackensack Meridian School of Medicine, Hackensack, USA 3. Internal Medicine, Richmond University Medical Center, Staten Island, USA

**Corresponding author:** Davood K. Hosseini, davood.karimihosseini@hmn.org

---

---

## Abstract

Cholecystectomy is one of the most commonly performed surgical interventions, and laparoscopic cholecystectomy is the standard intervention with open cholecystectomies having declined nowadays. Similar to other surgical procedures, cholecystectomy carries its own risks including sepsis, bleeding, damage to surrounding tissues, bile leakage, and abscess formation. Abscess formation can be due to a variety of reasons such as infection or gallstone spillage during surgery with the latter being more common to laparoscopic surgery. Here we describe a patient with an unusual presentation of gallbladder fossa abscess following open cholecystectomy.

---

**Categories:** Internal Medicine, Gastroenterology, Infectious Disease

**Keywords:** chronic cholecystitis, ct scan, cholecystitis, cholecystectomy, gallbladder fossa abscess

## Introduction

Acute cholecystitis is the inflammation of the gallbladder, which occurs due to obstruction of the cystic duct, resulting in bile stasis, and subsequently inflammation and edema of the gallbladder wall. Cholelithiasis is the most common cause of cystic duct obstruction, and accounts for 95% of acute cholecystitis [1].

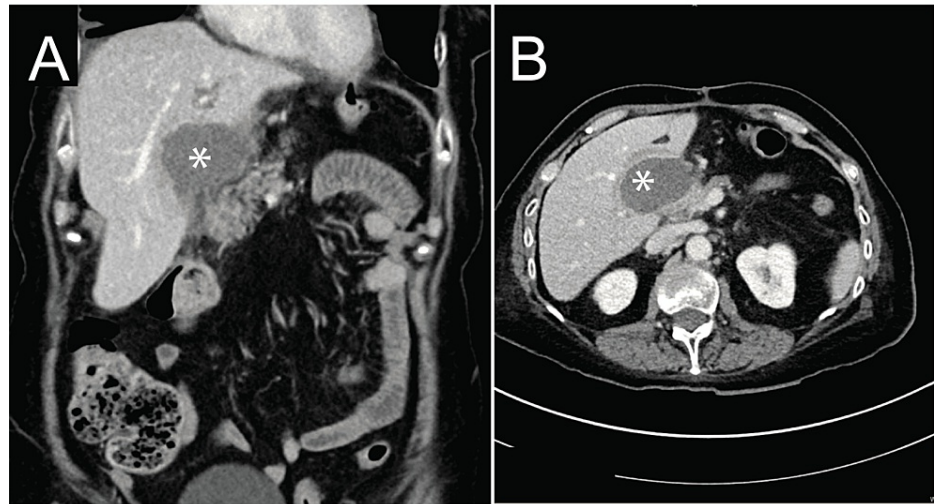
Laparoscopic cholecystectomy is the standard approach for this procedure with open cholecystectomies having declined nowadays [2-6]. This is in large part due to laparoscopic cholecystectomies having better patient outcomes with reduced morbidity, mortality, infection, and shorter hospitalizations [3]. However, like any surgical procedure, cholecystectomy carries its own risks such as sepsis, bleeding, damage to surrounding tissues, bile leakage, and abscess formation [2-4, 6, 7]. Abscess formation as seen in this case can be due to a variety of reasons such as infection or gallstone spillage during surgery with the latter being more common to laparoscopic surgery [4,6,7].

## Case Presentation

A 71-year-old female with a history significant for Barrett's esophagus with distal esophageal adenocarcinoma status post neoadjuvant chemotherapy, radiation therapy and Ivor Lewis Esophagectomy and following open cholecystectomy secondary to chronic cholecystitis, presented eight months later with right upper quadrant abdominal pain. Right upper quadrant abdominal pain was ongoing for a month, and it was accompanied by few days of non-bilious vomiting and fevers. On admission, she was found to be afebrile with a blood pressure of 130/90, heart rate of 85, and oxygen saturation of 97%. Laboratory findings were remarkable for leukocytosis with neutrophilic predominance (87.9%) and a potassium of 3.3. Computed tomography (CT) scan of the abdomen revealed a new 5.3 x 3.6 x 5.8 cm<sup>3</sup> fluid collection (Figure 1).

### How to cite this article

Vyas H, Burg E, Moradi R, et al. (May 24, 2022) Unusual Presentation of Gallbladder Fossa Abscess Following Open Cholecystectomy in a Patient With Cholecystitis: A Case Report. Cureus 14(5): e25274. DOI 10.7759/cureus.25274



**FIGURE 1: Abdominal computed tomographic (CT) scan.**

Abscess with complex fluid collection measured  $5.3 \times 3.6 \times 5.8 \text{ cm}^3$  (Asterisk) in coronal (A), and axial view (B).

The patient underwent a Jackson-Pratt drain placement and subsequent body fluid cultures showed *Streptococcus intermedius* and blood cultures grew the same organism. She was initially treated with aztreonam and flagyl until sensitivities resulted and afterwards, she received a course of vancomycin with resolution of her symptoms (as the patient was allergic to cephalosporins).

## Discussion

Cholecystectomy is one of the most commonly performed surgical interventions with an estimated 300,000 cases performed in the United States each year due to gallstones [2].

Adverse events such as abscess formation can lead to a post-cholecystectomy syndrome which most commonly presents with abdominal pain, dyspepsia, fever, and jaundice, however, it can present with other symptoms such as vomiting, pseudocysts, and liver abscess [4]. Abscesses usually present within a couple of weeks of cholecystectomy [8,9]. In the event of a gallstone spillage or retained stone, complications such as intra-abdominal abscess can manifest years following the initial surgery. These abscesses presenting years after cholecystectomy are commonly colonized by *E. coli* and have a female predominance. Despite prior occurrences, abscess formation protracted from surgery constitutes a rare occurrence [6,7].

## Conclusions

The case described here is an unusual presentation of a gallbladder fossa abscess, which was diagnosed eight months following an open cholecystectomy. Previous studies revealed that gallbladder fossa abscess may have been a potential distant complication of a spilled or retained gallstone which can commonly result in an intra-abdominal abscess. Abscesses such as these can have poor outcomes for patients if not recognized and treated with drainage of the source and appropriate antibiotic therapy.

## Additional Information

### Disclosures

**Human subjects:** Consent was obtained or waived by all participants in this study. **Conflicts of interest:** In compliance with the ICMJE uniform disclosure form, all authors declare the following: **Payment/services info:** All authors have declared that no financial support was received from any organization for the submitted work. **Financial relationships:** All authors have declared that they have no financial relationships at present or within the previous three years with any organizations that might have an interest in the submitted work. **Other relationships:** All authors have declared that there are no other relationships or activities that could appear to have influenced the submitted work.

## References

1. O'Connor OJ, Maher MM: Imaging of cholecystitis. *AJR Am J Roentgenol.* 2011, 196:367-374.

[10.2214/AJR.10.4340](https://doi.org/10.2214/AJR.10.4340)

2. Hassler KR, Collins JT, Philip K, Jones MW: Laparoscopic cholecystectomy. StatPearls [Internet]. StatPearls Publishing, Treasure Island, FL; 2022.
3. Coccolini F, Catena F, Pisano M, et al.: Open versus laparoscopic cholecystectomy in acute cholecystitis. Systematic review and meta-analysis. *Int J Surg*. 2015, 18:196-204. [10.1016/j.ijvsu.2015.04.083](https://doi.org/10.1016/j.ijvsu.2015.04.083)
4. Chowbey P, Sharma A, Goswami A, et al.: Residual gallbladder stones after cholecystectomy: a literature review. *J Min Access Surg*. 2015, 11:223-230. [10.4103/0972-9941.158156](https://doi.org/10.4103/0972-9941.158156)
5. Urbach DR, Stukel TA: Rate of elective cholecystectomy and the incidence of severe gallstone disease . *CMAJ*. 2005, 172:1015-1019. [10.1503/cmaj.1041363](https://doi.org/10.1503/cmaj.1041363)
6. Varathan N, Hess G, Nocera F, Lazaridis I, Posabella A: Intraabdominal abscess after cholecystectomy: do not forget the stones. *Int Clin Med*. 2019, 3:1-2. [10.15761/icm.1000156](https://doi.org/10.15761/icm.1000156)
7. Quinn E, Capanegro J, Hartigan J: A case report: delayed gallstone abscess formation 10 years post-cholecystectomy. *Int J Surg Case Rep*. 2020, 77:903-905. [10.1016/j.ijscr.2020.11.126](https://doi.org/10.1016/j.ijscr.2020.11.126)
8. Rodrigue P, Fakhri A, Baumgartner A: Gallbladder fossa abscess masquerading as cholecystitis after cholecystectomy. *J Nucl Med Technol*. 2015, 43:295-296. [10.2967/jnmt.115.155606](https://doi.org/10.2967/jnmt.115.155606)
9. Long DA, Long B: A 61-year-old female with right upper abdominal pain . *Clin Pract Cases Emerg Med*. 2020, 4:630-631. [10.5811/cpcem.2020.7.48514](https://doi.org/10.5811/cpcem.2020.7.48514)