


CASE REPORT

Exogenous insulin antibody syndrome treated with plasma exchange after an incomplete response to immunosuppressive therapy

Yuan Zhuang¹  | Xudong Wei^{2,3} | Yang Yu¹ | Deqing Wang¹

¹Department of Blood Transfusion, First Medical Center of Chinese PLA General Hospital, Beijing, China

²Department of Endocrinology, First Medical Center of Chinese PLA General Hospital, Beijing, China

³Department of Endocrinology, TCM Hospital of Shi Jia Zhuang City, Shijiazhuang, Hebei, China

Correspondence

Deqing Wang, Department of Blood Transfusion, First Medical Center of Chinese PLA General Hospital, No. 28# Fuxing Road, Haidian District, Beijing 10086, China.

Email: deqingw@vip.sina.com

Abstract

A 43-year-old man with a 23-year history of type II diabetes presented with uncontrolled hyperglycemia with frequent episodes of ketoacidosis. He was diagnosed with exogenous insulin antibody syndrome, and received high-dose methylprednisolone to treat insulin resistance. Ketoacidosis relapsed 2 years later, and the patient showed an incomplete response to glucocorticoids. We decided to administer therapeutic plasma exchange, which resulted in rapid lowering of the daily insulin requirement and improved glycemic control.

KEYWORDS

diabetes, exogenous insulin antibody syndrome, hyperglycemia, therapeutic plasma exchange

1 | INTRODUCTION

The prevalence of diabetes has increased exponentially in China over the past 10 years. According to the International Diabetes Federation, 116.4 million adults (aged 20-79 years) were diagnosed with diabetes in China in 2019, ranking first in the world,¹ and insulin, widely used for treatment of diabetes is known to produce significant therapeutic effects. However, a study has reported an immunological response to exogenous insulin,² especially anti-insulin antibody formation. This phenomenon was first described by Berson et al who reported circulating insulin antibodies (IAs) in patients receiving exogenous animal insulin therapy.³ Although human insulin may be less immunogenic than animal varieties of insulin, some patients treated with recombinant human insulin for diabetes could develop IAs,² particularly Asian populations.⁴⁻⁹ Exogenous insulin-induced IAs in patients

with diabetes are associated with clinical events, which is named exogenous insulin antibody syndrome (EIAS).¹⁰

We report a case of type II diabetes treated with recombinant human insulin/insulin analogs in a patient who developed uncontrollable hyperglycemia and intermittent episodes of ketoacidosis despite steroid therapy, who was successfully treated with therapeutic plasma exchange (TPE). Optimal treatment for EIAS is not described in the Eighth American Society for Apheresis guidelines,¹¹ TPE is reported as an effective therapeutic option in some intractable cases.¹²⁻¹⁴

2 | CASE PRESENTATION

A 43-year-old man with a 23-year history of type II diabetes received human insulin treatment that was initiated in 2006. The patient was intermittently hospitalized with

This is an open access article under the terms of the Creative Commons Attribution-NonCommercial-NoDerivs License, which permits use and distribution in any medium, provided the original work is properly cited, the use is non-commercial and no modifications or adaptations are made.

© 2021 The Authors. *Journal of Clinical Apheresis* published by Wiley Periodicals LLC.

hyperglycemia and ketoacidosis, prompting changes in therapy to insulin analogs including insulin glulisine, insulin aspart, and insulin glargine. The patient was admitted to our hospital in 2017 and received an increased daily insulin dosage of approximately 200 IU with a fasting blood glucose (FBG) level of 15 mmol/L (reference range, 3.4-6.1 mmol/L). The fasting serum C-peptide concentration was 0.52 ng/mL (reference range, 0.80-3.10 ng/mL). The fasting serum insulin level was elevated to 39.49 mU/L (reference range, 2.6-24.9 mU/L). Positive immunoglobulin IgG anti-human insulin test results were diagnostic and explained the elevated fasting insulin concentration, which occurred secondary to binding to these antibodies, which prolonged the $t_{1/2}$ of insulin from the usual time of approximately 4 minutes to potentially hours. Contrast-enhanced abdominopelvic computed tomography did not reveal evidence of pancreatic or adrenal disease or intra-abdominal malignancy. In view of EIAS with insulin resistance, the patient received a 3-day course of methylprednisolone (500 mg/day). The FBG concentration was controlled, and the daily insulin dosage gradually decreased from 225 U to 72 U (see Figure 1). He was subsequently discharged and continued to receive human insulin, isophane protamine insulin, metformin, and pioglitazone.

In October 2019, the patient was diagnosed with uncontrolled hyperglycemia despite daily insulin therapy. On admission, his FBG level and serum glycosylated hemoglobin were 18.57 mmol/L and 9.7% (reference range, 4%-6%), respectively. Anti-IAs concentrations were significantly elevated and were approximately 10-fold higher than the upper limit of normal. Tests for insulin-specific IgE antibody and islet-related autoantibodies, such as those directed against glutamic acid decarboxylase and insulinoma-associated antigen-2 showed negative results. The fasting serum insulin level was elevated to 69.93 mU/L,

which was much higher than that measured during his initial hospitalization. Figure 2 shows the treatment schema. The patient developed abrupt onset of palpitations, headache, and labored breathing, 5 days after admission, and laboratory test results showed with urinary ketones of 150.0 mg/day (reference range, negative). Blood gas analysis showed pH of 7.042 (reference range, 7.35-7.45), residual alkali -24.3 mmol/L (reference range, -3-3 mmol/L), actual bicarbonate 4.4 mmol/L (reference range, 20-26 mmol/L), partial pressure of oxygen at 140.0 mm Hg (reference range, 80-100 mm Hg) and partial pressure of carbon dioxide at 16.6 mm Hg (reference range, 35-45 mm Hg). In light of severe insulin resistance that could lead to acidosis, we administered azathioprine (100 mg/day) and high-dose methylprednisolone

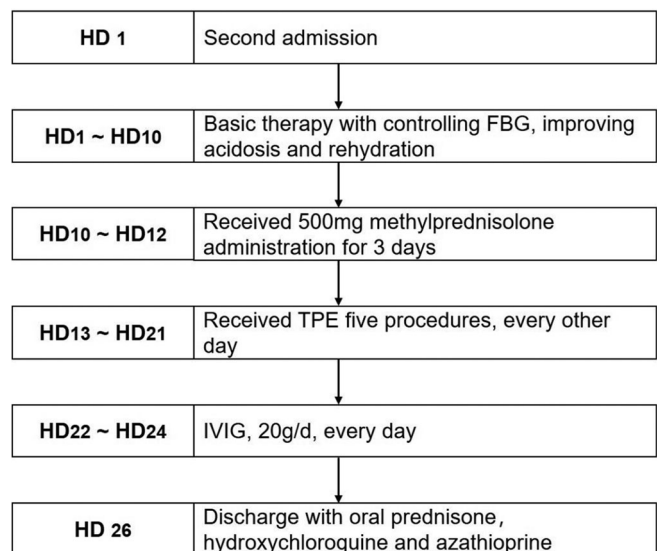
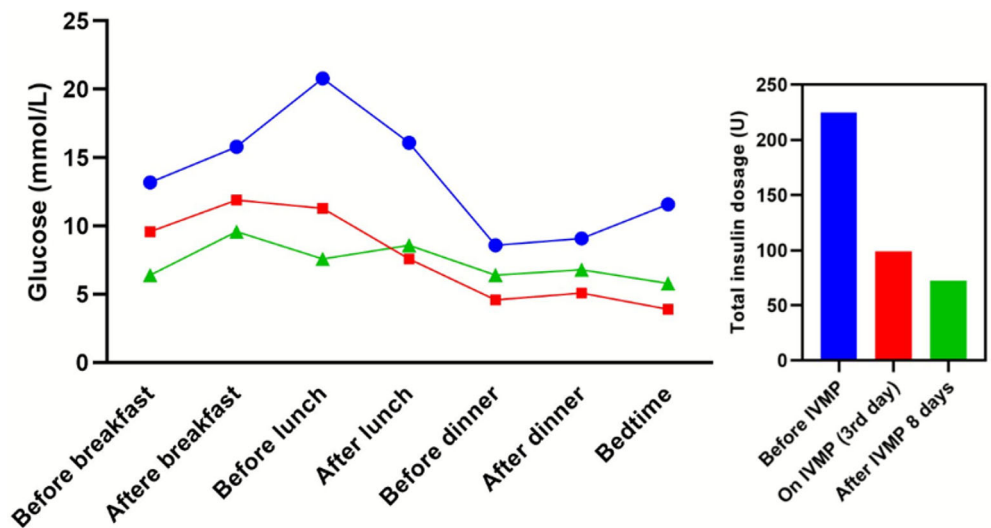


FIGURE 2 Immunosuppression treatment schema of the patient over the second hospitalization

FIGURE 1 The scatter line chart on the left shows the glucose profile at 7-time points in a day before IVMP therapy, on third day of IVMP therapy, and on eighth day after IVMP therapy (blue, red, and green line, respectively) on his first hospitalization. The column chart on the right shows the daily insulin dosage before IVMP therapy, on third day of IVMP therapy, and on eighth day after IVMP therapy. IVMP, intravenous methylprednisolone



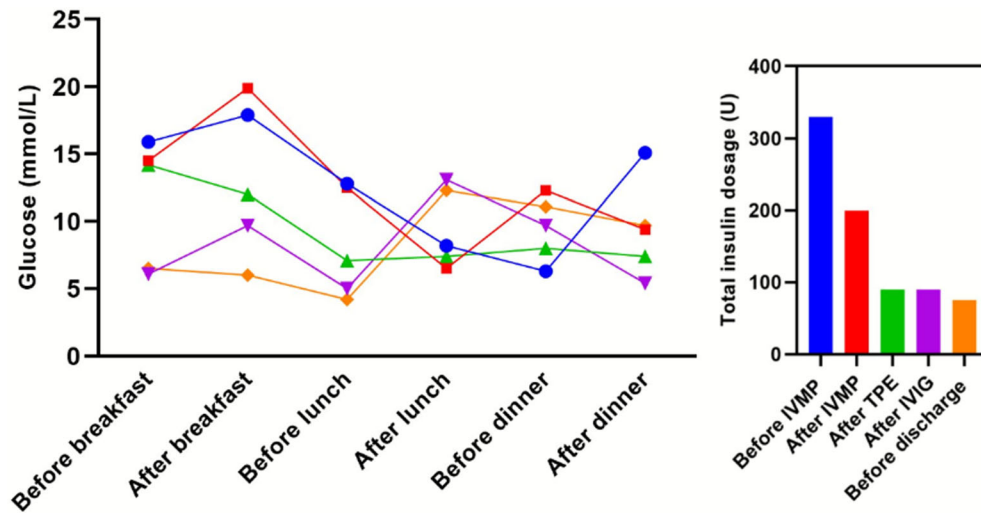


FIGURE 3 The scatter line chart on the left shows the glucose profile at 6-time points in a day, consecutively before IVMP, after IVMP, after TPE, after IVIG, and before discharge (blue, red, green, purple, and orange line, respectively) during the second hospitalization. The column chart on the right shows the daily insulin dosage after consecutive treatments. IVMP, intravenous methylprednisolone; IVIG, intravenous immunoglobulin; TPE, therapeutic plasma exchange;

(500 mg/day, 3 days) for immunosuppression; however, the glucose profile did not improve. TPE was initiated on day 13 of hospitalization. Vascular access was established using a 12.0 F double-lumen catheter via the femoral vein exclusively used for TPE. Five standard exchanges were performed every other day using Fresenius COM. TEC cell separator (Fresenius Kabi AG, Bad Homburg vor der Höhe, Germany). The total plasma volume (TPV) was calculated based on height, weight and hematocrit measurements using the following formula: $(TPV [mL]) = 70 \text{ mL/kg} \times [1 - \text{hematocrit}] \times \text{weight [kg]}$. Acid citrate dextrose solution A (ACD-A) was used as an anticoagulant during the TPE procedure, and the ratio of ACD-A to whole blood was maintained at 1:12-1:16. Approximately 1.2 TPV was replaced during each procedure. The replacement fluid included frozen plasma (2000 mL), 5% albumin solution (500 mL), and normal saline (500 mL). After the TPE series, he received 3 days of intravenous Ig (IVIg, 20 g/day) and sequential oral administration of prednisone (60 mg/day). The daily insulin dosage was 330 U on hospital day 1, which was decreased to 220 U after initiation of methylprednisolone therapy, rapidly trended down to 90 U after TPE and was maintained at 75-80 U after IVIG (see Figure 3). The patient's serum C-peptide level increased from 0.436 ng/mL to 2.48 ng/mL during the course of hospitalization, which indicated an increase in endogenous insulin secretion.

3 | DISCUSSION

EIAS is a rare immune disorder caused by IAs that triggers severe uncontrollable glycemic fluctuations in some

patients. The underlying mechanism is attributed to the reversible binding of insulin to IAs (association/binding, followed by dissociation to free insulin). Bound insulin is biologically inactive, which explains hyperglycemia observed in these patients. Dissociation of bound insulin increases free bioactive insulin levels, which precipitates hypoglycemia of varying severity.¹⁰ Administration of purified recombinant human insulin preparations is shown to reduce but not eliminate the development of IAs. Factors affecting IA development may include the recipient's immune response; genes; age; the purity, molecular structure, storage condition, formulation of insulin; as well as the sites of insulin delivery.² Initial treatment modalities for EIAS include reducing antigen exposure and immunosuppression. The former includes discontinuation of insulin, combination with oral hypoglycemic agents and replacement of insulin formulations because some insulin analogs may not bind to endogenous IAs. The use of insulin analogs and steroids was initially effective in our patient; however, we observed recurrent uncontrolled hyperglycemia accompanied with ketoacidosis. Therefore, immunomodulators such as glucocorticoids,^{15,16} mycophenolate mofetil,¹² cyclophosphamide,⁴ IVIG, and azathioprine can be utilized in refractory cases. TPE is viewed as a useful treatment option in severe cases of EIAS, particularly in those unresponsive to other therapeutic modalities.¹⁷ Our patient underwent five TPE procedures every other day, which led to a reduction in daily insulin dosage with the dose maintained at 90 U per day, which was associated with a stable blood glucose level. Subsequently, the patient received IVIG to strengthen the effects of the treatment. Most IVIG formulations usually show multi-compartmental kinetics (with 76% of intravascular IgM), with low volumes of distribution

($V_D < 0.3$ L/kg).¹⁸ This suggests that most IVIG medications are susceptible to TPE removal. Therefore, we administered IVIG after the TPE procedures, and IVIG reduced the daily insulin dosage slightly. It is important to consider the unpredictability and potential inaccuracy of insulin measurements in this case, secondary to endogenous IAs, which are known to interfere and cross-react in immunoassays.¹⁹ Therefore, we decided to evaluate the effect of treatment by daily insulin dosage and the patient's glycemic profile. TPE was the most important therapeutic strategy that played a key role in the treatment of this patient, although the cumulative effect of methylprednisolone in the later stage should not be ruled out. Until January 2021, the patient's daily insulin dosage was maintained at 120 U, and we observed no ketoacidosis occurred despite fluctuations in blood sugar levels.

4 | CONCLUSION

Evaluation of endogenous IAs is mandatory in patients with unexplained, poorly controlled diabetes, who receive insulin treatment and show high blood glucose levels or frequent recurrent hypoglycemia. TPE can serve as effective therapy in patients who are refractory to other therapeutic modalities.

CONFLICT OF INTEREST

The authors declare that they have no conflict of interest.

DATA AVAILABILITY STATEMENT

The data that support the findings of this study are available from the corresponding author upon reasonable request.

ORCID

Yuan Zhuang  <https://orcid.org/0000-0001-8521-5032>

REFERENCES

1. Federation. ID. *IDF Diabetes Atlas*. 9th ed. Brussels, Belgium: International Diabetes Federation; 2019.
2. Fineberg SEKT, Finco-Kent D, Fountaine RJ, Finch GL, Krasner AS. Immunological responses to exogenous insulin. *Endocr Rev*. 2007;6(28):625-652.
3. Berson Sa YR, Bauman A, Rothschild MA, Newerly K. Insulin-I131 metabolism in human subjects: demonstration of insulin binding globulin in the circulation of insulin treated subjects. *J Clin Invest*. 1956;2(35):170-190.
4. Ishizuka TOS, Mori T, Nako K, Nakamichi T, Oka Y, Ito S. Characteristics of the antibodies of two patients who developed daytime hyperglycemia and morning hypoglycemia because of insulin antibodies. *Diabetes Res Clin Pract*. 2009;2(84):e21-e23.
5. Zhao TY, Li F, Xiong ZY. Frequent reoccurrence of hypoglycemia in a type 2 diabetic patient with insulin antibodies. *Mol Diagn Ther*. 2010;4(14):237-241.
6. Itoh ASY, Mitsuishi M, Oikawa Y, et al. Insulin glulisine may ameliorate nocturnal hypoglycemia related to insulin antibody—a case report. *Diabetes Res Clin Pract*. 2011;2(94):e53-e54. Discussion e55.
7. Hu XMX, Wang X, Zhao X, et al. Insulin antibodies in patients with type 2 diabetic receiving recombinant human insulin injection: a report of 12 cases. *Ann Endocrinol*. 2015;6(76):694-697.
8. Li RMJ, Yu K, Wang L, Hu M, Xu L. Medical nutrition therapy is effective in the management of hypoglycemia caused by insulin antibodies: a case report and literature review. *J Am Coll Nutr*. 2016;1(35):86-90.
9. Quan HTH, Li Q, Li J, Li S. Immunological hypoglycemia associated with insulin antibodies induced by exogenous insulin in 11 Chinese patients with diabetes. *J Diabetes Res*. 2015;2015:746271. <https://doi.org/10.1155/2015/746271>.
10. Hu XCF. Exogenous insulin antibody syndrome (EIAS): a clinical syndrome associated with insulin antibodies induced by exogenous insulin in diabetic patients. *Endocr Connect*. 2018;1(7):R47-R55.
11. Padmanabhan A, Connelly SL, Aqui N, et al. Guidelines on the use of therapeutic apheresis in clinical practice—evidence-based approach from the Writing Committee of the American Society for Apheresis: the eighth special issue. *J Clin Apheresis*. 2019;3(34):171-354.
12. Greenfield JR TA, Soos MA, Semple RK, Halsall DJ, Chaudhry A, O'Rahilly S. Severe insulin resistance due to anti-insulin antibodies: response to plasma exchange and immunosuppressive therapy. *Diabetic Med J Br Diabetic Assoc*. 2009;1(26):79-82.
13. Robbins DJTN, Narayanan D, Hess AS, Rose WN. Therapeutic plasma exchange for exogenous insulin antibody syndrome in combined variable immunodeficiency: a case report. *J Clin Apheresis*. 2020;2(35):128-130.
14. Micić DBS, Kendereski A, Popović V, et al. Immunological resistance to human biosynthetic insulin—effects of immunosuppression and plasmapheresis. *Diabetes Res Clin Pract*. 1993;1(19):83-89.
15. Suzuki KHS, Ito S. A case of a non-insulin dependent diabetic patient with regular spontaneous hypoglycemic attacks, which were due to insulin-binding antibodies induced by human insulin therapy. *Tohoku J Exp Med*. 1997;2(182):163-173.
16. Matsuyoshi ASS, Tsuruzoe K, Taketa K, et al. A case of slowly progressive type 1 diabetes with unstable glycemic control caused by unusual insulin antibody and successfully treated with steroid therapy. *Diabetes Res Clin Pract*. 2006;3(72):238-243.
17. Sharwood EF, Hughes IP, Pretorius CJ, et al. Therapeutic plasma exchange normalizes insulin-mediated response in a child with type 1 diabetes and insulin autoimmune syndrome. *Pediatr Diabetes*. 2018;1(19):171-179.
18. Koleba T, Ensom MH. Pharmacokinetics of intravenous immunoglobulin: a systematic review. *Pharmacotherapy*. 2006;6(26):813-827.
19. Ismail AA. Insulin analogues as a new example of interference in insulin assays. *Ann Clin Biochem*. 2016;Pt 1(53):181-182.

How to cite this article: Zhuang Y, Wei X, Yu Y, Wang D. Exogenous insulin antibody syndrome treated with plasma exchange after an incomplete response to immunosuppressive therapy. *J Clin Apher*. 2021;36(4):664–667. <https://doi.org/10.1002/jca.21905>