








CASE REPORT

REVISED **Case Report: Pulmonary tuberculosis and raised transaminases without pre-existing liver disease- Do we need to modify the antitubercular therapy? [version 2; peer review: 1 approved, 2 approved with reservations]**

Previously titled: Case Report: Treating pulmonary tuberculosis with transaminitis with standard antitubercular four drugs therapy

Sanjeev Gautam¹, Keshav Raj Sigdel¹, Sudeep Adhikari ¹, Buddha Basnyat ^{1,2}, Buddhi Paudyal ¹, Jiwan Poudel ¹, Ujjwol Risal ¹

¹Internal Medicine, Patan Academy of Health Sciences, Lalitpur, State 3, Nepal

²Oxford University Clinical Research Unit, Patan Hospital, Lalitpur, State 3, Nepal

v2 First published: 17 Aug 2020, 5:193
<https://doi.org/10.12688/wellcomeopenres.16175.1>

Latest published: 16 Oct 2020, 5:193
<https://doi.org/10.12688/wellcomeopenres.16175.2>

Abstract

We report a case of an adult female with pulmonary tuberculosis who had biochemical evidence of liver injury during the presentation manifested as raised transaminases, but without clinically obvious pre-existing liver disease nor a history of hepatotoxic drug use. This is a fairly common scenario seen in tuberculosis endemic areas; however, this is an under reported condition in the literature and guidelines for its management has not been established. Many clinicians including the authors have treated such cases with modified liver friendly regimens in fear of increasing the hepatotoxicity with standard antitubercular drugs. However, the modified regimens may not be optimal in treating the underlying tuberculosis. In this report, we gave full dose standard drugs, and the liver injury resolved as evidenced by normalization of transaminases. Further research is required in this regard, but the presence of transaminitis with no obvious common underlying etiology may not warrant a modification of standard antitubercular regimen.

Keywords

tuberculosis, transaminitis, standard ATT, liver friendly regimen



This article is included in the [Oxford University Clinical Research Unit \(OUCRU\) gateway](#).

Open Peer Review

Reviewer Status   


	Invited Reviewers		
	1	2	3
version 2 (revision) 16 Oct 2020	 report		 report
			
version 1 17 Aug 2020	 report	 report	 report

1. **Vivek Neelakantan** , Independent

Medical Historian, Mumbai, India

2. **Prajowl Shrestha**, Bir Hospital, Kathmandu,

Nepal

Ashesh Dhungana , Bir Hospital,

Kathmandu, Nepal

3. **Neesha Rockwood** , Imperial College

London, London, UK

University of Cape Town, Cape Town, South

Africa

University of Colombo, Colombo, Sri Lanka

Any reports and responses or comments on the article can be found at the end of the article.

Corresponding author: Sudeep Adhikari (sudeepadh123@gmail.com)

Author roles: **Gautam S:** Data Curation, Writing – Original Draft Preparation; **Sigdel KR:** Conceptualization, Supervision, Writing – Review & Editing; **Adhikari S:** Writing – Original Draft Preparation, Writing – Review & Editing; **Basnyat B:** Conceptualization, Supervision, Writing – Review & Editing; **Paudyal B:** Supervision, Writing – Review & Editing; **Poudel J:** Writing – Review & Editing; **Risal U:** Writing – Review & Editing

Competing interests: No competing interests were disclosed.

Grant information: This work was supported by the Wellcome Trust [106680]

The funders had no role in study design, data collection and analysis, decision to publish, or preparation of the manuscript.

Copyright: © 2020 Gautam S *et al.* This is an open access article distributed under the terms of the [Creative Commons Attribution License](#), which permits unrestricted use, distribution, and reproduction in any medium, provided the original work is properly cited.

How to cite this article: Gautam S, Sigdel KR, Adhikari S *et al.* **Case Report: Pulmonary tuberculosis and raised transaminases without pre-existing liver disease- Do we need to modify the antitubercular therapy?** [version 2; peer review: 1 approved, 2 approved with reservations] Wellcome Open Research 2020, 5:193 <https://doi.org/10.12688/wellcomeopenres.16175.2>

First published: 17 Aug 2020, 5:193 <https://doi.org/10.12688/wellcomeopenres.16175.1>

REVISED Amendments from Version 1

The changes have been made in the revised manuscript as suggested by the reviewers. The concerns of reviewers regarding limited workup of the patient for liver disease has been addressed in the manuscript. This is a single case report and further studies are required to make a firm recommendation for management of pulmonary tuberculosis with transaminitis without pre-existing liver disease. We have acknowledged the fact in the revised manuscript.

Any further responses from the reviewers can be found at the end of the article

Background

Tuberculosis is the biggest infectious disease killer in the world¹, and is endemic in Nepal with the national prevalence at 416 cases per 100000 population². Pulmonary tuberculosis is the most common form. In Nepal, tuberculosis prevalence is more in productive age group (25–64 years) and men. Poverty, malnutrition, overcrowding, immunocompromised state like HIV infection, alcohol, smoking, air pollution, diabetes and other comorbidities are important risk factors for acquiring the disease³. Though under-reported, involvement of liver with tuberculosis is encountered often in clinical practice in endemic areas like Nepal. Liver can be involved; a) diffusely as a part of disseminated miliary tuberculosis or as primary miliary tuberculosis of liver, or b) focal involvement as hepatic tuberculoma or abscess, as was classified by Reed in 1990⁴. The biochemical pattern of liver function abnormality in these forms of extrapulmonary tuberculosis is cholestatic (predominantly raised alkaline phosphatase and gamma-glutamyltranspeptidase) rather than hepatocellular (predominantly raised transaminases)^{5,6}. The hepatocellular pattern of liver injury is seen in cases with pre-existing liver disease including hepatotoxic drug use, which are unrelated to tuberculosis^{7,8}.

As per national protocol of Nepal, any patient with tuberculosis receives combination antitubercular therapy (ATT) including four drugs; Isoniazid (H), Rifampicin (R), Pyrazinamide (Z) and Ethambutol (E) for initial 2 months popularly known as HRZE. This is followed by 4 months of two drugs; HR. Treatment is given under Directly Observed Treatment Short- Course (DOTS) to improve the patient compliance which could otherwise be compromised owing to lower socioeconomic status of patients, longer duration of treatment and side effects⁹. Patients with extrapulmonary hepatic tuberculosis are treated with full dose of standard ATT^{5,6}. But three out of the four drugs (H, R and Z) are hepatotoxic⁷. So the patients having pre-existing liver disease usually require liver-friendly modified regimens to protect the liver but they may be suboptimal for eradicating underlying tuberculosis⁸. The protocol of Nepal does not warrant baseline investigations except chest X-ray and sputum smear microscopy to be done routinely before prescribing ATT in programmatic setting⁹. However in hospital setting like our case, baseline blood investigations including liver function tests are usually done before starting treatment even in absence of features suggesting liver injury and therapy modified accordingly.

Here we present a case of pulmonary tuberculosis with predominant transaminitis but there was no feature of pre-existing liver disease nor a history of hepatotoxic drug use. The liver injury was attributed to the pulmonary tuberculosis itself, and treated with standard first line ATT which led to resolution of liver function abnormalities.

Case presentation

A 33 year old Newar housewife from Kathmandu, Nepal, with no known comorbidity, presented to Patan Hospital Emergency Department in November, 2019 with a history of cough with occasional sputum production over the previous 20 days and low grade fever for 10 days. There was no history of chest pain, difficulty breathing, headache, vomiting, altered mentation, abdominal pain, yellowish discoloration of eyes, burning urine, hair loss, photosensitivity, joint pain, or rash but she had decreased appetite and weight loss. There was no past history of tuberculosis or jaundice. She did not consume alcohol or any drugs including acetaminophen, aflatoxin or herbal products. Her father-in-law had been diagnosed with pulmonary tuberculosis five years earlier, but there was no family history of liver disease.

Initial examination showed temperature of 101°F with pulse of 110 beats/minute and respiratory rate of 26 breaths/minute. There was diffuse fine crepitation on the left side on auscultation of the chest. There was no lymphadenopathy, icterus, peripheral edema or wheezes. Neck veins were not distended. Liver and spleen were not palpable, and abdomen examination was normal.

Laboratory parameters with normal ranges in parenthesis are as follow:

Complete blood count before transfusion: white cell count 7.8 (4–10) × 10⁹/L; neutrophils 80%; lymphocytes 16%; monocytes 4%; red blood cells 3.6 (4.2–5.4) × 10¹²/L; haemoglobin 10.6 (12–15) g/dL; platelets 410 (150–400) × 10⁹/L.

Biochemistry: random blood sugar 126 (65–110) mg/dL; urea 39 (17–45) mg/dL; creatinine 1.1 (0.8–1.3) mg/dL; sodium 138 (135–145) mmol/L and potassium 4 (3.5–5) mmol/L.

Chest X-ray ([Figure 1](#)) showed thick walled cavitating lesions in the left upper lobe and patchy infiltrates in left middle and lower zones. There were hyperinflated lung fields with blunting of left costophrenic angle. Sputum smear examination showed 3+ acid fast bacilli. Sputum Gene Xpert was positive for Rifampicin sensitive tubercle bacilli. A diagnosis of pulmonary tuberculosis was made, and planned for starting ATT.

Liver function test was performed as baseline workup before starting treatment which showed the following results (with normal ranges in parenthesis): bilirubin total 1.1 (0.1–1.2) mg/dL and direct 0.5 (0–0.4) mg/dL; alanine transaminase 308 (5–30) units/L; aspartate transaminase 605 (5–30) units/L; alkaline phosphatase 149 (50–100) IU/L; gamma-glutamyltranspeptidase 66 (9–48) units/L. The raised transaminases led us to perform further workup for liver disease. There was no clinical evidence

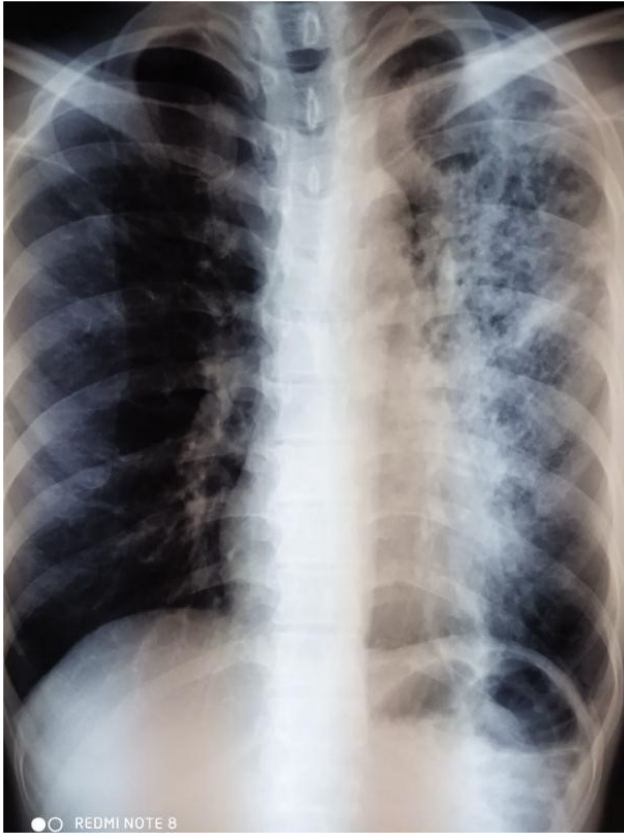


Figure 1. Chest X-ray showing thick walled cavitating lesions in the left upper lobe and patchy infiltrates in left middle and lower zones.

of chronic liver disease or portal hypertension. Liver synthetic functions were as following; albumin 3.5 (3.5–5) g/dL; total protein 6.5 (6–8.3) g/dL; prothrombin time 14 (11–13.5) s. Serologies for HIV, HBsAg, Hepatitis C virus (HCV), Hepatitis A virus (HAV) and Hepatitis E virus (HEV) were nonreactive. Testing for other hepatotropic viruses was not done because of unavailability of the tests. Neurological examinations and the slit lamp examination of eye were normal. Ultrasound of the abdomen showed a normal sized liver with smooth outline and echotexture. However fibroscan, upper gastrointestinal endoscopy, abdominal CT scan and liver biopsy were not done due to financial constraints of the patient.

She was admitted to the respiratory isolation unit. At first there was some hesitation in starting the full treatment for her pulmonary tuberculosis because of her liver function tests. But taking into consideration her presentation and laboratory findings, we opted for the full treatment rather than a modified TB regimen. We started standard four drugs ATT based on her weight as per national TB guidelines which included three tablets of HRZE given once daily with each tablet containing 75 mg isoniazid (H), 150 mg rifampicin (R), 400 mg pyrazinamide (Z) and 275 mg ethambutol (E). This led to improvement in her clinical

status. She was closely observed for possible worsening of her liver disease due to the hepatotoxic antitubercular drugs. Providentially, at 1 week after starting treatment, she was afebrile and continuing to improve and her liver function test showed a total bilirubin of 0.7 mg/dl, aspartate transaminase of 40 IU/L and alanine transaminase of 62 IU/L.

She was discharged with advice to follow up in 1 month. At 1 month follow up she had no symptoms and therefore no further tests were done. At 2 months, she was still asymptomatic and her sputum smear was negative for acid fast bacilli. Her liver function test showed a total bilirubin of 0.6 mg/dl, aspartate transaminase of 30 IU/L and alanine transaminase of 35 IU/L. She was switched to 3 tablets of HR to be taken for 4 months.

Discussion

Our patient with pulmonary tuberculosis had predominantly raised transaminases (hepatocellular pattern) during the initial presentation, with only modest elevation in alkaline phosphatase and gamma glutamyltranspeptidase. The workup for liver disease could not be performed completely because of resource limitation. Looking for clinical evidences by history and examination, and performing liver function tests, abdominal ultrasound and serology for common hepatotropic viruses are usually considered sufficient in our limited setup. We perform further tests only if the initial workup hints towards another etiology. There were no clinical features of chronic liver disease or portal hypertension. She had no risk factors for liver disease such as family history, alcohol, drugs, toxins, features suggesting autoimmune or metabolic liver diseases. Her viral hepatitis serologies were negative. Ultrasound also showed normal liver architecture and size. Though incomplete, the initial workup led us to believe that she had no pre-existing liver injury.

Patients with extrapulmonary hepatic tuberculosis as classified by Reed (diffuse or focal) usually present with nonspecific symptoms like abdominal pain, jaundice, fever, night sweats, fatigue, weight loss and hepatomegaly. They have cholestatic pattern of liver function abnormality with normal transaminases, increased protein- albumin gap owing to raised serum globulin. Hepatic imaging with ultrasound or CT scan reveal abnormalities in 76 and 88% cases respectively. Liver biopsy and demonstration of caseating granuloma and mycobacterial culture remain gold standard for diagnosing hepatic tuberculosis⁴⁻⁶. Following points in our patient precluded making the diagnosis of hepatic tuberculosis; a) absence of abdominal symptoms and hepatomegaly; b) predominantly raised transaminases (hepatocellular pattern) and normal protein- albumin gap; and c) normal ultrasound finding (though CT and biopsy were not done).

There is another classification schema, given by Levine in 1990 which has incorporated additional entity under hepatic tuberculosis which is 'pulmonary tuberculosis with liver involvement'¹⁰. In the absence of obvious pre-existing liver disease or drug and the presence of active cavitary tuberculosis in lungs, we attributed the transaminitis in our patient to the pulmonary tuberculosis itself. In our anecdotal experience, we have found many such patients though we do not have any formal data to back

this up. They are often managed with modified liver-friendly antitubercular regimens for fear of increasing the hepatotoxicity and causing acute liver failure with the use of standard regimens. Few case reports are available in literature reporting the use of the modified regimens^{11,12}. We believe such cases are underreported, and firm guidelines have not been established to guide clinicians in these cases. Given this, many clinicians in low-middle income countries, including Nepal, who have been treating tuberculosis patients tend to be skeptical in using full doses of first line ATT in such patients and tend to use a modified regimen. However, this practice may potentially lead to under-treatment and therefore increase fatality¹³. The use of modified regimens may also increase the risk of developing drug-resistant tuberculosis because of exclusion of more potent drugs¹⁴. Though there was some hesitation at first in our case, we soon started treatment with the standard ATT in our patient with close monitoring. This we believe led to the resolution of liver injury, evidenced by the normalization of transaminases.

However, acknowledging that the patient may develop drug induced liver injury (DILI) with the hepatotoxic antitubercular drugs, we should monitor such patients closely in an inpatient basis to look for clinical deterioration or any feature suggesting liver failure and liver function test repeated regularly. Though there is no firm recommendation for when to repeat the tests, patient should not be discharged till there is significant improvement in the transaminases level. The close monitoring is important in those with higher risks for developing DILI associated with ATT such as elderly, females, alcohol consumers, the malnourished and those with genetic susceptibility like slow acetylators⁷. Such monitoring is even more important in our setup because there are possibilities of missing occult hepatic diseases owing

to limited workup. Our patient had improving transaminases evidenced till 2 months follow up.

Though limited by incomplete investigations, we concluded pulmonary tuberculosis as the cause for transaminitis in our patient, and the normalization of transaminases after starting the standard dose of ATT further supports this conclusion. We believe pulmonary TB presenting with transaminitis is a common problem and that treatment may often be compromised because of decreased dosing of ATT. We further aim to perform case series study to explore the magnitude of problem and reach specific conclusions.

Conclusion

When treating a tuberculosis patient with transaminitis, it is important to look for any possibility of pre-existing liver disease or drug use. If none is found, then the use of standard ATT from the beginning with close inpatient monitoring of the patient may be essential for optimal management of tuberculosis, and this may help resolve any liver injury caused by the tuberculosis. This is a single case report, so further case series or cohort studies would be helpful to reach some conclusion and provide concrete recommendations.

Consent

Written informed consent for publication of their clinical details and clinical images was obtained from the patient.

Data availability

Underlying data

All data underlying the results are available as part of the article and no additional source data are required.

References

- <https://www.who.int/news-room/fact-sheets/detail/tuberculosis>.
- <https://nepalntp.gov.np/wp-content/uploads/2020/03/NEPAL-NATIONAL-TB-PREVALENCE-SURVEY-BRIEF-March-24-2020.pdf>.
- <https://nepalntp.gov.np/wp-content/uploads/2020/04/NTP-Annual-Report-2015-76-2018-19.pdf>.
- Reed DH, Nash AF, Valabhji P: **Radiological diagnosis and management of a solitary tuberculous hepatic abscess.** *Br J Radiol.* 1990; **63**(755): 902-4.
[PubMed Abstract](#) | [Publisher Full Text](#)
- Hickey AJ, Gounder L, Moosa MY, et al.: **A systematic review of hepatic tuberculosis with considerations in human immunodeficiency virus co-infection.** *BMC Infect Dis.* 2015; **15**: 209.
[PubMed Abstract](#) | [Publisher Full Text](#) | [Free Full Text](#)
- Wu Z, Wang WL, Zhu Y, et al.: **Diagnosis and treatment of hepatic tuberculosis: report of five cases and review of literature.** *Int J Clin Exp Med.* 2013; **6**(9): 845-50.
[PubMed Abstract](#) | [Free Full Text](#)
- Ramappa V, Aithal GP: **Hepatotoxicity related to anti-tuberculosis drugs: mechanisms and management.** *J Clin Exp Hepatol.* 2013; **3**(1): 37-49.
[PubMed Abstract](#) | [Publisher Full Text](#) | [Free Full Text](#)
- Sonika U, Kar P: **Tuberculosis and liver disease: management issues.** *Trop Gastroenterol.* 2012; **33**(2): 102-6.
[PubMed Abstract](#) | [Publisher Full Text](#)
- https://nepalntp.gov.np/wp-content/uploads/2019/10/National-Tuberculosis-Management-Guidelines-2019_Nepal.pdf.
- Levine C: **Primary macronodular hepatic tuberculosis: US and CT appearances.** *Gastrointest Radiol.* 1990; **15**(4): 307-9.
[PubMed Abstract](#) | [Publisher Full Text](#)
- Sanchez-Codez M, Hunt WG, Watson J, et al.: **Hepatitis in children with tuberculosis: a case report and review of the literature.** *BMC Pulm Med.* 2020; **20**(1): 173.
[PubMed Abstract](#) | [Publisher Full Text](#) | [Free Full Text](#)
- Shastri M, Kausadikar S, Jariwala J, et al.: **Isolated hepatic tuberculosis: An uncommon presentation of a common culprit.** *Australas Med J.* 2014; **7**(6): 247-50.
[PubMed Abstract](#) | [Publisher Full Text](#) | [Free Full Text](#)
- Essop AR, Posen JA, Hodkinson JH, et al.: **Tuberculosis hepatitis: a clinical review of 96 cases.** *Q J Med.* 1984; **53**(212): 465-77.
[PubMed Abstract](#)
- Kumar N, Kedarisetty CK, Kumar S, et al.: **Antitubercular therapy in patients with cirrhosis: challenges and options.** *World J Gastroenterol.* 2014; **20**(19): 5760-72.
[PubMed Abstract](#) | [Publisher Full Text](#) | [Free Full Text](#)

Open Peer Review

Current Peer Review Status:   

Version 2

Reviewer Report 26 October 2020

<https://doi.org/10.21956/wellcomeopenres.18014.r40969>

© 2020 Rockwood N. This is an open access peer review report distributed under the terms of the [Creative Commons Attribution License](#), which permits unrestricted use, distribution, and reproduction in any medium, provided the original work is properly cited.

 **Neesha Rockwood** 

¹ Department of Infectious Diseases, Imperial College London, London, UK

² Institute of Infectious Diseases and Molecular Medicine, Wellcome Centre for Infectious Diseases Research in Africa, University of Cape Town, Cape Town, South Africa

³ Department of Microbiology, University of Colombo, Colombo, Sri Lanka

The revised version has been significantly improved. However, further revisions should be made to strengthen the manuscript.

The statement in the introduction 'The liver injury was attributed to the pulmonary tuberculosis itself' is ambiguous as it is accepted that a significant proportion of patients with pulmonary TB also have extrapulmonary disease. Without a full complement of tests e.g. liver biopsy, CT abdomen, extrapulmonary TB cannot be ruled out.

In the discussion the authors say 'Following points in our patient precluded making the diagnosis of hepatic tuberculosis; a) absence of abdominal symptoms and hepatomegaly; b) predominantly raised transaminases (hepatocellular pattern)'. Is diffuse hepatic involvement as a part of disseminated miliary tuberculosis (mentioned in introduction) not compatible with absence of abdominal symptoms and signs and a predominantly transaminitis pattern?

Please give a table of serial ALT, AST, GGT, Alk phos, Albumin and clotting during inpatient admission to assess trend during early treatment.

The authors should review the literature for cases where standard quadruple therapy has been utilized for TB with hepatic involvement and should comment on circumstances when prolongation of length of therapy should be considered.

Competing Interests: No competing interests were disclosed.

Reviewer Expertise: Tuberculosis, Interventional Pulmonology, ILD

I confirm that I have read this submission and believe that I have an appropriate level of expertise to confirm that it is of an acceptable scientific standard, however I have significant reservations, as outlined above.

Reviewer Report 16 October 2020

<https://doi.org/10.21956/wellcomeopenres.18014.r40968>

© 2020 Neelakantan V. This is an open access peer review report distributed under the terms of the [Creative Commons Attribution License](#), which permits unrestricted use, distribution, and reproduction in any medium, provided the original work is properly cited.



Vivek Neelakantan 

Independent Medical Historian, Mumbai, India

The authors have seriously taken note of the reviewer suggestion. The title and the abstract are much clearer. The study leads to an inevitable conclusion. I think the manuscript's status should be emended to indexed.

Competing Interests: No competing interests were disclosed.

Reviewer Expertise: History of Tuberculosis, Global Health, South and Southeast Asia, Medical Humanities

I confirm that I have read this submission and believe that I have an appropriate level of expertise to confirm that it is of an acceptable scientific standard.

Version 1

Reviewer Report 24 September 2020

<https://doi.org/10.21956/wellcomeopenres.17759.r40504>

© 2020 Rockwood N. This is an open access peer review report distributed under the terms of the [Creative Commons Attribution License](#), which permits unrestricted use, distribution, and reproduction in any medium, provided the original work is properly cited.



Neesha Rockwood 

¹ Department of Infectious Diseases, Imperial College London, London, UK

² Institute of Infectious Diseases and Molecular Medicine, Wellcome Centre for Infectious Diseases Research in Africa, University of Cape Town, Cape Town, South Africa

³ Department of Microbiology, University of Colombo, Colombo, Sri Lanka

Title

The title needs to convey that this is new onset transaminitis attributed to tuberculosis prior to commencement of anti tubercular therapy

Background

Please outline the baseline work up for TB in programmatic setting in Nepal. Do all patients have baseline LFTs done?

Case presentation

Has this patient had normal LFTs recorded prior to current TB presentation?

Mention drug history incl. paracetamol, aflatoxin exposure, family history of liver disease. The liver screen is incomplete - e.g. autoimmune and inherited liver disease, paracetamol levels, ferritin, occult hep B. Also liver fibrosis assessment.

Baseline GGT and clotting needs to be given.

Please give a table of ALT, AST, GGT, Alk phos, Albumin and clotting during first 2 weeks of treatment (and any further tests during 6 months of treatment)

Of note, there is no clear evidence of disseminated miliary TB on CXR. Abdominal or liver CT was not done. Hence, no comment can be made regarding liver/splenic micronodular abscesses. It appears no mycobacterial blood cultures were taken to assess for bacteraemia. Nor was a liver biopsy done. All relevant negatives and limitations should be mentioned.

When was she discharged? Considering she was never symptomatic from the point of view of GI/hepatobiliary system, was there no further blood work to monitor LFTs since discharge?

Discussion

Briefly explain classifications of liver TB

e.g. Reed, Alvarez, Levine.

The authors do not clearly say what clinical, biochemical, radiological and histopathological presentation would be seen with disseminated TB involving liver.

This case does not clearly illustrate steps to confirm a transaminitis secondary disseminated miliary TB.

The implications of this case report would have greater impact and relevance for practitioners in the context of a case series or retrospective cohort¹ and the authors should consider doing this. Further discussion is needed of considerations such as potentiated toxicity with pharmacogenomic factors e.g. slow acetylators, the need for individualized monitoring e.g. therapeutic drug monitoring.

How long should these patients have monitoring of their LFTs? Is there are risk of paradoxical reactions?

Reference

European Respiratory Journal 2018 52: Suppl. 62, PA4771¹.

References

1. Hepatic tuberculosis – a case series. *European Respiratory Journal*. 2018. [Publisher Full Text](#) |

Reference Source

Is the background of the case's history and progression described in sufficient detail?

Partly

Are enough details provided of any physical examination and diagnostic tests, treatment given and outcomes?

Partly

Is sufficient discussion included of the importance of the findings and their relevance to future understanding of disease processes, diagnosis or treatment?

Partly

Is the case presented with sufficient detail to be useful for other practitioners?

No

Competing Interests: No competing interests were disclosed.

Reviewer Expertise: Management of HIV/tuberculosis; PK/PD for tuberculosis

I confirm that I have read this submission and believe that I have an appropriate level of expertise to confirm that it is of an acceptable scientific standard, however I have significant reservations, as outlined above.

Author Response 10 Oct 2020

Sudeep Adhikari, Patan Academy of Health Sciences, Lalitpur, Nepal

We would like to whole-heartedly thank you for spending so much time and effort to improve our manuscript. Here below is the point by point response.

The title needs to convey that this is new onset transaminitis attributed to tuberculosis prior to commencement of anti tubercular therapy

Response: Title has been modified. Thank you

Background Please outline the baseline work up for TB in programmatic setting in Nepal. Do all patients have baseline LFTs done?

Response: Programmatic setting does not require any baseline workup except sputum smear and in chest Xray. But in hospital setting, we perform baseline blood investigations like blood counts, renal function, electrolytes and liver function tests before starting treatment, so that treatment can be modified accordingly. Changes have been made in the background section.

Case presentation

Has this patient had normal LFTs recorded prior to current TB presentation?

Response: No prior LFT testing was done by the patient

Mention drug history incl. paracetamol, aflatoxin exposure, family history of liver disease.

Text has been modified to state the fact. Thank you

The liver screen is incomplete - e.g. autoimmune and inherited liver disease, paracetamol levels, ferritin, occult hep B. Also liver fibrosis assessment. Baseline GGT and clotting needs to be given. Please give a table of ALT, AST, GGT, Alk phos, Albumin and clotting during first 2 weeks of treatment (and any further tests during 6 months of treatment) Of note, there is no clear evidence of disseminated miliary TB on CXR. Abdominal or liver CT was not done. Hence, no comment can be made regarding liver/splenic micronodular abscesses. It appears no mycobacterial blood cultures were taken to assess for bacteraemia. Nor was a liver biopsy done. All relevant negatives and limitations should be mentioned.

Response: The liver disease screen is incomplete as the reviewer pointed out. However, because of resource limitation and financial constraints, it is not usually possible to perform full liver disease screening in Nepal. So we usually opt for limited screen, and rely more on history, physical examination and initial limited investigations. Then we perform further tests only if the initial workup hints towards another etiology. Text has been modified to include investigations and other limitations.

When was she discharged?

Response: She was discharged after 1 week after becoming afebrile and improvement in transaminases.

Considering she was never symptomatic from the point of view of GI/hepatobiliary system, was there no further blood work to monitor LFTs since discharge?

Response: LFT was repeated first at 1 week before discharge, then at 2 months follow up after discharge.

Discussion: Briefly explain classifications of liver TB e.g. Reed, Alvarez, Levine. The authors do not clearly say what clinical, biochemical, radiological and histopathological presentation would be seen with disseminated TB involving liver. This case does not clearly illustrate steps to confirm a transaminitis secondary disseminated miliary TB.

Response: Text has been modified to include further discussion. Thank you

The implications of this case report would have greater impact and relevance for practitioners in the context of a case series or retrospective cohort and the authors should consider doing this.

Response: Yes we hope further case reports and case series would be published in future, and we look forward to do case series and we have included this notion in the ms. Thank you.

Further discussion is needed of considerations such as potentiated toxicity with pharmacogenomic factors e.g. slow acetylators, the need for individualized monitoring e.g. therapeutic drug monitoring.

Response: Further discussion has been added. Unfortunately such therapeutic drug monitoring is not widely available in Nepal.

How long should these patients have monitoring of their LFTs? Is there are risk of paradoxical reactions?

Unlike Drug induced liver injury, there is no specific monitoring protocols for patients described in our case. The monitoring should be done till the deranged tests normalize and patient becomes clinically well. We have not encountered paradoxical reactions so far.

Competing Interests: none

Reviewer Report 15 September 2020

<https://doi.org/10.21956/wellcomeopenres.17759.r40181>

© 2020 Dhungana A et al. This is an open access peer review report distributed under the terms of the [Creative Commons Attribution License](#), which permits unrestricted use, distribution, and reproduction in any medium, provided the original work is properly cited.

**Prajowl Shrestha**

Department of Medicine, National Academy of Medical Sciences, Bir Hospital, Kathmandu, Nepal

Ashesh Dhungana 

Department of Medicine, National Academy of Medical Sciences, Bir Hospital, Kathmandu, Nepal

Title: The title is unclear as to whether the transaminitis in the index patient is caused by tuberculosis (as proposed by the authors in the subsequent report) or a consequence of other coexisting condition. The title needs to be rephrased as to impart a message that the authors want to convey

Abstract:

- The authors describe a patient with pulmonary tuberculosis and raised liver enzymes (Transaminases). They do mention that the patient did not have any preexisting liver disease or drug use, but do not mention how they systematically ruled out other causes of transaminitis (other non A-E viral hepatitis like GBV, Hep G, EBV, TT virus and other tropical infections).

References: DOI: 10.5812/hepatmon.18865¹; Alter HJ, Bradley DW. Non-A, non-B hepatitis unrelated to the hepatitis C virus (non ABC) Semin Liver Dis 1995; 15:110-120²; Current Opinion in Infectious Diseases: October 2002 - Volume 15 - Issue 5 - p 529-534³.

- "In this report, we gave full dose standard antitubercular drugs, and the liver injury resolved evidenced by normalization of transaminases". The authors should make their message more clear to "presence of transaminitis with no obvious common underlying etiology may not warrant a modification of standard antitubercular regimen"

Case report

1. Evaluation of patient: Diagnostic work-up is incomplete and should also include evaluation for degree of hepatocellular injury. Prothrombin time is not mentioned, GGT levels not mentioned, Serum globulin levels not mentioned (hepatic TB has inverted albumin to globulin ration), imaging was limited (only USG performed, CT not done), liver biopsy not performed. More investigations should have been performed to rule out underlying chronic liver diseases: Fibroscan, upper GI endoscopy for Portal HTN)

2. Figure 1: The quality of the image is suboptimal. The entire bony cage is not visible. Right costophrenic angle is not visible. Finding of hyperinflated lung fields and blunting of left CP angle are not described. Did the patient have underlying obstructive airway disease? If so did she also have pulmonary hypertension?. Could hepatic congestion due to RHF explain the raised liver enzymes?
3. Follow up: The patient improved significantly at 1 month follow up. It would be desirable to have a complete follow up of the patient with evaluation of liver enzymes at least once during treatment as patient initially also did not have any liver specific symptoms.

Discussion:

1. The authors argue that the patient did not have underlying liver disease or liver involvement due to tuberculosis as there was no features of Granuloma and cholestatic pattern of liver enzyme elevation. To ascribe the transaminitis to be caused by TB would be an arbitrary statement especially in the absence of liver biopsy.
2. The authors mention that they have found many patients of pulmonary TB to have predominant transaminitis and without any preexisting liver disease in their experience. Such statement is not backed by any formal data.
3. The authors conclude that pulmonary TB was the cause of transaminitis in their patient, not hepatic TB or underlying liver disease. In the absence of complete workup, such strong conclusions should not be made.

Conclusion

The authors recommend use of full dose standard ATT for patients with transaminitis and no underlying liver disease. This recommendation should not be made based on a single case report.

Opinion:

The case report describes a common scenario especially in low income countries while treating patients with tuberculosis. The availability of resources limit the diagnostic workup of such patients in our settings. I opine that this case report is suitable for indexing with modifications.

References

1. Wang C, Li Y, Shen C: Epstein-Barr Virus Infection Mimicking Drug-Induced Hepatitis in a Critically ill Patient During Antituberculosis Therapy. *Hepatitis Monthly*. 2014; **14** (9). [Publisher Full Text](#)
2. Alter HJ, Bradley DW: Non-A, non-B hepatitis unrelated to the hepatitis C virus (non-ABC). *Semin Liver Dis*. 1995; **15** (1): 110-20 [PubMed Abstract](#) | [Publisher Full Text](#)
3. Narayanan Menon KV: Non-A to E hepatitis. *Current Opinions in Infectious Diseases*. 2002; **15** (5): 529-534 [Reference Source](#)

Is the background of the case's history and progression described in sufficient detail?

Yes

Are enough details provided of any physical examination and diagnostic tests, treatment given and outcomes?

Partly

Is sufficient discussion included of the importance of the findings and their relevance to future understanding of disease processes, diagnosis or treatment?

Partly

Is the case presented with sufficient detail to be useful for other practitioners?

Partly

Competing Interests: No competing interests were disclosed.

Reviewer Expertise: Tuberculosis, Interventional Pulmonology, ILD

We confirm that we have read this submission and believe that we have an appropriate level of expertise to confirm that it is of an acceptable scientific standard, however we have significant reservations, as outlined above.

Author Response 10 Oct 2020

Sudeep Adhikari, Patan Academy of Health Sciences, Lalitpur, Nepal

We would like to whole-heartedly thank you for spending so much time and effort to improve our manuscript. Here below is the point by point response.

Title: The title is unclear as to whether the transaminitis in the index patient is caused by tuberculosis (as proposed by the authors in the subsequent report) or a consequence of other coexisting condition. The title needs to be rephrased as to impart a message that the authors want to convey

Response: Title has been modified to make our message clearer. Thank you

Abstract: The authors describe a patient with pulmonary tuberculosis and raised liver enzymes (Transaminases). They do mention that the patient did not have any preexisting liver disease or drug use, but do not mention how they systematically ruled out other causes of transaminitis (other non A-E viral hepatitis like GBV, Hep G, EBV, TT virus and other tropical infections). ○ **References:**

DOI: 10.5812/hepatmon.188651; Alter HJ, Bradley DW. Non-A, non-B hepatitis unrelated to the hepatitis C virus (non ABC) Semin Liver Dis 1995; 15:110-1202; Current Opinion in Infectious Diseases: October 2002 - Volume 15 - Issue 5 - p 529-5343.

Testing of other viruses were not done due to unavailability. Since raised transaminases resolved after starting ATT we assumed tuberculosis was most likely explanation.

“In this report, we gave full dose standard antitubercular drugs, and the liver injury resolved evidenced by normalization of transaminases”. The authors should make their message more clear to “presence of transaminitis with no obvious common underlying etiology may not warrant a modification of standard antitubercular regimen”

Response: Text has been modified to make our message clearer. Thank you

Case report Evaluation of patient: Diagnostic work-up is incomplete and should also include evaluation for degree of hepatocellular injury. Prothrombin time is not mentioned, GGT levels not mentioned, Serum globulin levels not mentioned (hepatic TB has inverted albumin to globulin ration), imaging was limited (only USG performed,

CT not done), liver biopsy not performed. More investigations should have been performed to rule out underlying chronic liver diseases: Fibroscan, upper GI endoscopy for Portal HTN)

Response: The liver disease screen is incomplete as the reviewers pointed out. However, because of resource limitation and financial constraints, it is not usually possible to perform full liver disease screening in Nepal. So we usually opt for limited screen, and rely more on history, physical examination and initial limited investigations. Then we perform further tests only if the initial workup hints towards another etiology. Text has been modified to include further lab reports. The limitations have been acknowledged.

Figure 1: The quality of the image is suboptimal. The entire bony cage is not visible. Right costophrenic angle is not visible. Finding of hyperinflated lung fields and blunting of left CP angle are not described. Did the patient have underlying obstructive airway disease? If so did she also have pulmonary hypertension?. Could hepatic congestion due to RHF explain the raised liver enzymes?

Response: There was no history of underlying lung disease. Although echocardiography was not done hepatic congestion due to RHF is unlikely as there was no suggestive history and examination findings and patient responded without any diuretics or fluid restrictions.

Follow up: The patient improved significantly at 1 month follow up. It would be desirable to have a complete follow up of the patient with evaluation of liver enzymes at least once during treatment as patient initially also did not have any liver specific symptoms.

Response: Text has been modified to include follow up reports. LFT was repeated first at 1 week before discharge, then at 2 months follow up after discharge.

Discussion:

The authors argue that the patient did not have underlying liver disease or liver involvement due to tuberculosis as there was no features of Granuloma and cholestatic pattern of liver enzyme elevation. To ascribe the transaminitis to be caused by TB would be an arbitrary statement especially in the absence of liver biopsy.

Response: Imaging and further investigations were limited, so hepatic tuberculosis could not be ruled out with certainty especially without biopsy of liver. However this would not make much difference. Because even if the diagnosis of hepatic tuberculosis had been considered in our patient, the management would be the same, i.e. with standard ATT as we did in our patient. The point we wanted to make here is that modification in treatment may not be required in the absence of pre-existing liver disease. Text has been modified to include the limitations. Thank you

The authors mention that they have found many patients of pulmonary TB to have predominant transaminitis and without any preexisting liver disease in their experience. Such statement is not backed by any formal data.

Response: We need more data but unfortunately not much is being published from low middle income countries even for endemic diseases like tuberculosis. There is no formal data to back up our claim, and this has been acknowledged as limitation.

The authors conclude that pulmonary TB was the cause of transaminitis in their patient, not hepatic TB or underlying liver disease. In the absence of complete workup, such strong conclusions should not be made.

Response: Due to rapid resolution of raised transaminases after starting ATT, preexisting liver disease would be unlikely cause. Although hepatic tb is a possibility, it was our opinion that standard dose ATT can be safely started in the patient and further imaging would not

be cost effective in terms of treatment. We agree with the reviewer that the strong conclusions are not justified due to incomplete workup and this section has been toned down and modified to highlight the limitations. Thank you

Conclusion The authors recommend use of full dose standard ATT for patients with transaminitis and no underlying liver disease. This recommendation should not be made based on a single case report.

Response: We agree. Text have been modified to include our limitations. Thank you.

Opinion: The case report describes a common scenario especially in low income countries while treating patients with tuberculosis. The availability of resources limit the diagnostic workup of such patients in our settings. I opine that this case report is suitable for indexing with modifications.

Response: Thank you

Competing Interests: none

Reviewer Report 27 August 2020

<https://doi.org/10.21956/wellcomeopenres.17759.r39997>

© 2020 Neelakantan V. This is an open access peer review report distributed under the terms of the [Creative Commons Attribution License](#), which permits unrestricted use, distribution, and reproduction in any medium, provided the original work is properly cited.



Vivek Neelakantan 

Independent Medical Historian, Mumbai, India

Title:

Drug-resistant TB is a hot topic in medicine today. Research on TB treatment-associated transaminitis would further the existing scholarly understanding on drug-resistant TB. A close keyword search on PubMed revealed only 17 hit on TB AND transaminitis. For this reason, the case report is potentially publishable but suffers from several drawbacks in its current draft that must be remedied before the contribution is re-refereed.

But the title itself is unclear. "With" is repeated twice. It is not clear to a medical historian what transaminitis is. A better framing of the title is urgently needed. A cogent argument can be organised around the title. What is four-drugs therapy? It is clear to medical practitioners but not clear to the larger scholarly community. Avoid jargons in the title.

- 1) What is transaminitis? Why not provide a brief explanation at the start so that the general reader can follow the rest of the article.
- 2) The two levels of transaminitis:
 - (a) pre-existing liver disease leads to transaminitis.
 - (b) Hepatotoxicity of anti-TB drugs.

This needs to be made explicit in the very beginning. The authors have not been explicit about the two levels of transaminitis and that is where the problem begins.

"While encountering such patients, it is important to differentiate if the patient had pre-existing liver disease or if the present infection with tuberculosis has impacted on the liver, as the approach to management differs given the hepatotoxicity associated with first line drugs."

Rewrite this sentence. Make more explicit.

Summary and Abstract:

The writers present a case of pulmonary TB with transaminitis without pre-existing liver damage. The therapeutic regimen of the authors included anti-TB drugs and liver injury resolved evidenced by normalization of transaminase.

The abstract merits rewriting for clarity.

Background:

Background: Needs to sketch out the larger socio-economic picture of TB patients in Nepal. Medicine for whom?

Case Presentation: How do you define compliance with TB treatment? How socio-economic factors militate against the successful completion of treatment?

Specific quote from the report: "In our anecdotal experience, we have found many patients with pulmonary tuberculosis, similarly to subject of this case report, present with predominant transaminitis and without pre-existing liver disease or drugs-use. They are often managed with modified liver-friendly antitubercular regimens for fear of increasing the hepatotoxicity and causing acute liver failure with the use of standard regimen. Few case reports are available in literature reporting the use of the modified regimens^{7,8}. We believe such cases are underreported, and firm guidelines have not been established to guide clinicians in these cases. Given this, many clinicians in low-middle income countries, including Nepal, who have been treating tuberculosis patients tend to be skeptical in using full doses of first line ATT in such patients and tend to use a modified regimen. However, this practice may potentially lead to under-treatment and therefore increase fatality⁹. Though there was some hesitation at first in our case, we soon started treatment with the standard ATT in our patient with close monitoring. This we believe led to the resolution of liver injury, evidenced by the normalization of transaminases."

What is your sample size? Unclear. What guidelines can be established with the aid of the study?" Make explicit and elaborate.

Conclusion:

The report lacks an inevitable conclusion.

The conclusion needs to point to the "so what" question? So, what are the implications of this study? What protocols could be devised? How does this case history further medical practitioners' as well as policymakers' understanding of drug-resistant TB?

Other points:

Please make sure that the manuscript is thoroughly copyedited for legibility of prose, clarity of

argument, and grammar.

The social context of TB in Nepal merits attention (alcoholism is a contributing factor).

You need to compare transaminitis with case studies from other countries. Carefully refer to the PLoS

One article below:

Murphy, Richard A., Vincent C. Marconi, Rajesh T. Gandhi, Daniel R. Kuritzkes, and Henry Sunpath. "Coadministration of lopinavir/ritonavir and rifampicin in HIV and tuberculosis co-infected adults in South Africa." *PLoS One* 7, no. 9 (2012): e44793¹.

Sarda, Pawan, S. K. Sharma, Alladi Mohan, Govind Makharia, Arvind Jayaswal, R. M. Pandey, and Sarman Singh. "Role of acute viral hepatitis as a confounding factor in antituberculosis treatment induced hepatotoxicity." *Indian Journal of Medical Research* 129, no. 1 (2009): 64².

How does your case differ from the 2 references mentioned above?

References

1. Murphy RA, Marconi VC, Gandhi RT, Kuritzkes DR, et al.: Correction: Coadministration of Lopinavir/Ritonavir and Rifampicin in HIV and Tuberculosis Co-Infected Adults in South Africa. *PLoS One*. 2013; **8** (12). [PubMed Abstract](#) | [Publisher Full Text](#)
2. Sarda P, Sharma SK, Mohan A, Makharia G, et al.: Role of acute viral hepatitis as a confounding factor in antituberculosis treatment induced hepatotoxicity. *Indian J Med Res*. 2009; **129** (1): 64-7 [PubMed Abstract](#)

Is the background of the case's history and progression described in sufficient detail?

No

Are enough details provided of any physical examination and diagnostic tests, treatment given and outcomes?

Yes

Is sufficient discussion included of the importance of the findings and their relevance to future understanding of disease processes, diagnosis or treatment?

Yes

Is the case presented with sufficient detail to be useful for other practitioners?

No

Competing Interests: No competing interests were disclosed.

Reviewer Expertise: History of Tuberculosis, Global Health, South and Southeast Asia, Medical Humanities

I confirm that I have read this submission and believe that I have an appropriate level of expertise to state that I do not consider it to be of an acceptable scientific standard, for

reasons outlined above.

Author Response 10 Oct 2020

Sudeep Adhikari, Patan Academy of Health Sciences, Lalitpur, Nepal

We would like to whole-heartedly thank you for spending so much time and effort to improve our manuscript. Here below is the point by point response.

Title: Drug-resistant TB is a hot topic in medicine today. Research on TB treatment-associated transaminitis would further the existing scholarly understanding on drug-resistant TB. A close keyword search on PubMed revealed only 17 hit on TB AND transaminitis. For this reason, the case report is potentially publishable but suffers from several drawbacks in its current draft that must be remedied before the contribution is re-refereed. But the title itself is unclear. "With" is repeated twice. It is not clear to a medical historian what transaminitis is. A better framing of the title is urgently needed. A cogent argument can be organised around the title. What is four-drugs therapy? It is clear to medical practitioners but not clear to the larger scholarly community. Avoid jargons in the title. 1) What is transaminitis? Why not provide a brief explanation at the start so that the general reader can follow the rest of the article. 2) The two levels of transaminitis: (a) pre-existing liver disease leads to transaminitis. (b) Hepatotoxicity of anti-TB drugs. This needs to be made explicit in the very beginning. The authors have not been explicit about the two levels of transaminitis and that is where the problem begins. "While encountering such patients, it is important to differentiate if the patient had pre-existing liver disease or if the present infection with tuberculosis has impacted on the liver, as the approach to management differs given the hepatotoxicity associated with first line drugs." Rewrite this sentence. Make more explicit.

Response: Title and text have been modified to make our message clearer. Thank you

Summary and Abstract: The writers present a case of pulmonary TB with transaminitis without pre-existing liver damage. The therapeutic regimen of the authors included anti-TB drugs and liver injury resolved evidenced by normalization of transaminase. The abstract merits rewriting for clarity.

Response: Abstract has been modified to make our message clearer

Background: Needs to sketch out the larger socio-economic picture of TB patients in Nepal. Medicine for whom?

Response: Background has been modified to make it clear. The socioeconomic picture of TB patients in Nepal has been highlighted. In Nepal, tuberculosis prevalence is more in productive age group (25-64 years) and men. Poverty, malnutrition, overcrowding, immunocompromised state like HIV infection, alcohol, smoking, air pollution, diabetes and other comorbidities are important risk factors for acquiring the disease. All patients diagnosed with TB receive treatment as per the national protocol which has been mentioned in the text.

Case Presentation:

How do you define compliance with TB treatment? How socio-economic factors militate against the successful completion of treatment?

Response: To improve the treatment compliance, treatment of TB is done under DOTS program all over Nepal, which stands for 'Directly Observed Treatment Short Course'. Otherwise the compliance would be compromised owing to the lower socioeconomic status of patients, longer duration of therapy and side effects of drugs.

Specific quote from the report: "In our anecdotal experience, we have found many patients with pulmonary tuberculosis, similarly to subject of this case report, present with predominant transaminitis and without pre-existing liver disease or drugs-use. They are often managed with modified liver-friendly antitubercular regimens for fear of increasing the hepatotoxicity and causing acute liver failure with the use of standard regimen. Few case reports are available in literature reporting the use of the modified regimens. We believe such cases are underreported, and firm guidelines have not been established to guide clinicians in these cases. Given this, many clinicians in low-middle income countries, including Nepal, who have been treating tuberculosis patients tend to be skeptical in using full doses of first line ATT in such patients and tend to use a modified regimen. However, this practice may potentially lead to undertreatment and therefore increase fatality⁹. Though there was some hesitation at first in our case, we soon started treatment with the standard ATT in our patient with close monitoring. This we believe led to the resolution of liver injury, evidenced by the normalization of transaminases." What is your sample size? Unclear. What guidelines can be established with the aid of the study?" Make explicit and elaborate

Response: Our opinion is that there are cases of pulmonary tb with some hepatic involvement, which are sometimes being managed with modified regimen when it can be safely managed with standard regimen. Unfortunately very few published research is available from low middle income countries. Text has been edited to include limitation of evidence. This is a case report only and further research is needed.

Conclusion:

The report lacks an inevitable conclusion. The conclusion needs to point to the "so what" question? So, what are the implications of this study? What protocols could be devised? How does this case history further medical practitioners' as well as policymakers' understanding of drug-resistant TB?

Response: Being a case report and paucity of previous research, we have toned down our previous strong conclusions, also as suggested above by another reviewer. We hope that further reports will be published. The use of modified drug regimen excluding more potent drugs, instead of standard regimen may promote drug resistance, and how far such practices are prevalent can be another area of further study.

Other points: Please make sure that the manuscript is thoroughly copyedited for legibility of prose, clarity of argument, and grammar. The social context of TB in Nepal merits attention (alcoholism is a contributing factor). You need to compare transaminitis with case studies from other countries. Carefully refer to the PLoS

Response: Text has been revised to correct errors. Social context of TB in Nepal has been mentioned in the text. Thank you

Murphy, Richard A., Vincent C. Marconi, Rajesh T. Gandhi, Daniel R. Kuritzkes, and Henry Sunpath. "Coadministration of lopinavir/ritonavir and rifampicin in HIV and tuberculosis co-infected adults in South Africa." *PLoS One* 7, no. 9 (2012): e447931.
Sarda, Pawan, S. K. Sharma, Alladi Mohan, Govind Makharia, Arvind Jayaswal, R. M.

Pandey, and Sarman Singh. "Role of acute viral hepatitis as a confounding factor in antituberculosis treatment induced hepatotoxicity." Indian Journal of Medical Research 129, no. 1 (2009): 642. How does your case differ from the 2 references mentioned above?

Response: As compared to first article our patient did not have HIV. As compared to second article, our patient did not have antituberculous drug induced hepatotoxicity but liver injury likely due to tuberculosis itself. Thank you

Competing Interests: none
