


## CLINICAL ARTICLE

# Reconstruction of Large Area of Deep Wound in the Foot and Ankle with Chimeric Anterolateral Thigh Perforator Flap

Run-guang Li, PhD<sup>1,2,3,4,5†</sup> , Can-jun Zeng, MD<sup>1,2,3,4†</sup>, Song Yuan, MD<sup>5</sup>, Ji-jie Hu, MD<sup>6,7</sup>, Ping Zhang, BD<sup>6,7</sup>, Yun-biao Chen, BD<sup>6,7</sup>, Shan-wen Zhao, BD<sup>1,2,3,4</sup>, Gao-hong Ren, PhD<sup>6,7</sup>

<sup>1</sup>Department of Foot and Ankle Surgery, Center for Orthopaedic Surgery, the Third Affiliated Hospital of Southern Medical University, <sup>2</sup>Orthopaedic Hospital of Guangdong Province, <sup>3</sup>Academy of Orthopaedics, Guangdong Province, <sup>4</sup>Guangdong Provincial Key Laboratory of Bone and Joint Degenerative Diseases and <sup>6</sup>Division of Orthopaedics and Traumatology, Department of Orthopaedics and <sup>7</sup>Guangdong Provincial Key Laboratory of Bone and Cartilage Regenerative Medicine, Nanfang Hospital, Southern Medical University, Guangzhou and <sup>5</sup>Department of Orthopedics, Linzhi People's Hospital, Linzhi, China

**Objective:** To evaluate the clinical application and surgical efficacy of the chimeric perforator flap pedicled with the descending branch of the lateral circumflex femoral artery and the lateral thigh muscle flap for the reconstruction of the large area of deep wound in foot and ankle.

**Methods:** Clinical data of 32 cases who underwent chimeric anterolateral thigh perforator flap to repair the large area of deep wound of the foot and ankle from January 2015 to December 2018 were retrospectively analyzed. The sizes of the defects ranged from 18 cm × 10 cm to 35 cm × 20 cm, with exposed tendon and bone and/or partial defects and necrosis, contaminations, accompanied by different degrees of infection. Following the radical debridement and VSD, chimeric anterolateral thigh perforator flap was employed to repair the deep wounds according to the position, site and deep-tissue injury of the soft-tissue defects. The skin flap and muscle flap were fanned out on the wound, and single- or two-staged split-thickness skin grafting was performed on the muscle flap. The operation time and blood loss were recorded. The survival and healing conditions of the operational site with chimeric anterolateral thigh perforator flap were evaluated post-operationally. Complications at both recipient site and donor site were carefully recorded.

**Results:** The mean time of the operation was 325.5 min and average blood loss was 424.8 mL. Among the 32 cases, two cases developed vascular crisis, which were alleviated with intensive investigation and treatment; Four cases suffered from partial necrosis of the flap or skin graft on the muscle flap or on the residual local wound, which were improved after treatment of further dressing change and skin grafting. Another four cases experienced post-traumatic osteomyelitis accompanied by bone defect were treated with simple bone grafting or Mesquite bone grafting at 6–8 months after wound healing. Postoperatively, the wounds were properly healed, and the infection was effectively controlled without sinus tract forming. Overall, all 32 cases received satisfactory efficacy, without influencing subsequent functional reconstruction, and observed infection during the 12–36 months post-operational follow-up.

**Conclusion:** The chimeric perforator flap pedicled with the descending branch of the lateral circumflex femoral artery and the lateral thigh muscle flap provides an effective and relative safe procedure for the repair of a large area of deep wound in the foot and ankle, particularly with irregular defect or deep dead space.

**Key words:** Free tissue flaps; Perforator flap; Soft tissue injuries; Wound closure techniques; Transplantation chimera

**Address for correspondence** Gao-hong Ren, PhD, Division of Orthopaedics and Traumatology, Department of Orthopaedics, Nanfang Hospital, Southern Medical University; Key Laboratory of Bone and Cartilage Regenerative Medicine, Nanfang Hospital, Southern Medical University, Guangzhou, China 511700 Tel: 0086-020-62787200; Fax: 0086-020-61641748; Email: doctor020@163.com

**Grant Sources:** This work was supported by Clinical Research Program of Nanfang Hospital, Southern Medical University (2020CR008); Shanghai Wang Zhengguo Trauma Medical Development Foundation (2017KJB-GK-001) and the National Natural Science Foundation of China (81101366), Natural Science Foundation of Guangdong Province (Approval no. 2018A030313640, 2019A1515012176).

<sup>†</sup>These authors contributed equally to this work (Runguang Li and Canjun Zeng).

Received 18 January 2021; accepted 13 April 2021

## Introduction

With the rapid development of industry and transportation, soft-tissue defects of the lower extremities caused by high-energy injuries often occur, especially in the foot and ankle<sup>1,2</sup>. As the skin on the back of the foot is thin, with less subcutaneous fat, while the cuticle on the plantar is thick, tough, compressive and wear-resistant, the soft tissue of the foot varies in thickness due to different parts, the incidence of open injuries is constantly complicated with the exposure of deep tissues, such as bone joints and tendons. A large deep wound in the foot and ankle, severely damaged superficial blood vessels and unclear boundaries of tissue damage often affect the early repair and reconstruction of the injuries. Foot and ankle functions to bear weight and wear shoes, which demand optimal reconstruction of wound in the foot and ankle are not only a simple wound coverage, but also a functional reconstruction, while the exposed deep tissues at the distal end of the foot make it difficult to transfer the local flap to the lower leg<sup>3</sup>. These characteristics of the large deep wound in the foot and ankle bring difficulties to the repair and reconstruction procedures. Due to the limited area of the flap that can be harvested at the donor site, it is difficult for conventional local flap to transfer or free flap completely to reconstruct the wound. For instance, Lee *et al.*<sup>4</sup> have found that flap complications can be independently predicted by the increasing flap size. Specifically, a flap size larger than 250 cm<sup>2</sup> would significantly increase the flap failure and complications. Moreover, if multiple flaps and anastomosed vessels are needed, the surgical risk and donor site injury will be significantly aggravated<sup>5,6</sup>.

In a previous study, we adopted thoughtfully debridement and vacuum sealing drainage for the treatment of large wounds complicated with deep tissue exposure after severe trauma. Waiting until fresh granulation tissues of the wound grew well, we used free flap transplantation combined with simple skin graft to repair the wound and relatively high efficacy was achieved<sup>7,8</sup>. However, there are some disadvantages for this strategy. Specifically, multiple debridement and vacuum sealing drainage are required until the growth of fresh granulation tissues to create a suitable environment for skin grafting, which usually takes a long time. Unfortunately, long-term exposure of deep tissues will also aggravate the infection of foot and ankle joints. Furthermore, to obtain better foot and ankle functions including movement, weight bearing and shoes-wearing, etc., the use of simple skin grafting on the deep wound should be minimized. Some studies<sup>9,10</sup> have reported that free flaps or transferred local flaps are often pedicled with an appropriate amount of muscle flaps to fill the infectious space after severe limb injuries, which plays a vital role in infection control. To decrease the limitations of our previous methods, chimeric anterolateral thigh perforator flap (the chimeric perforator flap pedicled with the descending branch of the lateral circumflex femoral artery and the lateral thigh muscle flap) was adopted to reconstruct a large deep wound of the foot and ankle after debridement and effective vacuum sealing drainage. In

addition to harvesting one or more leaves of perforator flaps, multiple levels of muscle flaps were also excised, which were spread out in a fan shape to repair the wound. Furthermore, simultaneous or staged skin grafting was conducted on the muscle flap to reduce the cut-off area of the free flap, to minimize the wound of direct skin grafting, and to ultimately reduce the surgical risk and restore better functions of the foot and ankle.

The chimeric perforator flap with the descending branch of lateral circumflex femoral artery is a special type of perforator flap. It also has the following advantages. Only one group of blood vessels need to be anastomosed to reconstruct the blood circulation of multiple independent tissue flaps at the same time. The advantages of good blood supply and strong anti-infection ability of the myocutaneous flap are retained, and the local blood circulation can be improved after transplantation. Both the perforator flap and muscle flap have enough free vascular pedicle length. The lateral thigh muscle flap has strong shaping ability. It can effectively fill the irregular dead space and cover all kinds of wounds freely. In this investigation, 32 cases that underwent chimeric anterolateral thigh perforator flap to reconstruct large deep wound of the foot and ankle from January 2015 to December 2018 were collected and retrospectively analyzed. The aim of this study was to: (i) functionally and aesthetically repair large area of deep wound in the foot and ankle; (ii) assess the feasibility and reliability of this method; (iii) list key surgical points; and (iv) provide the basis for further study.

## Patients and Methods

This was a retrospective review, and the analysis was approved by Southern Medical University institutional review board.

### Inclusion and exclusion criteria

Inclusion criteria: (i) large area of soft tissue defect and deep tissue exposure after debridement of foot and ankle trauma; (ii) patients who have undergone reconstruction with the chimeric perforator flap pedicled with the descending branch of the lateral circumflex femoral artery and the lateral thigh muscle flap; (iii) no injury or lesion in one of the thighs; (iv) postoperative follow-up term of at least 1 year; (v) a retrospective study; and patients with no serious underlying disease.

Exclusion criteria: (i) lost patients; (ii) cross leg flap (the contralateral blood vessels in the donor site were used); (iii) previous flap surgery had failed; (iv) recurrent osteomyelitis and severe infectious bone defects; and (v) patients with serious underlying disease.

### Patient Data

A total of 32 cases (followed up completely) with large wound in the foot and ankle included, there were 21 men and 11 women, mean (range) age 35.5 (12–66) years. The mechanisms of injury were traffic accidents ( $n = 22$ ), falling ( $n = 6$ ) and crush injury ( $n = 4$ ). The sizes of the defects

ranged from 18 cm × 10 cm to 35 cm × 20 cm, with exposed tendon and bone and/or partial defects and necrosis, contaminations, accompanied by different degrees of infection. Moreover, 21 cases were complicated with ipsilateral foot and ankle fractures, and eight cases were complicated with other bone fractures or other system injuries. There was no long-term history of smoking or vascular disease in any of the cases.

### **Preoperative Treatments**

Broad-spectrum antibiotics were administered during the early stage to all of them. According to our previous methods<sup>7,8,11,12</sup>, early debridement was carried out to remove the foreign debris and ischemic inactivated tissues as much as possible. Simple internal or external fixation was performed to reconstruct the bone, with appropriate repair on the deep injured tissues (tendons, nerves, etc.). Vacuum sealing drainage was applied to temporarily cover the wound. Following in the wound debridement, the chimeric perforator flap pedicled with the descending branch of the lateral circumflex femoral artery and the lateral thigh muscle flap was adopted to repair the lager wound.

### **Surgical Techniques**

Patients were required to lay in a supine position under general anesthesia or combined spinal-epidural anesthesia. The anterolateral thigh flap was designed according to the methods proposed by Luo *et al.*<sup>13</sup> and Lee *et al.*<sup>14</sup>, and the inner margin of the flap was incised, and each perforator vessel of the flap was identified under the skin or fascia lata. The descending branch of the lateral circumflex femoral artery was located between the rectus femoris and the lateral thigh muscle. With the identification of each musculocutaneous vessel connecting the flap, the perforating vessels were separated and their dominating flaps were dissected in a combined forward and reverse manner. According to the type of vascular nutrition of muscle flap<sup>15</sup>, thin layers of the muscle flaps were cut off in the control range of nutrient vessels. Finally, a chimeric ramified skin flap and muscle flap (one or more leaves of skin flaps or muscle flaps) were created. Their vessels for nutrient supplies were stemmed from the descending branch of the lateral circumflex femoral artery. Upon hemostasis of the muscle flap, ligation and cutting off vascular pedicle prepared for subsequent use. After thorough debridement at the acceptor site, the harvested chimeric flaps were spread out in a fan shape to repair the wound with deep tissue exposure. When ensuring the reach of the vascular pedicle of the flap to the anastomosis site of the vessels at the acceptor site, intermittent suture and fixation flap were performed. The vessels at the donor site were anastomosed end-to-end or end-to-side with the posterior or anterior tibial vessels at the acceptor site. Suturing was performed according to the arteriovenous ratio of 1:2, while healthy superficial vein was initially sutured. The exposed

surface of muscle flap was covered by skin graft, which was bandaged or covered by negative pressure (Fig. 1).

### **Postoperative Treatments**

Postoperatively, intensive observation and necessary brake should be carried out. Conventional microsurgical methods, such as anti-inflammation, anti-spasm and anti-coagulation were delivered as needed. The blood supply to the flap was closely monitored, while vascular crisis or other complications being effectively treated in a timely manner. During the negative pressure therapy in the skin grafting area on the muscle flap, the unobstructed vacuum sealing drainage should be maintained. The negative pressure should not be excessively high to prevent flap from compression. The negative pressure of free skin grafting site was removed at postoperative 7–8 days. According to the conditions of wound repair and fracture fixation, active and passive rehabilitation exercise were recommended and required at the early stages after the surgery.

### **Evaluation of Complications and Outcomes**

#### *Intraoperative*

The operation time and blood loss were recorded.

#### *Complications*

Complications at both recipient site and donor site were carefully recorded, including flap or skin graft necrosis, infection, vascular crisis, and delayed wound healing.

#### *Clinical Outcomes*

The survival and infection of flaps were evaluated postoperatively. During follow-up, the appearance and function of the affected limbs were observed.

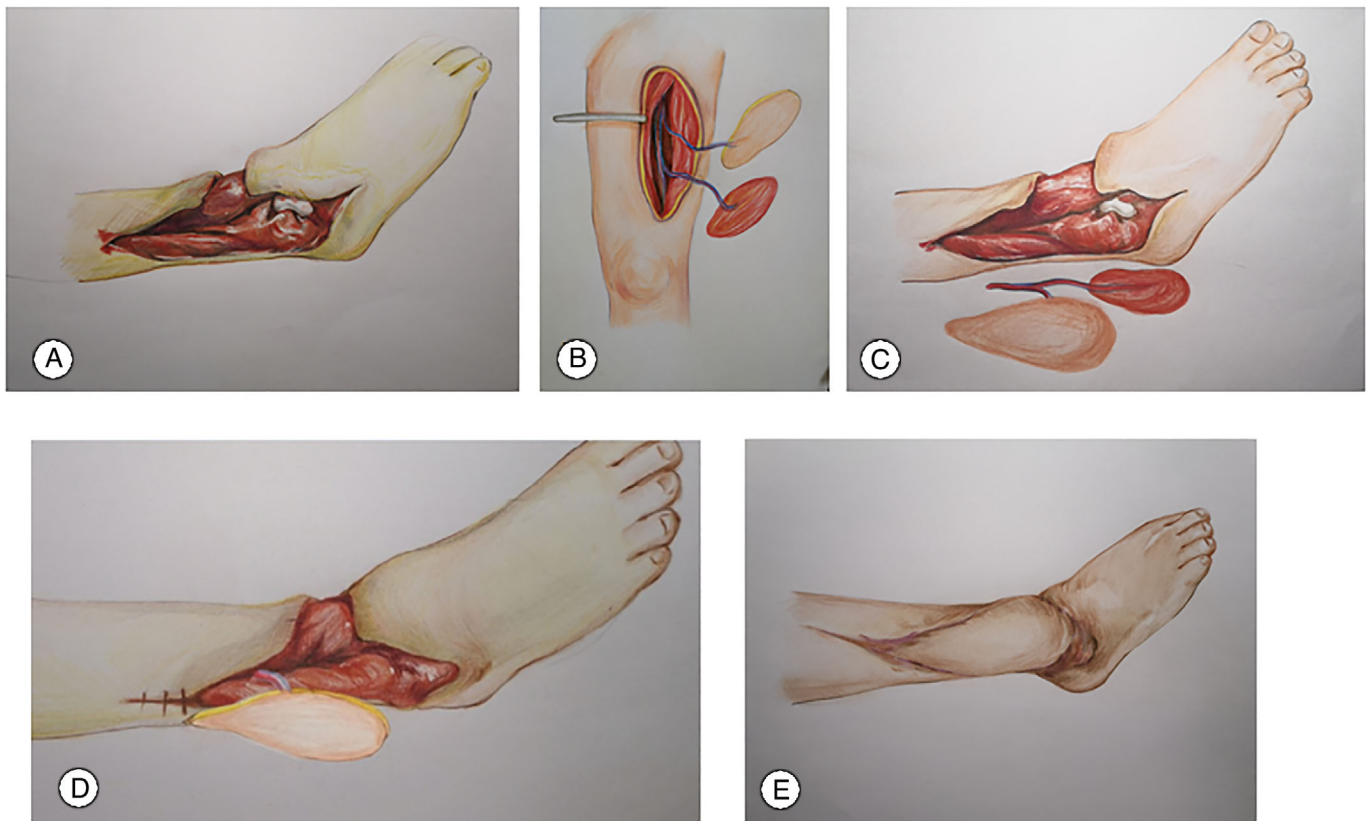
## **Results**

### **Demographics**

These 32 patients were systematically followed up for a mean of 20.3 months (range, 12–36 months). There were 21 men and 11 women, mean (range) age 35.5 (12–66) years. Of the 32 cases, 12 cases received emergency treatment in our hospital and 20 cases were transferred from local hospitals.

### **Surgery and Complications**

In this study, 32 with descending branch of lateral circumflex femoral artery and lateral thigh muscle flap were performed, and all the operations were successful. The mean time of the operation was 325.5 min (range, 210–600 min) and average blood loss was 424.8 mL (range, 300–800 mL). The donor sites were primarily closed in 22 cases, and skin grafts were performed in 10 cases. Among the 32 cases, two cases flap developed vascular crisis, which were relieved after exploration treatments. Four cases suffered from partial necrosis of the flap or skin graft on the



**Fig. 1** Diagram illustrated the design process of chimeric anterolateral thigh perforator flap for the repair of large area of deep wound in the foot and ankle. (A) Large area of deep wound in the foot and ankle with bone and tendon exposed. (B) Harvested chimeric anterolateral thigh perforator flappedicled with descending branch of lateral circumflex femoral artery. (C) Place the chimeric anterolateral thigh perforator flap near the wound of the foot and ankle. (D) The chimeric flap was used to fan out on the wound, the muscle flap covers the bone exposed wound. (E) The appearance of all wounds reconstructed by the flap and the skin grafting on the muscle flap.

muscle flap or simple skin graft on wound with residual local wound. Of these cases, two cases underwent secondary skin graft and the other two cases received active dressing change to eliminate the wound.

### Outcomes

Postoperatively, the wounds were properly healed and the infection was effectively controlled. Notably, subsequent operations of functional reconstruction were not affected for all 32 cases. Four cases with post-traumatic osteomyelitis accompanied by bone defect were treated with simple bone graft or Mesquite bone graft at 6–8 months after wound healing. During follow-up, no infection was observed and the appearance and function recovery of the affected limbs were satisfactory. Briefly, the appearance of the flaps was satisfactory with nearly normal texture and color. In contrary, the skin color followed by the muscle flap repair was slightly dark, but no abrasion and tear observed in the grafting site which was flexible and elastic.

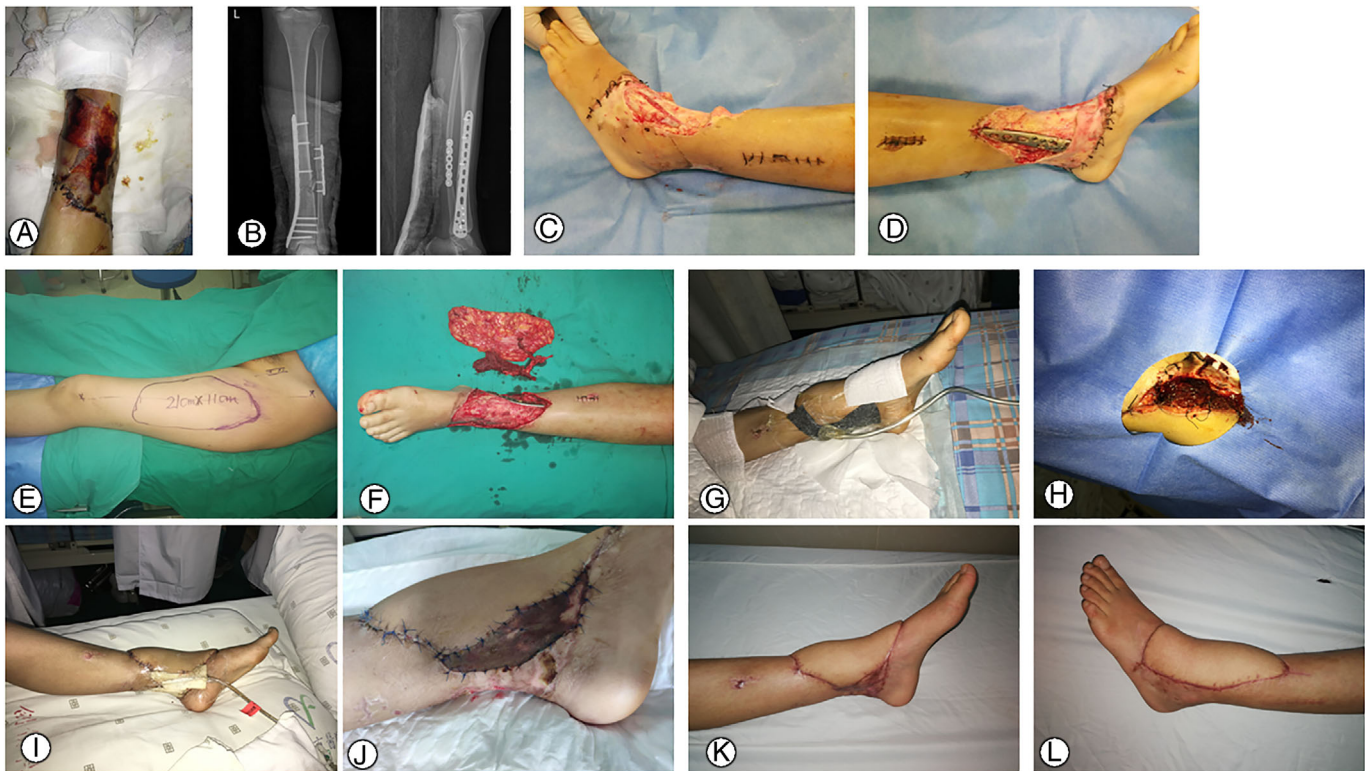### Case Report

Typical cases were shown in Figs 2,3,4.

### Discussion

#### Current Situation of Difficult Treatment for Large Soft Tissue Defect of Foot and Ankle

Most scholars believe that staged reconstruction is a safe and reliable option for the treatment of a large area of soft-tissue defects of the foot and ankle caused by trauma, which is relevant to the complicated local and systemic conditions. However, the timing for delayed repair is still controversial<sup>16,17</sup>. The application of negative pressure wound therapy provides an excellent guarantee for delayed repair of fresh wounds and debridement of infected wounds<sup>18,19</sup>. Nevertheless, this technique can only be used as a temporary wound-covering method without direct blood supply. It is considered as a transitional means due to the potential secondary ischemic necrosis after long-term covering of bone, tendon, nerve and other tissues. Liu *et al.*<sup>17</sup> has reported that vacuum sealing

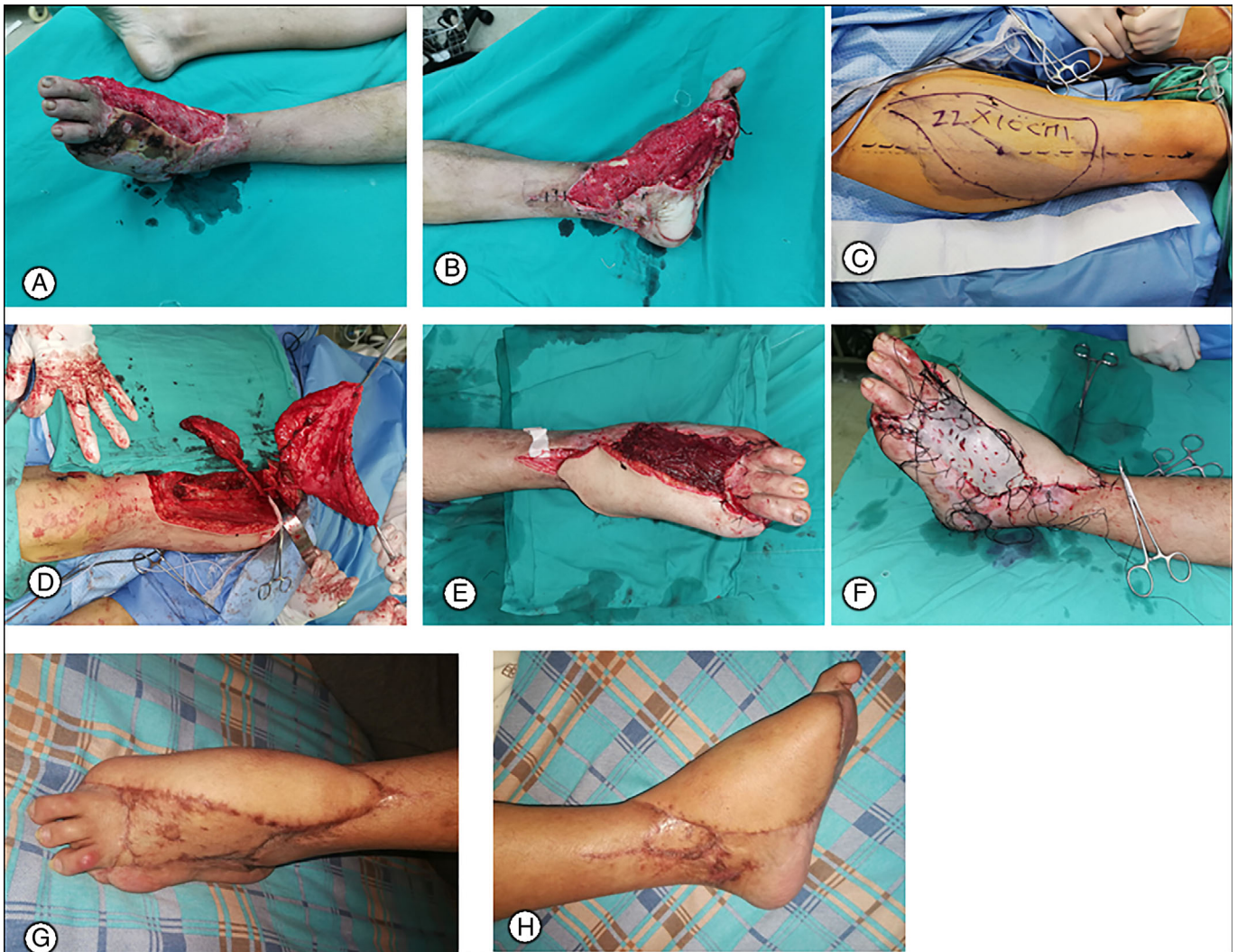

**Fig. 2** Case 1. A 24-year-old female patient with open fracture of distal tibia and fibula complicated with soft-tissue contusion caused by a traffic accident underwent debridement, fracture reduction and internal fixation in a local hospital and wound closure. At postoperative 1 week, she was transferred to our hospital due to secondary ischemic necrosis of the skin at the injured site. The larger deep wound was repaired with the chimeric anterolateral thigh perforator flap. (A, B) Appearance photos and anteroposterior and lateral radiographs of ankle joint. (C, D) After the debridement of the distal necrotic lesions of the ankle, tendon, tibia and internal fixator were exposed, with a total wound area of approximately 20 cm × 14 cm. (E, F) The chimeric anterolateral thigh perforator flap were designed and cut out. (G) The skin flap and muscle flap were arranged in a fan shape to cover the wound surface, the vascular pedicle at the donor site was anastomosed with the anterior tibial artery and vein, and the surface of muscle flap was covered with negative pressure. Postoperative microsurgical therapies, such as anti-inflammation, anti-spasm and anticoagulation, were performed as needed. (H, I) At postoperative 5 days, negative pressure on the muscle flap was removed. Blood oozed from the muscle flap. Full-thickness skin grafting was performed and the skin grafting site was covered by vacuum sealing drainage. (J) At 1 week after skin grafting, all flaps and skin grafting sites survived. (K, L) At postoperative 6 months, the flap and skin grafting site on the muscle flap had excellent appearance and no deep infection occurred.

drainage failed to provide delay in definitive free flap reconstruction while providing temporary effective wound coverage. The functional recovery of the foot and ankle is correlated with excellent flap coverage. In general, flap should be fully utilized to cover the weight-bearing site and the exposed sites of deep bone, tendon, nerve and other tissues to provide the maximum tendon sliding and to obtain the premium functional recovery<sup>20</sup>. However, when the wound exceeds a certain range, it is challenging to achieve a satisfactory effect with a single large flap. Alternatively, simultaneous use of two or more combined flaps can be used to repair a large wound while the increased complexity of the procedure would also elevate the surgical risk and aggravate the injury at the donor site. That is to say, once the repair operation fails, it often causes injuries at both the donor and acceptor sites, even leading to amputation.

### *The Characteristic of Chimeric Anterolateral Thigh Perforator Flap*

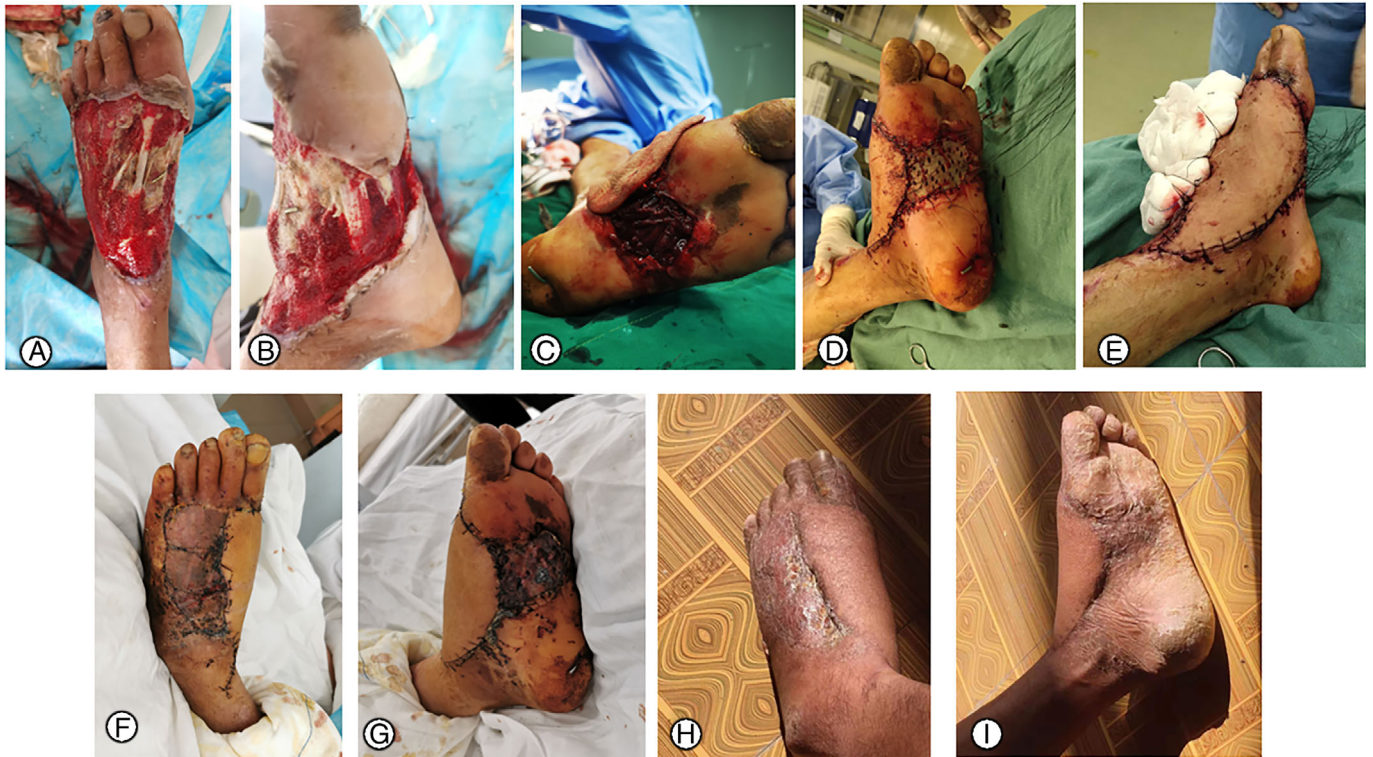The anterolateral thigh flap is considered to be a universal and preferential flap for the repair of extremities wounds<sup>21,22</sup>, because of its constant anatomical position of nutrient vessels, small variations, long vascular pedicle, thick vascular diameter and relatively concealed donor site. In addition, the donor site contains abundant soft tissues, so various types of myocutaneous flaps can be harvested. Meanwhile, morbidity of the lateralis flap donor site is negligible<sup>23</sup>, and the volume of the harvested lateralis flap is adequate for filling deep defects. The concept of chimeric perforator flap was first proposed by Hallock in 1991<sup>24</sup>. The chimeric perforator flap is a special form of perforator flap, which refers to two or more different types of independent tissue flaps (such as skin, fascia, muscle, bone, etc.) harvested in the same



**Fig. 3** Case 2. A male patient, 35 years old, suffered from serious injury of the left foot and ankle caused by a car accident, with multiple phalangeal fractures, calcaneal fractures, complicated with the right acetabular fractures and the right ulna and radius fractures. In a local hospital, the patient was treated with “injury control” to maintain the vital signs. At 1 week after debridement of the left ankle, he was transferred to our hospital. Following multiple times of debridement on the left foot, the right acetabular fracture, the ulnar and radial fracture were treated with open reduction and internal fixation, and the chimeric anterolateral thigh perforator flap was performed for reconstruction of this large area of soft-tissue defects of foot and ankle. (A, B) The appearance of foot and ankle before debridement. The first and fifth toes were absent, the distal injured bone and the tendon were exposed. The wound surface, approximately 22 cm × 15 cm in size, was involved with the plantar weight-bearing site and the dorsum of the foot. (C, D) The chimeric anterolateral thigh perforator flap was designed and created. (E, F) The harvested skin flap and muscle flap were arranged in a fan shape to cover the wound surface. The vascular pedicle at the donor site was anastomosed with the anterior tibial artery and vein, as well as the great saphenous vein. Medium-thickness skin grafting was performed on the surface of the muscle flap. Conventional microsurgical procedures, such as anti-inflammation, anti-spasm and anti-coagulation, were conducted after operation. At postoperative 7 days, all flaps and skin graft sites survived. (G, H) During postoperative 6-month follow-up, the flap and skin graft sites had excellent appearance and no deep infection was observed.

vascular supply area. At least one perforator flap is included in these independent tissue flaps, and the nutrient vessels originate from the same primary blood vessels. Anastomosing a group of vascular pedicle (primary blood vessels) can reconstruct the blood circulation of multiple independent

tissue flaps at the same time. It is novel and practical, makes the three-dimensional reconstruction of wounds achievable and expands the application range of flaps, thus it has been increasingly applied in clinical practice in recent years<sup>15,25</sup>. The blood-supply arteries of the anterolateral thigh flap and



**Fig. 4** Case 3. A male patient, 38 years old, suffered from serious injury of the right foot by a car accident with multiple metatarsal fractures and dislocation. (A, B) The appearance of the foot wound with exposing the local tendon and bone. The wound involved the medial plantar area and dorsum of foot. It was irregular about 18 cm × 19 cm. (C, D, E) The chimeric anterolateral thigh perforator flap was designed and cut. Skin flap and muscle flap were arranged in a fan shape to cover the wound surface in the front of the dorsum and the medial plantar. The vascular pedicle of the donor site was anastomosed with the anterior tibial artery and vein and great saphenous vein. Skin grafting was performed on the surface of dorsolateral foot wound and muscle flap (F, G) All flaps and skin grafting areas survived 10 days after operation. (H, I) Six months follow-up showed that the appearance of flap and skin graft area was good, and no deep infection occurred.

the chimeric muscle flap are both stemmed from the descending branch of the lateral circumflex femoral artery. Only one group of blood vessels needs to be anastomosed intraoperatively to reconstruct the blood circulation of multiple independent tissue flaps<sup>10</sup>. Therefore, the chimeric anterolateral thigh perforator flap not only incorporates the advantages of perforator flap, but also possesses abundant blood supply and potent anti-infection capability of the muscle flap. The flap can be utilized parallel to the chimeric muscle flap, in a spread fan shape to repair different wounds in a flexible way. In particular, the extensibility of the muscle flap provides wider coverage of deep tissues. In this study, we adopted this technique to repair large areas of wounds to the foot and ankle, instead of the use of a single large flap or multiple combined flaps. This technique allowed excision of the flap within the range of direct suturing, thereby minimizing the injury at the donor site. Due to denervation after the grafting of the harvested muscle flap, the muscle site shrinks after the operation and the appearance is not swollen in the advanced stage. Therefore, skin grafting on the muscle flap

can do achieve satisfactory results<sup>26</sup>. After the harvesting of the muscle flap, the wounds at the donor site are more likely to heal due to the reduction of donor site volume. In addition, partial excised muscle flaps exert slight effect upon the movement function at donor site. The descending branch of the lateral circumflex femoral artery serves as the common stem vascular pedicle of both skin flaps and muscle flaps, which is divided into multiple branches when stretching to the distal end. Multiple branches enter the flaps as the perforating branches to nourish the flaps<sup>13</sup>. In a systematic review with analysis on 1251 thighs described in 23 articles, Smith *et al.*<sup>27</sup> revealed that the average number of perforating branches is 1.15–4.26. The lateral femoral muscle belongs to a single main artery muscle, and the muscular branches are constantly present in a multi-branch pattern. The distance stretched by the descending branch of the lateral femoral circumflex artery in the muscle can be utilized to adjust the leaf distance between the flap and muscle flaps, providing a suitable space to cover the wound, especially for irregular wounds.

### **Chimeric Anterolateral Thigh Perforator Flap for Large Soft Tissue Defects of Foot and Ankle**

There are still many challenges in repairing large area of soft-tissue defects of the foot and ankle. In this investigation, the use of chimeric anterolateral thigh perforator flap combined with skin grafting on the surface of the muscle flap achieved excellent reconstruction outcomes. To better satisfy the requirements in clinical practice, multi-leaf skin flaps or muscle flaps can be excised according to the size, shape, location, deep tissue exposure of the wound and the distribution of perforating vessels at the donor site, to repair irregular wounds. The flaps can be thinned to achieve aesthetic repairing effect and simplify the second-stage plastic surgery<sup>28</sup>. The excised chimeric muscle flap can simultaneously fill the deep cavity, stereoscopically repair the tissue defects while controlling infection<sup>29</sup>. Excising a long tendinous muscle flap can also reconstruct the dynamic defect of the foot and ankle. For example, Ando *et al.*<sup>30</sup> applied ALT and TFL fabricated chimeric flaps to reconstruct Achilles tendon and overlaying skin defects successfully. However, it is necessary to obtain the multi-leaf flap and muscle flap during the operation, which increases the time to separate the nutrient vessels and the risk of necrosis of the muscle flap. Taken together, the advantages and disadvantages of flap, skin grafting on the muscle flap and direct skin grafting on the wound should be carefully evaluated to obtain the most optimized performance. Especially for the reconstruction of super huge soft-tissue defects, the chimeric flap technique cannot replace the combined use of multiple groups of flaps.

### **Technical Essentials for Chimeric Anterolateral Thigh Perforator Flap**

The findings in this study suggested that the key for the successful implementation of the chimeric anterolateral thigh perforator flap lies in intra-operative design of the branched perforator flap and muscle flap, as well as the microscopic exploration of respective perforating vessels. Anatomical dissection is a time-consuming and laborious procedure, and the surgeons should be proficient to avoid rough pulling and accidental cutting. Moreover, it is especially necessary to avoid excessive pulling of the vascular pedicle of the muscle flap during the operation, while the appropriate hemostasis measures being carefully conducted to prevent the postoperative incidence of serious bleeding from the flap wound. The incision of the muscle flap differs according to the wound conditions at different acceptor sites. If only wound coverage is required, wide and thin tissues should be incised along the vessel passage in the muscle flap according to the position

that the vascular pedicle may reach. By doing this, the coverage area of the wound will be increased while lowering the postoperative bulky deformity. If coverage needed for both the wound and the dead space, the tissues should be incised according to the size of the dead space. The perforator vascular pedicles of different multi-leaf skin flaps and muscle flaps converge at the descending branch of lateral circumflex femoral artery should be treated flexibly according to the possible variations of vessels<sup>31</sup>. If the sources of blood supply for the multi-leaf skin flaps and muscle flaps are different, additional vascular anastomosis, internal-pressurization, external-pressurization or vascular grafting can be adopted appropriately<sup>3,11,32</sup>. Upon vascular crisis, given the deep location of the chimeric muscle flap, there is no need to take care of muscle flap after the exploration of the vascular pedicle and the removal of the vascular crisis. In this group, five cases were complicated with other severe injuries or intolerable general conditions. Skin grafting was performed on the muscle flap after their general conditions were stable 5–7 days after operation.

This study has the following limitations: (i) through retrospective analysis of cases, this study aimed to evaluate the application of chimeric anterolateral thigh perforator flap for the reconstruction of the large deep wound in the foot and ankle, without comparison with other repair methods; (ii) this paper mainly focused on the treatment of wound soft tissue, and did not discuss much about the repair and reconstruction of the fracture, broken nerve and tendon, so the score of the postoperative limb function was not examined; and (iii) this was a single center study with a limited number of cases. More rigorous and large-scale research will be carried out in the future.

Taken together, compared to conventional flap grafting, with descending branch of lateral circumflex femoral artery and lateral thigh muscle flap is an efficacious and relatively safe procedure for reconstructing large area of soft-tissue defects of the foot and ankle. It is particularly applicable for large area of wounds with irregular defect or deep cavity space after debridement of local infection in clinical practice. However, each procedure during the operation should be performed with cautions, especially during the procedure of cutting off the multi-leaf skin flaps and muscle flaps. Intensive attention should be paid on the protection the perforating vessels and the improvement of the survival rate of the skin flaps and muscle flaps.

## **References**

1. Song B, Chen J, Han Y, *et al.* The use of fabricated chimeric flap for reconstruction of extensive foot defects. *Microsurgery*, 2016, 36: 303–309.
2. Pederson WC, Grome L. Microsurgical reconstruction of the lower extremity. *Semin Plast Surg*, 2019, 33: 54–58.
3. Zheng J, Hua L, Li J, *et al.* Double-pedicle propeller flap for reconstruction of the foot and ankle: anatomical study and clinical applications. *J Int Med Res*, 2019, 47: 4775–4786.
4. Lee ZH, Abdou SA, Ramly EP, *et al.* Larger free flap size is associated with increased complications in lower extremity trauma reconstruction. *Microsurgery*, 2020, 40: 473–478.
5. Kim TG, Kim IK, Kim YH, Lee JH. Reconstruction of lower extremity complex wounds with combined free tissue transfer using the anterolateral thigh flap as a link. *Microsurgery*, 2012, 32: 575–579.
6. Kang CS, Lee JH, Chung KJ, Kim TG. Vastus intermedius-antrolateral thigh chimeric free flap for lower extremity reconstruction. *Arch Plast Surg*, 2018, 45: 604–605.
7. Li RG, Ren GH, Tan XJ, Yu B, Hu JJ. Free flap transplantation combined with skin grafting and vacuum sealing drainage for repair of circumferential or sub-circumferential soft-tissue wounds of the lower leg. *Med Sci Monit*, 2013, 19: 510–517.



- 8.** Li RG, Yu B, Wang G, et al. Sequential therapy of vacuum sealing drainage and free-flap transplantation for children with extensive soft-tissue defects below the knee in the extremities. *Injury*, 2012, 43: 822–828.
- 9.** Zheng X, Zheng C, Wang B, et al. Reconstruction of complex soft-tissue defects in the extremities with chimeric anterolateral thigh perforator flap. *Int J Surg*, 2016, 26: 25–31.
- 10.** Kim SW, Kim KN, Hong JP, Park SW, Park CR, Yoon CS. Use of the chimeric anterolateral thigh free flap in lower extremity reconstruction. *Microsurgery*, 2015, 35: 634–639.
- 11.** Ren G, Li R, Jiang G, Chen CH, Bao ZH. A solution to the vessel shortage during free vascularized fibular grafting for reconstructing infected bone defects of the femur: bridging with vein transplantation. *Injury*, 2017, 48: 486–494.
- 12.** Li R, Zhu G, Chen CH, Chen Y, Ren G. Bone transport for treatment of traumatic composite tibial bone and soft tissue defects: any specific needs besides the Ilizarov technique?. *Biomed Res Int*, 2020, 2020: 13.
- 13.** Luo S, Raffoul W, Luo J, et al. Anterolateral thigh flap: a review of 168 cases. *Microsurgery*, 1999, 19: 232–238.
- 14.** Lee YC, Chen WC, Chou TM, Shieh SJ. Anatomical variability of the anterolateral thigh flap perforators: vascular anatomy and its clinical implications. *Plast Reconstr Surg*, 2015, 135: 1097–1107.
- 15.** Wu K, Ji T, Cao W, Wu HJ, Ren ZH. Application of a new classification of chimeric anterolateral thigh free flaps. *J Craniomaxillofac Surg*, 2019, 47: 1198–1202.
- 16.** Lee ZH, Stranix JT, Rifkin WJ, et al. Timing of microsurgical reconstruction in lower extremity trauma: an update of the Godina paradigm. *Plast Reconstr Surg*, 2019, 144: 759–767.
- 17.** Liu DS, Sofiadellis F, Ashton M, MacGill K, Webb A. Early soft tissue coverage and negative pressure wound therapy optimises patient outcomes in lower limb trauma. *Injury*, 2012, 43: 772–778.
- 18.** Iheozor-Ejiofor Z, Newton K, Dumville JC, Costa ML, Norman G, Bruce J. Negative pressure wound therapy for open traumatic wounds. *Cochrane Database Syst Rev*, 2018, 7: CD012522.
- 19.** Sirisena R, Bellot GL, Puhadrans ME. The role of negative-pressure wound therapy in lower-limb reconstruction. *Indian J Plast Surg*, 2019, 52: 73–80.
- 20.** Hallock GG. The mangled foot and ankle: soft tissue salvage techniques. *Clin Podiatr Med Surg*, 2014, 31: 565–576.
- 21.** Huang WC, Chen HC, Wei FC, Cheng MH, Schnur DP. Chimeric flap in clinical use. *Clin Plast Surg*, 2003, 30: 11.
- 22.** Di Candia M, Lie K, Kumiponjera D, Simcock J, Cormack GC, Malata CM. Versatility of the anterolateral thigh free flap: the four seasons flap. *Eplasty*, 2012, 12: e21.
- 23.** Kaminsky AJ, Li SS, Copeland-Halperin LR, Miraliakbari R. The vastus lateralis free flap for lower extremity gustilo grade III reconstruction. *Microsurgery*, 2017, 37: 212–217.
- 24.** Hallock GG. Simultaneous transposition of anterior thigh muscle and fascia flaps: an introduction to the chimera flap principle. *Ann Plast Surg*, 1991, 27: 126–131.
- 25.** Qing L, Wu P, Yu F, Zhou Z, Tang J. Use of a sequential chimeric perforator flap for one-stage reconstruction of complex soft tissue defects of the extremities. *Microsurgery*, 2020, 40: 167–174.
- 26.** Khundkar R. Lower extremity flap coverage following trauma. *J Clin Orthop Trauma*, 2019, 10: 839–844.
- 27.** Smith RK, Wykes J, Martin DT, Niles N. Perforator variability in the anterolateral thigh free flap: a systematic review. *Surg Radiol Anat*, 2017, 39: 779–789.
- 28.** Seth AK, Iorio ML. Super-thin and suprafascial anterolateral thigh perforator flaps for extremity reconstruction. *J Reconstr Microsurg*, 2017, 33: 466–473.
- 29.** Kang MJ, Chung CH, Chang YJ, Kim KH. Reconstruction of the lower extremity using free flaps. *Arch Plast Surg*, 2013, 40: 575–583.
- 30.** Ando J, Sakuraba M, Sugawara A, et al. Free flap reconstruction of Achilles tendon and overlying skin defect using ALT and TFL fabricated chimeric flap. *Case Reports Plast Surg Hand Surg*, 2019, 6: 82–85.
- 31.** Lakhiani C, Lee MR, Saint-Cyr M. Vascular anatomy of the anterolateral thigh flap: a systematic review. *Plast Reconstr Surg*, 2012, 130: 1254–1268.
- 32.** Gao QF, Niu XT, Ma B, Li ZB, Zhang WF, Ma YJ. Clinical application effect of blood circulation enhancement technique in repairing large area of skin and soft tissue defects of extremities with super large free anterolateral thigh flap. *Zhonghua Shao Shang Za Zhi*, 2019, 35: 814–818.