

# Emphysematous Gastritis in a Transplant Recipient With *Clostridium ventriculi* Infection

David Patrick St. Michel, DO, MPH<sup>1</sup>, Amy Borth, ACNP, MS<sup>1</sup>, Jonah Rubin, MD, MA<sup>1</sup>, Naeem Goussous, MD<sup>1</sup>, William Twaddell, MD<sup>1</sup>, Saad Malik, MD<sup>1</sup>, and Rolf Barth, MD<sup>1</sup>

<sup>1</sup>Department of Medicine, University of Maryland School of Medicine, Baltimore, MD

## ABSTRACT

*Clostridium ventriculi* is a rare infection in poorly controlled diabetic patients with a history of gastroparesis. We present the first documented case in a transplant recipient, who underwent a simultaneous liver kidney transplant. Computed tomography showed emphysematous gastritis, endoscopy revealed gastric necrosis, and microscopy confirmed the diagnosis. Operative intervention was high risk, given the previous liver transplant. Antibiotics and proton pump inhibitor treatment with repeat endoscopy at 4 days showed resolution of gastric necrosis and elimination of microscopic evidence of infection. Combination antibiotic and proton pump inhibitor therapy may be an effective treatment for this rare, life-threatening infection.

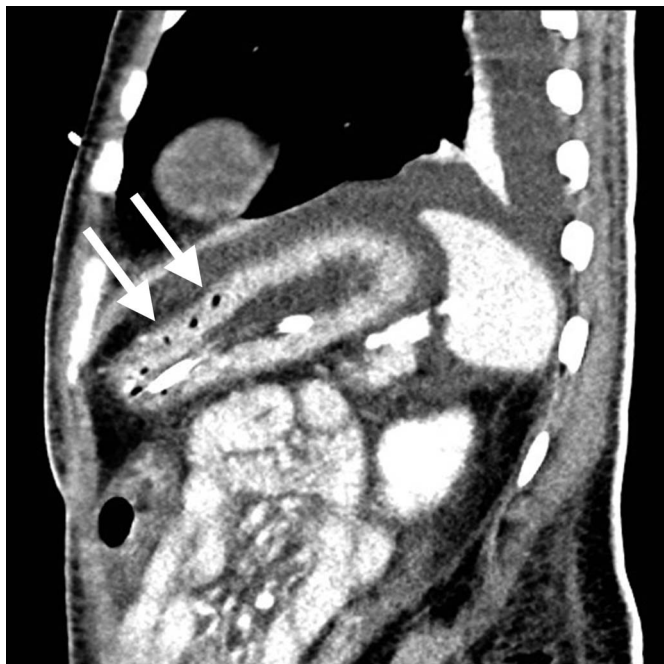
## INTRODUCTION

*Clostridium ventriculi* (previously *Sarcina ventriculi*) infection is exceedingly rare with a total of 22 reported cases.<sup>1,2</sup> Previous reports describe poorly controlled diabetic patients with a history of gastroparesis who present with epigastric pain, low volume hematemesis and may demonstrate emphysematous gastritis on imaging.<sup>1-4,6</sup> In the correct clinical context, diagnosis is confirmed with the presence of characteristic findings on microscopy because biochemical testing can be unreliable and the organism grows poorly on culture.<sup>5</sup> Therefore, endoscopy for biopsy of the affected tissue is required for definitive diagnosis. Treatment has included antibiotics and gastric resection. However, there are little to no data on the efficacy of these treatment regimens, and mortality rates are reported to be as high as 75% if emphysematous gastritis is present.<sup>2,4</sup> We describe the first known case within the literature of emphysematous gastritis caused by *C. ventriculi* in a transplant recipient.

## CASE REPORT

A 35-year-old African American man underwent simultaneous liver and kidney transplant for primary sclerosing cholangitis and end-stage renal disease secondary to diabetes mellitus. His immediate postoperative course was uncomplicated. However, the months after his transplant were plagued with multiple readmissions for hyperkalemia, diabetic ketoacidosis, complications of gastroparesis, and elevated liver enzymes. Twenty-two months after transplant, he presented with a 1-week history of low volume hematemesis, epigastric pain, and blood glucose elevated to greater than 500 mmol/L. His white blood cell count was 15,400 cells per cubic millimeter of blood, consistent with an infectious process. He reported nonadherence to his immunosuppressive medications, with laboratory values indicative of an episode of rejection: tacrolimus less than 1 ng/mL, creatinine of 4 mg/dL, total bilirubin of 24.7 mg/dL, aspartate aminotransferase of 459 U/L, and alanine transaminase of 287 U/L. His vitals were stable, and he was not in distress. A computed tomography study was obtained which revealed emphysematous gastritis prompting an esophagogastroduodenoscopy which showed a superficial gastric ulcer in the antrum with necrotic debris. Biopsies revealed necrosis as well as tetrads and octets of individual bacterial cells measuring up to 3  $\mu$ m, the microscopic findings consistent with *C. ventriculi*<sup>5</sup> (Figure 1).

A multidisciplinary team (including hepatology, transplant surgery, pathology, and infectious disease) was involved in determining the treatment course. Antibiotic treatment was initiated with piperacillin-tazobactam and clindamycin in addition to intravenous pantoprazole 80 mg twice daily. This antibiotic regimen was selected after review of the literature, and pantoprazole was initiated to



**Figure 1.** Computed tomography showing emphysematous gastritis (arrows).

encourage healing of the ulceration. The patient had not been adherent to his immunosuppressive regimen, and at the time of presentation was minimally suppressed (tacrolimus level less than 1) with creatinine, total bilirubin, aspartate aminotransferase, and alanine transaminase elevated, indicating possible rejection. He did have a history of previous rejection episodes. Therefore, we initiated low-dose immunosuppression with tacrolimus and myfortic concurrent with our management of his infection, with daily monitoring of tacrolimus levels.

Operative intervention in the setting of emphysematous gastritis was considered but was deferred because of high mortality risk in the setting of previous liver transplant. The technical challenges in the operative field of a previous liver transplant would likely have been significant, and the area of infection on imaging seemed to

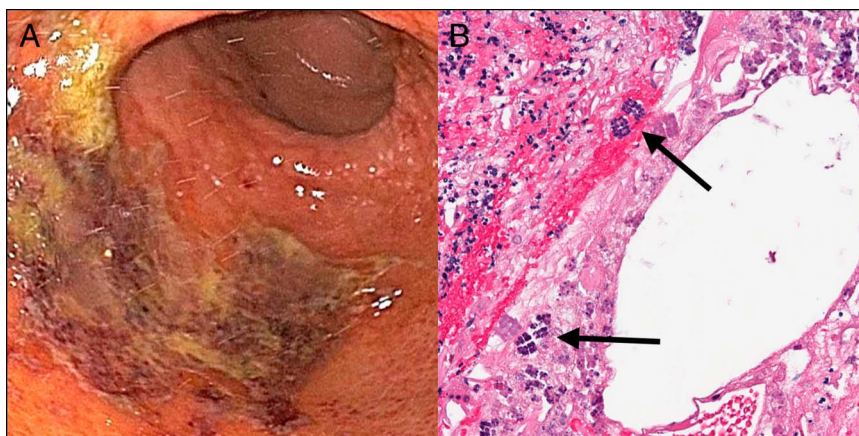
extend from the stomach into the duodenum. Instead, a short-interval repeat esophagogastroduodenoscopy was performed 4 days after initiation of treatment which revealed significantly improved gastric mucosa and healing of the ulcer. Repeat gastric biopsies also showed no necrosis and no microscopic evidence of *C. ventriculi*, and his white blood cell count had dropped to 10,500 cells per cubic millimeter of blood (Figure 2).

Unfortunately, after treatment of his infection, the patient's concomitant rejection of his transplanted grafts secondary to immunosuppression medication nonadherence was complicated by a hypotensive and ischemic event, and he died 17 days after admission. At the time of this event, the patient's infectious symptoms had been resolved for 12 days, imaging had shown resolution of the emphysematous gastritis, and microscopy had demonstrated eradication of his *C. ventriculi* gastric infection (Figure 3).

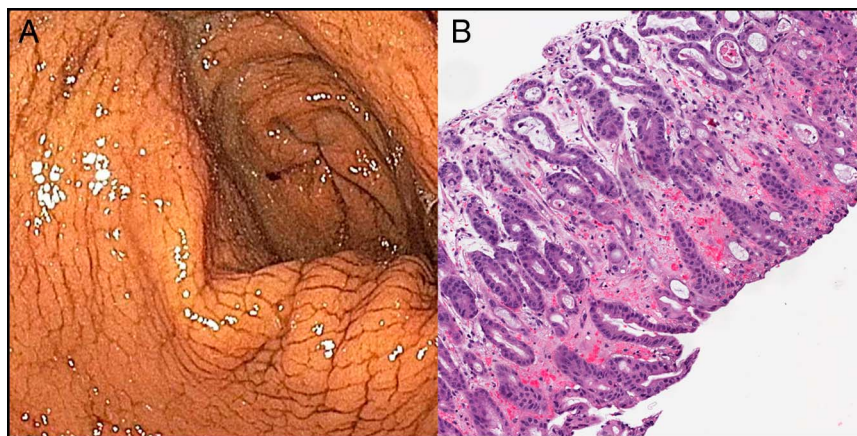
## DISCUSSION

*C. ventriculi* was first described by Goodsir in 1842 as a human pathogen found in stomach contents, with unclear clinical significance.<sup>1</sup> Originally identified as *Sarcina ventriculi*, it has since been reclassified as *C. ventriculi* as it is a gas-producing organism. It is a rare organism that most commonly infects the stomach and affects poorly controlled diabetics with a history of gastroparesis.<sup>1-4,6</sup> Case reports also indicate an association with chronic liver disease.<sup>6</sup>

Previous case reports describe an infection resulting in hematemesis, emphysematous gastritis, and frequently mortality secondary to gastric necrosis or perioperative complications after gastrectomy.<sup>1-4,6</sup> Portal venous gas is the worst prognostic marker with estimated mortality approaching 75% in these patients.<sup>4</sup> Infections can involve the esophagus and duodenum, but gastric infection (85%) is the most common site.<sup>6</sup> Endoscopy is frequently performed, with a common finding of vegetative material (presumably secondary to gastroparesis) and erosions, ulcerations, mucosal necrosis, or stricture in 68.4% of cases.<sup>6</sup>



**Figure 2.** (A) Initial endoscopy of stomach with ulceration and necrosis and (B) microscopy findings characteristic of *Clostridium ventriculi*, with tetrads and octets of individual bacterial cells measuring up to 3  $\mu\text{m}$  (arrows).



**Figure 3.** (A) After 4 days of treatment, endoscopy antibiotic and proton pump inhibitor treatment showed resolution of ulcer and improvement in condition of the gastric mucosa and (B) microscopic resolution of *Clostridium ventriculi* infection.

Although a molecular test exists for the diagnosis of *C. ventriculi*, the identification of characteristic tetrads and octets on light microscopy is sufficient for diagnosis.<sup>6</sup>

The patient had several risk factors for the development of infection particularly *C. ventriculi*. Immunosuppression after transplant increased his risk of infection, although the impact in this case is unclear, given his nonadherence to his regimen. The patient was also a poorly controlled diabetic, who was not adherent to dietary restrictions and often presented in diabetic ketoacidosis. Previous case reports of *C. ventriculi* describe poorly controlled diabetes and a history of gastroparesis.<sup>6</sup>

This is the first reported case of *C. ventriculi* in an organ transplant recipient and presented significant treatment challenges. Patients who present with abdominal distention, hematemesis, and abdominal pain have been successfully treated with antibiotics, proton pump inhibitors (PPIs), and supportive care.<sup>6</sup> Unfortunately, our patient also exhibited emphysematous gastritis, a poor prognostic factor.<sup>4,6</sup> Previous case reports of patients presenting with emphysematous gastritis describe operative intervention with total gastrectomy.<sup>1-4</sup> Transplant patients may also poorly tolerate major operative intervention secondary to immunosuppressive regimens and often have additional comorbidities leading to difficult postoperative management. Therefore, we opted to treat with antibiotics, PPI therapy, and short-interval endoscopy for surveillance of treatment efficacy. This demonstrated that a 4-day course of antibiotics and PPI therapy resolved the previously noted necrosis and eliminated microscopic evidence of the infection. This nonoperative treatment course for emphysematous gastritis associated with *C. ventriculi* infection may reduce mortality by avoiding the highly morbid treatment option of a total gastrectomy.

We report the first documented case of emphysematous gastritis secondary to *C. ventriculi* infection in a transplant recipient. The data available on appropriate treatment of this infection are incomplete. In an immunosuppressed, high-risk surgical candidate, we attempted conservative, nonoperative management with

short-interval evaluation of treatment progress using endoscopy. Although the patient died secondary to other complications related to his transplant, this course demonstrated successful nonoperative treatment of emphysematous gastritis associated with this rare infection.

## DISCLOSURES

Author contributions: DP St. Michel and N. Goussous wrote and edited the manuscript. A. Borth wrote the manuscript and reviewed the literature. J. Rubin wrote the manuscript and provided the images. W. Twaddell, S. Malik, and R. Barth approved the final manuscript. DP St. Michel is the article guarantor.

Financial disclosure: none to report.

Informed consent could not be obtained from the family of the deceased patient despite several attempts. All identifying information has been removed from this case report to protect patient privacy.

Received March 11, 2020; Accepted July 17, 2020

## REFERENCES

1. Goodsir J, Wislon G. History of a case in which a fluid periodically ejected from the stomach contained vegetable organisms of an undescribed form. *J Nat Hist* 1843;11(68):125-6.
2. Murdoch DA. Gram-positive anaerobic cocci. *Clin Microbiol Rev* 1998;11: 81-120.
3. Laass MW, Pargac N, Fischer R, et al. Emphysematous gastritis caused by *Sarcina ventriculi*. *Gastrointest Endosc* 2010;72(5):1101-3.
4. Haroon Al Rasheed M, Senseng C. *Sarcina ventriculi*: Review of the literature. *Arch Pathol Lab Med* 2016;140:1441-5.
5. Lam-Himlin D, Tsiatis AC, Anders RA, et al. *Sarcina* organisms in the gastrointestinal tract: A clinicopathologic and molecular study. *Am J Surg Pathol* 2011;35(11):1700-5.
6. Gaspar BL. The significance of *Sarcina* in routine surgical pathology practice. *APMIS* 2016;124:436-43.

**Copyright:** © 2020 The Author(s). Published by Wolters Kluwer Health, Inc. on behalf of The American College of Gastroenterology. This is an open-access article distributed under the terms of the Creative Commons Attribution-Non Commercial-No Derivatives License 4.0 (CCBY-NC-ND), where it is permissible to download and share the work provided it is properly cited. The work cannot be changed in any way or used commercially without permission from the journal.