



# HHS Public Access

Author manuscript

*J Hum Genet.* Author manuscript; available in PMC 2012 January 01.

Published in final edited form as:

*J Hum Genet.* 2011 July ; 56(7): 534–540. doi:10.1038/jhg.2011.55.

## Molecular and Clinical Studies of X-linked Deafness Among Pakistani Families

Ali M. Waryah<sup>1,6</sup>, Zubair M. Ahmed<sup>2,3,6</sup>, Daniel I. Choo<sup>2</sup>, Robert A. Sisk<sup>3</sup>, Munir A. Binder<sup>1</sup>, Mohsin Shahzad<sup>1</sup>, Shaheen N. Khan<sup>1</sup>, Thomas B. Friedman<sup>4</sup>, Sheikh Riazuddin<sup>5</sup>, and Saima Riazuddin<sup>2,3</sup>

<sup>1</sup> National Center of Excellence in Molecular Biology, University of the Punjab, Lahore, Pakistan

<sup>2</sup> Division of Pediatric Otolaryngology Head & Neck Surgery, Children Hospital Research Foundation, and the Department of Otolaryngology, College of Medicine, University of Cincinnati, OH, USA

<sup>3</sup> Division of Pediatric Ophthalmology, Cincinnati Children's Hospital Research Foundation, and the Department of Ophthalmology, College of Medicine, University of Cincinnati, OH, USA

<sup>4</sup> Section on Human Genetics, Laboratory of Molecular Genetics, National Institute on Deafness and Other Communication Disorders, National Institutes of Health, Rockville, MD, USA

<sup>5</sup> Allama Iqbal Medical College-Jinnah Hospital Complex, University of Health Sciences, Lahore, Pakistan

### Abstract

There are 68 sex-linked syndromes that include hearing loss as one feature and five sex-linked nonsyndromic deafness loci listed in the OMIM database. The possibility of additional such sex-linked loci was explored by ascertaining three unrelated Pakistani families (PKDF536, PKDF1132, PKDF740) segregating X-linked recessive deafness. Sequence analysis of *POU3F4* (*DFN3*) in affected members of families PKDF536 and PKDF1132 revealed two novel nonsense mutations, p.Q136X and p.W114X, respectively. Family PKDF740 is segregating congenital blindness, mild to profound progressive hearing loss that is characteristic of Norrie disease (MIM#310600). Sequence analysis of *NDP* among affected members of this family revealed a novel single nucleotide deletion c.49delG causing a frameshift and premature truncation (p.V17fsX1) of the encoded protein. These mutations were not found in 150 normal DNA samples. Identification of pathogenic alleles causing X-linked recessive deafness will improve molecular diagnosis, genetic counseling, and molecular epidemiology of hearing loss among Pakistanis.

---

Users may view, print, copy, download and text and data- mine the content in such documents, for the purposes of academic research, subject always to the full Conditions of use: [http://www.nature.com/authors/editorial\\_policies/license.html#terms](http://www.nature.com/authors/editorial_policies/license.html#terms)

Correspondence: Saima Riazuddin, Ph.D; Laboratory of Molecular Genetics, Division of Pediatric Otolaryngology Head & Neck Surgery, Cincinnati Children's Hospital Medical Center, Cincinnati, OH, USA., [saima.riazuddin@cchmc.org](mailto:saima.riazuddin@cchmc.org).

<sup>6</sup>These authors contributed equally to this work

### CONFLICT OF INTEREST

The authors declare no conflict of interest.

## Keywords

*DFN3*; Norrie disease; *POU3F4*; NDP; hearing loss; gushers

---

## INTRODUCTION

X-linked nonsyndromic hearing impairment is genetically heterogeneous with a prevalence of 1% to 5% in different populations.<sup>1,2</sup> To date, five loci for nonsyndromic hearing loss (*DFN2*, *DFN3*, *DFN4*, *DFN6*, *AUNX*) have been reported and genes for two of them, *PRPS1* (*DFN2*) and *POU3F4* (*DFN3*), have been identified.<sup>3,4</sup> *PRPS1* encodes phosphoribosylpyrophosphate synthetase 1 (PRS-I; EC 2.7.6.1), which is essential for the first step of nucleotide synthesis pathway. Missense mutations that dysregulate PRS-I enzymatic activity are also associated with X-linked Charcot-Marie-Tooth disease-5 (CMTX5; MIM 311070), Arts syndrome (MIM 301835), and PRS-I superactivity disorder (MIM 300661).<sup>4</sup> *POU3F4* (*DFN3*) mutations are the most common cause of sex-linked nonsyndromic deafness.<sup>2,3</sup> *POU3F4* encodes a transcription factor, which belongs to the POU-domain family and is comprised of two subdomains, POU-specific domain and a homeodomain.<sup>5</sup> To date, 30 mutations, including two nonsense alleles, in the coding region of the *POU3F4* have been identified as a cause of nonsyndromic hearing loss in *DFN3* families.<sup>6</sup>

X-linked hearing loss can also manifest as part of a syndrome. For example, Norrie disease is characterized by congenital or early childhood blindness and progressive mental retardation with reduced penetrance.<sup>7,8</sup> Progressive sensorineural hearing loss has been reported in about one third of the Norrie disease cases.<sup>7,8</sup> Mutations of *NDP* encoding norrin, a protein of 133 residues, were identified in subjects with Norrie disease.<sup>8-10</sup> Fifty five different pathogenic alleles including missense, nonsense, splice site, insertion and deletions, have been identified in Norrie disease subjects of North American, European and Japanese ancestries (<http://www.retina-international.com/sci-news/ndgmut.htm>).

To understand the genetic causes of X-linked hearing impairment in the Pakistani population, we ascertained families segregating sex-linked hearing loss in this population. Here we report three large consanguineous Pakistan families, PKDF536, PKDF1132 and PKDF740, segregating X-linked recessive hearing loss. Clinical investigation revealed nonsyndromic deafness segregating in families PKDF536 and PKDF1132. We found two novel nonsense mutations, p.Q136X and p.W114X, of *POU3F4* co-segregating with hearing loss in these two families, respectively. Affected individuals of family PKDF740 were diagnosed with Norrie disease and mutational analysis of *NDP* revealed a one bp deletion, c.49delG, that results in a translation frameshift and a predicted premature truncation of 117 residues of norrin.

## MATERIAL AND METHODS

### Family Enrollment and Diagnosis

This study was approved by the IRB at the National Centre of Excellence in Molecular Biology (NCEMB), Lahore, Pakistan (FWA00001758), the Combined Neuroscience IRB at

the National Institutes of Health, USA (OH-93-N-016) and, the IRB Committee at the Cincinnati Children's Hospital Research Foundation, USA (2009-0684). Written informed consent was obtained from all participating individuals and parents of minor subjects. The pedigree structure and information about consanguinity is based on interviews with family members.

### Clinical Evaluation

Participating subjects were evaluated by medical history interviews. A physical examination was performed on at least one hearing impaired individual from each family. The degree of hearing loss was assessed by pure tone audiometry using air conduction at frequencies ranging from 250–8000 Hz. Computational Tomography (CT) was performed on members of families PKDF536 and PKDF1132 to access *POU3F4* mutation-linked middle ear anomalies. Detailed funduscopic examination of some affected individuals ruled out obvious signs of retinopathy. Magnetic Resonance Imaging (MRI) and Brightness scan (B-scan) was performed to characterize the ocular phenotype of Norrie disease in PKDF741. During MRI, multi-planer imaging was done through both orbits acquiring T1/T2 weighted and proton density sequences. Vestibular function was evaluated by tandem gait and Romberg testing.

### DNA Isolation, Linkage analysis and Sequencing

Venous blood samples were obtained and genomic DNA was extracted using a standard protocol (5). STR (Short Tandem Repeats; ABI Prism Linkage Mapping Set v2.5, Applied Biosystems Foster City, CA) markers spaced at approximately 10 cM and also covering the X-chromosome were used for linkage analysis. Markers were amplified on a Gene Amp PCR system 2700, analyzed on ABI Prism 3730 Genetic Analyzer and the alleles were assigned using GeneMapper software (Applied Biosystems). Sequencing primers of *POU3F4* and *NDP* were designed from the flanking region of each exon using Primer3 web utility ([http://www.frodo.wi.mit.edu/cgi-in/primer3/primer3\\_www.cgi](http://www.frodo.wi.mit.edu/cgi-in/primer3/primer3_www.cgi)). Sequencing reactions and mutational analyses were performed as described previously.<sup>11</sup>

## RESULTS

### Family PKDF536

The proband V:1 was first enrolled through a school for hearing impaired individuals. A family history revealed the presence of additional affected members all of whom were male (Figure 1a). According to the parents or other family members, the time of hearing loss was pre-lingual. Air and bone conduction audiometry of two affected individuals of this family showed severe to profound mixed hearing loss (Figure 1c).

X-chromosome haplotype analysis revealed co-segregation of hearing loss in family PKDF536 with *DFN3*-linked STR markers (data not shown). *DFN3* is caused by mutations in *POU3F4* gene as well as by inversions, duplications and deletions upstream of this gene.<sup>2,3,12–17</sup> Sequence analysis of *POU3F4* in affected males of family PKDF536 revealed a novel transversion mutation (c.406C>T), which results in a nonsense mutation (p.Q136X; Figure 1e). The p.Q136X mutation is predicted to truncate the protein prior to the POU-specific and homeobox domains. All affected males had the c.406C>T mutation, while the

female carrier had normal hearing (Figure 1b). c.406C>T was absent in 150 DNA samples from normal hearing Pakistani individuals and was also absent from the 1000 Genomes database of human genetic variation.

High-resolution temporal bone CT scan of affected individual IV:11 of PKDF536 showed bilaterally minimal widening of the lateral ends of the internal auditory canals (Figure 2). The basal and middle turns of cochlea, semicircular canals, vestibules and ossicles were normally developed. But the mid and apical turns are not clearly partitioned in individual IV:11 (Figure 2c). A wide modiolus at the junction of the cochlea with the internal auditory canal was also observed (Figure 2e).

### Family PKDF1132

A multi-generation family (Figure 3a) segregating pre-lingual hearing loss was ascertained from Punjab province of Pakistan. Pure tone audiometry of the three participating hearing-impaired individuals showed bilateral severe to profound mixed hearing loss (Figure 3c). A high-resolution temporal bone CT scan was performed on individual VI:4 of family PKDF1132 (Figure 3a). The internal auditory canal had an unusual bulbous morphology and it directs antromedially rather than continuing in a straight direction. Bony deficiency at the base of cochlea was also observed (Figure 3d).

Linkage analysis studies revealed common alleles among all of the affected individuals for *DFN3*-linked STR markers (data not shown). Sequence analysis of *POU3F4* in affected members of family PKDF1132 revealed a novel transition mutation (c.341G>A), which results in a nonsense mutation (p.W114X; Figure 3e). The c.341G>A transition mutation was absent in 150 DNA samples from normal hearing Pakistani individuals and in the 1000 Genomes database of human genetic variation. The truncated protein due to p.W114X is predicted to lack all of the known domains of POU3F4.

### Family PKDF740

Family PKDF740 has four affected individuals in two non-consanguineous sibships (Figure 4a). All of the affected individuals had congenital, bilateral blindness, and progressive mild to profound hearing loss (Figure 4c–e) as well as microphthalmia, clinical features consistent with Norrie disease.<sup>7</sup> B-scan of individual III:1 of family PKDF740 revealed severe microphthalmia with retinal dysplasia and disorganization of intraocular contents in the right eye. A focal area of calcification posteriorly may represent a pseudoglioma. The scan of the left eye showed severe microphthalmia with three foci of increased sonoreflexivity corresponding to a dense cataract and total funnel retinal detachment with calcific shadowing blocking the contour of the posterior curvature of the globe. Magnetic resonance imaging (MRI) of individual III:1 showed that anteroposterior dimensions of the globes are microphthalmic and were 0.5 cm at right and 0.8cm (normal range: 2.38 cm to 3.11 cm) on the left side with hypointense masses projecting anteriorly from the optic nerves (Figure 5). These represent either funnel retinal detachment and/or pseudogliomas (dysplastic retina/optic nerve mass). No evidence of conal or extra-conal mass. Lacrimal glands and optic nerves are normal in appearance. Brain parenchyma was normal, but the optic nerves, chiasm, and tracts were small, if present at all, indicating either primary

hypoplasia or secondary postaxonal degeneration (Figure 5). Four of the five available females have normal hearing and vision. One female (III:2) has normal hearing (Figure 4b) but B-scan images of her right eye showed severe microphthalmia, phthisis and discoid calcific lens with absent anterior chamber. Strong acoustic shadowing prevents evaluation of the remaining posterior segment. B-scan of the left eye revealed severe microphthalmia and phthisis. Ocular contents are not discernible posterior to calcification.

Norrie disease appears to be genetically homogenous as it is caused by mutations in *NDP*.<sup>8-10</sup> Mutational analysis of all the exons of *NDP* in the DNA samples from affected individuals of family PKDF740 revealed a novel frameshift mutation c.49delG in exon 2. Deletion of a single nucleotide is predicted to cause a translation reading frameshift and premature truncation of the encoded protein, p.V17fsX1. This mutation was not found in 150 DNA samples from normal hearing Pakistani individuals and in the 1000 Genomes database of human genetic variation.

## DISCUSSION

### DFN3 (POU3F4)

Five *DFN* loci have been mapped and genes for two of them, *PRPS1* (*DFN2*) and *POU3F4* (*DFN3*), have been identified.<sup>3,4</sup> Among the known loci, *DFN3* accounts for approximately 50% of nonsyndromic X-linked hearing loss.<sup>2</sup> Clinically, *DFN3* is characterized by congenital sensorineural or mixed hearing loss and perilymphatic gusher occurring during stapes surgery.<sup>18</sup> *POU3F4*, mutated in *DFN3* families, encodes a polypeptide of 361 amino acids with bi-partite DNA-binding domains (POU and homeobox), and thus belongs to the POU family of transcription factors.<sup>5,8-10</sup> Thirty different mutations, including nonsense mutations, deletions, inversions and duplication, within or upstream of the *POU3F4* gene have been reported.<sup>6</sup> Most of these alleles have been identified in Caucasian populations and very few studies have described an Asian population.<sup>14,19</sup> In this study, we identified two novel nonsense mutations (p.Q136X) and (p.W114X) in *POU3F4* as a cause of nonsyndromic recessive hearing loss in two large Pakistani families. Both of these mutations (p.Q136X and p.W114X) are predicted to cause premature truncation of the POU3F4 protein prior to the POU and homeobox domains, hence likely representing functional null alleles. Some studies have reported the hearing loss in female siblings or mothers of affected males with mutations in *POU3F4*.<sup>20</sup> However, in our two families we did not observe hearing loss in heterozygous mothers (Figures 1 and 3). Air and bone conduction audiometry of both families revealed the severe to profound bilateral mixed hearing loss in all the affected individuals of both families along with structural abnormalities of the cochlea, a phenotype consistent with previous studies.<sup>6,12,13,16,21</sup> Deficiency of POU3F4 associated defects of the bony labyrinth includes dilation of the internal auditory canal, partial hypoplasia of the spiral limbus, scala tympani, and stria fibrocytes, with incomplete penetrance of a reduction in the cochlear turns. Outward pressure of perilymphatic fluid on the oval window coupled with defects in the size and shape of stapes footplate further compromise ossicular movement and collectively, these anomalies result in a conductive hearing loss in *DFN3* patients.<sup>21,22</sup>

The management of patients with mixed hearing loss depends upon the degree of the overall hearing loss, as well as the relative contributions of the sensorineural and conductive hearing loss components. For those patients with milder hearing impairments (whether conductive or sensorineural), or if the hearing loss is predominantly sensorineural, then hearing aids are often a first line recommendation. However, if the overall hearing impairment is more severe, and there is a substantial conductive component, then consideration is given to a surgical intervention to address the conductive component. A pertinent cautionary aspect in this line of management is the possibility of a “stapes gusher” that is well described in some patients.<sup>6,12,13</sup> In this phenomenon, surgical removal or manipulation of the stapes can result in a robust flow of perilymph from the oval window. Such brisk outflow of cochlear fluids can result in an immediate deafness along with concomitant complaints of vertigo and tinnitus. Recently, some patients with bilateral mixed hearing losses but serviceable bone conduction thresholds have been shown to benefit from bone anchored hearing aid technologies. Such interventions are attractive in avoiding surgical manipulation of the stapes and thus avoiding the risk of a gusher, but still providing effective gain via bone conduction technologies.

### Norrie disease (NDP)

Norrie disease is a severe X-linked recessive disorder with clinical manifestations of congenital or very early childhood blindness due to degenerative and proliferative changes of the neuroretina. About 50% of ND patients show progressive mental disorder, often with psychotic features, and approximately one-third of the cases develop bilateral, progressive, sensorineural deafness in the second decade.<sup>7</sup> In addition, some patients have more complex phenotypes, including growth failure, seizures, profound psychomotor retardation, delayed sexual maturation, stereotypies, microcephaly, cardiovascular abnormalities and idiopathic pulmonary arterial hypertension, and are thus diagnosed with “Norrie-plus” syndrome.<sup>8–10,23–31</sup> The Norrie-plus syndrome is associated with microdeletions encompassing *NDP* and neighboring genes at Xp11.3-11.4 including *MAO-A*, *MAO-B* and *EFHC2*.<sup>23</sup> The *NDP* gene encodes norrin, a secreted cysteine-rich protein of 133 residues that belongs to the cystine knot growth factor family.<sup>5,9</sup> Fifty five different pathogenic alleles of *NDP* have been reported, including the thirteen private mutations found in Asian populations, mainly Japanese and Chinese families. However, to our knowledge, no *NDP* mutation in the Indo-Pak subcontinent population has been reported. Sequence analysis of *NDP* in DNA samples from affected individuals of Pakistani family PKDF740 revealed a novel single base pair deletion, c.49delG, in exon 2, which is predicted to cause premature truncation (p.V17fsX1) of Norrin protein, and thus is likely to be a functional null allele.

Based on the mutational screening of 109 patients with pediatric vitreoretinopathies, Wu and co-authors defined a genotype-phenotype correlation, in which the *NDP* mutations disrupt the cysteine-knot motif resulting in severe retinal dysgenesis and a diagnosis of Norrie disease, whereas patients with noncysteine mutations have varying degrees of avascular peripheral retina, extraretinal vasculature, and subretinal exudate.<sup>32</sup> In family PKDF740, congenital blindness due to microphthalmia co-segregated with mild to profound, progressive hearing loss. One obligatory carrier female III:2 (30y) share the ocular symptoms with affected individuals but had normal air and bone conduction thresholds



(Figure 4b). The incomplete penetrance of the clinical symptoms in the obligate carrier females has been documented in a few studies.<sup>33–35</sup> This unusual phenotype in a female has been attributed to Lyonization or an adverse effect of the mutant copy of the protein on the retina during development.<sup>33–35</sup> In family PKDF740 there were no obvious signs of mental retardation although this phenotype was not methodically pursued at the time family members were ascertained.

Incomplete retinal vascularization, retinal folding and detachment, microphthalmia, alteration in the composition of vitreous body and vitreoretinal hemorrhages, the highly penetrant clinical symptoms of ND, bear significant phenotypic overlap with familial exudative vitreoretinopathy (FEVR). FEVR is a genetically heterogeneous disease and can manifest under a variety of inheritance models.<sup>10,36,37</sup> Mutations in *FDZA* and *LRP5* that encode frizzled 4 and low density lipoprotein receptor protein 5, respectively, are associated with autosomal dominant FEVR.<sup>38,39</sup> Functional studies have shown that NDP serves as a ligand and binds with high affinity to frizzled-4 membrane receptor, which in turn activates the canonical Wnt signaling pathway. Furthermore, the norrin-FZD4 signaling system plays a central role in vascular development in the eye and ear.<sup>40</sup>

## Conclusion

The identification of three families segregating recessive hearing loss due to mutations in genes present on the X chromosome among the 1000 Pakistani families did not reveal a novel locus, an observation consistent with many similar studies in other populations.<sup>6,14</sup> In combination, these data suggest that most or all of the X-linked genes, which when mutated cause nonsyndromic deafness, have already been identified. Admittedly there may be an ascertainment bias, but if not, our data also suggest that there is a low prevalence of X-linked hearing impairment (0.3%; 95% CI: 0.1–0.8%) in Pakistan.

## Acknowledgments

The authors are grateful to the families who made this research possible. This work was supported by Cincinnati Children's Hospital Research Foundation (CCHMC) intramural research funds to SR and ZA, the National Institute on Deafness and Other Communication Disorders (NIDCD/NIH) research grant R00-DC009287-03, a Career Development Award from RPB to ZA. Work in Pakistan was supported by the Higher Education Commission to SR, Islamabad; EMRO/WHO-COMSTECHE and Ministry of Science and Technology (MoST) to SR, Islamabad; the International Center for Genetic Engineering and Biotechnology, Trieste, Italy under project CRP/PAK08-01 Contract no. 08/009 to SR. Part of this study carried out in the USA was supported by intramural funds from the NIDCD/NIH (Z01-DC00039-14) to TBF.

### Mutation nomenclature

The A nucleotide of the start codon (ATG) of GenBank *POU3F4* and *NDP* cDNA sequences (NM\_000307, NM\_000266; respectively) is nucleotide +1.

## References

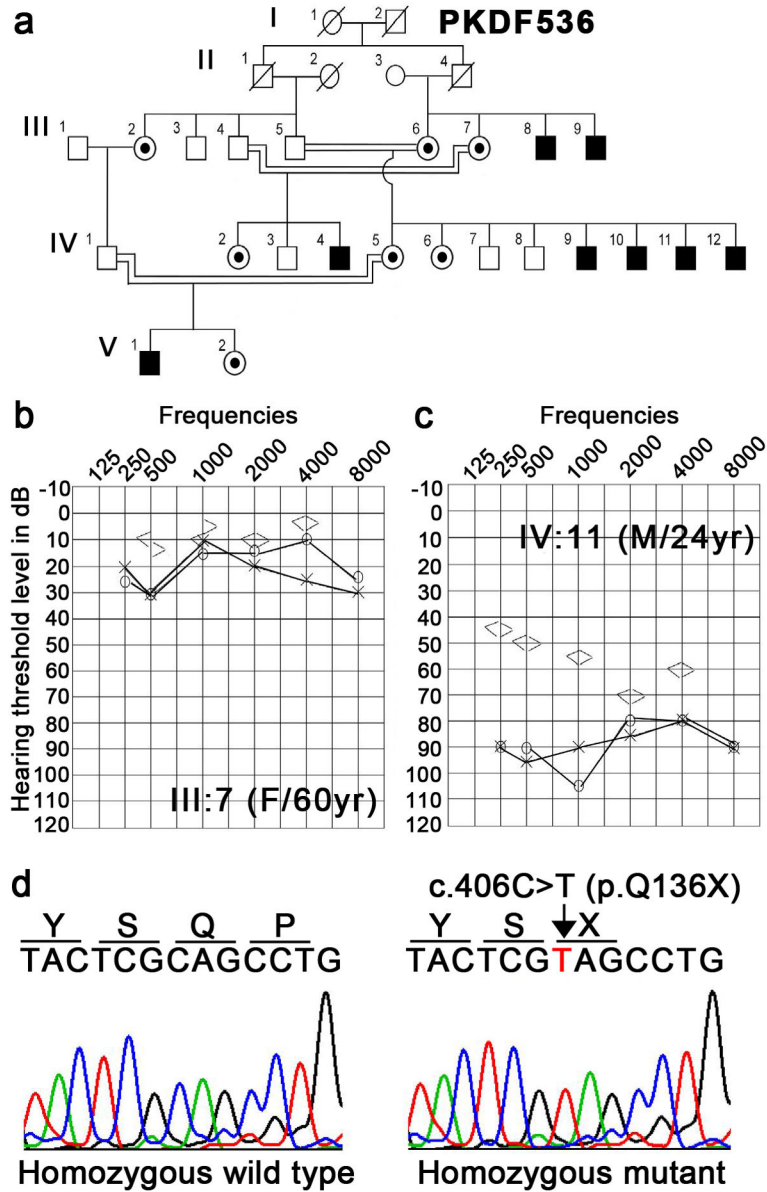
1. Cohen, MM.; Gorlin, RJ. Epidemiology, etiology, and genetic patterns. Oxford University Press; Oxford: 1995.
2. Petersen MB, Wang Q, Willems PJ. Sex-linked deafness. Clin Genet. 2008; 73:14– 23. [PubMed: 18005182]

3. de Kok YJ, van der Maarel SM, Bitner-Glindzicz M, Huber I, Monaco AP, Malcolm S, Pembrey ME, Ropers HH, Cremers FP. Association between X-linked mixed deafness and mutations in the POU domain gene POU3F4. *Science*. 1995; 267:685–688. [PubMed: 7839145]
4. de Brouwer AP, van Bokhoven H, Nabuurs SB, Arts WF, Christodoulou J, Duley J. PRPS1 mutations: four distinct syndromes and potential treatment. *Am J Hum Genet*. 2010; 86:506–518. [PubMed: 20380929]
5. Mathis JM, Simmons DM, He X, Swanson LW, Rosenfeld MG. Brain 4: a novel mammalian POU domain transcription factor exhibiting restricted brain-specific expression. *EMBO J*. 1992; 11:2551–2561. [PubMed: 1628619]
6. Li J, Cheng J, Lu Y, Chen A, Sun Y, Kang D, Zhang X, Dai P, Han D, Yuan H. Identification of a novel mutation in POU3F4 for prenatal diagnosis in a Chinese family with X-linked nonsyndromic hearing loss. *J Genet Genomics*. 2010; 37:787–793. [PubMed: 21193157]
7. Bleeker-Wagemakers LM, Friedrich U, Gal A, Wienker TF, Warburg M, Ropers HH. Close linkage between Norrie disease, a cloned DNA sequence from the proximal short arm, and the centromere of the X chromosome. *Hum Genet*. 1985; 71:211–214. [PubMed: 2998969]
8. Berger W, Meindl A, van de Pol TJ, Cremers FP, Ropers HH, Doerner C, et al. Isolation of a candidate gene for Norrie disease by positional cloning. *Nat. Genet*. 1992; 2:84. [PubMed: 1303256]
9. Meindl A, Berger W, Meitinger T, van de Pol D, Achatz H, Dorner C, et al. Norrie disease is caused by mutations in an extracellular protein resembling C-terminal globular domain of mucins. *Nat Genet*. 1992; 2:139–143. [PubMed: 1303264]
10. Chen ZY, Battinelli EM, Fielder A, Bunday S, Sims K, Breakefield XO, Craig IW. A mutation in the Norrie disease gene (NDP) associated with X-linked familial exudative vitreoretinopathy. *Nat Genet*. 1993; 5:180–183. [PubMed: 8252044]
11. Ahmed ZM, Riazuddin S, Bernstein SL, Ahmed Z, Khan S, Griffith AJ, Morell RJ, Friedman TB, Wilcox ER. Mutations of the protocadherin gene PCDH15 cause Usher syndrome type 1F. *Am J Hum Genet*. 2001; 69:25–34. [PubMed: 11398101]
12. Wang QJ, Li QZ, Rao SQ, Zhao YL, Yuan H, Yang WY, Han DY, Shen Y. A novel mutation of POU3F4 causes congenital profound sensorineural hearing loss in a large Chinese family. *Laryngoscope*. 2006; 116:944–950. [PubMed: 16735904]
13. Vore AP, Chang EH, Hoppe JE, Butler MG, Forrester S, Schneider MC, Smith LL, Burke DW, Campbell CA, Smith RJ. Deletion of and novel missense mutation in POU3F4 in 2 families segregating X-linked nonsyndromic deafness. *Arch Otolaryngol Head Neck Surg*. 2005; 131:1057–1063. [PubMed: 16365218]
14. Lee HK, Lee SH, Lee KY, Lim EJ, Choi SY, Park RK, Kim UK. Novel POU3F4 mutations and clinical features of DFN3 patients with cochlear implants. *Clin Genet*. 2009; 75:572–575. [PubMed: 19438930]
15. de Kok YJ, Merck GF, van der Maarel SM, Huber I, Malcolm S, Ropers HH, Cremers FP. A duplication/paracentric inversion associated with familial X-linked deafness (DFN3) suggests the presence of a regulatory element more than 400 kb upstream of the POU3F4 gene. *Hum Mol Genet*. 1995; 4:2145–2150. [PubMed: 8589693]
16. Bitner-Glindzicz M, Turnpenny P, Hoglund P, Kaariainen H, Sankila EM, van der Maarel SM, et al. Further mutations in Brain 4 (POU3F4) clarify the phenotype in the X-linked deafness, DFN3. *Hum Mol Genet*. 1995; 4:1467–1469. [PubMed: 7581392]
17. Collin RW, Chellappa R, Pauw RJ, Vriend G, Oostrik J, van Drunen W, Huygen PL, Admiraal R, Hoefsloot LH, Cremers FP, Xiang M, Cremers CW, Kremer H. Missense mutations in POU4F3 cause autosomal dominant hearing impairment DFNA15 and affect subcellular localization and DNA binding. *Hum Mutat*. 2008; 29:545–554. [PubMed: 18228599]
18. Phelps PD, Reardon W, Pembrey M, Bellman S, Luxom L. X-linked deafness, stapes gushers and a distinctive defect of the inner ear. *Neuroradiology*. 1991; 33:326–330. [PubMed: 1922747]
19. Song MH, Lee HK, Choi JY, Kim S, Bok J, Kim UK. Clinical evaluation of DFN3 patients with deletions in the POU3F4 locus and detection of carrier female using MLPA. *Clin Genet*. 2010; 78:524–532. [PubMed: 20412083]

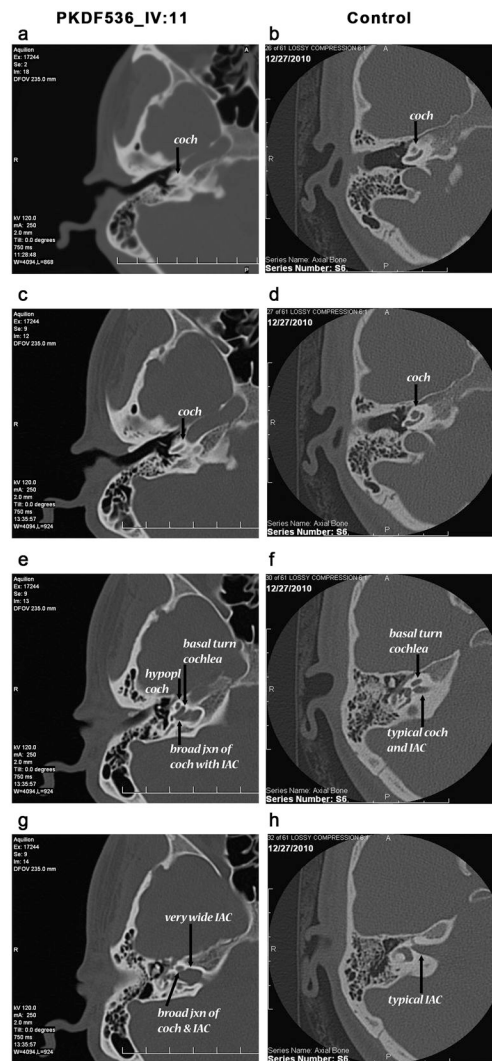


20. Marlin S, Moizard MP, David A, Chaissang N, Raynaud M, Jonard L, Feldmann D, Loundon N, Denoyelle F, Toutain A. Phenotype and genotype in females with POU3F4 mutations. *Clin Genet*. 2009; 76:558–563. [PubMed: 19930154]
21. Samadi DS, Saunders JC, Crenshaw EB 3rd. Mutation of the POU-domain gene *Brn4/Pou3f4* affects middle-ear sound conduction in the mouse. *Hear Res*. 2005; 199:11–21. [PubMed: 15574296]
22. Cremers CW, Hombergen GC, Wentges RT. Perilymphatic gusher and stapes surgery. A predictable complication? *Clin Otolaryngol Allied Sci*. 1983; 8:235–240. [PubMed: 6652936]
23. Staropoli JF, Xin W, Sims KB. Co-segregation of Norrie disease and idiopathic pulmonary hypertension in a family with a microdeletion of the NDP region at Xp11.3-p11.4. *J Med Genet*. 2010; 47:786–790. [PubMed: 20679667]
24. Gal A, Wieringa B, Smeets DF, Bleeker-Wagemakers L, Ropers HH. Submicroscopic interstitial deletion of the X chromosome explains a complex genetic syndrome dominated by Norrie disease. *Cytogenet Cell Genet*. 1986; 42:219–224. [PubMed: 3502689]
25. Sims KB, Ozelius L, Corey T, Rinehart WB, Liberfarb R, Haines J, et al. Norrie disease gene is distinct from the monoamine oxidase genes. *Am J Hum Genet*. 1989; 45:424–434. [PubMed: 2773935]
26. Zhu DP, Antonarakis SE, Schmeckpeper BJ, Diergaarde PJ, Greb AE, Maumenee IH. Microdeletion in the X-chromosome and prenatal diagnosis in a family with Norrie disease. *Am J Med Genet*. 1989; 33:485–488. [PubMed: 2596510]
27. Collins FA, Murphy DL, Reiss AL, Sims KB, Lewis JG, Freund L, Karoum F, Zhu D, Maumenee IH, Antonarakis SE. Clinical, biochemical, and neuropsychiatric evaluation of a patient with a contiguous gene syndrome due to a microdeletion Xp11.3 including the Norrie disease locus and monoamine oxidase (MAOA and MAOB) genes. *Am J Med Genet*. 1992; 42:127–134. [PubMed: 1308352]
28. Rodriguez-Revenga L, Madrigal I, Alkhalidi LS, Armengol L, Gonzalez E, Badenas C, Estivill X, Mila M. Contiguous deletion of the NDP, MAOA, MAOB, and EFHC2 genes in a patient with Norrie disease, severe psychomotor retardation and myoclonic epilepsy. *Am J Med Genet A*. 2007; 143A:916–920. [PubMed: 17431911]
29. Chen ZY, Hendriks RW, Jobling MA, Powell JF, Breakefield XO, Sims KB, Craig IW. Isolation and characterization of a candidate gene for Norrie disease. *Nat Genet*. 1992; 1:204–208. [PubMed: 1303236]
30. Royer G, Hanein S, Raclin V, Gigarel N, Rozet JM, Munnich A, Steffann J, Dufier JL, Kaplan J, Bonnefont JP. NDP gene mutations in 14 French families with Norrie disease. *Hum Mutat*. 2003; 22:499. [PubMed: 14635119]
31. Schuback DE, Chen ZY, Craig IW, Breakefield XO, Sims KB. Mutations in the Norrie disease gene. *Hum Mutat*. 1995; 5:285–292. [PubMed: 7627181]
32. Wu WC, Drenser K, Trese M, Capone A Jr, Dailey W. Retinal phenotype-genotype correlation of pediatric patients expressing mutations in the Norrie disease gene. *Arch Ophthalmol*. 2007; 125:225–230. [PubMed: 17296899]
33. Meire FM, Lafaut BA, Speleman F, Hanssens M. Isolated Norrie disease in a female caused by a balanced translocation t(X,6). *Ophthalmic Genet*. 1998; 19:203–207. [PubMed: 9895245]
34. Sims KB, Irvine AR, Good WV. Norrie disease in a family with a manifesting female carrier. *Arch Ophthalmol*. 1997; 115:517–519. [PubMed: 9109762]
35. Yamada K, Limprasert P, Ratanasukon M, Tengtrisorn S, Yingchareonpukdee J, Vasiknanonte P, Kitaoka T, Ghadami M, Niikawa N, Kishino T. Two Thai families with Norrie disease (ND): association of two novel missense mutations with severe ND phenotype, seizures, and a manifesting carrier. *Am J Med Genet*. 2001; 100:52–55. [PubMed: 11337749]
36. Criswick VG, Schepens CL. Familial exudative vitreoretinopathy. *Am J Ophthalmol*. 1969; 68:578–594. [PubMed: 5394449]
37. de Crecchio G, Simonelli F, Nunziata G, Mazzeo S, Greco GM, Rinaldi E, Ventruto V, Ciccodicola A, Miano MG, Testa F, Curci A, D'Urso M, Rinaldi MM, Cavaliere ML, Castelluccio P. Autosomal recessive familial exudative vitreoretinopathy: evidence for genetic heterogeneity. *Clin Genet*. 1998; 54:315–320. [PubMed: 9831343]

38. Robitaille J, MacDonald ML, Kaykas A, Sheldahl LC, Zeisler J, Dube MP, Zhang LH, Singaraja RR, Guernsey DL, Zheng B, Siebert LF, Hoskin-Mott A, Trese MT, Pimstone SN, Shastry BS, Moon RT, Hayden MR, Goldberg YP, Samuels ME. Mutant frizzled-4 disrupts retinal angiogenesis in familial exudative vitreoretinopathy. *Nat Genet.* 2002; 32:326–330. [PubMed: 12172548]
39. Toomes C, Bottomley HM, Jackson RM, Towns KV, Scott S, Mackey DA, Craig JE, Jiang L, Yang Z, Trembath R, Woodruff G, Gregory-Evans CY, Gregory-Evans K, Parker MJ, Black GC, Downey LM, Zhang K, Inglehearn CF. Mutations in LRP5 or FZD4 underlie the common familial exudative vitreoretinopathy locus on chromosome 11q. *Am J Hum Genet.* 2004; 74:721–730. [PubMed: 15024691]
40. Ye X, Wang Y, Nathans J. The Norrin/Frizzled4 signaling pathway in retinal vascular development and disease. *Trends Mol Med.* 2010; 16:417–425. [PubMed: 20688566]



**Figure 1.** Family PKDF536. **(a)** Pedigree of PKDF536 with seven affected individuals in four sibships. Circles indicate females and fully shaded squares represent males with hearing loss; and the central dot in the female symbol indicate the carrier of the affected X chromosome. **(b–c)** Representative pure-tone air and bone conduction audiometric data of affected individual IV:11 (24 years old) along with a normal hearing subject, III:7 (60 years old). Bilateral severe to profound mixed hearing loss with a significant low frequency conductive hearing loss was observed in the affected individuals of family PKDF536. **(d)** Sequence chromatogram of pathogenic variant, c.406C>T (p.Q136X), along with a homozygous wild type allele.



**Figure 2.** Representative axial and bone-window images from computed tomographic (CT) scans from individual IV:11 of family PKDF536 with p.Q136X mutation in *POU3F4* along with a control subject (with normal hearing, normal CT anatomy and no known deafness-causing genetic mutation). (a–d) Highlights the subtle cochlear hypoplasia associated with the *POU3F4* genotype in comparison to the control subject. While a clear basal turn of the cochlea is apparent in both affected and control subjects (**coch**: cochlea and arrows in a–d), the mid and apical turns are not clearly partitioned in the affected individual. (e, g) Illustrate the modiolar and internal auditory canal anomalies typical in individuals with the *POU3F4* mutation. (f, h) Normal morphology is seen in the control subject. (e) Demonstrates the extremely wide modiolus at the junction of the cochlea with the internal auditory canal (contrast with the typical modiolus and internal auditory canal shown in panel f). (g–h) CT scans from a normal hearing individual to provide a comparison of the dysmorphic internal auditory canals seen in the affected individual (g). This combination of a dilated and dysmorphic internal auditory canal along with the very broad modiolus have been postulated

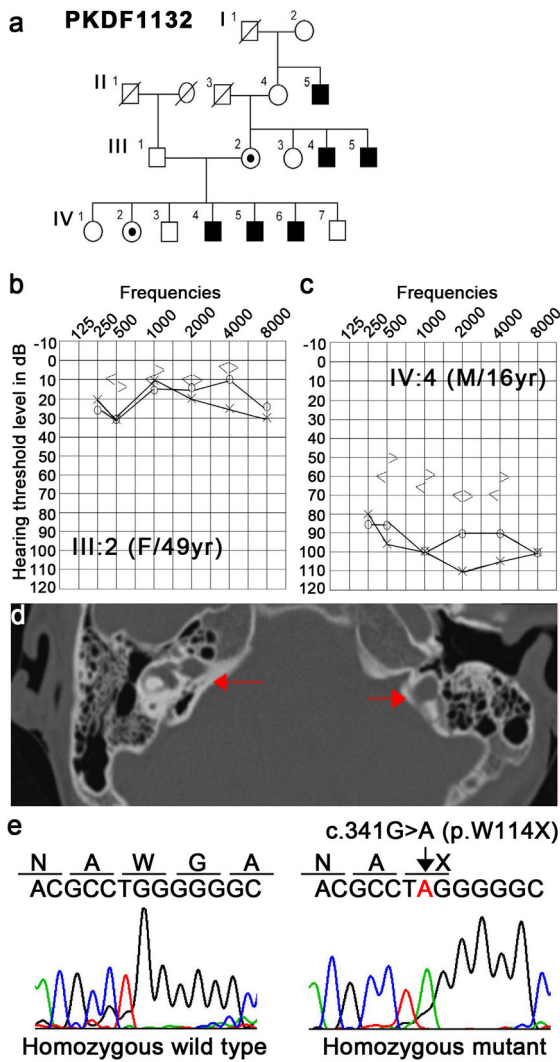
to be the cause of a “stapes gusher” seen at the time of surgery in patients with *POU3F4* mutations.

Author Manuscript

Author Manuscript

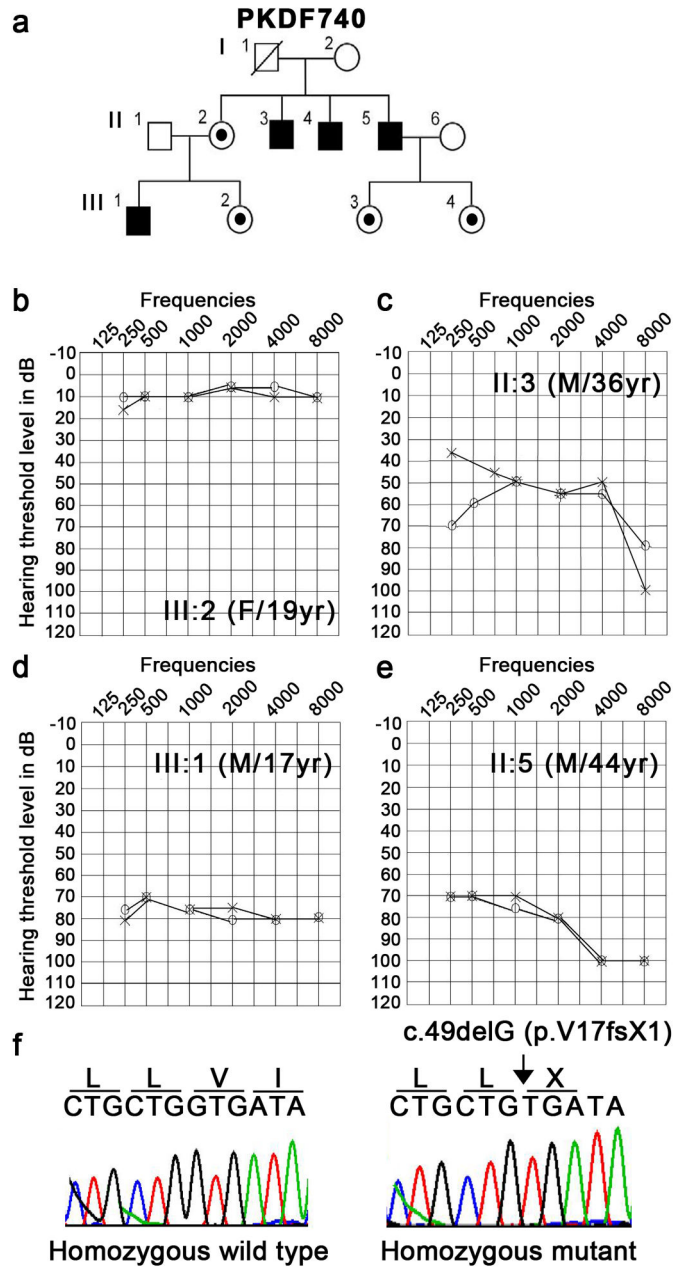
Author Manuscript

Author Manuscript



**Figure 3.** Family PKDF1132. **(a)** Pedigree of family PKDF1132 with six affected individuals present in three sibships. Circles indicate females and fully shaded squares represent males with hearing loss; and the central dot in a female symbol indicates a carrier of a X-linked mutation. **(b–c)** Representative pure-tone air and bone conduction audiometric data of affected individual IV:4 (16 years old male) along with a normal hearing subject, III:2 (49 years old female). Severe to profound mixed hearing loss in both ears was observed in the affected individuals of family PKDF536. **(d)** Temporal bone computed tomography (CT) of individual IV:4. Basal turn of the cochlea was incompletely separated from the internal auditory canal (IAC), and seemed to be a continuation of the IAC. Typically, a bulbous dilation of the lateral end of the IAC (arrow) was identified. **(e)** Sequence chromatogram of pathogenic variant, c.341G>A (p.W114X), along with a homozygous wild type allele.





**Figure 4.** Family PKDF740. **(a)** Pedigree of family PKDF740 with four affected individuals present in two sibships. Circles indicate females and fully shaded squares represent males with hearing loss; and the central dot in a female symbol indicates a carrier of a X-linked mutation. **(b–c)** Pure-tone air conduction audiometric data of three affected individuals along with a normal hearing subject, III:2 (19 years old female). **(b)** Normal hearing thresholds were observed across all frequencies for individual III:2. **(c)** Mild to profound hearing loss was observed in individual II:3. **(d)** Severe hearing impairment across all frequencies were seen in both ears of individual III:1. **(e)** Oldest affected individual, II:5, of family PKDF740 has severe to

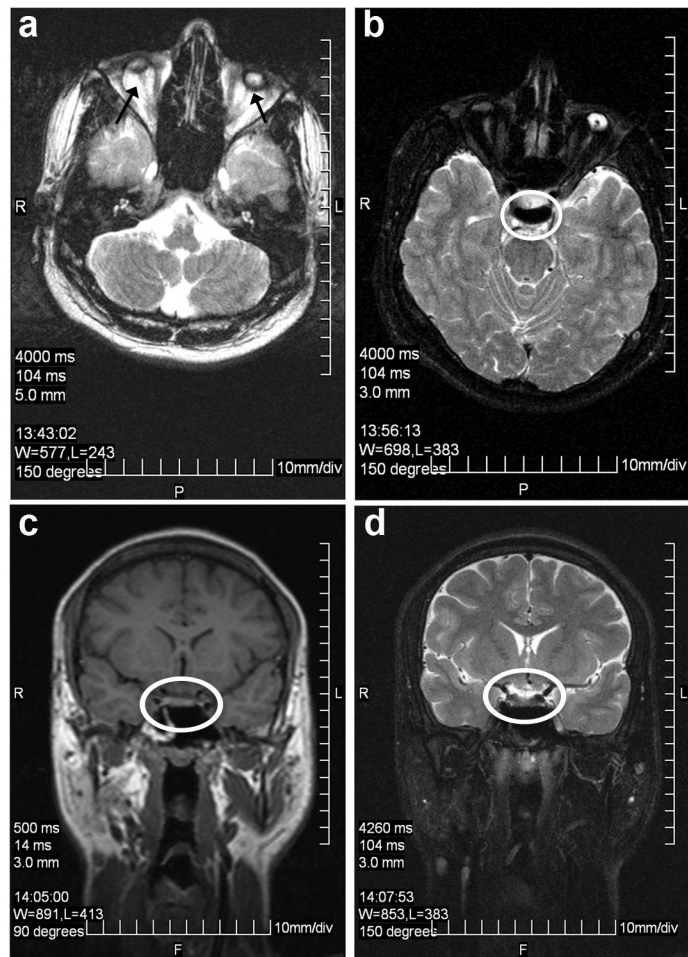
profound hearing loss in both ears. (f) Sequence chromatogram of pathogenic variant, c.49delG (p.V17fsX1), along with a homozygous wild type allele.

Author Manuscript

Author Manuscript

Author Manuscript

Author Manuscript



**Figure 5.** MRI imaging of individual III:1 of family PKDF740. (a) Axial T2 image of microphthalmic phthisical globes with atrophic optic nerves exiting the globes posteriorly bilaterally. (b–d) Optic tracts and chiasm were not discernable on axial T2 (b), coronal T1 (c), and coronal T2 (d) images, indicating either primary hypoplasia or postaxonal degeneration.