



# A CASE OF OPTIC CHIASM STROKE, A CONDITION RARELY DESCRIBED IN THE LITERATURE

Rita Fideles<sup>1</sup>, Marina Coelho<sup>1</sup>, João Araújo<sup>1</sup>, Carolina Gonçalves<sup>2</sup>, Carla Henriques<sup>1</sup>, Ana Costa<sup>1</sup>

<sup>1</sup> Internal Medicine Department, Centro Hospitalar do Oeste, Torres Vedras, Portugal

<sup>2</sup> Neurology Department, Centro Hospitalar Lisboa Ocidental, Lisbon, Portugal

**Corresponding author:** Rita Fideles **e-mail:** ritafideles@gmail.com

**Received:** 15/11/2023 **Accepted:** 27/11/2023 **Published:** 06/12/2023

**Conflicts of Interests:** The Authors declare that there are no competing interests.

**Patient Consent:** The authors state that informed consent was obtained from the patient authorising the publication of his clinical history.

**This article is licensed under a Commons Attribution Non-Commercial 4.0 License**

**How to cite this article:** Fideles R, Coelho M, Araújo J, Gonçalves C, Henriques C, Costa A. A case of optic chiasm stroke, a condition rarely described in the literature. *EJCRIM* 2023;10:doi:10.12890/2023\_004213.

## ABSTRACT

Acute bilateral blindness is an emergent condition that may signal life-threatening disease. The approach focuses on identification of life-threatening disease processes, while differentiating between ocular, psychogenic and neurologic aetiologies. We present the case of an 88-year-old man with multiple cardiovascular risk factors and bilateral chronic glaucoma and cataracts. He presented to the emergency department with sudden onset bilateral loss of visual acuity with no other relevant changes on physical examination, including other neurologic deficits. Ophthalmologic observation showed no sign of acute disease.

Contrast orbit and cranioencephalic CT was unremarkable, so the patient underwent an orbit and cranioencephalic MRI that showed changes in fluid-attenuated inversion recovery (FLAIR) sequences and diffusion restriction involving the optic chiasm and the initial segment of the optic radiations bilaterally. Optic chiasm strokes are rare, owing to the rich supply of collateral circulation. The most frequent presentation is bitemporal hemianopsia but rarer presentations are described. Bilateral loss of visual acuity is very rare and infarction of the whole optic chiasm is unusual.

## KEYWORDS

Optic chiasm stroke, neuroimaging, bilateral loss of visual acuity

## LEARNING POINTS

- Acute bilateral blindness has an extensive differential diagnosis but chiasmopathy of ischaemic aetiology is rare.
- Optic chiasm stroke is rarely described in the literature and can pose a diagnostic challenge as its presentation can vary greatly.

## INTRODUCTION

Acute bilateral blindness has an extensive differential diagnosis that requires a careful history and physical examination to narrow it down. Possible causes include bilateral occipital infarcts, endogenous bacterial

endophthalmitis, orbital cellulitis, orbital compartment syndrome, cavernous sinus thrombophlebitis, thyroid disease and bilateral nonarteritic ischaemic optic neuropathy, but chiasmopathy of ischaemic aetiology has been reported previously as a rare cause acute bilateral



blindness<sup>[1,2]</sup>. Involvement of multiple medical specialities, usually internal medicine, ophthalmology and neurology, is often required to adequately diagnose and treat patients.

## CASE DESCRIPTION

The case involves an 88-year-old male with past medical history of arterial hypertension, type 2 diabetes mellitus, dyslipidaemia, and bilateral chronic glaucoma and cataract. He had presented to the emergency department with sudden bilateral loss of visual acuity 6 hours earlier.

On physical examination at the bedside, the blink-to-visual-threat reflex was absent bilaterally; however, there was no anisocoria or relative afferent pupillary defect, ptosis or ophthalmoplegia. Anterior segment examination showed no acute disease with pseudophakia, and normal intraocular pressure. Dilated fundus examination was normal. There were no other focal neurological deficits. The patient was hypertensive (blood pressure 165/80 mmHg) and hyperglycaemic (glycaemia 280 mg/dl), but there was nothing else of note on general or neurological examination. A contrast CT scan of the orbit was unremarkable and the contrast cranioencephalic CT scan showed no ischaemic lesions or arterial stenosis, including in the visual cortex.

The patient underwent a cranioencephalic and orbit MRI at day three of symptoms that showed signal changes in fluid-attenuated inversion recovery (FLAIR) sequences and diffusion restriction involving the optic chiasm and the initial segment of the optic radiations bilaterally (Fig. 1), suggestive of ischaemic stroke of the optic chiasm in relation to small vessel atherosclerotic disease.

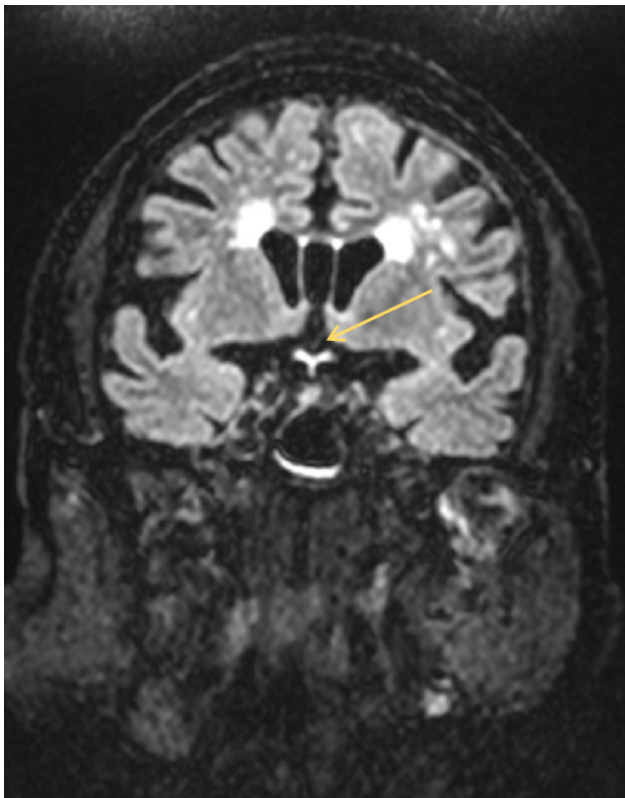


Figure 1. Coronal view of MRI FLAIR sequence showing enhancement of the optic chiasm (arrow)

Three months after discharge the patient was re-evaluated in internal medicine consultation, maintaining the same visual acuity deficit.

## DISCUSSION

Optic chiasm stroke is rarely described in the literature. Its myriad of clinical syndromes can pose a diagnostic challenge as the extension of the involvement of the optic fibres can vary greatly. Chiasmatal strokes are rare, owing to the rich supply of collateral circulation provided by the circle of Willis to the optic chiasm, and there is little knowledge about interindividual variations of vascularisation. When chiasmatal strokes do occur, usually patients experience acute onset bitemporal hemianopsia. Other rare clinical presentations have been described such as junctional scotoma, but bilateral loss of visual acuity is even rarer. The CT scan has a low sensitivity to detect ischaemic lesions in this location, so the MRI has a major role in diagnosing this type of minor stroke. No definitive standard treatment options exist due to insufficient evidence. Spontaneous recovery can occur with varying degrees of visual field enlargement, and it predominantly occurs within the first three months following a stroke<sup>[2,3]</sup>.

## CONCLUSION

The authors present this case for its atypical location, with ischaemia involving the entirety of the optic chiasm and the initial segments of the optic radiations bilaterally. This case helps to stress the role of MRI to diagnose minor strokes with atypical clinical presentations to which the CT scan offers limited insight.

## REFERENCES

1. Zarei S, Vo P, Sam C, Crow RW, Stout C, Al-Khoury L. Acute bilateral blindness in the setting of sudden onset of bilateral proptosis and ophthalmoplegia: a case report with literature review. *Neurol Clin Pract* 2021;11:E706–713.
2. Sigireddi RR, Bhat N, Raviskanthan S, Mortensen PW, Bindiganavile SH, Klucznik R, et al. Bitemporal hemianopsia secondary to ischemic chiasmopathy following mechanical thrombectomy. *Am J Ophthalmol Case Rep* 2021;23:101191.
3. Pula JH, Yuen CA. Eyes and stroke: the visual aspects of cerebrovascular disease. *Stroke Vasc Neurol* 2017;2:210–220.