

## Case Report

# Bilateral Thoracic Ganglion Cyst : A Rare Case Report

Burak Kazanci, M.D.,<sup>1</sup> Ozkan Tehli, M.D.,<sup>2</sup> Erhan Türkoglu, M.D.,<sup>3</sup> Bulent Guclu, M.D.<sup>1</sup>

Neurosurgery Clinic,<sup>1</sup> Ministry of Health, Sevkett Yilmaz Education and Research Hospital, Bursa, Turkey

Department of Neurosurgery,<sup>2</sup> Gulhane Military Medical Academy and School of Medicine, Ankara, Turkey

Neurosurgery Clinic,<sup>3</sup> Private Koru Hospital, Ankara, Turkey

Ganglion cysts usually arise from the tissues around the facet joints. It is usually associated with degenerative changes in facet joints. Bilateral thoracic ganglion cysts are very rare and there is no previous case that located in bilateral intervertebral foramen compressing the L1 nerve root associated with severe radiculopathy. We report a 53 years old woman who presented with bilateral groin pain and severe numbness. Magnetic resonance imaging revealed bilateral cystic mass in the intervertebral foramen between 12th thoracic and 1st lumbar vertebrae. The cystic lesions were removed after bilateral exposure of Th12-L1 foramina. The result of histopathology confirmed the diagnosis as ganglion cyst. The ganglion cyst may compromise lumbar dorsal ganglion when it located in the intervertebral foramen. The surgeon should keep this rare entity in their mind for differential diagnosis.

**Key Words :** Ganglion cyst · Radiculopathy · Synovial cyst · Thoracic spine.

## INTRODUCTION

Ganglion cyst usually originates from vertebral facet joints like synovial cyst<sup>8)</sup>. The terms "ganglion cyst" and "synovial cyst" have similar clinical and radiographic features and are considered an extrusion of the synovium through a capsular defect from a degenerative or unstable facet joint. Usually, they are asymptomatic but it may cause symptoms if it compromise the surrounding thecal sac or nerve roots<sup>13,18)</sup>.

## CASE REPORT

A 53-year-old female suffered from severe bilateral groin pain and dysesthesia for three months. She had this intermittent pain for 12 years, but the symptoms became worsening in the last three months. The visual analog scale score for pain was 8 out of 10. The pain was not relieved by conservative treatment. Her medical history was unremarkable. Her neurological examination was normal but she was suffering so much groin pain while walking. Thoracic magnetic resonance imaging (MRI) revealed bilateral, well circumscribed extradural, intraforaminal masses in continuity with the right and left apophyseal joints at

Th12-L1 level (Fig. 1). Sagittal T2-weighted thoracolumbar MRI revealed the bilateral roots compression caused by this cystic lesion cystic lesions at Th12-L1 level (Fig. 2). The patient underwent bilateral hemi-laminectomy and flavectomy at the Th12 level. Using the operative microscope, following exposure the foramina, bilateral cystic masses, emerging from the facet joints and compressing the dural sac and nerve roots were removed. The cysts were adhered tightly to the first lumbar dorsal root ganglion. The histopathological findings were consistent with ganglion cyst (Fig. 3). The patient made an excellent post-operative recovery with full resolution of preoperative symptoms.

## DISCUSSION

The terms intraspinal ganglion and synovial cysts are used interchangeably, but the presence or absence of a synovial lining membrane is the distinguishing feature. These two entities are more likely different endpoints of the same etiopathologic process. They have similar clinical and radiographic features and are considered an extrusion of the synovium through a capsular defect from a degenerative or unstable facet joint. The ganglion/

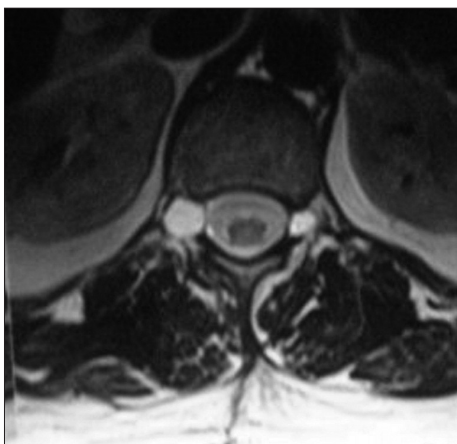
• Received : March 29, 2012 • Revised : February 12, 2013 • Accepted : April 8, 2013

• Address for reprints : Erhan Türkoglu, M.D.

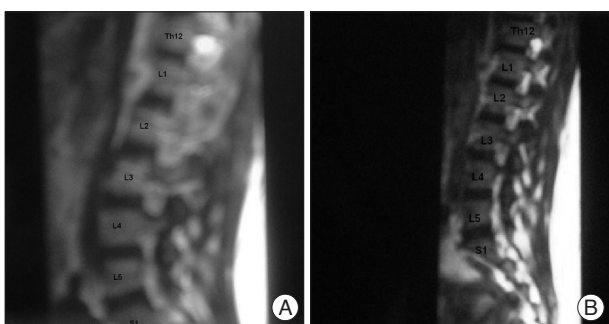
Private Koru Hospital, Neurosurgery Clinic, Cukurambar Mah. Ogretmenler Cad. Kardelen Apt. No.5/6 Cankaya, 06290, Ankara, Turkey

Tel : +903542121070, Fax : +903124359506, E-mail : drmet122@yahoo.com

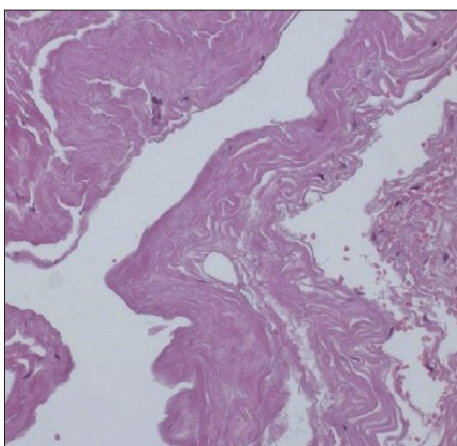
• This is an Open Access article distributed under the terms of the Creative Commons Attribution Non-Commercial License (<http://creativecommons.org/licenses/by-nc/3.0>) which permits unrestricted non-commercial use, distribution, and reproduction in any medium, provided the original work is properly cited.



**Fig. 1.** Axial T2-weighted thoracolumbar MRI shows cystic mass in the bilateral intervertebral foramen between 12th thoracic and 1st lumbar vertebrae.



**Fig. 2.** Preoperative right sided (A) and left sided (B) sagittal T2 images shows cystic mass associated with the synovial joints bilaterally as well as bilateral nerve roots compression.



**Fig. 3.** Photomicrographs shows the wall of the cyst is lined by nonsynovial flattened cells and is surrounded by a dense inflammatory cell.

synovial cysts generally arise from facet joint but they may arise also from ligamentum flavum, posterior longitudinal ligament, annulus fibrosus and disc itself<sup>3,8,17</sup>. The majority of ganglion cysts in the lumbar spine occur at L4-L5 level and occasionally at L5-S1 and L3-L4<sup>1,8,9,14</sup>. Intraforaminal cysts at Th12-L1 level and bilateral formation are very rare<sup>6</sup>. Cysts in the cervical spine and thoracic spine are also more rare<sup>2,4,10</sup>.

The pathogenesis of ganglion cysts is the subject of considerable controversy in the literature, but the most accepted etiology is the herniation of synovial tissue and its content from the articular cavity through a defect in the wall of the articular capsule<sup>3</sup>. The possible causative factors include repetitive trauma, spondylolysis, facet arthrosis, myxoid degeneration, proliferation of mesenchymal cells, and increased hyaluronidase production. Increased stress placed on the mobile segment of the vertebrae may precipitate the development of the ganglion cyst<sup>15</sup>.

The clinical presentation of a ganglion cyst depends on its site, size and relationship with surrounding structures. Ganglion cysts usually are asymptomatic due to mostly located on the dorsal aspect of facet joints. According to its location, ganglion cyst may cause neurogenic claudication, cauda equine syndrome or radicular pain<sup>13</sup>. Acute radicular pain may be associated with intracystic haemorrhage and can result from acute cyst distention or compression of a nervous element<sup>8</sup>. Surgical treatment is recommended if it is causing intractable pain and/or neurological deficit<sup>12</sup>. The use of newer imaging modalities such as CT and MRI increased the frequency of preoperative diagnosis of this pathology that could once be identified during surgery<sup>1,5</sup>. MRI is the modality of choice for the diagnosis of ganglion cysts<sup>11,16</sup>. Ganglion cysts appear high signal intensity lesions with a fibrous capsule on T2 weighted image. In the differential diagnosis, extruded or sequestered disc fragment, cyst of the ligamentum flavum, perineural cyst, schwannoma, meningioma, metastasis, arachnoid cysts and rheumatoid pannus should be considered<sup>1,3,7</sup>.

### CONCLUSION

The ganglion cyst occurs mostly in the dorsolateral trunk and arise with the greatest frequency in the lumbar spine and less frequently in the cervical and thoracic spine. They may cause symptoms if they located in the intervertebral foramens and compromise dorsal root ganglion. This is an uncommon case that ganglion cyst is located at Th12-L1 intervertebral foramens, bilaterally.

### References

1. Boviatisis EJ, Stavrinou LC, Kouyialis AT, Gavra MM, Stavrinou PC, Themistokleous M, et al. : Spinal synovial cysts : pathogenesis, diagnosis and surgical treatment in a series of seven cases and literature review. *Eur Spine J* 17 : 831-837, 2008
2. Cheng YY, Chen CC, Yang MS, Hung HC, Lee SK : Intraspinal extradural ganglion cyst of the cervical spine. *J Formos Med Assoc* 103 : 230-233, 2004
3. Cho SM, Rhee WT, Lee SY, Lee SB : Ganglion cyst of the posterior longitudinal ligament causing lumbar radiculopathy. *J Korean Neurosurg Soc* 47 : 298-301, 2010
4. Cohen-Gadol AA, White JB, Lynch JJ, Miller GM, Krauss WE : Synovial cysts of the thoracic spine. *J Neurosurg Spine* 1 : 52-57, 2004
5. Hemminghytt S, Daniels DL, Williams AL, Houghton VM : Intraspinal synovial cysts : natural history and diagnosis by CT. *Radiology* 145 : 375-376, 1982

6. Holtzman RN, Dubin R, Yang WC, Rorat E, Liu HM, Leeds NE : Bilateral symptomatic intraspinal T12-L1 synovial cysts. *Surg Neurol* **28** : 225-230, 1987
7. Kao CC, Uihlein A, Bickel WH, Soule EH : Lumbar intraspinal extradural ganglion cyst. *J Neurosurg* **29** : 168-172, 1968
8. Kim SW, Choi JH, Kim MS, Chang CH : A ganglion cyst in the second lumbar intervertebral foramen. *J Korean Neurosurg Soc* **49** : 237-240, 2011
9. Liu SS, Williams KD, Drayer BP, Spetzler RF, Sonntag VK : Synovial cysts of the lumbosacral spine : diagnosis by MR imaging. *AJNR Am J Neuroradiol* **10** : 1239-1242, 1989
10. Lopes NM, Aesse FF, Lopes DK : Compression of thoracic nerve root by a facet joint synovial cyst : case report. *Surg Neurol* **38** : 338-340, 1992
11. Martin D, Awwad E, Sundaram M : Radiologic case study. Lumbar ganglion cyst causing radiculopathy. *Orthopedics* **13** : 1177, 1182-1183, 1990
12. Oertel ME, Ryang Y, Ince A, Gilsbach JM, Rohde V : Microsurgical therapy of symptomatic lumbar juxta facet cysts. *Minim Invasive Neurosurg* **46** : 349-353, 2003
13. Pendleton B, Carl B, Pollay M : Spinal extradural benign synovial or ganglion cyst : case report and review of the literature. *Neurosurgery* **13** : 322-326, 1983
14. Radatz M, Jakubowski J, Cooper J, Powell T : Synovial cysts of the lumbar spine : a review. *Br J Neurosurg* **11** : 520-524, 1997
15. Shah RV, Lutz GE : Lumbar intraspinal synovial cysts : conservative management and review of the world's literature. *Spine J* **3** : 479-488, 2003
16. Weyns F, Van Calenbergh F, Goffin J, Plets C : Intraspinal juxta-facet cysts : a case of bilateral ganglion cysts. *Clin Neurol Neurosurg* **94** : 55-59, 1992
17. Wilby MJ, Fraser RD, Vernon-Roberts B, Moore RJ : The prevalence and pathogenesis of synovial cysts within the ligamentum flavum in patients with lumbar spinal stenosis and radiculopathy. *Spine (Phila Pa 1976)* **34** : 2518-2524, 2009
18. Yamamoto A, Nishiura I, Handa H, Kondo A : Ganglion cyst in the ligamentum flavum of the cervical spine causing myelopathy : report of two cases. *Surg Neurol* **56** : 390-395, 2001