

Thoracic Ganglioneuroma Presenting with Paraneoplastic Cerebellitis and ROHHAD-NET Syndrome

Sir,

Rapid-onset obesity with hypoventilation, Hypothalamic dysfunction, and Autonomic Dysregulation Syndrome (ROHHAD) is a rare pediatric onset syndrome with a female preponderance.^[1] Later, the acronym was extended to ROHHAD-NET (ROHHAD Neuro Endocrine Tumors) in 2008 in view of increased risk of neural crest origin tumors, particularly ganglioneuroma or ganglioneuroblastoma in approximately 40%–50% of cases.^[1,2] It has been characterized by sequential clinical features usually appearing in the acronym order – rapid onset of obesity being the first and most common feature at presentation followed by features of hypothalamic dysfunction and hypoventilation.^[1,2] The occurrence of hypoventilation, leading to respiratory arrest makes the syndrome more fatal. We report a case of a child who was diagnosed to have ROHHAD-NET syndrome.

A 4-year-old girl presented with complaints of hyperphagia, associated weight gain, and episodes of inappropriate laughter of 6 months duration. The perinatal and past history was unremarkable. On examination, she was playful and cooperative. Her blood pressure readings showed some variation, but most of them were in the hypertensive range. Her weight was 22.4 kg (weight for age Z score + 2.2 standard deviation), and her height was 98 cm (height for age Z score was -1.2 standard deviation). Thyroid hormone and baseline cortisol levels were within normal limits. Bone age was normal. Renal ultrasound with renal artery doppler done for hypertension workup was normal.

Brain magnetic resonance imaging (MRI) was done to look for hypothalamic abnormalities. It showed diffuse cerebellar atrophy with prominent folial spaces and the fourth ventricle along with mild atrophy of the midbrain [Figure 1a and b]. Hypothalamus was morphologically normal. The presence of the cerebellar and midbrain atrophy prompted screening of the spine to look for a paraneoplastic etiology. MRI spine showed a well-defined left paravertebral enhancing solid mass lesion measuring 2.3 cm (anteroposterior) × 2.5 cm (width) × 3.8 cm (craniocaudal extension) spanning from the 2nd thoracic vertebra (T2) to 5th thoracic vertebra (T5) level with extension into the extradural spinal canal along the left neural exit foramina at T2-3 and T3-4 levels without any significant spinal cord compression [Figure 1c-f]. The mass was extending laterally along the intercostal nerves. The imaging features were suggestive of a left thoracic paravertebral neural crest tumor (ganglioneuroma/ganglioneuroblastoma) with paraneoplastic cerebellitis.

The child underwent an uneventful thoracoscopic excision of the tumor. The resected tumor specimen, on gross examination, was well-circumscribed, smooth, gray-white, firm in consistency, and had a whorled appearance. Microscopic examination showed spindle cells arranged in irregular short fascicles and whorls in the background of schwannian stroma. Singly scattered and small clusters of mature ganglion cells were seen in the stroma [Figure 1g]. Neuroblastomatous component was absent. The histopathological features were consistent with ganglioglioma. At a follow-up of 1 year, the child is doing well with no features of hypoventilation.

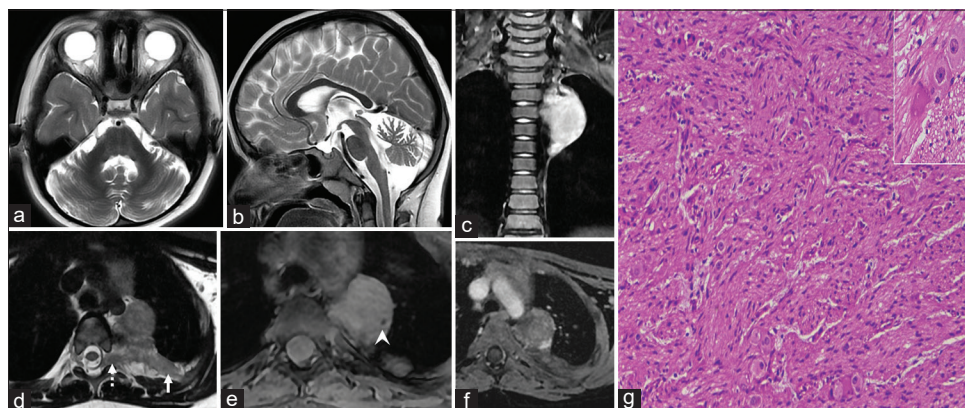


Figure 1: MR imaging of the brain and spine. (a) Axial, (b) sagittal T2W images of the brain show diffuse cerebellar atrophy with prominent folial spaces. (c) Coronal STIR, (d) axial T2W images reveal a well-defined left paravertebral solid mass lesion extending from D2-D5 thoracic vertebral levels with extension into the extradural spinal canal along the left neural exit foramina without any spinal cord compression (dashed arrow). The lateral extension is noted along the intercostal nerves (white arrow). (e) Axial gradient image shows calcification within the lesion (arrowhead). (f) Postcontrast T1W image reveals only minimal enhancement. (g) Microphotograph of Hematoxylin-eosin (H and E) sections at higher magnification (100×) shows irregularly formed fascicles in schwannian stroma with scattered mature ganglion cells, confirming the diagnosis of ganglioneuroma. Inset shows a closer view of ganglion cells

ROHHAD/ROHHAD-NET is an exceptionally rare syndrome with only around 117 cases reported worldwide.^[3] The median age at the time of diagnosis is 4 years with a definite female preponderance (F: M =2-3:1).^[1,2] The diagnostic criteria consist of rapid-onset weight gain followed by autonomic dysfunction and hypoventilation appearing after 1.5 years of age. Hypothalamic dysfunction is defined by evidence of more than one of the following: Rapid onset obesity, endocrine abnormalities like central hypothyroidism, hyperprolactinemia, failed growth hormone stimulation test, disordered water balance, and disorders of puberty. Additional symptoms of hypothalamic dysfunction include thermal dysregulation, inappropriate laughter (as seen in our case), and pain hyposensitivity making the clinical presentation variable.^[4] Though in our case, hypoventilation was not evident at the presentation, it has been reported that the interval between the hypothalamic dysfunction and onset of the hypoventilation is variable, and the earliest presentation is almost always rapid onset obesity which was present in our case.^[1,2,4,5] The timeline of disease suggests the onset of central hypoventilation after 2.2–2.6 years of initial diagnosis of rapid-onset obesity.^[2,5] Furthermore, the presence of ganglioneuroma in the present clinical scenario favors the diagnosis of ROHHAD-NET, and we were able to diagnose the entity before the onset of hypoventilation.

Being a rare entity, this condition is usually not considered in the evaluation of the rapid onset of childhood obesity, leading to delay in diagnosis and increased morbidity secondary to hypoventilation. The clinical phenotype of ROHHAD syndrome often overlaps with that of Prader-Willi Syndrome (PWS), making PWS a close clinical differential diagnosis.^[6] Congenital central hypoventilation syndrome (CCHS) also has an almost similar clinical presentation with the presence of PHOX2B paired-like homeobox 2B (PHOX2B) mutation helping to differentiate it from ROHHAD.^[1] No genetic mutation has been described in ROHHAD so far.

Neural crest tumors are reported in approximately half of ROHHAD cases which was also present in our case.^[1,2] Though the exact etiology is still unknown, the autoimmune pathogenesis of this syndrome is considered with the detection of the antipituitary and antihypothalamic autoantibodies in serum and cerebrospinal fluid.^[7] It is postulated to result from lymphocytic and histiocytic infiltration of the hypothalamus.^[8] A positive response to immunosuppressive drugs like cyclophosphamide also strengthens the autoimmune etiology of the syndrome.^[9]

Neuroimaging is normal in most cases of the ROHHAD-NET syndrome. Our patient had diffuse cerebellar atrophy which guided us to image the complete craniospinal axis, revealing the thoracic paravertebral ganglioneuroma. Similar paraneoplastic cerebellar degeneration in the pediatric population is also reported with Hodgkin and nonHodgkin lymphoma, langerhans cell histiocytosis, neuroblastomas, and other neural crest-derived tumors. Considering the strong

association with mediastinal and abdominal neural crest tumors, these sites should be imaged in a patient with rapid onset obesity and hypothalamic dysfunction to facilitate early diagnosis of this condition.

Though a rare entity, ROHHAD/ROHHAD-NET syndrome should be considered in the differential diagnosis of a child presenting with rapid weight gain, who was healthy until the early years of life. Hypothalamic dysfunction gives the syndrome variable clinical presentation with the onset of obesity. Early diagnosis is often not delivered making the disease a fatal one due to the hypoventilation leading to cardio-respiratory arrest. Brain imaging is often done to rule out the central causes of obesity and may hint at the findings of paraneoplastic encephalitis. Increased association with neural crest tumors demands chest and abdominal screening which may aid in early diagnosis.

Declaration of patient consent

The authors certify that they have obtained all appropriate patient consent forms. In the form, the patients have given their consent for their images and other clinical information to be reported in the journal. The patient understands that their names and initials will not be published and due efforts will be made to conceal their identity, but anonymity cannot be guaranteed.

Financial support and sponsorship

Nil.

Conflicts of interest

There are no conflicts of interest.

Sarbesh Tiwari, Mufeed Arimbrakkunanan, Taruna Yadav, Varuna Vyas¹, Kirti K. Rathod², Vikarn Vishwajeet³

Departments of Diagnostic and Interventional Radiology, ¹Pediatrics, ²Pediatric Surgery and ³Pathology, All India Institute of Medical Sciences, Jodhpur, Rajasthan, India

Address for correspondence: Dr. Taruna Yadav, Department of Diagnostic and Interventional Radiology, All India Institute of Medical Sciences, Jodhpur - 342 005, Rajasthan, India. E-mail: drtanu.taruna@gmail.com

REFERENCES

1. Lee JM, Shin J, Kim S, Gee HY, Lee JS, Cha DH, *et al.* Rapid-onset obesity with hypoventilation, hypothalamic, autonomic dysregulation, and neuroendocrine tumors (ROHHADNET) syndrome: A systematic review. *Biomed Res Int* 2018;2018:1250721. doi: 10.1155/2018/1250721.
2. Harvengt J, Gernay C, Mastouri M, Farhat N, Lebrethon MC, Seghaye MC, *et al.* ROHHAD (NET) Syndrome: Systematic review of the clinical timeline and recommendations for diagnosis and prognosis. *J Clin Endocrinol Metab* 2020;105:dga247. doi: 10.1210/clinem/dgaa247.
3. Jalal Eldin AW, Tombayoglu D, Butz L, Affinati A, Meral R, Ontan MS, *et al.* Natural history of ROHHAD syndrome: Development of severe insulin resistance and fatty liver disease over time. *Clin Diabetes Endocrinol* 2019;5:9.
4. Ma GM, Chow JS, Taylor GA. Review of paraneoplastic syndromes in children. *Pediatr Radiol* 2019;49:534-50.
5. Ize-Ludlow D, Gray JA, Sperling MA, Berry-Kravis EM, Milunsky JM, Farooqi IS, *et al.* Rapid-onset obesity with hypothalamic dysfunction, hypoventilation, and autonomic dysregulation presenting in childhood.

- Pediatrics 2007;120:e179-88.
6. Kocaay P, Şıklar Z, Çamtosun E, Kendirli T, Berberoğlu M. ROHHAD syndrome: Reasons for diagnostic difficulties in obesity. *J Clin Res Pediatr Endocrinol* 2014;6:254-7.
 7. Giacomozzi C, Guaraldi F, Cambiaso P, Niceta M, Verrillo E, Tartaglia M, *et al.* Anti-hypothalamus and anti-pituitary autoantibodies in ROHHAD syndrome: Additional evidence supporting an autoimmune etiopathogenesis. *Horm Res in Paediatr.* 2019;92:124-32.
 8. Ibáñez-Micó S, Marcos Oltra AM, de Murcia Lemauviel S, Ruiz Pruneda R, Martínez Ferrández C, Domingo Jiménez R. Rapid-onset obesity with hypothalamic dysregulation, hypoventilation, and autonomic dysregulation (ROHHAD syndrome): A case report and literature review. *Neurologia* 2017;32:616-22.
 9. Jacobson LA, Rane S, McReynolds LJ, Stepan DA, Chen AR, Paz-Priel I. Improved behavior and neuropsychological function in children with ROHHAD after high-dose cyclophosphamide. *Pediatrics* 2016;138:e20151080.

Submitted: 29-Apr-2021 **Revised:** 07-Aug-2021

Accepted: 25-Aug-2021 **Published:** 08-Feb-2022

This is an open access journal, and articles are distributed under the terms of the Creative Commons Attribution-NonCommercial-ShareAlike 4.0 License, which allows others to remix, tweak, and build upon the work non-commercially, as long as appropriate credit is given and the new creations are licensed under the identical terms.

DOI: 10.4103/aian.aian_372_21