

## Massive biloma presenting as gastric outlet obstruction

Emmanuel C. Gorospe, Cadman L. Leggett, Nikhil A. Nadkarni

St. Mary's Hospital, Rochester, Minnesota, USA

Bile leaks are an important cause of morbidity after living donor liver transplantation (LDLT). This complication occurs in the early postoperative period and has an incidence of 15-40% [1]. These images (Figs. 1 and 2) are from a 57-year-old female who presented with symptoms of gastric outlet obstruction and was found to have a massive biloma. She had undergone a LDLT for hepatitis C cirrhosis one month prior to presentation. The liver transplantation was performed with a biliary duct-to-duct anastomosis with unremarkable immediate perioperative course. Two weeks after transplantation, she began to complain of abdominal fullness, nausea and vomiting.

On admission, a CT abdomen revealed a large fluid collection in the lesser sac, resulting in almost complete gastric compression (Fig. 1). CT-guided aspiration and placement of a 10-French locking loop pigtail catheter drained 1 L of bilious fluid. Cholangiography confirmed a native distal bile duct with narrowing at the anastomosis. A localized, free-flowing, high-grade bile leak was observed above the anastomosis (Fig. 2). This was accessed with a guidewire, dilated with a 4-mm balloon and stented with a 7-French plastic stent. The percutaneous drainage output subsequently decreased with improvement in abdominal fullness and nausea, prompting discontinuation of the percutaneous drain. The plastic biliary stent was removed after 8 weeks. There was no recurrence of the biloma.

The treatment of biloma may require either endoscopic management or percutaneous intervention. Surgical drainage and bile duct repair may be warranted in cases of persistent biloma after endoscopic intervention [2].

### References

1. Ramacciato G, Varotti G, Quintini C, et al. Impact of biliary complications in right lobe living donor liver transplantation. *Transpl Int* 2006;**19**:122-127.
2. Kawachi S, Shimazu M, Wakabayashi G, et al. Biliary complications in adult living donor liver transplantation with duct-to-duct hepaticocholedochostomy or Roux-en-Y hepaticojejunostomy biliary reconstruction. *Surgery* 2002;**132**:48-56.

Division of Gastroenterology and Hepatology, St' Mary's Hospital, Rochester, Minnesota, USA

Conflict of Interest: None

Correspondence to: Emmanuel C. Gorospe, MD, MPH, CNSC, Alfred-Main Endoscopy, St. Mary's Hospital, 1216 Second Street SW, Rochester, Minnesota, USA 55902, Tel: +1 507 538 1231, Fax: +1 507 284 0538, e-mail: gorospe.emmanuel@mayo.edu

Received 5 December 2011; accepted 15 December 2011

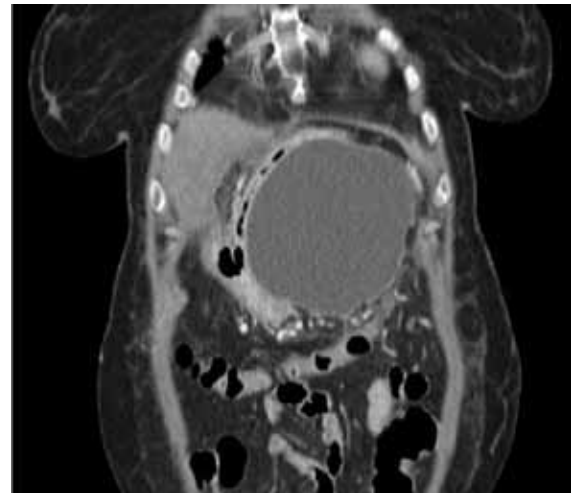


Figure 1 Massive biloma compressing the stomach

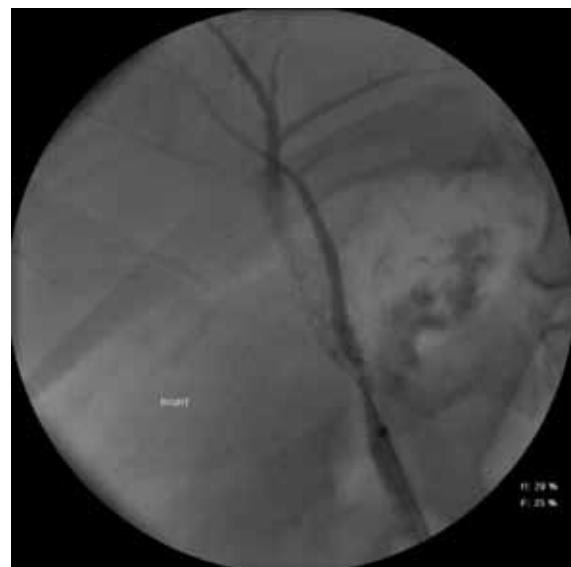

Figure 2 Bile leak above the duct anastomosis