



LAPAROSCOPY / ROBOTICS
ORIGINAL ARTICLE

The long-term results of laparoscopic retroperitoneal pyeloplasty in adults



Mohamed M. Gargouri *, Yassine Nouria, Yousri Kallel, Ahmed Sellami, Rami Boulma, Chlif Mohamed, Sami Ben Rhouma

Department of Urology, La Rabta University Hospital, Tunis, Tunisia

Received 12 May 2013, Received in revised form 29 August 2013, Accepted 1 September 2013
Available online 29 September 2013

KEYWORDS

Laparoscopy;
Pelvi-ureteric junction obstruction;
Pyeloplasty;
Retroperitoneal;
Outcome

ABBREVIATIONS

LRP, laparoscopic retroperitoneal pyeloplasty;
PUJO, pelvi-ureteric junction obstruction

Abstract Objectives: To report the long-term outcome of laparoscopic retroperitoneal pyeloplasty (LRP) in adults.

Patients and methods: Thirty patients underwent LRP for primary pelvi-ureteric junction obstruction (PUJO). Anderson–Hynes dismembered pyeloplasty was used in 28 patients and a Foley Y–V pyeloplasty in two. A JJ stent was inserted antegradely during the procedure. Patients were reviewed at 1 month after LRP for stent removal, and then at 6 and 12 months routinely, using excretory urography.

Results: The mean patient age was 29.7 years, with a female predominance of 60%. Conversion to open surgery was mandated by dense adhesions secondary to previous pyelonephritis in three patients, and difficulty in suturing in one. The mean (range) operative duration was 228 (190–280) min. There was a crossing vessel in 11 patients and it was not transposed in any. The mean hospital stay after LRP was 4.2 days. The mean (range) follow-up was 60 (29–106) months. Of the 26 patients who had complete laparoscopic procedures, 23 had no evidence of obstruction on long-term postoperative intravenous urography and/or diuretic renography.

Conclusion: LRP combines the high functional success rate of open pyeloplasty in the long term and the minimally invasive morbidity of laparoscopy.

© 2013 Production and hosting by Elsevier B.V. on behalf of Arab Association of Urology.

* Corresponding author. Tel.: +216 98695753.
E-mail address: gargourimourad@yahoo.fr (M.M. Gargouri).
Peer review under responsibility of Arab Association of Urology.



Production and hosting by Elsevier

Introduction

Open pyeloplasty has been the standard procedure for correcting pelvi-ureteric junction obstruction (PUJO), with success rates of >90% in the long term [1,2]. In this

present era of laparoscopic surgery, virtually all open urological procedures have been reproduced laparoscopically. Laparoscopic pyeloplasty is no exception, and results equivalent to open surgery were reported [3,4]. This enthusiasm for the laparoscopic approach is mainly fuelled by the significant reduction in the morbidity resulting from the flank incision of open surgery.

Although there are many reports of transperitoneal laparoscopic pyeloplasty, few authors report the results of laparoscopic retroperitoneal pyeloplasty (LRP) [5]. This might be due to the very confined retroperitoneal space that makes the retroperitoneal approach less appealing. Here we report the long-term results of LRP and use this experience as a background to discuss the technical issues.

Patients and methods

From January 2003 to December 2008, 30 patients underwent LRP for primary PUJO at our institution. Patients were evaluated before LRP with excretory urography, ultrasonography and/or diuretic renography. The reconstruction used in each patient was most often an Anderson–Hynes dismembered pyeloplasty, but two were judged as suitable for a non-dismembered pyeloplasty because of a high ureteric insertion in the pelvis, so a Foley Y–V pyeloplasty was used. A retroperitoneal approach was used in all patients.

Patients were reviewed at 1 month after LRP, for stent removal, and then at 6 and 12 months routinely with excretory urography.

We evaluated patient demographic data, the results of preoperative investigations, operative details, hospital course, and complications for all patients. Objective success was determined by the absence of symptoms and the absence of obstruction on excretory urography.

Technique

All patients were assessed using cystoscopy and a 6 F open-tip ureteric catheter was placed immediately before LRP. The catheter facilitated the identification and dissection of the ureter during surgery. Its extremity was kept plugged and sterile for the retrograde insertion of a guidewire to facilitate placing a JJ stent. The patient was then turned into a full-flank position with the side ipsilateral to the PUJ uppermost, and the surgery was carried out as described previously by Nourira et al. [6]. The trocar placements are shown in Fig. 1.

The ureter was located, dissected and traced to the PUJ. Complete mobilisation of the PUJ and the pelvis is necessary before excision. The PUJ was then excised and the anastomosis made with 3–0 polyglactin running sutures. After completing the posterior wall anastomosis, a JJ stent was placed antegradely on a guidewire pushed through the previously placed open-tip ureteric

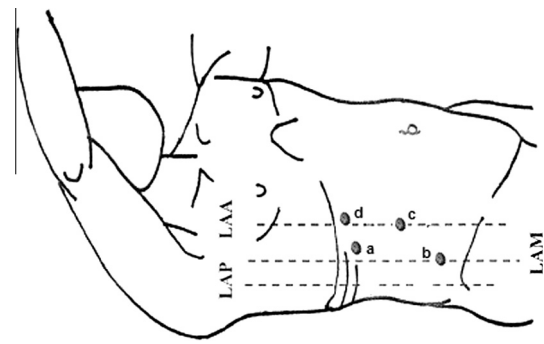


Figure 1 Trocar placement: (a) the 10-mm port for the telescope at the extremity of the 12th rib; (b) The 10-mm port above the iliac crest in the mid-axillary line; (c) The 5-mm port on the anterior axillary line midway between the two other ports; (d) A 10-mm optional port in the anterior axillary line just below the rib margin.

catheter, according to our technique reported previously [7]. Once the JJ stent was secured in the pelvis, the anterior wall of the PUJ anastomosis was completed. A perirenal suction drain was left in place and removed when producing < 50 mL daily.

Results

All patients had primary PUJO, and Table 1 summarises all the demographic and operative results. Because of infection, two patients needed preoperative decompression of the pelvicalyceal system with a nephrostomy. Six patients had concomitant stone disease and so required stone extraction at the time of pyeloplasty. In three patients conversion to open surgery was mandated by dense adhesions secondary to previous pyelonephritis, and in one because of difficulty in suturing, early in our experience. There were minor postoperative complications in three patients, consisting of pyelonephritis in two, and one with a urinoma requiring percutaneous drainage. There were no major complications during or after LRP in this series. The intraoperative blood loss

Table 1 The demographic and operative results of the 30 patients.

Variable	Value
Mean (range) age (years)	29.7 (18–53)
Male/female	11/19
Operative side, R/L	17/13
Concomitant stone disease, n (%)	6 (20)
Preoperative nephrostomy, n (%)	2 (6.6)
Crossing vessel present, n (%)	11(36)
Transposing of a crossing vessel	0
Mean operative time (min)	228
Conversion to open surgery, n (%)	4 (13)
<i>Complications</i>	
Intraoperative	0
Postoperative	3 ^a
Mean hospital stay (days)	4.2

^a Pyelonephritis; prolonged anastomotic leak.

was < 50 mL in all patients. The mean (range) operative duration, measured from the initial cystoscopy to completion of the procedure, was 228 (190–280) min.

There was a crossing vessel in 11 patients and it was not transposed with the PUJ in any patient. The peri-renal drain was removed at 2 or 3 days after LRP. The mean hospital stay after LRP was 4.2 days. All patients had their JJ stents removed by 1 month after LRP. The mean (range) follow-up was 60 (29–106) months.

Of the 26 patients who had complete LRPs, 23 had no evidence of obstruction on IVU and/or diuretic renography. Three patients had a very dilated renal pelvis with persistent obstruction detected on renography, although they were asymptomatic. In one patient the kidney was eventually destroyed and she had a nephrectomy. The other two had no further procedures, as the ipsilateral renal function did not decline excessively.

Discussion

Laparoscopic pyeloplasty was initially reported by Kavoussi and Peters in 1993 [8]. It has been shown to be safe and effective for treating PUJO. The reported success rate can be up to 95% after robotic or laparoscopic procedures [9–12]. In the present study the 5-year success rate for LRP was 88%, and this is equivalent to the results from the open technique. Our success rate was less than for other laparoscopic procedures probably because of bias in the selection of our patients. We used LRP in some young adults who could have had a nephrectomy rather than pyeloplasty, because of significant dilation, had they been older.

The laparoscopic approach can be transperitoneal or retroperitoneal, with a good success rate, and lower morbidity and shorter convalescence than after open surgery [3,4]. The retroperitoneal approach has the advantage of direct access to the urinary system, an easier detection of crossing vessels, and a lower morbidity if there is urinary leakage. However, because this approach has a limited working space that makes dissection and especially suturing more difficult, it is less appealing than the transperitoneal approach, and only a few series have been reported to date.

The first prospective randomised study comparing the transperitoneal and retroperitoneal approach was reported in 2007 by Shoma et al. [13]. Those authors found that both approaches had comparable outcomes, with no significant difference in the success rate, but the retroperitoneal approach was associated with a longer operation (189 vs. 149 min). A recent report [14] showed that both the transperitoneal and retroperitoneal approaches can be used for laparoscopy as a minimally invasive treatment for PUJO, and both are associated with a high success rate and a low complication rate, although the transperitoneal approach provides a quicker operation and a lower conversion rate.

In our department we have used laparoscopic surgery since 2002, and the retroperitoneal approach was always used for PUJO. We started the transperitoneal approach later and used it for adrenal tumours or nephrectomies.

Some authors reported that right-sided retroperitoneoscopic pyeloplasty is easier for right-handed surgeons because of a better working angle [3]. In our series, although we operated on 13 left-sided cases, we did not notice any difference between the sides.

Laparoscopic Anderson–Hynes pyeloplasty is the preferred technique, as it provides better results. In the present series we tried to use that technique, but due to per-operative difficulties we used the Y–V procedure in some patients. A recent report compared these two procedures, finding that laparoscopic Anderson–Hynes pyeloplasty gave a higher success rate than Y–V pyeloplasty, but the difference was not statistically significant [15].

Ureteric stent insertion is a time-consuming step in LRP. To reduce this duration we inserted the JJ stent antegradely on a guidewire pushed through the previously placed open-tip ureteric catheter, as reported previously [7]. Some would prefer to place the stent retrogradely at the beginning of the procedure, but this would deflate the pelvis, and thus we prefer to take advantage of the dilated pelvis during dissection. Also, other authors argue that previous stent placement would hinder the trimming of the ureter and might be the cause of postoperative obstruction [16].

In the present series we found crossing vessels in 11 patients and we did not transpose them in any. This had no effect on the outcome in these patients. In a recent series of robot-assisted laparoscopic dismembered pyeloplasty, the success rates were similar in terms of the change in symptoms and renal function in patients with or without transposition of the anterior crossing vessels. Crossing vessels should only be transposed when the anatomical relationship dictates, and it should be an intraoperative decision [9,17].

In conclusion, LRP in experienced hands combines the high functional success rate of open pyeloplasty and the minimally invasive morbidity of laparoscopy. It is a feasible and reproducible procedure, and is effective, with excellent long-term success rates.

Conflict of interest

None.

Source of funding

None.

References

- [1] Brooks JD, Kavoussi LR, Preminger GM, Schuessler WW, Moore RG. Comparison of open and endourological approaches to the obstructed ureteropelvic junction. *Urology* 1995;46:791–5.

- [2] O'Reilly PH, Brooman PJ, Mak S, Jones M, Pickup C, Atkinson C, et al. The long-term results of Anderson–Hynes pyeloplasty. *BJU Int* 2001;**87**:287–9.
- [3] Bachmann A, Ruszat R, Forster T, Eberli D, Zimmermann M, Müller A, et al. Retroperitoneoscopic pyeloplasty for ureteropelvic junction obstruction (UPJO): solving the technical difficulties. *Eur Urol* 2006;**49**:264–72.
- [4] Soulie M, Salomon L, Patard JJ, Mouly P, Manunta A, Antiphon P, et al. Extraperitoneal laparoscopic pyeloplasty. A multicenter study of 55 procedures. *J Urol* 2001;**166**:48–50.
- [5] Hao G, Xiao J, Yang P, Shen H. Laparoscopic retroperitoneal dismembered pyeloplasty: single-center experience in China. *J Laparoendosc Adv Surg Tech A* 2013;**23**:38–41.
- [6] Nouira Y, Kallel Y, Binous MY, Dahmoul H, Horchani A. Laparoscopic retroperitoneal ureterolithotomy: initial experience and review of literature. *J Endourol* 2004;**18**:557–61.
- [7] Nouira Y, Horchani A. How to insert a double J stent in laparoscopic retroperitoneal dismembered pyeloplasty: a new technique. *Surg Laparosc Endosc Percutan Tech* 2004;**14**:306–8.
- [8] Kavoussi LR, Peters CA. Laparoscopic pyeloplasty. *J Urol* 1993;**150**:1891–4.
- [9] Pardalidis NP, Papatsoris AG, Kosmaoglou EV. Endoscopic and laparoscopic treatment of ureteropelvic junction obstruction. *J Urol* 2002;**168**:1937–40.
- [10] Boyle U, Oommen M, Lee BR, Thomas R. Ureteropelvic junction obstruction secondary to crossing vessels—to transpose or not? The robotic experience. *J Urol* 2009;**181**:1751–5.
- [11] Zaman F, Masood J, Papatsoris A, Albanis S, Junaid I, Buchholz N. Laparoscopic transposition of lower-pole crossing vessels in the management of pelvi-ureteric junction obstruction. *BJU Int* 2008;**101**:1490–2.
- [12] Masood J, Panah A, Zaman F, Papatsoris AG, Buchholz N, Junaid I. Laparoscopic cranial plication in pelviureteral junction obstruction by aberrant lower pole artery. *J Endourol* 2009;**23**:7–10.
- [13] Shoma AM, El Nahas AR, Bazeed MA. Laparoscopic pyeloplasty. A prospective randomized comparison between the transperitoneal approach and retroperitoneoscopy. *J Urol* 2007;**178**:2020–4.
- [14] Wu Y, Dong Q, Han P, Liu L, Wang L, Wei Q. Meta-analysis of transperitoneal versus retroperitoneal approaches of laparoscopic pyeloplasty for ureteropelvic junction obstruction. *J Laparoendosc Adv Surg Tech A* 2012;**22**:658–62.
- [15] Szydelko T, Kasprzak J, Lewandowski J, Apoznanski W, Dembowski J. Dismembered laparoscopic Anderson–Hynes pyeloplasty versus nondismembered laparoscopic Y–V pyeloplasty in the treatment of patients with primary ureteropelvic junction obstruction: a prospective study. *J Endourol* 2012;**26**:1165–70.
- [16] Zhang X, Li HZ, Wang SG, Ma X, Zheng T, Fu B, et al. Retroperitoneal laparoscopic dismembered pyeloplasty: experience with 50 cases. *Urology* 2005;**66**:514–7.
- [17] Gallo F, Schenone M, Giberti C. Ureteropelvic junction obstruction: which is the best treatment today? *J Laparoendosc Adv Surg Tech A* 2009;**19**:657–62.