

Congenital toxoplasmosis after adalimumab treatment before pregnancy

Eloïse Krull¹, Gianmarco Taraschi¹, Emmanuelle Boffi El Amari², Jean-Marie Pellegrinelli¹ and Begoña Martinez de Tejada^{1,3}

¹Obstetrics Service, Department of Pediatrics, Gynecology, and Obstetrics Geneva University Hospitals, Geneva, Switzerland

²Private Practice, Geneva, Switzerland

³Faculty of Medicine, University of Geneva, Geneva, Switzerland

Abstract

We present a case of congenital toxoplasmosis (TXP) in a woman with *Toxoplasma gondii* infection more than 6 months before conception. The woman has been treated with adalimumab for ankylosing spondylitis for 4 years until 5 months before conception. TXP serology at the first trimester was compatible with infection prior pregnancy. An ultrasound performed at 26 weeks gestation (WG) showed cerebral echogenic lesions compatible with intrauterine infection. Amniocentesis was performed which confirmed TXP fetal infection. Termination of the pregnancy was performed upon parent's requests and the fetal autopsy confirmed the diagnosis. Here, we discuss the potential role of immunosuppressive treatments, such as adalimumab, in the risk of congenital toxoplasmosis and the importance of counseling before pregnancy.

Key words: congenital toxoplasmosis, immunosuppressive therapy, infectious diseases, pregnancy, prenatal diagnosis.

Introduction

Toxoplasmosis (TXP) is a common worldwide infection caused by the parasite *Toxoplasma gondii*. In immunocompetent humans, acute infection is often asymptomatic, self-limited and it results in a long-lasting immunity.¹ Since in many countries, like in Switzerland, a universal screening for toxoplasmosis has been dropped out,¹ care should be taken in counseling immunocompromised women during pregnancy.

Here, we discuss the potential role of immunosuppressive treatments, such as adalimumab, in the risk of congenital toxoplasmosis and the importance of counseling before pregnancy.

The Case

A 36-year-old Caucasian, gravida 2, para 1 pregnant woman was referred to the Obstetrics Service of the University Hospitals of Geneva (HUG) due to an abnormal fetal scan performed by her gynecologist at 26 weeks gestation (WG). The exam showed 11-mm right cerebral ventriculomegaly and multiple 4- to 5-mm echogenic images of hyperechoic lesions in the cerebral parenchyma compatible with fetal infection. Her medical history was remarkable for ankylosing spondylitis for which she was treated with adalimumab for 4 years until 5 months before conception. She was screened for TXP at 6 WG (Table 1) and had positive IgG and IgM with a high avidity index compatible with TXP infection

Received: March 30 2021.

Accepted: July 29 2021.

Correspondence

Gianmarco Taraschi, Department of Pediatrics, Gynecology, and Obstetrics, Geneva University Hospitals, 30 Bld de la Cluse, Geneva 1211, Switzerland.

Email: gianmarco.taraschi@hcuge.ch

Eloïse Krull and Gianmarco Taraschi contributed equally to this work.

TABLE 1 Toxoplasmosis serology and avidity results before, during, and after pregnancy

Antibodies (method)	Unity (reference values)	6 months before conception	6 + 1	12 + 4 WG	15 + 4 WG	20 + 0 WG	26 days after TOP	3 months after TOP	6 months after TOP
IgM (ECLIA)	<0.80–0.99		1.51	1.32	1.11	1.29	1.00	0.92	0.84
IgM (CMIA)	<0.50–0.60	1.83	1.65	1.32	1.17	1.28	1.39	1.24	1.25
IgM (ELFA)	<0.55	1.37							
IgG (ECLIA)	<1.00–3.00		3650	5080	5960	6200	24 600	28 000	22 000
IgG (CMIA)	<1.60–2.99	>200	306	329	361	390	1340	1480	1180
IgG (ELFA)	<4.0	>300							
IgG avidity ^a	60%	22	69.4	73.7	—	—	—	—	—

Note: Data are given in international units/milliliter (IU/mL) unless otherwise stated.; Abbreviations: CMIA, chemiluminescent microparticle immunoassay; ECLIA, electrochemiluminescence immunoassay; ELFA, enzyme-linked fluorescence assay; Ig, immunoglobulin; TOP, termination of pregnancy; WG, weeks of gestation. and ^a(Architect).

prior pregnancy. Her routine first-trimester and 20 weeks ultrasounds and the aneuploidy screening were normal. The fetal scan performed at HUG at 27 WG confirmed the lesions found by her gynecologists (Figure 1). An IRM showed multiple subependymal T2-weighted intense lesions in the right frontal and left temporal cerebral parenchyma as long as multiple cortical–subcortical cystic T2-weighted intense lesions in the left parieto-occipital region. We

performed then an amniocentesis searching for cytomegalovirus (CMV) and TXP infections by PCR (polymerase chain reaction) that become positive for the latter. The patient requested termination of pregnancy. The fetal autopsy showed hepatosplenomegaly, calcifications of the adrenal glands, and a T-lymphocyte infiltration in the skeletal muscles. The placenta pathology study showed irregular villous dysmaturity, stage I subchorionitis, and high stage of chronic villitis. The

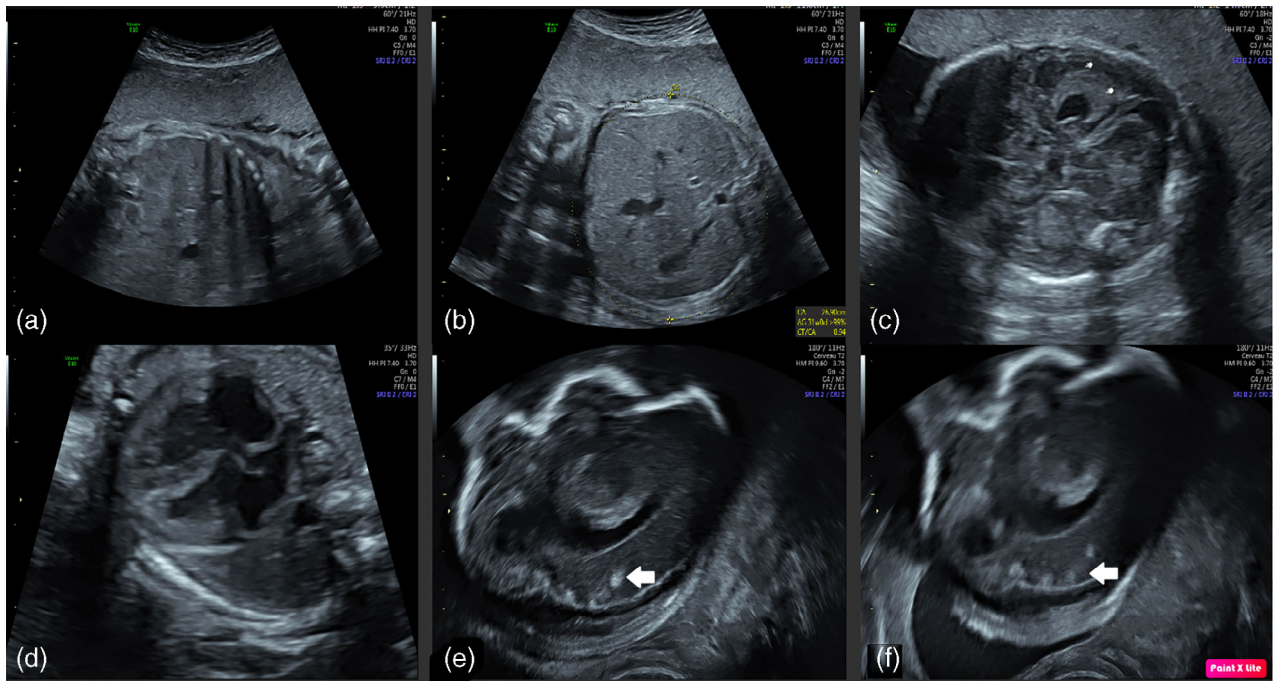


Figure 1 Transabdominal ultrasound performed at 27 GW. (a) Hepatomegaly, liver measured at 55 mm (>p95). (b) Abdominal circumference: 269 mm (>p95). (c) Periventricular hyperechogenicity (fingertip). (d) Four chambers view of the fetal heart showing slight cardiac wall hypertrophy. (e,f) Parasagittal view of fetal right lateral ventricle with multiple 4–5 mm hyperechoic lesions at the cortical–subcortical junction and in the cerebral parenchyma (arrows).

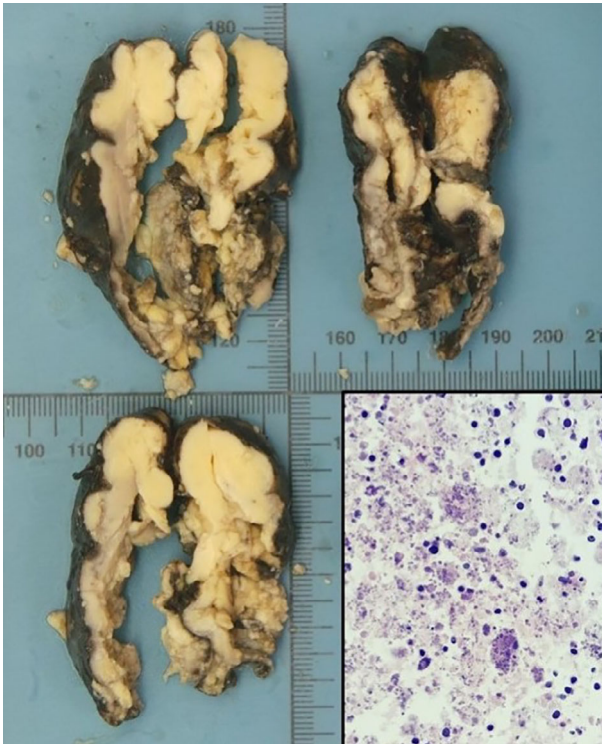


Figure 2 Pathological examination of the fetal brain. Three macroscopic coronal sections of the brain, showing extensive tissue necrosis; a histology insert (hematoxylin and eosin stain, $\times 400$ magnification), showing tissue necrosis with free forms and toxoplasmic pseudocysts

microscopy exam on brain tissue confirmed congenital TXP infection, with large necrotic and inflammatory lesions in the central nervous system (Figure 2).

Discussion with the patient revealed that she had been treated with adalimumab for ankylosing spondylitis for almost 4 years until 5 months before conception. She recalled having asthenia and myalgia 1 month before conception lasting less than a week with no fever. She did not recall any signs or symptoms compatible with toxoplasma infection at that time or before. The patient had no contact with cats and therefore the probable mode of transmission was foodborne.

We performed a retrospective TXP serology evaluation including Architect and Cobas IgM and IgG serologies and avidity tests on stored blood samples of the patient to find out the moment of the TXP primary infection (Table 1). The patient had contracted the TXP infection 6–7 months before conception when she was on adalimumab treatment. The IgG titers

continued to increase for more than a year after infection.

The patient signed an informed consent for anonymous publication of this case report. A copy is available to the corresponding author.

Discussion

TXP is a common worldwide infection caused by the parasite *Toxoplasma gondii*. It is transmitted to humans mostly by ingestion of raw or undercooked infected meat that contains tissue cysts and by contact with cat feces, contaminated soil, and litter boxes during pregnancy.¹

In Switzerland, with its 73 000 live births per year, approximately 130 women develop primary TXP during pregnancy, with 32 cases of congenital infection annually.² Congenital TXP causes brain, eye, heart, liver lesions, miscarriage, and intrauterine fetal demise. The risk of vertical transmission increases with gestational age (15% during the first trimester, 60%–90% during the third trimester), although the severity of fetal morbidity decreases with gestational age.³ The risk of vertical transmission when infection happens prior pregnancy (3 months) and in the first weeks of pregnancy is extremely low.⁴

Congenital TXP infection usually results from a primary infection that happens during pregnancy or exceptionally during the 3 months before conception in a seronegative woman, but it can also be due to secondary infection (reactivation of latent infection or reinfection) in an immunocompromised pregnant woman.⁵

Screening and diagnosis rely on serological tests. Specific IgM antibodies signal the presence of an acute infection. These antibodies have excellent sensitivity, but low specificity³ as they can last for several months⁶ after resolution of the acute infection. It is recommended to use the avidity test of TXP-specific IgG antibodies to date the timing of infection when IgM and IgG antibodies are positive during the first trimester. The presence of a high avidity indicates that the infection happened at least 3–5 months earlier.⁶ In the case of our patient, who was tested at 6 WG, the avidity was high meaning that the primary infection occurred at least 2 months prior conception and that the risk of congenital infection was supposed to be extremely low. In fact, she had got the infection more than 6 months prior conception (Table 1) when on treatment with biologics.

Human immunodeficiency viruses (HIV) infection, use of immunosuppressive drugs or even type 2 diabetes during pregnancy are well-known risk factors for vertical transmission of TXP.^{7–9} Our patient had been treated with adalimumab (Humira, AbbVie Inc., North Chicago, IL, USA) for almost 4 years and until 5 months before conception. Adalimumab is a recombinant IgG1 monoclonal antibody that is an anti-tumor necrosis factor α (TNF α) immunosuppressant commonly used for autoimmune conditions, such as rheumatoid polyarthritis, Chron's disease, psoriasis among others. It induces suppression of one of the primary mechanisms involved in the clearance of *T. gondii*—the Th1-type immune response mediated by TNF α and interleukin-12.¹⁰ Several studies have shown an increased risk of reactivation of chronic hepatitis C and opportunistic infections (i.e., tuberculosis, granulomatous fungal infection, invasive aspergillosis, CMV, Epstein–Barr virus), in patients using anti-TNF α agents, including adalimumab.¹¹ Its half-life is 14 days,¹² however, the delay for the immune system to totally recover after stopping the drug is not well known. Immunosuppressed women with HIV infection are strictly followed for risk of TXP complications when the CD4 levels are low. Unfortunately, there are no such markers for patients on anti-TNF α drugs.

Our patient acquired the infection while on adalimumab, as indicated by the low avidity result (22) at 6 months prior conception. Even though the treatment was stopped about 1 month after the infection, its on-going effect on the immune system had probably allowed for persistent parasitemia for more than 6 months which resulted in the fetal infection. The gynecologist was reassured as the IgG avidity was high at 6 weeks of gestation. On the other hand, the IgG titers were very high and this has been shown to be associated with a high risk of vertical transmission among women with primary infection¹³ Moreover, very high IgG levels could reflect the presence of severe or disseminated disease.¹³

The debate about TXP screening during pregnancy is still ongoing in Europe. Switzerland does not recommend screening since 2010 following the recommendation of the Swiss Working Group on congenital TXP and the Eurotox project.¹ A cord blood screening program from 1982 until 2015 showed a continuous decrease in seroprevalence from 53% to 20% and in the incidence of congenital TXP from 0.08% to 0.012%,² suggesting that the no-screening policy is justified. Despite the current Swiss recommendations, a recent study showed that 24.1% of private

gynecologists caring for pregnant women systematically screen for TXP and that 32.9% are willing to screen for TXP infection upon the patient's demand.¹⁴

On the other hand, the interpretation of serology tests can be challenging in the presence of immunosuppression. Increasing and very high IgG titers may represent a lack of protective immunity, which can lead to fetal infection, even in the presence of high avidity.

To the best of our knowledge, this is the first case of congenital TXP infection in a woman on adalimumab who had become infected >6 months before pregnancy. The strategies currently used to evaluate the risk of congenital infection, including high IgG avidity, might not be satisfactory in women on immunosuppressive therapy, even when the treatment had been stopped several months before conception. Also, women are recommended to wait for at least 3 months after primary TXP infection before attempting conception. In immunocompromised women or among those on immunosuppressive drugs such as adalimumab, the delay should be longer.

Education, primary prevention, and routine surveillance should be reinforced among childbearing age women treated with immunosuppressive medications. We recommend increasing the interval to attempt conception after primary infection and to cautiously interpret the results of the serology when the IgG titers are very high, even in the presence of high avidity.

Acknowledgment

Open Access Funding provided by Universite de Geneve.

Conflict of Interest

None declared.

Author Contributions

EK and GT: wrote the manuscript and made research with support of EBE JMP and BMT. **EBE:** collected the data and supervised the writing of the manuscript. **JMP:** collected the data and supervised the writing of the manuscript. **BMT:** was in charge of overall direction and planning.

Data Availability Statement

The data that support the findings of this study are available from the corresponding author upon reasonable request.

References

1. Boubaker K, Raeber PA, Vaudaux B, Bucher HC, Garweg JG, Hoesli I, et al. Toxoplasmosis during pregnancy and infancy. A new approach for Switzerland. *Swiss Med Wkly*. 2008;**138**:1–8.
2. Rudin C, Hirsch HH, Spaelti R, Schaedelin S, Klimkait T. Decline of Seroprevalence and incidence of congenital toxoplasmosis despite changing prevention policy—three decades of cord-blood screening in North-Western Switzerland. *Pediatr Infect Dis J*. 2018;**37**:1087–92.
3. group Ss, Thiebaut R, Leproust S, Chene G, Gilbert R. Effectiveness of prenatal treatment for congenital toxoplasmosis: a meta-analysis of individual patients' data. *Lancet*. 2007;**369**:115–22.
4. Chaudhry SA, Gad N, Koren G. Toxoplasmosis and pregnancy. *Can Fam Physician*. 2014;**60**:334–6.
5. Maldonado YA, Read JS, Committee On Infectious Diseases. Diagnosis, treatment, and prevention of congenital toxoplasmosis in the United States. *Pediatrics*. 2017;**139**:2.
6. Garnaud C, Fricker-Hidalgo H, Evengard B, Alvarez-Martinez MJ, Petersen E, Kortbeek LM, et al. *Toxoplasma gondii*-specific IgG avidity testing in pregnant women. *Clin Microbiol Infect*. 2020;**26**:1155–60.
7. Nourollahpour Shiadeh M, Esfandyari S, Ashrafmansouri M, Mirzapor A, Taghipour A, Spotin A, et al. The prevalence of latent and acute toxoplasmosis in HIV-infected pregnant women: a systematic review and meta-analysis. *Microb Pathog*. 2020;**149**:104549.
8. Sato S, Nishida M, Nasu K, Narahara H, Norose K, Aosai F. Congenital toxoplasmosis from a mother with type 2 diabetes mellitus: a case report. *J Obstet Gynaecol Res*. 2014;**40**:2158–61.
9. Lewis JM, Clifford S, Nsutebu E. Toxoplasmosis in immunosuppressed patients. *Rheumatology (Oxford)*. 2015;**54**:1939–40.
10. Rezende-Oliveira K, Silva NM, Mineo JR, Rodrigues JV. Cytokines and chemokines production by mononuclear cells from parturient women after stimulation with live *Toxoplasma gondii*. *Placenta*. 2012;**33**:682–7.
11. Baddley JW, Cantini F, Goletti D, Gomez-Reino JJ, Mylonakis E, San-Juan R, et al. ESCMID Study Group for Infections in Compromised Hosts (ESGICH) consensus document on the safety of targeted and biological therapies: an infectious diseases perspective (soluble immune effector molecules [I]: anti-tumor necrosis factor-alpha agents). *Clin Microbiol Infect*. 2018;**24**:S10–20.
12. T eratog enes CdRslA. *Adalimumab—allaitement et grossesse*. Paris, France: CRAT - Centre de R ef erence sur les Agents T eratog enes H opital Armand Trousseau; 2018. <https://www.lecrat.fr>.
13. Gomez-Chavez F, Canedo-Solares I, Ortiz-Alegria LB, Flores-Garcia Y, Luna-Pasten H, Figueroa-Damian R, et al. Maternal immune response during pregnancy and vertical transmission in human toxoplasmosis. *Front Immunol*. 2019;**10**:285.
14. Aebi-Popp K, Kahlert C, Rauch A, Mosimann B, Baud D, Low N, et al. Heterogeneity in testing practices for infections during pregnancy: national survey across Switzerland. *Swiss Med Wkly*. 2016;**146**:w14325.