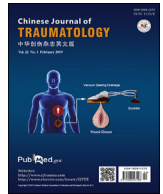




Contents lists available at ScienceDirect

Chinese Journal of Traumatology

journal homepage: <http://www.elsevier.com/locate/CJTEE>

Review Article

Chinese Trauma Surgeon Association for management guidelines of vacuum sealing drainage application in abdominal surgeries—Update and systematic review

Yang Li ^a, Pei-Yuan Li ^a, Shi-Jing Sun ^a, Yuan-Zhang Yao ^a, Zhan-Fei Li ^b, Tao Liu ^b, Fan Yang ^b, Lian-Yang Zhang ^{a,*}, Xiang-Jun Bai ^{b,**}, Jing-Shan Huo ^c, Wu-Bing He ^d, Jun Ouyang ^e, Lei Peng ^f, Ping Hu ^g, Yan-An Zhu ^h, Ping Jin ⁱ, Qi-Feng Shao ^j, Yan-Feng Wang ^k, Rui-Wu Dai ^l, Pei-Yang Hu ^m, Hai-Ming Chen ⁿ, Ge-Fei Wang ^o, Yong-Gao Wang ^p, Hong-Xu Jin ^q, Chang-Ju Zhu ^r, Qi-Yong Zhang ^s, Biao Shao ^t, Xi-Guang Sang ^u, Chang-Lin Yin ^v

^a Trauma Center of PLA, State Key Laboratory of Trauma, Burns and Combined Injury, Institute of Surgery Research, Daping Hospital, Third Military Medical University, Chongqing, China

^b Trauma Center/Department of Emergency and Trauma Surgery, Tongji Hospital of Tongji Medical College, Huazhong University of Science & Technology, Wuhan, China

^c Foshan Hospital of Traditional Chinese Medicine, Foshan, Guangzhou Province, China

^d Fujian Provincial Hospital, Fuzhou, China

^e Emergency Surgery of the First Affiliated Hospital, Shihezi University School of Medicine, Shihezi, Xinjiang Autonomous Region, China

^f The First Affiliated Hospital of Hainan Medical University, Haikou, China

^g Chongqing Emergency Medical Center, Chongqing, China

^h Taizhou Hospital of Zhejiang Province, Taizhou, Zhejiang Province, China

ⁱ Yuyao People's Hospital of Zhejiang Province, Yuyao, Zhejiang Province, China

^j Ninth People's Hospital of Zhengzhou, Zhengzhou, China

^k Zhongnan Hospital of Wuhan University, Wuhan, China

^l Chengdu Military General Hospital, Chengdu, China

^m Tiantai County People's Hospital, Tiantai, Zhejiang, China

ⁿ The First Affiliated Hospital of Nanchang University, Nanchang, China

^o Department of Surgery, Jinling Hospital, Medical School of Nanjing University, Nanjing, China

^p Department of Surgery, The First Affiliated Hospital of Zhejiang Chinese Medical University, Hangzhou, China

^q Shenyang Military General Hospital, Shenyang, China

^r The First Affiliated Hospital of Zhengzhou University, Zhengzhou, China

^s The Affiliated Hospital of Guizhou Medical University, Guiyang, China

^t The First People's Hospital of Kunming, Kunming, China

^u Qilu Hospital of Shandong University, Jinan, China

^v The First Affiliated Hospital of Third Military Medical University, Chongqing, China

ARTICLE INFO

Article history:

Received 17 October 2018

Received in revised form

12 December 2018

Accepted 12 January 2019

Available online 14 February 2019

Keywords:

Guideline

Vacuum sealing drainage

Abdominal surgery

ABSTRACT

Vacuum sealing drainage (VSD) is frequently used in abdominal surgeries. However, relevant guidelines are rare. Chinese Trauma Surgeon Association organized a committee composed of 28 experts across China in July 2017, aiming to provide an evidence-based recommendation for the application of VSD in abdominal surgeries.

Eleven questions regarding the use of VSD in abdominal surgeries were addressed: (1) which type of materials should be respectively chosen for the intraperitoneal cavity, retroperitoneal cavity and superficial incisions? (2) Can VSD be preventively used for a high-risk abdominal incision with primary suture? (3) Can VSD be used in severely contaminated/infected abdominal surgical sites? (4) Can VSD be used for temporary abdominal cavity closure under some special conditions such as severe abdominal trauma, infection, liver transplantation and intra-abdominal volume increment in abdominal

* Corresponding author.

** Corresponding author.

E-mail addresses: dpzhangly@163.com (L.-Y. Zhang), baixiangjun@hotmail.com (X.-J. Bai).

Peer review under responsibility of Chinese Medical Association.

compartment syndrome? (5) Can VSD be used in abdominal organ inflammation, injury, or postoperative drainage? (6) Can VSD be used in the treatment of intestinal fistula and pancreatic fistula? (7) Can VSD be used in the treatment of intra-abdominal and extra-peritoneal abscess? (8) Can VSD be used in the treatment of abdominal wall wounds, wound cavity, and defects? (9) Does VSD increase the risk of bleeding? (10) Does VSD increase the risk of intestinal wall injury? (11) Does VSD increase the risk of peritoneal adhesion?

Focusing on these questions, evidence-based recommendations were given accordingly. VSD was strongly recommended regarding the questions 2–4. Weak recommendations were made regarding questions 1 and 5–11. Proper use of VSD in abdominal surgeries can lower the risk of infection in abdominal incisions with primary suture, treat severely contaminated/infected surgical sites and facilitate temporary abdominal cavity closure.

© 2019 Chinese Medical Association. Production and hosting by Elsevier B.V. This is an open access article under the CC BY-NC-ND license (<http://creativecommons.org/licenses/by-nc-nd/4.0/>).

Introduction

Drainage is a basic surgical technique, and the methods and materials are constantly improving. In 1954, Redon¹ first proposed the concept of vacuum negative pressure wound drainage and then applied a device named “Sterimed” in clinical practice in 1959 which achieved the effect of enhanced drainage, reduced infection, and promoted wound healing. In 1964, Mclean² described the role of wound sealing and vacuum suction in a head and neck surgery. In 1977, Fox et al.³ first proposed the idea that continuous vacuum suction could accelerate wound healing. In 1992, Fleischmann et al.^{4,5} from Trauma Surgery Hospital of Ulm University in Germany introduced vacuum sealing drainage (VSD), which combined traditional negative pressure drainage with modern sealing dressings for the treatment of infected wound surfaces of limbs, and achieved remarkable results. In 1995, Professor Qiu Hua-de and colleagues from Zhongnan Hospital of Wuhan University in China applied VSD to the abdomen for the first time.⁶ In 1997, Argenta and Morykwas et al.^{7,8} used porous polyurethane sponge materials to improve the drainage on chronic refractory wounds and proposed the concepts of vacuum-assisted closure (VAC) and negative pressure wound therapy (NPWT). In 2008, VSD was incorporated into the “Ten Years of 100 Projects” promotion plan of the Chinese Ministry of Health. VSD covers the surgical concepts of “negative pressure, sealing, and drainage”, including NPWT and VAC. In this article, VSD is used as the collective name for the three technologies.

In July 2017, Chinese Trauma Surgeon Association organized a committee composed of 28 experts across China to discuss the indications and contraindications of VSD application, aiming to provide an evidence-based recommendation for the application of VSD in abdominal surgeries. Eleven questions regarding the use of VSD in abdominal surgeries were addressed, and an evidence-based medicine method was used to propose the recommendations for those questions.

Statement of the problems

- (1) Which type of materials should be chosen for the intraperitoneal cavity, retroperitoneal cavity, and superficial incisions separately?
- (2) Can VSD be preventively used for a high-risk abdominal incision with primary suture?
- (3) Can VSD be used in severely contaminated/infected abdominal surgical sites?
- (4) Can VSD be used for temporary abdominal cavity closure due to conditions such as severe abdominal trauma, infection, liver transplantation and intra-abdominal volume increment in abdominal compartment syndrome (ACS)?

- (5) Can VSD be used in abdominal organ inflammation, injury, or postoperative drainage?
- (6) Can VSD be used in the treatment of intestinal fistula and pancreatic fistula?
- (7) Can VSD be used in the treatment of intra-abdominal and extra-peritoneal abscess?
- (8) Can VSD be used in the treatment of abdominal wall wounds, wound cavity, and defects?
- (9) Does VSD increase the risk of bleeding?
- (10) Does VSD increase the risk of intestinal wall injury?
- (11) Does VSD increase the risk of peritoneal adhesion?

Literature searches and appraisal

The keywords “VSD or vacuum sealing drainage”, “NPWT or negative pressure wound therapy”, “vacuum-assisted closure”, “topical negative pressure”, Chinese character keywords “负压封闭引流” namely vacuum sealing drainage” and “负压辅助封闭” namely vacuum-assisted closure” were used to search the well-known databases of PubMed, MEDLINE, Cochrane Library, OVID, Elsevier, China Biomedical Literature Database (CBM), China Knowledge Network, VIP Net, and Wanfang Data. The time-frame of the inquiries was from the establishment of the databases to September 2017. A manual search of related magazines, conference papers, and unpublished literature was also conducted.

Oxford Center for Evidence-based Medicine Levels of Evidence (March 2009)⁹ was used to evaluate the quality of the evidence and grade the level of recommendation (Table 1).

Recommendations

General remarks

Generally, VSD is regarded as a safe and reliable method. Reports of related complications have increased with the expanded application and an increased number of clinical cases.

Which type of material should be chosen for intraperitoneal cavity, retroperitoneal cavity, and superficial incisions separately?

Recommendation 1: Polyvinyl alcohol foam is recommended to be used in intraperitoneal and retroperitoneal cavities, while polyurethane or polyvinyl alcohol foam is recommended for superficial incisions and external areas of sutured incisions.¹⁰ (Grade C).

The materials and equipment required for VSD include foam, drainage tubes, transparent adhesive films, and negative pressure

Table 1
Oxford Centre for Evidence-based Medicine Levels of Evidence (March 2009)⁹.

Levels of evidence and grades of recommendation	
Level of evidence	Therapy/Prevention, Aetiology/Harm
1a	SR (with homogeneity ^a) of RCTs
1b	Individual RCT (with narrow confidence interval)
1c	All or none ^b
2a	SR (with homogeneity ^a) of cohort studies
2b	Individual cohort study (including low quality RCT; e.g., <80% follow up)
2c	"Outcomes" research; Ecological studies
3a	SR (with homogeneity ^a) of case-control studies
3b	Individual case-control study
4	Case-series (and poor quality cohort and case control studies)
5	Expert opinion without explicit critical appraisal, or based on physiology, bench research or "first principles"
Grades of recommendation	
A	Consistent level 1 studies
B	Consistent level 2 or 3 studies or extrapolations from level 1 studies
C	Level 4 studies or extrapolations from level 2 or 3 studies
D	Level 5 evidence or troublingly inconsistent or inconclusive studies of any level

Note: The table was produced by Bob Phillips, Chris Ball, Dave Sackett, et al since November 1998 and updated by Jeremy Howick March 2009. <http://www2.cch.org.tw/ebm/file/CEBM-Levels-of-Evidence.pdf?crazycache=1>.

^a Homogeneity here means the systematic review is free of worrisome variations (heterogeneity) in the directions and degrees of results between individual studies. Not all systematic reviews with statistically significant heterogeneity need be worrisome, and not all worrisome heterogeneity need be statistically significant. As noted above, studies displaying worrisome heterogeneity should be tagged with a "-" at the end of their designated level.

^b Met when all patients died before the Rx became available, but some now survive on it; or when some patients died before the Rx became available, but none now die on it.

sources. Among them, the porous sponge-like foam materials are in contact with tissues, such as the wound surface, and the pores are connected to each other. There are two types of materials (1) polyvinyl alcohol (PVA), which has a small pore size of 0.06–0.27 mm in diameter and a high tensile strength (522.4 kPa) and is tough, and (2) polyurethane (PU), which has larger pores with a diameter of 0.4–0.6 mm that allows easy penetration for granulation, has low tensile strength (111.1 kPa) and is fragile.^{11–15} Retention of PU foam debris in the wound has been observed to affect healing.¹⁶

In actual application, the surface of the foam material must be covered with a semipermeable membrane. After the generation of negative pressure, the foam is fixed with surrounding tissues to form a complete seal.^{17,18} Considering the effect of negative pressure on the intestinal blood supply, typically the negative pressure intensity applied on the abdomen is lower than that on the extremities when using VSD technique.¹⁹ The value can be set at –125 mmHg to –300 mmHg (–17 kPa to –40 kPa) for skin outside the incision, extraperitoneal wounds, or within body cavity; while for temporary peritoneal closure and intra-abdominal application, the pressure should be adjusted to –50 mmHg to –175 mmHg (–6.7 to –23.3 kPa).^{20–31} Although there is no high-level evidence in evidence-based medicine, a lower negative pressure value, such as –50 mmHg to –80 mmHg, is recommended for patients with intestinal repair or anastomosis.²³

Can VSD be preventively used for a high-risk abdominal incision with primary suture?

Recommendation 2: For abdominal incisions with a primary suture which have a high risk of infection, prophylactic use of VSD is recommended to help reduce the onset of incision infection (Grade B).

A total of 35 articles discussed prophylactic VSD (pVSD) for abdominal incisions with primary suture, of which 6 were RCTs^{32–37} and 29 were observational studies.^{38–66}

In 2016, the WHO issued a procedure based on evidence-based evidence for the prevention of intraoperative and postoperative surgical site infections (SSIs) in *Lancet Infectious Diseases* and

proposed the application of prophylactic NPWT for stage I sutured incisions with a high risk of infection (conditional recommendation, low quality).⁶⁷ A total of 20 articles were reviewed, including 6 RCTs and 14 observational studies. Compared with traditional wound dressings, prophylactic NPWT (pNPWT) reduces the risk of SSIs in closed wounds. Subgroup analysis of different surgical procedures revealed that use of pVSD reduced the risk of SSIs in abdominal and cardiac surgeries but had no effect in orthopedic or traumatic surgeries. In subgroups with different incision categories (clean-contaminated incisions and clean incisions), pVSD showed significant differences in reducing the incidence of SSIs. By using a cost-effectiveness analysis, Chopra et al.⁶⁸ compared closed-incision VSD therapy with standard dressings after abdominal incision closure in high-risk patients: 829 abdominal wall surgeries (260 closed-incision VSDs and 569 standard dressings) were included, and the results showed that closed-incision VSD saved 1546.52 US dollars compared with standard dressing, suggesting that closed-incision VSD was a cost-effective method when the SSI rate was greater than 16.39%. An international multidisciplinary consensus recommendation published in 2017 reviewed 100 articles published from 2000 to 2015 that compared traditional wound dressings with closed-incision negative pressure therapy. The results supported the use of VSD for sutured incisions in patients with a high risk of SSI and can reduce the incidence of SSI.⁶⁹

In subgroup analyses of different surgical types, four observational studies of abdominal wall reconstructive surgery showed that pVSD reduced the incidence of SSIs,^{62–64,66} whereas one observational study showed that pVSD had no apparent advantages in reducing the incidence of SSIs.⁶⁰ Additionally, six observational studies of colorectal surgery showed that pVSD reduced the incidence of SSIs,^{38–43} one observational study of pancreatoduodenectomy showed that pVSD reduced the incidence of SSIs,⁶⁰ and one RCT of ulcerative colitis ileostomy reversal showed that pVSD did not reduce the incidence of SSIs.³² A total of six RCTs investigated multiple abdominal surgeries, among which three showed that pVSD reduced the incidence of SSIs,^{32,35,36} two showed that pVSD did not reduce the incidence of SSIs,^{33, 37} and one showed that VSD reduced the incidence of SSIs, but the differences were not significant.³⁴ Eleven observational studies of

abdominal surgeries, including pediatric contaminated surgery, gynecological malignancy surgery, cesarean section surgery, and liver transplantation surgery, also showed that pVSD reduced the incidence of incision infections.^{44,45,49,50,52,57,59,65} One RCT showed that pVSD reduced postoperative pain and the need for anesthetics³⁴; however, although the incidence of SSIs decreased, the difference was not significant.

Regarding the level of contamination in subgroups with different incision categories, one observational study showed that pVSD reduced the incidence of SSIs in contaminated incisions,⁶⁵ whereas another observational study showed that pVSD did not reduce the incidence of SSIs in contaminated incisions.⁶¹ A total of twenty studies were included in the clean-contaminated surgery group, of which 13 observational studies showed that pVSD reduced the incidence of SSIs for clean-contaminated incisions,^{38–41,43–45,60,62–64,66,70} three RCTs showed that pVSD reduced the incidence SSIs,^{34–36} and another three RCTs showed that pVSD did not have apparent advantages in reducing infection incidences.^{32,33,37}

The high-risk factors for the onset of SSIs include vascular disorders due to peripheral soft tissue injuries, hemorrhage or hematoma, necrotic tissue, intraoperative contamination, a long surgical time, and obesity, diabetes as well as smoking.^{67,69}

Can VSD be used in severely contaminated/infected abdominal surgical sites?

Recommendation 3: The use of VSD in severely contaminated/infected abdominal surgical sites is recommended, which can prevent/treat infections, quicken stage II closure of the incision, and shorten hospital stay (Grade B).

A total of 26 articles were included, of which 3 were RCTs^{20,71,72} and 23 were observational studies and case series.^{26,50,64,71–90}

One RCT consisting of 81 cases of severely contaminated incisions showed that 27 cases were closed in stage I, 29 cases had delayed closure, and 25 cases were applied VSD. The incision infection rates were 37%, 17%, and 0.2%, respectively.²⁰ In two observational studies, VSD was used for an early deep incision infection after abdominal wall hernia tension-free repair. Among the 33 cases treated with suture removal and VSD, 9 had mesh removal and the other 24 did not; all wounds healed within 4 weeks.^{26,64}

In the analysis of the effects and feasibility of VSD in severely contaminated/infected abdominal surgical sites, one RCT showed that VSD was safe in an open abdomen (OA) after severe intra-abdominal infection and improved the quality of life of patients,²⁰ whereas the RCT by Roberts et al.⁷² on secondary abdominal cavity abscess following damage control surgery suggested that VSD reduced systemic inflammatory responses. Another RCT by Kirkpatrick et al.⁷¹ showed that VSD did not accelerate pus drainage or reduce systemic inflammatory markers.

Multiple observational studies on the use of VSD for retroperitoneal space infections with different causes have shown that VSD can control early local infection, keep the abscess clean, promote collapse of the abscess, shorten healing time, reduce local complications, and reduce VSD-related complications.^{73–75} Tao et al.⁷⁶ confirmed that VSD prevented subgingival infection after hepatectomy. In the study of 39 patients with severe intra-abdominal infection conducted by Pliakos et al.,⁷⁷ VSD effectively reduced mortality but could not reduce the systemic bacterial burden or prevent the incidence of hospital-acquired infections. Another two observational studies showed that application of VSD during severe abdominal infection drained the pus and promoted the reduction of the abscess cavity; thus, granulation of the wound was fresh, and formation of a residual abscess was avoided.^{78,79}

Regarding the mechanism of action of indwelling VSD at the site of abdominal surgery, it is suggested that VSD could actively induce complete drainage, enlarge the drainage area and drainage range, prevent clogging, accelerate tissue swelling subsidence, and eliminate dead space effectively.^{50,80,81} In addition, VSD promoted blood circulation, reduced tissue edema, inhibited bacterial growth, and applied a local mechanical pull to promote shrinkage of the wound surface or wound cavity.^{82–84} Takei et al.⁹¹ suggested that the mechanism of action might be that the continuous vacuum negative pressure actively removed water, exudate, and residual pus from the edema tissue, induced cell proliferation & matrix synthesis, and accelerated healing. Additional observational and experimental studies suggested that the mechanism was the acceleration of blood perfusion, promotion of vascularization, and improvement of local circulation and that negative pressure indirectly decreased the hydrostatic pressure of local tissue edema, reduced leakage, and accelerated regression of the edema.^{85–88} The hypoxic state caused by continuous negative pressure due to VSD also inhibited bacterial proliferation and eliminated bacterial colonization and the bacterial growth medium.^{89,90}

When VSD is used for the prevention and treatment of infections associated with abdominal surgical sites, the foam material should be in the lower or central part of the abscess; thus, the abdominal wall incision should be made in the nearest area to drain the foaming, and local bleeding and excessive growth of granulation tissue into the foam should be prevented. The foam materials and the drainage tube are firmly fixed by the suture to prevent exposure of the side hole of the drainage tube outside of the sponge, which can cause focal necrosis of the intestinal wall. In general, the foam materials should be removed or replaced every 5–7 days; after more than 9 days, granulation tissue may grow into the foam, resulting in bleeding and difficulty in removing the foam.⁹²

Can VSD be used for temporary abdominal cavity closure under the conditions such as severe abdominal trauma, infection, and liver transplantation and intra-abdominal volume increment in ACS?

Recommendation 4: VSD is recommended as the preferred method for temporary abdominal closure (TAC) and intra-abdominal volume increment under the conditions such as severe abdominal trauma, infection, and liver transplantation (Grade B).

This topic included 20 related articles: one RCT,⁹³ and 19 were retrospective studies.^{33,49,53,55,56,65,68,94–105}

For patients with severe abdominal trauma or severe intra-abdominal infection received intraperitoneal procedures, such as hemorrhage and contamination control, primary suture of the abdominal wall may result in serious consequences, such as unplanned secondary surgery, ACS, severe intra-abdominal infection, and multiple organ failure, and thus has a high failure rate. TAC technology is needed for these patients. TAC can significantly increase the abdominal cavity volume and reduce abdominal pressure, avoid extravasation of intraperitoneal fluid, reconstruct abdominal wall barriers, protect intra-abdominal organs, prevent infection, and reduce the incidence of gastrointestinal fistulae.

TAC can be used in the following situations: (1) peritonitis, necrotizing fasciitis, and purulent abdominal infection; (2) abdominal trauma, damage control laparotomy, and abdominal wall damage; (3) mesenteric ischemia and situations when bowel circulation is difficult to determine due to various causes; (4) primary or secondary abdominal hypertension or ACS; and (5) liver transplantation.

Ideally, TAC should be able to keep the abdominal cavity in a closed state, protect the internal organs of the abdominal cavity, avoid exogenous contamination or mechanical injury, drain the

exudate from the abdominal cavity, expand the volume of the abdominal cavity to reduce the intra-abdominal pressure and prevent or treat ACS, and protect the integrity of the fascia to facilitate definitive abdominal closure in the future. Various TAC methods are available, including simple skin closure (jacket clamp or suture), suturing plastic and other materials to the skin, suture of artificial mesh to the fascia, and VSD-assisted closure.

The application of VSD-assisted TAC has become the mainstream method. The VSD system (ABC Ira set, KCI, USA) meets most of the requirements of an ideal TAC. The surgical method is as follows: after completion of the intraperitoneal surgical operation, the greater omentum is placed under the incision to cover the intestine, lined with a thin film to help prevent adhesion between the intestinal tract and the abdominal wall, and then VSD foam is sutured to the abdominal fascia or skin to seal the abdomen incision. The film covers the entire wound and maintains a sealed environment. The drainage tube is connected to a vacuum suction device, and the pressure is adjusted to -60 kPa to -80 kPa. Generally, drainage can be continued for 5–7 days.⁹⁸

Negative pressure drainage prevents the accumulation of exudates and inflammatory mediators in the abdominal cavity. Continuous negative pressure drainage ensures timely transfer of intra-abdominal fluids that are rich in digestive fluids to outside of the body, thereby reducing systemic toxin reactions and creating a good local environment for recovery of the damaged pancreas. This approach minimizes the corrosive effects of harmful liquids on intestinal and abdominal wall tissues, facilitates debridement of necrotic tissue in pancreatitis, prevents or reduces opening of the abdominal fascia tissue by acting alone or in combination with sustained traction of the fascia to significantly increase the rate of delayed closure of the fascia and reduce the occurrence of abdominal wall hernias, reduces hospital-acquired wound infections, and facilitates post-operative care.^{33,53,99}

In one retrospective study of TAC with 58 patients, VSD was applied in 27 patients, other treatments were applied in the rest 31 patients. The results showed that VSD was superior to other methods regarding the length of the abdominal opening, the frequency of dressing changes, re-exploration rate, the success rate of abdominal incision closure, and enteroatmospheric fistula.⁶⁸ A prospective study conducted by Perez et al.¹⁰⁰ showed that VSD after abdominal infection and intra-abdominal hypertension shortened the recovery time and increased the success rate of abdominal closure.

A study of VSD in 24 patients after liver transplantation showed that early fascial closure time can be shortened to a median of 5.5 days (1–12 days).⁵⁶ The use of VSD can reduce the incidence of complications and mortality in liver transplantation patients undergoing TAC.^{49,56,101} One observational study by Plaudis et al.⁵⁵ showed that the intra-abdominal pressure was effectively reduced with the use of VSD in patients with ACS caused by pancreatitis or multiple injuries. A case report of an open abdomen due to acute pancreatitis showed that VSD (ABThera kit, KCI, USA) helped aspirate large amounts of exudate in the abdominal cavity and facilitated infection management.⁶⁵

After TAC, the abdomen should be directly closed when patient's general condition improves, intra-abdominal inflammatory edema subsides, intra-abdominal infection is controlled within 1–2 weeks, intestinal edema is absorbed, and intra-abdominal pressure is < 12 mmHg; if the intra-abdominal pressure remains > 12 mmHg after 1–2 weeks or abdominal wall defects are evident, the abdomen closure should be performed by skin grafting after formation of granulation tissue under the foam material and generate planned abdominal hernia, followed by definitive abdominal wall reconstruction in 6–12 months.^{102,103} VSD can increase the closure rate of the fascia layer to 70%–90% at the first stage.⁹⁴ A systematic

review of OAs which included 112 articles found that the rates of early fascial layer closure were in a descending order of 74.6%, 48%, 35%, and 27% with the use of VSD plus active abdominal wall closure, VSD alone, negative pressure pack, and Bogota bag respectively.²¹ A retrospective study by Sibaja et al.¹⁰⁴ on 48 patients with severe intra-abdominal infections using VSD-assisted OA revealed a higher rate of early fascial closure, shortened ICU length of stay, decreased mortality, and reduced rates of associated complications. If the abdomen cannot be closed early, a series of complications may occur, including enteroatmospheric fistula, abdominal cavity infection, abdominal bleeding, and abdominal wall hernia. The most complicated complication is an enteroatmospheric fistula, which has an incidence of 5%–75%.¹⁰⁵ Different TAC techniques have different rates of postoperative complications. One RCT showed that VSD-assisted TAC did not cause intestinal fistulas,⁹³ and a review suggested that VSD was better than the Bogota bag and Barker techniques in reducing complications and infection rates.¹⁰⁶

Can VSD be used in abdominal organ inflammation, injury, or postoperative drainage?

Recommendation 5: Application of VSD after inflammation, injury or surgery in the intraabdominal organs, such as the liver, biliary tract, pancreas, and duodenum, can facilitate adequate drainage, prevent and control infections, and promote wound healing (Grade C).

Eleven studies on VSD application in intraperitoneal organ inflammation, injury and surgical treatment were included, one RCT¹⁰⁷ and 10 observational studies.^{46,47,49,53,71,76,81,92,108,109}

One RCT showed an increase in granulocyte membrane fluidity and an increased survival rate in patients with severe pancreatitis undergoing necrotizing tissue debridement and VSD ($p < 0.041$).¹⁰⁷ One observational study reported the effects of laparoscopic VSD on the treatment of 8 patients with severe pancreatitis for which the gastocolic ligament was cut and 4 cm \times 15 cm foam was placed in the lesser sac on the pancreatic surface. The foam was replaced 4–7 times after surgery; the average drainage within 48 h was 600 mL/d and decreased gradually every day, and the cure rate was significantly improved.⁷⁶

A case study showed that compared with conventional staged hepatectomy, foam materials placed between open liver lobes and application of VSD technique in gallbladder cancer patients with liver metastases who underwent liver segmentation and portal vein ligation in staged hepatectomy increased the volume of the remaining liver to 117% of the original (increased significantly on the left lateral side) and facilitated wound healing.⁴⁷ An observational study of liver transplantation combined with VSD showed that VSD application reduced the incidence of wound infection.⁴⁹

The studied of VSD application in pancreatic duodenal injury by Huo et al.^{46,53,81} showed that VSD had good treatment effects on severe injuries of the common bile duct, duodenum, and pancreas and reduced complications and the infection rate. Moreover, VSD drainage could be safely and effectively passed through the jejunostomy fistula back to the gastrointestinal tract.⁴⁹

For patients with severe pancreatitis or pancreatic injury, VSD can improve the drainage efficiency and has good treatment effects in early pancreas damage without self-digestion; however, pancreatitis patients with self-digestion can have floccular necrotic tissue clogging the foam, and thus, the foam needs to be repeatedly changed. In addition, the colon often has clogged foam due to mucus or feces, and thus, VSD is not suitable for colonic injury.¹⁰⁹ Intraperitoneal placement should follow the principle of taking the shortest route out of the body; the appropriate length and width should be trimmed according to the need, and at least 1 cm

of material should be retained outside the body to facilitate observation of the negative pressure effect.⁷¹ To avoid damage to the intestine, contact between the foam material and the intestinal suture should be avoided or minimized. A reliable method is to shorten the foam material so that approximately 1 cm is present between the foam material and the anastomosis, or the greater omentum should be placed between the foam and the intestine. Negative pressure and drainage effects, such as elasticity and collapse of the foam material exposed on the body surface, should be closely monitored. The effective drainage time of the foam material is 4–7 days; this timeframe can be shortened or extended depending on the properties of the drainage materials.¹⁰⁸ If blockage occurs, the foam material should be replaced, especially in patients with severe pancreatitis. Intra-abdominal irrigation is not recommended because irrigation is not synchronized with drainage and thus immediate detection of drainage defects due to foam or catheter blockage is almost impossible; moreover, the flushing fluid may enter the large abdominal cavity after the blockage, resulting in contamination or spread infection. In therapeutic applications, irrigation can be considered with drainage area limitations.¹⁰⁷ After drainage for 48–72 h, the drainage tube patency and drainage of the irrigation fluid should be ensured; normal saline is recommended for irrigation.⁹²

Can VSD be used in intestinal fistula and pancreatic fistula treatment?

Recommendation 6: VSD facilitates adequate drainage, controls infections, and promotes wound healing in the treatment of enterocutaneous, enteroatmospheric, and pancreatic fistulas (Grade B).

A total of 22 studies were included, one RCT,¹¹⁰ one systematic review,¹¹¹ and 20 observational studies.^{80,93,110–127}

Intestinal fistulas include enterocutaneous fistulas (ECFs) and enteroatmospheric fistulas (EAFs). In intestinal fistulas, VSD can be used as the fistula mouth or surrounding wound drainage to reduce fistula exudates, control secondary infection, and improve healing. In the subgroup study of therapeutic VSD and pVSD, two observational studies showed that therapeutic VSD minimized erosion of the surrounding tissue by the digestive juice, avoided secondary infection, and promoted intestinal fistula closure. Polyvinyl alcohol white foam and the intubation vacuum suction method are recommended.^{79,99} There have been reports on the use of polyurethane black foam for the treatment of acute intestinal fistulas, with direct sealing, full coverage, and continuous drainage of the suction cups. Five observational studies showed that the application of polyurethane black foam reduced fistula exudate, improved wound healing, and facilitated intestinal fistula closure.^{112,119–121,128} VSD can be used as a temporary preoperative measure in chronic intestinal fistulas to isolate wounds and bowel fistulas with polyurethane foam dressings. One RCT showed that VSD increased the natural closure rate of fistulas.¹¹⁰ A case-controlled study applied VSD in 16 cases of intestinal fistula and found that VSD accelerated the healing of intestinal fistulas compared with traditional methods (8 cases).¹²⁶ Eight observational studies have shown that VSD can control fistula exudates, improve wound healing, and increase the success rate of intestinal fistula repair.^{111–118}

In one observational study, 12 cases of high intestinal fistula were treated with VSD. In the end, all patients had spontaneous healing, with an average healing time of 45.3 days.¹¹⁹ Magalini et al.¹²⁰ reported that the use of negative pressure closure and drainage successfully promoted self-healing for three cases of duodenal fistula and avoided reoperation. Pepe et al.¹²² reported the successful cure of four cases of intestinal fistula using negative pressure closure. Boulanger et al.¹²¹ reported that a case of small

intestinal fistula successfully healed following negative pressure closure. Another case report showed that the use of negative pressure closure and drainage in the incision wounds of three cases of multiple intestinal fistulas facilitated control of the intestinal fistulas and promoted proliferation of granulation tissue on the wound surface, thereby creating conditions for the definitive digestive tract and abdominal wall reconstruction. One observational study suggested that additional studies were needed to assess the role of VSD.¹¹⁸

One systematic review of the literature retrospectively included 10 articles with a total of 151 ECF patients and showed that over 58 (12–90) days, the average healing rate of VSD was 64.6% (7.7%–100%).¹¹¹ In Bobkiewicz et al.'s¹¹⁰ observational study, 16 ECF patients undergoing VSD therapy and another 8 undergoing routine treatment were compared. The results showed that the frequency of dressing changes, healing times, treatment costs, and times required for the body temperature to return to normal, onset times of enteral nutrition, and incidences of secondary related complications were significantly lower in the VSD group than in the control group. A controlled study by Boulanger et al.¹²¹ investigated 18 cases of enteroatmospheric fistula undergoing continuous irrigation and negative pressure drainage using a self-made double-lumen drainage tube and 20 cases of ECF undergoing wound filling using a self-made drainage dressing or VSD at the fistula opening. The results showed that wound filling using the self-made drainage dressings or VSD at the fistula opening shortened the time for ECF wound healing, reduced the frequency of dressing changes, and shortened the hospitalization period.

Treatment of an open abdomen with an enteroatmospheric fistula is very tricky. VSD has been reported to have many advantages for the treatment of enteroatmospheric fistulas.^{93,127} Regarding the study of isolation techniques for enteroatmospheric fistulas, four observational studies showed that VAC could be combined with a “ring”/“silo”, tire ring, or pacifier method to isolate wounds and intestinal fistulas.^{80,123–125}

VSD is not recommended for the prevention and treatment of colonic fistulas because the colon secretes mucus, which can block the foam material and result in ineffective drainage.⁹²

Can VSD be used in the treatment of intra-abdominal and extraperitoneal abscess?

Recommendation 7: Use of VSD technique for the treatment of intra-abdominal and extraperitoneal abscesses facilitates adequate drainage, controls infection, and promotes wound healing (Grade C).

A total of 6 observational studies were included.^{20,48,52,71,121,129}

The effects and feasibility of VSD for severe intra-abdominal infections and abdominal abscesses caused by severe pancreatitis or perforation of the gastrointestinal tract were analyzed. Wondberg et al.²⁰ suggested that VSD was safe for an OA in cases of severe intra-abdominal infection and improved patient quality of life. Ruiz-Lopez et al.⁵² found that VSD after abdominal infection and/or abdominal hypertension shortened the recovery time and increased the success rate of abdominal closure. Additionally, Kirkpatrick et al.⁷¹ showed that VSD did not accelerate pus drainage nor reduce systemic inflammatory markers.

Regarding the effect of VSD in complex conditions with different pathogenic factors, an observational study of VSD for post-perforation abscesses in diverticulitis proved that VSD reduced the mortality and permanent rate of intestinal ostomy.¹²¹ Another observational study of pancreatic abscesses by Olejnik et al.⁴⁸ showed that VSD reduced mortality and other complications. A retrospective study of VSD in intraperitoneal abscesses with multiple causes showed that the incidence of VSD-related

complications and the rate of abdominal closure in stage I were increased. However, the benefits for other subgroups need to be further investigated.¹²⁹

Can VSD be used in the treatment of abdominal wall wounds, wound cavity and defects?

Recommendation 8: VSD can be used for the treatment of abdominal wounds, wound cavities, and defects with various causes and can facilitate adequate drainage, control infections, promote granulation tissue hyperplasia and wound healing, and shorten the repair time (Grade C).

A total of 14 articles were included, of which 12 were observational studies^{48,61–63,66,112,129–133} and 2 were animal experimental studies.^{87,88}

VSD can be used for the treatment of abdominal wall defects with different causes. Infection-induced abdominal wall defects can be treated with negative pressure drainage; one observational study of abdominal wall infections, necrotizing fasciitis, and abdominal wall defects caused by abdominal wall liposuction showed that the use of VSD promoted necrotic tissue drainage, controlled infection, promoted granulation, and facilitated early reconstruction of the impaired abdominal wall.¹³⁴ Traumatic abdominal wall defects can be treated with negative pressure drainage; two animal experiments investigated abdominal wall defects caused by explosion and showed that application of VSD in early TAC effectively protected the exposed organs, prevented the need for an intestinal fistula, reduced the incidence of wound and abdominal infection, shortened the preoperative preparation time, reduced the number of dressing changes, and facilitated early closure of the abdominal cavity.^{87,88}

Several key technical points should be considered for the use of VSD for abdominal wall defects. Chen et al.¹³³ suggested direct coverage of VSD dressings on the surface of the intestinal tract and immediate skin grafting after granulation formation. While Aydin et al.¹³² supported indirect contact with the intestinal tract and recommended the use of greater omentum or synthetic materials (such as silica gel mesh) to fence out the intestine and dressings. After then negative pressure drainage was applied to promote granulation. One observational study concluded that direct contact of the dressing with the intestinal tract had the risk of causing an intestinal fistula.¹³⁰ With respect to negative pressure in abdominal wall defects, six observational studies recommend that the negative pressure should be at the range of 70–100 mm Hg.^{61–63,66,112,132}

VSD is performed in the repair stage of abdominal wall defects. Three observational studies have shown that VSD can be used in combination with defect repair using synthetic materials (absorbable or non-absorbable) or flap transfer and skin graft during the repair and reconstruction of abdominal wall defects, which can increase the survival rate and shorten the healing time.^{48,129,131}

Does VSD increase the risk of bleeding?

Recommendation 9: Direct contact of VSD foams with blood vessels should be avoided. The use of spacers with self-tissue or artificial materials is recommended and close observation of drainage traits is nonnegligible (Grade C).

A total of 8 observational studies were included.^{135–142}

Although PU material has a large pore size and the potential to injured blood vessels and causes hemorrhage, vascular complications caused by VSD are rare in clinical practice.^{136,137} Bleeding often results from bleeding from fresh granulation tissue, but delayed hemorrhage due to vascular wall erosion after vascular injury is fairly common. Bleeding after VSD is mainly due to the two

situations: coagulation dysfunction and placement of VSD devices directly on the exposed heart or blood vessels, especially blood vessels after anastomosis, from which the suction may block thin-walled blood vessels and cause bleeding.¹³⁷ An observational study has shown that multiple hemorrhages occur after VSD treatment in patients with proximal vascular anastomosis.¹³⁸ To prevent such bleeding, an artificial barrier should be placed between the drainage surface and the foam to avoid affecting contraction of the wound and suction of exudates.^{139,140} Severe bleeding of the aorta after application of VSD to the sternotomy incision was observed in some cases, indicating that scattered fragments at the wound should be removed before applying negative pressure.¹⁴¹ One study has also found that VSD device blockage might cause active bleeding.¹⁴² A retrospective study on 16 patients with deep spinal infection showed two cases of bleeding associated with continuous negative pressure after surgery.¹³⁵

Does VSD increase the risk of intestinal wall injury?

Recommendation 10: When using VSD, the risk of intestinal injury should be monitored (Grade B).

A total of 19 articles involving VSD-related secondary intestinal injury after abdominal surgery were included, of which 2 were RCTs^{143,144} and 17 were retrospective studies.^{19,30,55,93,98,130,145–155}

Whether the use of VSD after abdominal surgery can lead to secondary intestinal injury and increase the incidence of intestinal fistulas is controversial. At present, an increasing number of studies have confirmed that the use of VSD does not increase the incidence of intestinal fistulas.^{21,30,34,50,55,96,127,145,148,152,154,156}

For patients who had no intestinal fistula before surgery, the incidence of intestinal fistula was 1.6%–37% after VSD-assisted TAC.^{19,93,98,130,144–151} In the prospective studies, two RCTs^{143,144} compared the incidence of intestinal fistulas in TAC surgeries using VSD and absorbable mesh fixed on the abdominal fascia and found no significant differences. Among the five observational studies, Plaudis et al.⁵⁵ applied VSD for the treatment of ACS and peritonitis in 22 patients, of whom three had intestinal fistulas. Navsari et al.¹⁴⁸ treated 20 abdominal trauma patients with VSD after surgery, of whom one occurred secondary intestinal fistula and one had intestinal necrosis. Rao et al.³⁰ applied VSD in 29 patients after abdominal surgery and met 6 cases of intestinal fistulas. However, in a prospective observational study of 578 patients undergoing abdominal surgery, Carlson et al.¹⁵² found that the use of VSD did not increase the incidence of intestinal fistulas or intestinal insufficiency; sample matching in this study included a total of 187 pairs of patients and the analysis showed the same conclusions. In a prospective study examining clinical outcomes associated with a negative pressure wound therapy system and Barker's vacuum-packing technique performed by Cheatham et al.,¹⁵³ 280 patients undergoing abdominal surgery were included; 178 were treated with VSD, of which 13 had gastrointestinal ischemic necrosis, 7 intestinal fistulas, and 5 intestinal obstruction. Among the 102 patients treated with Barker's vacuum-packing technique, 3 had gastrointestinal ischemic necrosis, 4 intestinal fistulas, and none intestinal obstruction. The outcomes of using VSD and Barker's vacuum-packing technique were not significantly different. Kleif et al.¹⁵⁴ found that the use of VSD together with mesh-foil-mediated closure reduced the incidence of intestinal fistulas. In a retrospective study of 108 patients undergoing surgical treatment for severe diffuse peritonitis, Mutafchiyski et al.¹⁴⁶ found that the incidences of intestinal fistulas in the groups treated with VSD-assisted TAC and mesh-foil laparostomy were respectively 8% and 19%, but without statistical significance. In another two studies by Bee et al.¹⁴⁴ and Carlson et al.,¹⁵² incidence of intestinal fistulas after

VSD was higher than that of the mesh-foil group, but the difference was not significant.

Five observational studies have shown that OA negative pressure wound treatment does not increase the incidence of intestinal fistulas.^{98,145,147,151,155} Shaikh et al.¹⁵⁵ observed 42 cases of VSD treatment for abdominal incision dehiscence and OA over 5 years. The results showed that the VSD technique was safe and had no direct correlation with the incidence of intestinal fistulas. In a retrospective study performed by Fieger et al.,¹⁴⁷ 82 patients with open abdomen underwent VSD therapy, 16 had intestinal fistulas. Similarly, Björck et al.⁹⁸ showed there's no difference in the incidence of intestinal fistulas between the group using VSD and the group using mesh-mediated fascial traction for TAC after abdominal surgery. A retrospective study performed by Mintziras et al.¹⁵¹ of 43 patients with secondary peritonitis treated with VSD post-operatively, 16 developed intestinal fistulas and the receiver operating characteristic curve (ROC) analysis found that VSD treatment significantly reduced the incidence of intestinal fistulas when the application duration was less than 13 days. In a double-center retrospective study of 81 patients undergoing laparotomy performed by Acosta et al.,¹⁴⁵ the results showed no correlation between intestinal fistula formation and VSD therapy. Additionally, a retrospective study by Montori et al.¹⁵⁷ showed no difference in the incidence of intestinal fistulas between the use of VSD and the modified Barker negative pressure package after abdominal surgery.

Mechanisms of intestinal injury secondary to abdominal VSD include the following. (1) Injury accompanied by abdominal or systemic pathological changes,^{145,151,152,155} including peritonitis & diverticulitis,⁸⁵ mesenteric ischemia, arterial blood lactate greater than 3.5,¹⁵² intestinal blood supply insufficiency, pancreatic necrosis, and diverticulitis.^{34,145,154} (2) Injury caused by decreased blood flow to the intestine due to negative pressure. Two observational studies showed that a negative pressure value of -17 kPa (-125 mmHg) had excellent drainage effects and caused little damage to the small intestine.^{8,17} One observational study showed that a negative pressure of -6.7 kPa to -22.6 kPa (-50 mmHg to -170 mmHg) significantly reduced the intestinal microvascular blood flow and the reduction amount was positively correlated with the negative pressure values.¹⁴² Two observational studies showed that -10.6 kPa (-80 mmHg) was the optimal negative pressure for blood perfusion and cell growth^{23,24}; however, the setting of negative pressure value needs to be further investigated. (3) The injury caused by direct stimulation of foam materials, which is associated with an excessive long application of VSD and frequent replacement.⁵⁵ Two observational studies have shown that trimming the foam to approximately 1 cm from the anastomosis,^{158,159} placing the greater omentum between the foam and the intestine, applying hydrocolloid Ag dressing, and open hole dressing (such as Vaseline gauze, plastic films, or Bogota bag) can reduce spotty intestinal hemorrhagic lesions.^{19,160}

Does VSD increase the risk of peritoneal adhesion?

Recommendation 11: During the application of VSD, the occurrence of peritoneal adhesions should be monitored. When applying VSD-assisted TAC, placement of a plastic film between the intestine and the abdominal wall helps reduce adhesions and improve early closure of the fascia (Grade C).

A total of 9 articles were included, with eight retrospective studies^{161–167} and one expert consensus.¹⁶⁸

Intestinal adhesion is a common complication after abdominal surgery, with an incidence of up to 90%.^{169–173} Peritoneal adhesion mainly refers to abnormal adhesion between the intestinal tracts, between the intestine and the peritoneum, or between the

intestine and the intra-abdominal organs.¹⁷⁴ Pathological factors, such as peritoneal inflammation, mechanical injury, tissue ischemia, and foreign body implantation, can cause damage to the peritoneal surface, leading to the occurrence of peritoneal adhesions.^{175–182} The impact of the intraperitoneal application of VSD on the formation of peritoneal adhesions has not been established. One observational studies by Magalini et al.¹²⁰ suggested that the use of VSD to enhance drainage of gastrointestinal fistulas could reduce the extent and scope of intestinal adhesion and facilitate subsequent surgery.

In OA surgeries for the treatment of diseases such as ACS, the use of VSD-assisted TAC technology can effectively reduce the intra-abdominal pressure but cannot avoid the formation of adhesions.^{161–163} Intestinal adhesions and fascia retraction could occur with prolonged length of the abdominal opening; if the abdominal wall cannot be closed early, skin grafting must be performed on top of the granulation tissue, to form a planned abdominal hernia.^{162,164–167} Consensus on the open abdomen in trauma 2016¹⁶⁸ recommended the use of a layer of polypropylene plastic film between the VSD and the intra-abdominal organs to reduce the incidence of intestinal adhesion, thus facilitating fascial closure and reducing the occurrence of related complications.

Summary

There are many problems to be solved in abdominal surgeries. The invention of VSD and related technologies has brought hope to the treatment of some abdominal surgery complications. Proper use of VSD in abdominal surgery can lower the risk of infection in the high-risk abdominal incision with primary suture, treat the severely contaminated/infected surgical site and for the temporary abdominal cavity closure. However, the recommendations in this guideline were concluded based on the clinical using experience and the research results, some of which were with small sample retrospective ones. So more high-quality RCTs are needed to validate and improve the future application of VSD for abdominal surgery.

Funding

Nil.

Acknowledgement

None at present.

Ethical statement

Not applicable; as this is a review.

Conflicts of interest

The authors disclose no conflicts of interest relevant to the present study.

References

- Redon H, Jost WH, Troques R. Closure under reduced atmospheric pressure of extensive wounds. *Mem Acad Chir (Paris)*. 1954;80:394–396.
- WC M. The role of closed wound negative pressure suction in radical surgical procedures of the head and neck. *Laryngoscope*. 1964;74:70–94.
- Fox 4th JW, Golden GT, Rodeheaver G, Edgerton MT, Edlich RF. Nonoperative management of fingertip pulp amputation by occlusive dressings. *Am J Surg*. 1977;133:255–256.
- Fleischmann W., Lang E., Russ M. [Treatment of infection by vacuum sealing]. *Unfallchirurg*. 1997;100:301–304.

5. Fleischmann W, Strecker W, Bombelli M, et al. [Vacuum sealing as treatment of soft tissue damage in open fractures]. *Unfallchirurg*. 1993;96:488–492.
6. Zeng ZQ, Qiu HD, Tao SM, et al. Application of vacuum sealing drainage in body surface abscess. *Modern Clin General Surg*. 1998;3:20–21.
7. Argenta LCM. Vacuum-assisted closure: a new method for wound control and treatment: clinical experience. *Ann Plast Surg*. 1997;38:563–576.
8. Morykwas MJ, Argenta LC, Shelton-Brown EI, et al. Vacuum-assisted closure: a new method for wound control and treatment: animal studies and basic foundation. *Ann Plast Surg*. 1997;38:553–562.
9. Oxford Centre for Evidence-Based Medicine – Levels of Evidence; March 2009. <http://www2.cch.org.tw/ebm/file/CEBM-Levels-of-Evidence.pdf?crazycache=1>.
10. Milleret V, Bittermann AG, Mayer D, et al. Analysis of effective interconnectivity of DegraPol-foams designed for negative pressure wound therapy. *Materials*. 2009;2:292–306.
11. Chattopadhyay DK, Raju KVS. Structural engineering of polyurethane coatings for high performance applications. *Prog Polym Sci*. 2007;32:352–418.
12. Meng Q, Hu J, Liu B, et al. A low-temperature thermoplastic anti-bacterial medical orthotic material made of shape memory polyurethane ionomer: influence of ionic group. *J Biomater Sci Polym Ed*. 2009;20:199–218.
13. Acelity. A Versatile, Comfortable Polyvinyl Alcohol (PVA) Dressing for Use with V.A.C.[®] Therapy.
14. Dai L, Yu S. Effect of degree of saponification on structural and property change of poly(Vinyl alcohol) fibers. *Polym Adv Technol*. 2010;14:449–457.
15. Cole PA, Theodore M, Ly TV, et al. What's new in orthopaedic trauma. *J Bone Joint Surg Am Vol*. 2004;86(A):2782.
16. Ranjeetesh K, Singh RN, Singh BN. Comparative prospective study of proximal femoral nail and dynamic hip screw in treatment of intertrochanteric fracture femur. *J Clin Orthop Traumatol*. 2012;3:28–36.
17. Pan Y, Zeng Q, Wang K, et al. Application of negative pressure wound therapy with different negative pressures to open abdominal wound repair. *Practical J Clin Med*. 2015;12(2):44–46.
18. LY Z. Emphasizing the application of vacuum sealing drainage in abdominal surgery. *J Trauma Surg*. 2012;14:389–391.
19. Heller L, Levin SL, Butler CE. Management of abdominal wound dehiscence using vacuum assisted closure in patients with compromised healing. *Am J Surg*. 2006;191:165–172.
20. Wondberg D, Larusson HJ, Metzger U, et al. Treatment of the open abdomen with the commercially available vacuum-assisted closure system in patients with abdominal sepsis. *World J Surg*. 2008;32:2724–2729.
21. Bruhin A, Ferreira F, Chariker M, et al. Systematic review and evidence based recommendations for the use of negative pressure wound therapy in the open abdomen. *Int J Surg*. 2014;12:1105–1114.
22. Suliburk JW, Ware DN, Zsolt B, et al. Vacuum-assisted wound closure achieves early fascial closure of open abdomens after severe trauma. *J Trauma*. 2003;55:1155–1160.
23. Ola B, Richard I, Malin M. Wound edge microvascular blood flow during negative-pressure wound therapy: examining the effects of pressures from –10 to –175 mmHg. *Plast Reconstr Surg*. 2010;125:502–509.
24. Nease C. Using low pressure, NPWT for wound preparation & the management of split-thickness skin grafts in 3 patients with complex wound. *Ostomy/Wound Manag*. 2009;55:32–42.
25. Yang YT, Song CJ, Ma BQ, et al. Intra-abdominal volume increment combined with VSD in the treatment of intra-abdominal hypotension/abdominal compartment syndrome. *J Trauma Surg*. 2016;18:455–457.
26. HT Y. Vacuum sealing drainage system in the treatment of early postoperative wound infection following abdominal wall hernia repair. *Chin J Hernia Abdom Wall Surg (Electronic Version)*. 2015;9:337–339.
27. Du JWLY. Clinical effect of temporary closure of abdomen in severe abdominal infection. *E-J Transl Med*. 2015;2:52–53.
28. Chuo CB, Thomas SS. Absorbable mesh and topical negative pressure therapy for closure of abdominal dehiscence with exposed bowel. *J Plast Reconstr Aesthetic Surg*. 2008;61:1378–1381.
29. Caviggioli F, Klinger FM, Lisa A, et al. Matching biological mesh and negative pressure wound therapy in reconstructing an open abdomen defect. *Case Rep Med*. 2014;235930:19.
30. Rao M, Burke D, Finan PJ, et al. The use of vacuum-assisted closure of abdominal wounds: a word of caution. *Colorectal Dis*. 2007;9:266–268.
31. Armstrong DG. Discussion. Update on negative-pressure wound therapy. *Plast Reconstr Surg*. 2011;127.
32. Uchino M, Hirose K, Bando T, et al. Randomized controlled trial of prophylactic negative-pressure wound therapy at ostomy closure for the prevention of delayed wound healing and surgical site infection in patients with ulcerative colitis. *Dig Surg*. 2016;33:449–454.
33. Shen P, Blackham AU, Lewis S, et al. Phase II randomized trial of negative-pressure wound therapy to decrease surgical site infection in patients undergoing laparotomy for gastrointestinal, pancreatic, and peritoneal surface malignancies. *J Am Coll Surg*. 2017;224:726–737.
34. Gunatilake RP, Swamy GK, Brancaccio LR, et al. Closed-incision negative-pressure therapy in obese patients undergoing cesarean delivery: a randomized controlled trial. *AJP Rep*. 2017;7:e151–e157.
35. O'Leary DP, Peirce C, Anglim B, et al. Prophylactic negative pressure dressing use in closed laparotomy wounds following abdominal operations: a randomized, controlled, open-label trial: the P.I.C.O. Trial. *Ann Surg*. 2017;265:1082–1086.
36. Li PY, Yang D, Liu D, et al. Reducing surgical site infection with negative-pressure wound therapy after open abdominal surgery: a prospective randomized controlled study. *Scand J Surg*. 2017;106:189–195.
37. Masden D, Goldstein J, Endara M, et al. Negative pressure wound therapy for at-risk surgical closures in patients with multiple comorbidities: a prospective randomized controlled study. *Ann Surg*. 2012;255:1043–1047.
38. Selvaggi F, Pellino G, Sciaudone G, et al. New advances in negative pressure wound therapy (NPWT) for surgical wounds of patients affected with Crohn's disease. *Surg Technol Int*. 2014;24:83–89.
39. Allen G. Evidence appraisal of Blackham AU, Farrah JP, McCoy TP, Schmidt BS, Shen P. Prevention of surgical site infections in high-risk patients with laparotomy incisions using negative-pressure therapy. *Am J Surg*. 2013;205(6):647–654. Aorn J. 2013;98:320–324.
40. Bonds AM, Novick TK, Diertier JB, et al. Incisional negative pressure wound therapy significantly reduces surgical site infection in open colorectal surgery. *Dis Colon Rectum*. 2013;56:1403–1408.
41. Chadi SA, Kidane B, Britto K, et al. Incisional negative pressure wound therapy decreases the frequency of postoperative perineal surgical site infections: a cohort study. *Dis Colon Rectum*. 2014;57:999–1006.
42. Pellino G, Sciaudone G, Candilio G, et al. Effects of a new pocket device for negative pressure wound therapy on surgical wounds of patients affected with Crohn's disease: a pilot trial. *Surg Innovat*. 2014;21:204–212.
43. Zaidi A, El-Masry S. Closed-incision negative-pressure therapy in high-risk general surgery patients following laparotomy: a retrospective study. *Colorectal Dis*. 2017;19:283–287.
44. Lynam S, Mark KS, Temkin SM. Primary placement of incisional negative pressure wound therapy at time of laparotomy for gynecologic malignancies. *Int J Gynecol Cancer*. 2016;26:1525–1529.
45. Anglim B, O'Connor H, Daly S. Prevena, negative pressure wound therapy applied to closed Pfannenstiel incisions at time of caesarean section in patients deemed at high risk for wound infection. *J Obstet Gynaecol*. 2015;35:255–258.
46. Huo JS, Chen WM, Wu RZ, et al. Treatment for severe injury in conjoint part of common bile duct, duodenum and pancreas by vacuum sealing drainage. *J Trauma Surg*. 2017;19:17–21.
47. Zhai B, Jin X, Wang R, et al. Applying negative pressure wound therapy in associating liver partition and portal vein ligation for staged hepatectomy: a case report. *Exp Ther Med*. 2017;14:642–646.
48. Obolenskii VN, Ermolov AA, Oganessian KS, et al. [Vacuum-assisted laparotomy in complex treatment of patient with peritonitis and internal biliary fistula]. *Khirurgiia*. 2013;12:91–94.
49. Dondossola D, Cavenago M, Piconi S, et al. Negative pressure wound treatment of infections caused by extensively drug-resistant gram-negative bacteria after liver transplantation: two case reports. *Transplant Proc*. 2015;47:2145–2149.
50. Fitzgerald JE, Gupta S, Masterson S, et al. Laparostomy management using the ABThera open abdomen negative pressure therapy system in a grade IV open abdomen secondary to acute pancreatitis. *Int Wound J*. 2013;10:138–144.
51. Zanus G, Boetto R, D'Amico F, et al. A novel approach to severe acute pancreatitis in sequential liver-kidney transplantation: the first report on the application of VAC therapy. *Transpl Int*. 2011;24:1432–1437.
52. Ruiz-Lopez M, Carrasco Campos J, Sanchez Perez B, et al. [Negative pressure therapy in wounds with enteric fistulas]. *Cir Esp*. 2009;86:29–32.
53. Huo JS, Chen JS, Chen WM, et al. Use of vacuum sealing drainage in treatment of severe pancreatic-duodenal injuries: a report 16 cases. *Chin J Gen Surg*. 2014;23:343–347.
54. Jannasch O, Tautenhahn J, Lippert H, et al. [Temporary abdominal closure and early and late pathophysiological consequences of treating an open abdomen]. *Zentralbl Chir*. 2011;136:575–584.
55. Plaudis H, Rudzats A, Melberga L, et al. Abdominal negative-pressure therapy: a new method in countering abdominal compartment and peritonitis - prospective study and critical review of literature. *Ann Intensive Care*. 2012;20:2110–2120.
56. Hobeika C, Allard MA, Bucur PO, et al. Management of the open abdomen after liver transplantation. *World J Surg*. 2017;41:3199–3204.
57. Kugler NW, Carver TW, Paul JS. Negative pressure therapy is effective in abdominal incision closure. *J Surg Res*. 2016;203:491–494.
58. Smallwood NR, Fleshman JW, Leeds SG, et al. The use of endoluminal vacuum (E-Vac) therapy in the management of upper gastrointestinal leaks and perforations. *Surg Endosc*. 2016;30:2473–2480.
59. Lozano-Balderas G, Ruiz-Velasco-Santacruz A, Diaz-Elizondo JA, et al. Surgical site infection rate drops to 0% using a vacuum-assisted closure in contaminated/dirty infected laparotomy wounds. *Am Surg*. 2017;83:512–514.
60. Burkhardt RA, Javed AA, Ronnekleiv-Kelly S, et al. The use of negative pressure wound therapy to prevent post-operative surgical site infections following pancreaticoduodenectomy. *HPB*. 2017;19:825–831.
61. Pauli EM, Krpata DM, Novitsky YW, et al. Negative pressure therapy for high-risk abdominal wall reconstruction incisions. *Surg Infect*. 2013;14:270–274.
62. de Vries FEE, Atema JJ, Lapid O, et al. Closed incision prophylactic negative pressure wound therapy in patients undergoing major complex abdominal wall repair. *Hernia*. 2017;21:583–589.
63. Gassman A, Mehta A, Bucholdz E, et al. Positive outcomes with negative pressure therapy over primarily closed large abdominal wall reconstruction reduces surgical site infection rates. *Hernia*. 2015;19:273–278.

64. Soares KC, Baltodano PA, Hicks CW, et al. Novel wound management system reduction of surgical site morbidity after ventral hernia repairs: a critical analysis. *Am J Surg.* 2015;209:324–332.
65. Chen B, Hao F, Yang Y, et al. Prophylactic vacuum sealing drainage (VSD) in the prevention of postoperative surgical site infections in pediatric patients with contaminated laparotomy incisions. *Medicine.* 2017;96:000000000006511.
66. Conde-Green A, Chung TL, Holton 3rd LH, et al. Incisional negative-pressure wound therapy versus conventional dressings following abdominal wall reconstruction: a comparative study. *Ann Plast Surg.* 2013;71:394–397.
67. Allegranzi B, Zayed B, Bischoff P, et al. New WHO recommendations on intra-operative and postoperative measures for surgical site infection prevention: an evidence-based global perspective. *Lancet Infect Dis.* 2016;16:e288–e303.
68. Chopra K, Gowda AU, Morrow C, et al. The economic impact of closed-incision negative-pressure therapy in high-risk abdominal incisions: a cost-utility analysis. *Plast Reconstr Surg.* 2016;137:1284–1289.
69. Willy C, Agarwal A, Andersen CA, et al. Closed incision negative pressure therapy: international multidisciplinary consensus recommendations. *Int Wound J.* 2017;14:385–398.
70. Pellino G, Sciaudone G, Candilio G, et al. Preventive NPWT over closed incisions in general surgery: does age matter? *Int J Surg.* 2014;12:S64–S68.
71. Kirkpatrick AW, Roberts DJ, Faris PD, et al. Active negative pressure peritoneal therapy after abbreviated laparotomy: the intraperitoneal vacuum randomized controlled trial. *Ann Surg.* 2015;262:38–46.
72. Roberts DJ, Jenne CN, Ball CG, et al. Efficacy and safety of active negative pressure peritoneal therapy for reducing the systemic inflammatory response after damage control laparotomy (the Intra-peritoneal Vacuum Trial): study protocol for a randomized controlled trial. *Trials.* 2013;14:1745–6215.
73. Giudicelli G, Rossetti A, Scarpa C, et al. Prognostic factors for enterocutaneous fistula in open abdomen treated with negative pressure wound therapy: a multicentre experience. *J Gastrointest Surg.* 2017;21:1328–1334.
74. Franchin M, Tozzi M, Soldini G, et al. A case of continuous negative pressure wound therapy for abdominal infected lymphocele after kidney transplantation. *Case Rep Transpl.* 2014;742161:8.
75. Durai R, Ng PC. Perirectal abscess following procedure for prolapsed haemorrhoids successfully managed with a combination of VAC sponge and Redivac systems. *Tech Coloproctol.* 2009;13:307–309.
76. Tao SM, Wang YF, Qiu HD, et al. Laparoscopic negative pressure closure drainage for severe acute pancreatitis. *J Practical Med.* 2001;17:641–642.
77. Pliakos I, Michalopoulos N, Papavramidis TS, et al. The effect of vacuum-assisted closure in bacterial clearance of the infected abdomen. *Surg Infect.* 2014;15:18–23.
78. Rudzka-Nowak A, Luczywek P, Gajos MJ, et al. Application of manuka honey and GENADYNE A4 negative pressure wound therapy system in a 55-year-old woman with extensive phlegmonous and necrotic lesions in the abdominal integuments and lumbar region after traumatic rupture of the colon. *Med Sci Mon Int Med J Exp Clin Res.* 2010;16:CS138–CS142.
79. Wang YFQH. Application of vacuum sealing drainage in abdominal surgery. *Chin Med J.* 1998;3:119–120.
80. Banasiewicz T, Borejsza-Wysocki M, Meissner W, et al. Vacuum-assisted closure therapy in patients with large postoperative wounds complicated by multiple fistulas. *Wideochir Inne Tech Maloinwazyjne.* 2011;6:155–163.
81. Huo JS, Tao SM, Zeng ZQ, et al. Application of negative pressure closed drainage in primary suture of biliary duct and common bile duct under laparoscopy. *Chin J Minim Invasive Surg.* 2007;7:863–864.
82. Wang CXLL, Wang XY. Research progress of application mechanism of vacuum sealing drainage for trauma repair. *J Trauma Surg.* 2009;11:184–186.
83. LM H. Current concepts in negative pressure wound therapy. *Vet Clin North Am Small Anim Pract.* 2015;45:565–584.
84. Moues CM, Heule F, Hovius SE. A review of topical negative pressure therapy in wound healing: sufficient evidence? *Am J Surg.* 2011;201:544–556.
85. Mennigen R, Senninger N, Laukoetter MG. Novel treatment options for perforations of the upper gastrointestinal tract: endoscopic vacuum therapy and over-the-scope clips. *World J Gastroenterol.* 2014;20:7767–7776.
86. Damiani G, Pinnarelli L, Sommella L, et al. Vacuum-assisted closure therapy for patients with infected sternal wounds: a meta-analysis of current evidence. *J Plast Reconstr Aesthetic Surg.* 2011;64:1119–1123.
87. Shi J, Xi W, Yi C, et al. [Vacuum sealing drainage promotes experimental pig explosive abdomen wound healing]. *Xi Bao Yu Fen Zi Mian Yi Xue Za Zhi.* 2014;30:312–315.
88. Shao JC, Han Y, Wang HK, et al. Research of treating blast injury wound-induced abdominal wall defects in pigs with vacuum sealing drainage. *Chin J Aesthetic Med.* 2011;20:1110–1113.
89. Weed T, Ratliff C, Drake DB. Quantifying bacterial bioburden during negative pressure wound therapy: does the wound VAC enhance bacterial clearance? *Ann Plast Surg.* 2004;52:276–279.
90. Phillips PG, Birnby LM, Narendran A. Hypoxia induces capillary network formation in cultured bovine pulmonary microvessel endothelial cells. *Am J Physiol.* 1995;268.
91. Takei T, Mills I, Arai K, et al. Molecular basis for tissue expansion: clinical implications for the surgeon. *Plast Reconstr Surg.* 1998;102:247–258.
92. Zhang LY. Application of vacuum sealing drainage in abdominal surgery: status and prospects. *J Trauma Surg.* 2016;18(8):490–491.
93. Richter S, Dold S, Doberauer JP, et al. Negative pressure wound therapy for the treatment of the open abdomen and incidence of enteric fistulas: a retrospective bicentre analysis. *Gastroenterol Res Pract.* 2013;730829:28.
94. Regner JL, Kobayashi L, Coimbra R. Surgical strategies for management of the open abdomen. *World J Surg.* 2012;36:497–510.
95. Kirkpatrick AW, Roberts DJ, De Waele J, et al. Intra-abdominal hypertension and the abdominal compartment syndrome: updated consensus definitions and clinical practice guidelines from the World Society of the Abdominal Compartment Syndrome. *Intensive Care Med.* 2013;39:1190–1206.
96. Cristaudo A, Jennings S, Gunnarsson R, et al. Complications and mortality associated with temporary abdominal closure techniques: a systematic review and meta-analysis. *Am Surg.* 2017;83:191–216.
97. Leppaniemi A, Johansson K, De Waele JJ. Abdominal compartment syndrome and acute pancreatitis. *Acta Clin Belg.* 2007;1:131–135.
98. Bjorck M. Vacuum and mesh-mediated fascial traction for primary closure of open abdomen in critically ill surgical patients. *Br J Surg.* 2012;99:1732–1733 (Br J Surg 2012; 99: 1725–1732).
99. Wen JLZX, Liu X. The nursing of pancreatic and duodenal injury in pancreatic juice by vacuum sealing drainage jejunostic tube reinfusion. *Clin Med Eng.* 2011;18:943–944.
100. Perez D, Wildi S, Demartines N, et al. Prospective evaluation of vacuum-assisted closure in abdominal compartment syndrome and severe abdominal sepsis. *J Am Coll Surg.* 2007;205:586–592.
101. Assirati G, Serra V, Tarantino G, et al. Vacuum-assisted closure therapy in patients undergoing liver transplantation with necessity to maintain open abdomen. *Transplant Proc.* 2016;48:383–385.
102. Anand RJ, Ivatury RR. Surgical management of intra-abdominal hypertension and abdominal compartment syndrome. *Am Surg.* 2011;77:S42–S45.
103. Tautenhahn J, Pross M, Kuhn R, et al. The use of VAC(R)-System in wound management for borderline indications. *Zbl Chir.* 2004;129:S12–S13.
104. Sibaja P, Sanchez A, Villegas G, et al. Management of the open abdomen using negative pressure wound therapy with instillation in severe abdominal sepsis: a review of 48 cases in Hospital Mexico, Costa Rica. *Int J Surg Case Rep.* 2017;30:26–30.
105. Riha GM, Kiraly LN, Diggs BS, et al. Management of the open abdomen during the global war on terror. *JAMA Surg.* 2013;148:59–64.
106. Ribeiro Junior MA, Barros EA, de Carvalho SM, et al. Open abdomen in gastrointestinal surgery: which technique is the best for temporary closure during damage control? *World J Gastrointest Surg.* 2016;8:590–597.
107. Miranda-Diaz AG, Hermsillo-Sandoval JM, Gutierrez-Martinez CA, et al. Effect of necrosectomy and vacuum-assisted closure (VAC) on mitochondrial function and oxidative stress markers in severe acute pancreatitis. *Rev Esp Enferm Dig.* 2014;106:505–514.
108. Sermoneta D, Di Mugno M, Spada PL, et al. Intra-abdominal vacuum-assisted closure (VAC) after necrosectomy for acute necrotising pancreatitis: preliminary experience. *Int Wound J.* 2010;7:525–530.
109. Olejnik J, Vokurka J, Vician M. Acute necrotizing pancreatitis: intra-abdominal vacuum sealing after necrosectomy. *Hepato-Gastroenterology.* 2008;55:315–318.
110. Bobkiewicz A, Walczak D, Smolinski S, et al. Management of enterocutaneous fistula with negative pressure wound therapy in open abdomen treatment: a multicentre observational study. *Int Wound J.* 2017;14:255–264.
111. Misky A, Hotouras A, Ribas Y, et al. A systematic literature review on the use of vacuum assisted closure for enterocutaneous fistula. *Colorectal Dis.* 2016;18:846–851.
112. de Weerd L, Kjaeve J, Aghajani E, et al. The sandwich design: a new method to close a high-output enterocutaneous fistula and an associated abdominal wall defect. *Ann Plast Surg.* 2007;58:580–583.
113. Gunn LA, Follmar KE, Wong MS, et al. Management of enterocutaneous fistulas using negative-pressure dressings. *Ann Plast Surg.* 2006;57:621–625.
114. Nienhuijs SW, Manupassara R, Strobbe LJ, et al. Can topical negative pressure be used to control complex enterocutaneous fistulae? *J Wound Care.* 2003;12:343–345.
115. Alvarez AA, Maxwell GL, Rodriguez GC. Vacuum-assisted closure for cutaneous gastrointestinal fistula management. *Gynecol Oncol.* 2001;80:413–416.
116. Cro C, George KJ, Donnelly J, et al. Vacuum assisted closure system in the management of enterocutaneous fistulae. *Postgrad Med.* 2002;78:364–365.
117. Tavusbay C, Genc H, Cin N, et al. Use of a vacuum-assisted closure system for the management of enterocutaneous fistulae. *Surg Today.* 2015;45:1102–1111.
118. Wainstein DE, Fernandez E, Gonzalez D, et al. Treatment of high-output enterocutaneous fistulas with a vacuum-compaction device. A ten-year experience. *World J Surg.* 2008;32:430–435.
119. Ma D, Chen JH, Yang H, et al. Application of vacuum sealing drainage in high intestinal fistula. *J Trauma Surg.* 2016;18:458–460.
120. Magalini S, Pepe G, Cozza V, et al. Negative pressure wound therapy (NPWT) in duodenal breakdown fistulas: negative pressure fistula therapy (NPFT)? *Eur Rev Med Pharmacol Sci.* 2017;21:2452–2457.
121. Boulanger K, Lemaire V, Jacquemin D. Vacuum-assisted closure of enterocutaneous fistula. *Acta Chir Belg.* 2007;107:703–705.
122. Pepe G, Magalini S, Callari C, et al. Vacuum Assisted Closure (VAC) therapy/TM as a swiss knife multi-tool for enteric fistula closure: tips and tricks: a pilot study. *Eur Rev Med Pharmacol Sci.* 2014;18:2527–2532.
123. Becker HP, Willms A, Schwab R. Small bowel fistulas and the open abdomen. *Scand J Surg.* 2007;96:263–271.

124. Verhaalen A, Watkins B, Brasel K. Techniques and cost effectiveness of enteroatmospheric fistula isolation. *Wounds*. 2010;22:212–217.
125. Goverman J, Yelon JA, Platz JJ, et al. The “Fistula VAC,” a technique for management of enterocutaneous fistulae arising within the open abdomen: report of 5 cases. *J Trauma*. 2006;60:428–431.
126. Shen W, Zhang YC, Tao GQ, et al. Treatment of intestinal cutaneous fistula by vacuum sealing drainage device. *Chin J Curr Adv Gen Surg*. 2016;19:707–710.
127. Jaguscik R, Walczak DA, Porzezynska J, et al. The use of negative pressure wound therapy (NPWT) in the management of enteroatmospheric fistula—case report and literature review. *Pol Przegl Chir*. 2015;87:522–527.
128. Stremitzer S, Dal Borgo A, Wild T, et al. Successful bridging treatment and healing of enteric fistulae by vacuum-assisted closure (VAC) therapy and targeted drainage in patients with open abdomen. *Int J Colorectal Dis*. 2011;26:661–666.
129. Schmelzle M, Aildinger I, Matthaei H, et al. Long-term vacuum-assisted closure in open abdomen due to secondary peritonitis: a retrospective evaluation of a selected group of patients. *Dig Surg*. 2010;27:272–278.
130. Bertelsen CA, Fabricius R, Kleif J, et al. Outcome of negative-pressure wound therapy for open abdomen treatment after nontraumatic lower gastrointestinal surgery: analysis of factors affecting delayed fascial closure in 101 patients. *World J Surg*. 2014;38:774–781.
131. Kafka-Ritsch R, Birkfellner F, Perathoner A, et al. Damage control surgery with abdominal vacuum and delayed bowel reconstruction in patients with perforated diverticulitis Hinchey III/IV. *J Gastrointest Surg*. 2012;16:1915–1922.
132. Aydin D, Paulsen IF, Bentzen VE, et al. Reconstruction of massive full-thickness abdominal wall defect: successful treatment with nonabsorbable mesh, negative pressure wound therapy, and split-skin grafting. *Clin Case Rep*. 2016;4:982–985.
133. Chen FZH, Qian H. Clinical comparison of temporary abdominal closure and conventional abdominal closure in the treatment of severe abdominal infection. *Chin J Minimally Invasive Surg*. 2015;15:628–631.
134. Shin JS, Choi HJ. Application of a silicone sheet in negative-pressure wound therapy to treat an abdominal wall defect after necrotizing fasciitis. *Arch Plast Surg*. 2017;44:76–79.
135. Jones GA, Butler J, Lieberman I, et al. Negative-pressure wound therapy in the treatment of complex postoperative spinal wound infections: complications and lessons learned using vacuum-assisted closure. *J Neurosurg Spine*. 2007;6:407–411.
136. Nolf MC, Meyer-Lindenberg A. [Negative Pressure Wound Therapy (NPWT) in small animal medicine. Mechanisms of action, applications and indications]. *Tierarztl Prax Ausg K Kleintiere Heimtiere*. 2016;44:26–37.
137. Martindell D. The safe use of negative-pressure wound therapy. *Am J Nurs*. 2012;112:59–63.
138. Cheng HT, Hsu YC, Wu CI. Efficacy and safety of negative pressure wound therapy for Szilagyi grade III peripheral vascular graft infection. *Interact Cardiovasc Thorac Surg*. 2014;19:1048–1052.
139. Anesater E, Borgquist O, Torbrand C, et al. The use of a rigid disc to protect exposed structures in wounds treated with negative pressure wound therapy: effects on wound bed pressure and microvascular blood flow. *Wound Repair Regen*. 2012;20:611–616.
140. Anesater E, Roupe KM, Robertsson P, et al. The influence on wound contraction and fluid evacuation of a rigid disc inserted to protect exposed organs during negative pressure wound therapy. *Int Wound J*. 2011;8:393–399.
141. Kiessling AH, Lehmann A, Isgro F, et al. Tremendous bleeding complication after vacuum-assisted sternal closure. *J Cardiothorac Surg*. 2011;6:1749–8090.
142. Schimp VL, Worley C, Brunello S, et al. Vacuum-assisted closure in the treatment of gynecologic oncology wound failures. *Gynecol Oncol*. 2004;92:586–591.
143. Correa JC, Mejia DA, Duque N, et al. Managing the open abdomen: negative pressure closure versus mesh-mediated fascial traction closure: a randomized trial. *Hernia*. 2016;20:221–229.
144. Bee TK, Croce MA, Magnotti LJ, et al. Temporary abdominal closure techniques: a prospective randomized trial comparing polyglactin 910 mesh and vacuum-assisted closure. *J Trauma*. 2008;65:337–342.
145. Acosta S, Bjarnason T, Petersson U, et al. Multicentre prospective study of fascial closure rate after open abdomen with vacuum and mesh-mediated fascial traction. *Br J Surg*. 2011;98:735–743.
146. Mutafchiyski VM, Popivanov GI, Kjossev KT, et al. Open abdomen and VAC(R) in severe diffuse peritonitis. *J Roy Army Med Corps*. 2016;162:30–34.
147. Fieger AJ, Schwatlo F, Mundel DF, et al. [Abdominal vacuum therapy for the open abdomen – a retrospective analysis of 82 consecutive patients]. *Zentralbl Chir*. 2011;136:56–60.
148. Navsaria P, Nicol A, Hudson D, et al. Negative pressure wound therapy management of the “open abdomen” following trauma: a prospective study and systematic review. *World J Emerg Surg*. 2013;8:1749–7922.
149. Hougaard HT, Ellebaek M, Holst UT, et al. The open abdomen: temporary closure with a modified negative pressure therapy technique. *Int Wound J*. 2014;1:13–16.
150. Kafka-Ritsch R, Zitt M, Schorn N, et al. Open abdomen treatment with dynamic sutures and topical negative pressure resulting in a high primary fascia closure rate. *World J Surg*. 2012;36:1765–1771.
151. Mintziras I, Miligkos M, Bartsch DK. High risk of fistula formation in vacuum-assisted closure therapy in patients with open abdomen due to secondary peritonitis—a retrospective analysis. *Langenbeck's Arch Surg*. 2016;401:619–625.
152. Carlson GL, Patrick H, Amin AI, et al. Management of the open abdomen: a national study of clinical outcome and safety of negative pressure wound therapy. *Ann Surg*. 2013;257:1154–1159.
153. Cheatham ML, Demetriades D, Fabian TC, et al. Prospective study examining clinical outcomes associated with a negative pressure wound therapy system and Barker's vacuum packing technique. *World J Surg*. 2013;37:2018–2030.
154. Kleif J, Fabricius R, Bertelsen CA, et al. Promising results after vacuum-assisted wound closure and mesh-mediated fascial traction. *Dan Med J*. 2012;59.
155. Shaikh IA, Ballard-Wilson A, Yalamarthi S, et al. Use of topical negative pressure in assisted abdominal closure does not lead to high incidence of enteric fistulae. *Colorectal Dis*. 2010;12:931–934.
156. Seternes A, Rekstad LC, Mo S, et al. Open abdomen treated with negative pressure wound therapy: indications, management and survival. *World J Surg*. 2017;41:152–161.
157. Montori G, Allievi N, Coccolini F, et al. Negative pressure wound therapy versus modified barker vacuum pack as temporary abdominal closure technique for open abdomen management: a four-year experience. *BMC Surg*. 2017;17:017–0281.
158. Lindstedt S, Malmso M, Hansson J, et al. Macroscopic changes during negative pressure wound therapy of the open abdomen using conventional negative pressure wound therapy and NPWT with a protective disc over the intestines. *BMC Surg*. 2011;11:1471–2482.
159. Lindstedt S, Malmso M, Hansson J, et al. Pressure transduction and fluid evacuation during conventional negative pressure wound therapy of the open abdomen and NPWT using a protective disc over the intestines. *BMC Surg*. 2012;12:1471–2482.
160. Fansler RF, Taheri P, Cullinane C, et al. Polypropylene mesh closure of the complicated abdominal wound. *Am J Surg*. 1995;170:15–18.
161. Fantus RJ, Mellett MM, Kirby JP. Use of controlled fascial tension and an adhesion preventing barrier to achieve delayed primary fascial closure in patients managed with an open abdomen. *Am J Surg*. 2006;192:243–247.
162. Barker DE, Kaufman HJ, Smith LA, et al. Vacuum pack technique of temporary abdominal closure: a 7-year experience with 112 patients. *J Trauma*. 2000;48:201–206.
163. Miller PR, Meredith JW, Johnson JC, et al. Prospective evaluation of vacuum-assisted fascial closure after open abdomen: planned ventral hernia rate is substantially reduced. *Ann Surg*. 2004;239:608–614.
164. Vidal MG, Ruiz Weisser J, Gonzalez F, et al. Incidence and clinical effects of intra-abdominal hypertension in critically ill patients. *Crit Care Med*. 2008;36:1823–1831.
165. Raeburn CD, Moore EE, Biffi WL, et al. The abdominal compartment syndrome is a morbid complication of postinjury damage control surgery. *Am J Surg*. 2001;182:542–546.
166. Cheatham ML, Safcsak K. Is the evolving management of intra-abdominal hypertension and abdominal compartment syndrome improving survival? *Crit Care Med*. 2010;38:402–407.
167. Miller RS, Morris Jr JA, Diaz Jr JJ, et al. Complications after 344 damage-control open celiotomies. *J Trauma*. 2005;59:1365–1371.
168. Chiara O, Cimbanassi S, Biffi W, et al. International consensus conference on open abdomen in trauma. *J Trauma Acute Care Surg*. 2016;80:173–183.
169. Ellis H. The clinical significance of adhesions: focus on intestinal obstruction. *Eur J Surg Suppl*. 1997;577:5–9.
170. Ellis H. Medicolegal consequences of postoperative intra-abdominal adhesions. *J R Soc Med*. 2001;94:331–332.
171. Duron JJ. Postoperative intraperitoneal adhesion pathophysiology. *Colorectal Dis*. 2007;2:14–24.
172. Moris D, Chakedis J, Rahnemai-Azar AA, et al. Postoperative abdominal adhesions: clinical significance and advances in prevention and management. *J Gastrointest Surg*. 2017;21:1713–1722.
173. Boland GM, Weigel RJ. Formation and prevention of postoperative abdominal adhesions. *J Surg Res*. 2006;132:3–12.
174. Hackethal A, Sick C, Szalay G, et al. Intra-abdominal adhesion formation: does surgical approach matter? Questionnaire survey of South Asian surgeons and literature review. *J Obstet Gynaecol Res*. 2011;37:1382–1390.
175. Bruggmann D, Tchartchian G, Wallwiener M, et al. Intra-abdominal adhesions: definition, origin, significance in surgical practice, and treatment options. *Dtsch Arztebl Int*. 2010;107:769–775.
176. Beyene RT, Kavalukas SL, Barbul A. Intra-abdominal adhesions: anatomy, physiology, pathophysiology, and treatment. *Curr Probl Surg*. 2015;52:271–319.
177. Maciver AH, McCall M, James Shapiro AM. Intra-abdominal adhesions: cellular mechanisms and strategies for prevention. *Int J Surg*. 2011;9:589–594.
178. Thaler K, Mack JA, Zhao RH, et al. Expression of connective tissue growth factor in intra-abdominal adhesions. *Dis Colon Rectum*. 2002;45:1510–1519.
179. Tokita Y, Yuzurihara M, Satoh K, et al. The cholinergic nervous system plays an important role in rat postoperative intestinal adhesion. *Surgery*. 2008;143:226–232.
180. Arung W, Meurisse M, Detry O. *Pathophysiology and Prevention of Postoperative Peritoneal Adhesions*. vol. 17. 2011:4545–4553.
181. Holmdahl L, Eriksson E, al-Jabreen M, et al. Fibrinolysis in human peritoneum during operation. *Surgery*. 1996;119:701–705.
182. Ivarsson ML, Bergstrom M, Eriksson E, et al. Tissue markers as predictors of postoperative adhesions. *Br J Surg*. 1998;85:1549–1554.