

Percutaneous gastrostomy placement by intervention radiology: Techniques and outcome

Balasubramanian Karthikumar, Shyamkumar N Keshava, Vinu Moses, George K Chiramel, Munawwar Ahmed, Suraj Mammen

Department of Radiology, Christian Medical College, Vellore, Tamil Nadu, India

Correspondence: Dr. Shyamkumar N Keshava, Professor, Department of Radiology, Christian Medical College, Vellore, Tamil Nadu, India.
E-mail: aparna_shyam@cmcvellore.ac.in

Abstract

Background: Interventional radiology (IR) has played an important role in the technical evolution of gastrostomy, from the first surgical, endoscopical to percutaneous interventional procedures. **Aim:** This study is done to assess the technical feasibility and outcome of IR-guided percutaneous gastrostomy for patients requiring nutritional support for neuromuscular disorders or head and neck malignancies, as well as to describe simplified and newer technique for pull-type gastrostomy. **Materials and Methods:** This is a retrospective study including 29 patients who underwent IR-guided percutaneous gastrostomy over a period of 8 years in a tertiary-level institution. Either pull or push-type gastrostomy was performed in these patients as decided by the interventional radiologist. The procedures were assessed by analyzing the indications, technical aspects, and complications. **Statistical Analysis:** Descriptive summary statistics and frequencies were used to assess the techniques and related complications. **Results:** The sample consists of 27 patients (93%) with pull technique and 2 patients (7%) with push technique. The technical success rate was 100%. Most of the complications were minor 24% (7/29), including superficial skin infections around the tube site, self-resolving pneumoperitoneum, tube-related complications such as block, leakage, deformation, and dislodgement. Three patients (10.3%) had major complications. One patient (3.4%) developed massive pneumoperitoneum and mild peritonitis due to technical failure in the first attempt and needed re-puncture for successful placement, and other two patients (6.9%) developed peristomal focal abscess. One patient died on the third postoperative day due to type II respiratory failure. **Conclusion:** IR-guided percutaneous gastrostomy is a safe and effective procedure in selected patients.

Key words: Fluoroscopy-guided percutaneous gastrostomy; percutaneous radiological gastrostomy; per-oral image-guided gastrostomy; pull-type gastrostomy; push-type gastrostomy

Introduction

Gastrostomy provides an alternative access for nutritional support in patients with long-term impairment of oral intake. It is well tolerated for nutritional supplementation, generally provides improved quality of life when compared

to available alternatives, and limits disorders of intestinal motility by maintaining gastrointestinal tract function.^[1]

Gastrostomy tubes can be placed surgically, endoscopically, and radiologically. Surgical gastrostomy has the highest

This is an open access journal, and articles are distributed under the terms of the Creative Commons Attribution-NonCommercial-ShareAlike 4.0 License, which allows others to remix, tweak, and build upon the work non-commercially, as long as appropriate credit is given and the new creations are licensed under the identical terms.

For reprints contact: reprints@medknow.com

Cite this article as: Karthikumar B, Keshava SN, Moses V, Chiramel GK, Ahmed M, Mammen S. Percutaneous gastrostomy placement by intervention radiology: Techniques and outcome. *Indian J Radiol Imaging* 2018;28:225-31.

Access this article online	
Quick Response Code:	Website: www.ijri.org
	DOI: 10.4103/ijri.IJRI_393_17

total complication rate of 29% compared to approximately 15% for percutaneous endoscopic gastrostomy (PEG) or radiological gastrostomy.^[2] Percutaneous radiological gastrostomy (PRG) is the least invasive compared to other techniques, and major complications are the fewest with radiological gastrostomy.^[2] The term PRG is used generically to indicate percutaneous access to stomach or jejunum under fluoroscopic guidance.^[3]

Since the introduction of PRG in 1981, several different techniques were subsequently developed. The techniques for percutaneous insertion and the equipment used have been refined since then and it is now considered as the gold standard for gastrostomy insertion.^[4] Radiologically-guided techniques can be divided into two classes. The first is the “push-type gastrostomy,” namely the conventional percutaneous gastrostomy with an external/internal access through the abdominal wall into the stomach. The second is the “pull-type gastrostomy,” which has been adapted from the PEG technique with an internal/external placement of the respective gastrostomy catheter.^[5]

The purpose of this study is to describe the technical aspects of routine PRG catheter placement and to provide procedural variations based on different etiologies as well as to assess the technical feasibility and outcome of PRG.

Materials and Methods

This was a retrospective study conducted among 29 patients who underwent PRG over a period of 8 years in a tertiary-level academic institution. The clinical details of each patient were collected from the online medical records department of the institution (Clinical workstation, GE Healthcare, USA). Pull type was performed in 27 patients (27/29) and push type was performed in 2 patients (2/29).

Ultrasound abdomen screening was done to look for anatomical variations and to plan the procedure. In patients who had already undergone abdominal computed tomography (CT) for tumor screening or other purposes, CT images were also reviewed to plan the procedure.

Techniques

Patients were usually admitted in hospital at least 12 h before the procedure and kept fasting for at least 6 h. The coagulation profile was checked in all cases and nasogastric tube was placed shortly before the procedure to allow air insufflation. In our protocol the pre-procedural preparation for both the techniques remain the same [Table 1] except additional antiseptic mouthwash given for patients undergoing pull type. Both types of procedures were done under intravenous sedation and local anesthesia.

Table 1: Pre-procedural workup for PRG

Lab results and prior imaging studies:

Platelets >50,000/ μ L, PT INR <1.5, aPTT <40

Imaging to preclude ascites and anatomical variations like hiatus hernia, interposition of colon, enlarged liver and situs inversus etc.,

Patient preparation before the procedure:

Antiseptic mouth rise on the day of procedure in pull type

Local preparation of abdomen (shaving and betadine scrub)

Premedication

Broad spectrum i.v antibiotics on the day of procedure

Pull-type percutaneous radiological gastrostomy (Pull-type-PRG)

The “pull-through gastrostomy” was performed using the 24-Fr silicon tube of a PEG set for endoscopic use (PEG-24-PULL-I-S; Wilson-Cook Medical, Winston-Salem, USA). This tube consists of a mushroom catheter tip at the proximal end with inner and outer bolsters for fixation with tubing clamp.

The stomach was distended with atmospheric air through an indwelling nasogastric tube (approx. 1000 ml). Gastric puncture performed under fluoroscopic guidance with 18G puncture needle in lower one-third of body in the middle of the stomach (equidistant from the greater and lesser curvatures) to avoid injury to gastroepiploic artery and lateral to the rectus muscle, or in the midline to avoid puncture of epigastric arteries. These are the preferred sites for gastric puncture^[6] [Figure 1].

After gastric puncture confirmed by aspiration of air into a syringe or flushing with contrast media, the needle was exchanged over a wire (J wire/Terumo hydrophilic wire) for a 5-Fr sheath (Input TS Introducer Sheath, Medtronic). A 65-cm, 4/5-Fr guiding catheter (Cobra/headhunter, Cordis, Miami, FL, USA) was introduced over guidewire. On the basis of different probing techniques, the pull-type PRG can be divided into the direct retrograde and the antegrade fixation technique.^[5]

In most cases, the anatomy allowed for a simple direct retrograde access to the esophageal lumen with the guiding catheter. In such cases, a hydrophilic guidewire (0.035 in.; 180 cm, Terumo, Eschborn, Germany) with 4/5-Fr Cobra/headhunter guiding catheter combination was used to enter the esophagus from the stomach retrogradely until the catheter guidewire combination exited through the mouth^[5] or pulled out through mouth with the help of forceps, when guidewire reaches at the level of nasopharynx. Sometimes a combination of 18 G needle directing towards the gastro-esophageal junction and manipulation of the hydrophilic guide wire was successful to advance the guide wire into the esophagus. The hydrophilic guidewire was exchanged for super stiff guidewire (0.035 in.; 260 cm, Amplatz, Cook, Winston-Salem, USA) and short sheath for

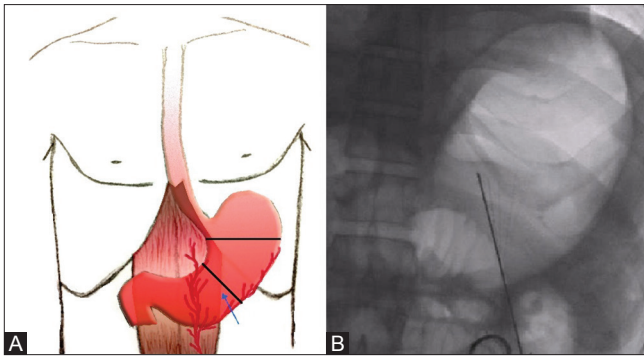


Figure 1 (A and B): (A and B) Site of puncture – Lower one-third of body of stomach equidistant from greater and lesser curvature lateral to rectus muscle to avoid injury to epigastric or gastroepiploic arteries

65 cm, 9-Fr long sheath (Super arrow flex sheath, Teleflex, Westmeath, Ireland) exiting through mouth. An extra-long super stiff Amplatz guidewire was folded and doubled in the midway. This was introduced through the 9-Fr long sheath in a retrograde fashion from stomach end to exit through tip of sheath in mouth end. After lubrication with a water-soluble lubricant, the blue wire of the feeding tube and folded end of guidewire were linked together by a square knot and whole assembly pulled out through the anterior abdominal wall under fluoroscopy guidance, until mushroom end was felt to abut the gastric wall. Instead of using stiff guidewire and 9-Fr long sheath combination, an extra-long hydrophilic wire folded in midway can be used through 9/10-Fr suction tubing for pulling the feeding tube. The feeding tube was cut at the marking of X, and after cleaning the stromal site with antiseptic swabsticks, the outer bolster was secured and fastened.

In cases with difficult anatomy where the glide wire could not be negotiated into the esophagus retrogradely, the glide wire was snared using a loop snare (Bard snare retrieval kit 20 mm) from the oral route [Figures 2 and 3], with the remaining steps being identical to the direct retrograde technique. This technique is slightly different from antegrade fixation technique described by Yang *et al.*

Percutaneous radiological push-type gastrostomy (Push-type-PRG)

In this technique, the gastrostomy tube is inserted directly by using the Seldinger technique into the stomach (without passing through the pharynx), after the gastric and abdominal wall have been securely fastened together (gastropexy). The stomach is distended with air and gastric puncture site similar to pull type. Gastropexy done by puncturing the stomach with 17G introducer needles preloaded with anchors (Cope gastrointestinal suture anchor set, Cook, Bloomington, IN, USA) [Figure 4]. After confirming intragastric position, the anchors were deployed by pushing the guidewire into the gastric lumen. The needle is withdrawn and the anchor pulled and fastened as the stomach snug against the anterior abdominal wall.

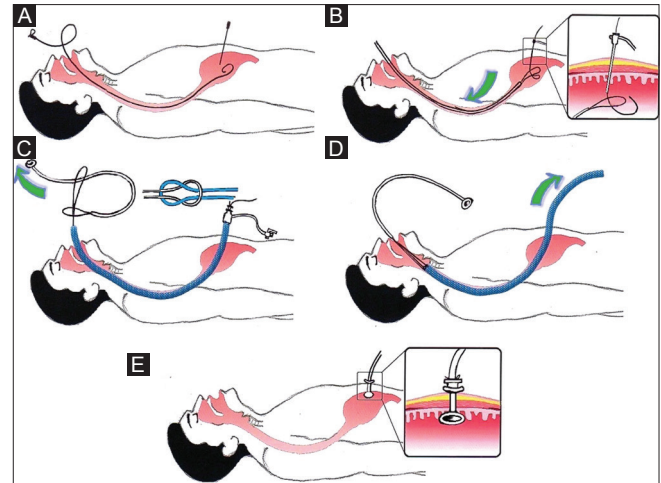


Figure 2 (A-E): Diagrammatic representation of pull technique. (A) Gastric puncture in air inflated stomach. (B) Glide wire snared out through mouth. (C) Through long sheath, folded stiff Amplatz wire introduced and linked with gastrostomy tube with square knot. (D) Whole assembly pulled out from stomach end until the mushroom end felt to abut inner gastric wall. (E) Tube fixed and fastened with external bolster

After fastening the sutures to approximate the gastric wall to abdominal wall, the gastric wall re-punctured close to anchors and after serial dilatation of the tract using dilators up to 18-Fr, an 18-Fr silicon balloon catheter (ENTUIT Gastrostomy BR, Wilson-Cook Medical, Winston-Salem, USA) was pushed into gastric lumen through peel away sheath, and latter was removed. The retention balloon was inflated with a small volume of saline, retracted to the anterior gastric wall and secured in place by a retention disc advanced to the overlying skin.

Both types of procedures were completed with a contrast injection in order to confirm correct intraluminal tube position and to exclude extravasation or other complications and are considered as technically successful.

Feeding was usually started after 48 h with a test bolus of oral rehydration solution to minimize the risk related to leakage of gastric content into the peritoneal cavity along the tract. If there were no signs of leakage or other complications, a formula diet was started. Instructions were given to nursing personal to flush the tube after each feed. Further imaging was only performed if clinically indicated, including suspicion of tube malfunctioning or dislodgement.

Follow-up

Patient records were examined in clinical workstation regarding procedure-related mortality rate and complications. The average follow-up period was 10 months. Complications of PRG tube placement are classified as minor or major according to the Society of Interventional Radiology classification system for complications by outcome.

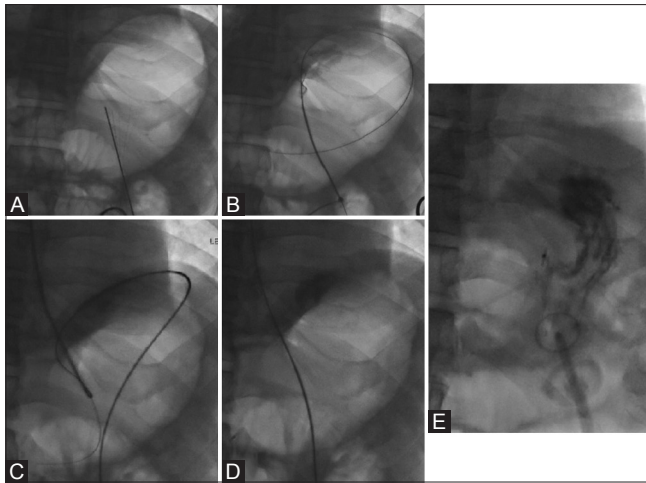


Figure 3 (A-E): Pull technique. (A) Gastric puncture. (B) Inset short sheath with guidewire. (C) Snaring of guidewire from oral route. (D) Guidewire placement across stomach, esophagus, and exiting through mouth. (E) Mushroom end of tube fixed and fastened after confirmation with contrast injection

Minor complications were defined as superficial stromal infection (aspiration), pneumonia, and minor hemorrhage requiring nominal therapy, including overnight admission for observation only.^[7] Simple tube displacement, tube occlusion, and leakage around the tube are also considered minor.^[7,8] Pneumoperitoneum was categorized as minor complication if it was nonsymptomatic or symptomatic but resolved without intervention.^[5]

Major complications were defined as any complication requiring surgery, minor or prolonged hospitalization, intensive care, hemorrhage requiring blood transfusion, tube dislodgement into the peritoneal cavity, or deep stromal infection may or may not necessitating tube removal,^[7,8] and symptomatic pneumoperitoneum requiring repeat intervention (i.e., drainage placement).^[5]

Statistical analysis

Descriptive summary statistics were presented as means (standard deviation) for continuous variables and as frequencies with percentages for categorical variables. All statistical analyses were performed using Statistical Package for the Social Sciences software.

Results

Between December 2009 and June 2017, a total of 29 patients were supplied with radiological gastrostomies (22 males, 7 females; age: mean \pm SD, 55.8 \pm 14.9 years; range: 16–83 years). Of the 29 patients, 27 (93%) were served with the fluoroscopy-guided pull-type technique and 2 patients (7%) with push technique.

Patient data, underlying diseases, and indications for gastrostomy are summarized in Table 2. Myasthenia

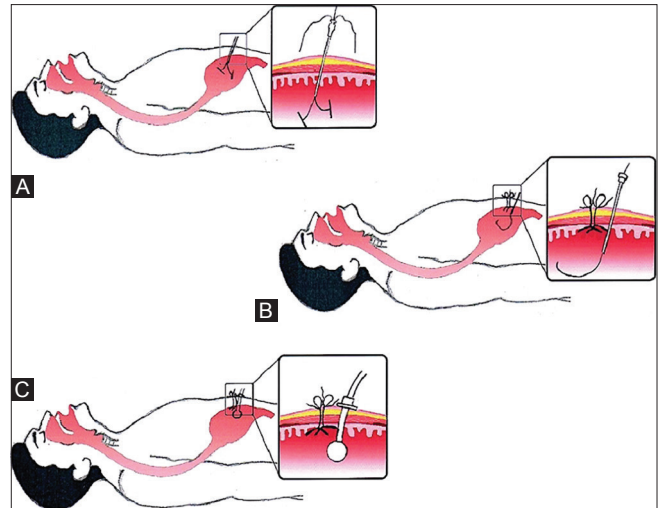


Figure 4 (A-C): Diagrammatic representation of push technique. (A) Gastric anchors inserted into stomach for gastropexy. (B) Stomach re-punctured to introduce guidewire. (C) After serial dilatation of tract, balloon catheter pushed through peel away sheath and fastened to stomach wall

gravis 11 patients (39%) and motor system disease 9 patients (31%) are the two common indications. Rarely in one post cordectomy patient of bilateral abductor palsy, PRG was done to initiate swallowing exercise [Figure 5].

All intended pull-type and push-type gastrostomies were successfully completed by the techniques described here. In pull-type-PRG patients, four types of minor complications occurred among 7 patients (24%). Two cases with superficial skin infections was treated conservatively. One patient developed tube block within 10 days and was relieved by forceful saline flushing of tube. One patient developed tube leakage and other had deformed tube (after 1 year); both were managed by replacing and upgrading the tube from 24 to 26-Fr [Figure 6].

In push-type-PRG, both patients developed minor complications (2/2). One patient showed tube dislodgement due to inadvertent deflation of balloon. It was corrected by tube re-positioning and re-inflation of balloon under fluoro guidance using guidewire. Another patient developed pneumoperitoneum, which was managed conservatively [Figure 7]. Three patients (10.3%) had developed major complications.

In one patient (pull-type), the feeding tube slipped out during the first attempt of placement, subsequently the stomach was re-punctured and the tube was placed successfully in second attempt in the same sitting. The patient developed massive pneumoperitoneum with features of mild peritonism due to gastric perforation [Figure 7]. The patient managed conservatively with antibiotics and feeding started on seventh postprocedure day.

Table 2: Percutaneous Radiological Gastrostomy (PRG)

No of patients	29
Age	
Range	16-83y
Average ± Std	55.8 ± 14.9
Male	22(76%)
Female	7(24%)
Diagnosis and indication	
Myasthenia gravis	11(39%)
Motor system disease	9(31%)
Bulbar onset ALS	3(10%)
Inflammatory myopathy	2(7%)
HIE post MI	1(3%)
Medullary infarct	1(3%)
Bil Abductor palsy post cordectomy	1(3%)
Carcinoma base of tongue	1(3%)
Interventional technique	
Pull type	27(93%)
Push type	2(7%)
Intraprocedural problem	
Slippage of feeding tube	1(3%)
Complications	
Minor	7(24%)
Superficial infection	2(7%)
Tube block/displacement	2(7%)
Leakage from tube	1(3%)
Deformed PEG tube	1(3%)
Pnemoperitium	1(3%)
Major	3(10%)
Abscess	2(7%)
Gastric perforation with features of mild peritonism	1(3%)
Mortality	
Procedure related	Nil
Non procedural related	3(10%)

Two patients (pull-type) suffered from moderate local pain at the puncture sites with fever. Both showed focal abscess around the tubes with volume approximately measuring <4 cc [Figure 7]. Both were treated conservatively with antibiotics. There was no complication related to hemorrhage or peri-interventional mortality.

Three patients died on postprocedure follow-up, one on third day due to type 2 respiratory failure and other on fourth day, due to sepsis and other medical problems, and third patient died after few months due to sudden cardiac arrest and respiratory failure.

Discussion

For fluoroscopy-guided gastrostomy, numerous gastrostomy devices and techniques have been described in the literature. The initially described Foley catheters have been demonstrated to have increased morbidity rate due to tube leakage, breakage, migration, proximal small bowel

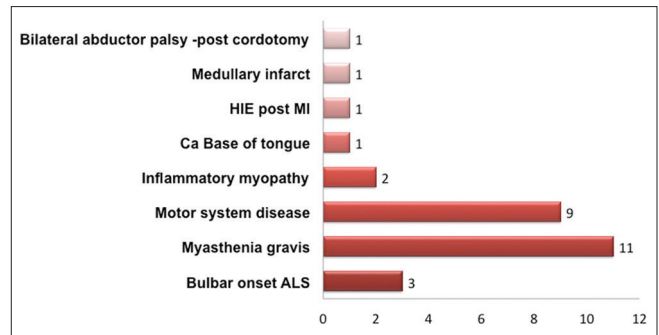


Figure 5: Indications for PRG in our study group

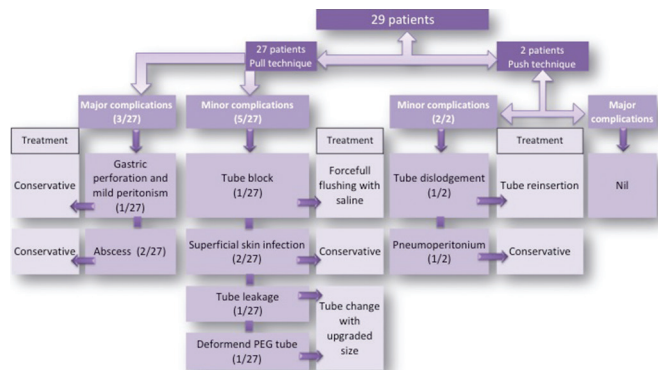


Figure 6: Flowchart of postprocedural complications and management in our study group

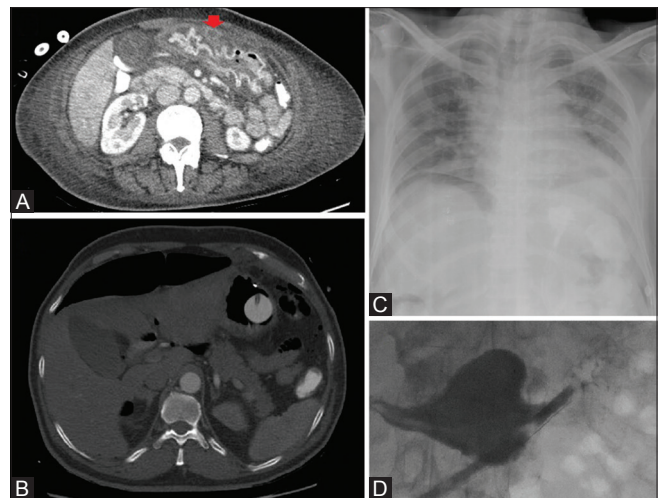


Figure 7 (A-D): Complications. (A) Peristomal abscess after pull technique. (B) Pneumoperitoneum after push technique. (C) Massive pneumoperitoneum after pull technique. (D) Dislodged tube due to inadvertent deflation of balloon in push technique

obstruction, and gastric wall penetration.^[9] Gastrostomy buttons (balloon and mushroom types) consist of a low-profile catheter with a feeding hub, designed for mature tracts; however, *de novo* placement of balloon-retained button-type gastrostomies has been performed with a 98% success rate.^[10] In Cope loop retention device, T-fasteners were used for gastropexy to facilitate introduction of gastrostomy catheters.

The fluoroscopy-guided percutaneous pull-through gastrostomy described in this study combines the advantages of both the ease, speediness and the high technical success rate with the beneficial design of the gastrostomy tubes that were traditionally used with endoscopic assistance. Some authors describe this technique as per-oral image-guided gastrostomy (PIG) hybrid technique.^[11] It uses larger bore catheter (24-Fr and above) and does not require gastropepy.^[12] It combines advantages of both traditional methods with a higher success and lower re-intervention rate^[13] with reduced infectious risk complications related to T-fasteners.^[14]

Pull-type PRG are more secure than the conventional push-type tubes, as the pull-type retention device cannot be deflated, unlocked, or injected with the feeding bolus^[12] and is preferred for patients with nonobstructive, neuromuscular esophageal dysmotility disorders.

For inflation of stomach, some authors recommend CO₂ as it is more readily absorbed and less uncomfortable for the patient.^[15] However, most of the recent studies for PRG are not using CO₂, as it is tedious and time-consuming.

Several techniques have been described for guidewire placement by transabdominal access into the stomach and across esophagus through the mouth. The hydrophilic guidewire (glide wire) can be captured by different types of snares (readymade or artificial using guidewire) through oral route or through transabdominal route. In our institution, we prefer pulling the glide wire inserted through stomach by transabdominal route and snared out through oral cavity. Alternatively, the esophagus can also be cannulated with glide wire retrogradely by directing the puncture needle itself toward the lower gastroesophageal junction.

However, there are some drawbacks to the pull-type technique. Wound infection is more frequently encountered using pull type than push type owing to contamination of wound with oropharyngeal bacteria contamination of the tube as it traverses through the mouth and pharynx during the procedure.^[16] To minimize this, prophylactic antibiotics can be given on the day of procedure and antiseptic mouthwash a day before and on the day of procedure. Statistically significant reduction in the incidence of peristomal infection has been noted with prophylactic antibiotics.^[17] In our study group, two patients developed peristomal abscess and both were managed conservatively with antibiotics. However, sometimes it may necessitate percutaneous drainage with or without removal of gastrostomy tube.^[7]

Push-type technique, which some authors describe as radiologically inserted gastrostomy technique (RIG),^[13] is preferred for patients with head and neck or upper gastrointestinal malignancies causing proximal esophageal obstruction. As it obviates the need for catheter passage

from oral cavity to stomach, it also reduces the possibility of implant metastasis.^[18] Yoshitaka *et al.*^[19] showed that percutaneous radiologic gastrostomy is feasible even for patients in whom a nasogastric tube cannot be inserted.

In push-type gastrostomy, instead of double puncture, a single puncture of the stomach can be done, creating a single tract for both T-fasteners (suture anchors) and guidewire over which dilatation and tube insertion can be performed. Postprocedure, the T-fasteners can be released, as gastrostomy balloon tube was retracted and fixed externally, which affix the gastric wall to the abdominal wall. It minimizes the procedure time and infectious risk related to T-fasteners.^[8] Inadvertent deflation of balloon is a frequent complication, in such situation pig-tail retained (Cope loop) can be used.

In our series, one patient with amyotrophic lateral sclerosis died on third day due to type 2 respiratory failure. A retrospective analysis from brain-derived neurotrophic factor and ciliary neurotrophic factor trials showed that morbidity with PEG increases with worsening respiratory function, and it also recommended that the procedure should be undertaken before forced vital capacity (FVC) falls below 50% predicted;^[20] however, subsequent studies have shown conflicting results.^[21,22] Chavada *et al.*^[7] also concluded that FVC did not predict survival of postgastrostomy procedure. PEG insertion may be regarded as safe even in patients with low FVC and can be offered even for patients with respiratory dysfunction.^[23]

The results presented in this study describe our experience with pull and push techniques. As most referrals for gastric feeding tube insertion that come to our department are for patients with neurological or neuromuscular disorders, pull technique might serve as a simpler alternative to the endoscopic method with lesser complications.

Our data analysis demonstrated high technical success rate and low peri-interventional complication. However, limitations of our study include retrospective analysis, small sample size, unequal distribution of cases, limited experience with push technique, adequate data not available for its technical feasibility, and complications related to cases with upper GI, head and neck malignancies.

Conclusion

PRG is effective, safe, and easy to perform, with low morbidity and mortality rates and high technical success rate in selected patients. The limitation of smaller tube size leading to higher rates of tube blockage can be overcome with the pull-type PRG (PIG) technique. Our study describes a new technique for pull-type gastrostomy.

Financial support and sponsorship

Nil.

Conflicts of interest

There are no conflicts of interest.

References

- Bannerman E, Pendlebury J, Phillips F, Ghosh S. A cross-sectional and longitudinal study of health-related quality of life after percutaneous gastrostomy. *Eur J Gastroenterol Hepatol* 2000;12:1101-9.
- Wollman B, D'Agostino HB, Walus-Wigle JR, Easter DW, Beale A. Radiologic, endoscopic, and surgical gastrostomy: An institutional evaluation and meta-analysis of the literature. *Radiology* 1995;197:699-704.
- Ozmen MN, Akhan O. Percutaneous radiologic gastrostomy. *Eur J Radiol* 2002;43:186-95.
- Sutcliffe J, Wigham A, Mceniff N, Dvorak P, Crocetti L, Uberoi R. CIRSE standards of practice guidelines on gastrostomy. *CardiovascInterventRadiol* 2016;39:973-87.
- Yang Y, Schneider J, Düber C, Pitton MB. Comparison of fluoroscopy-guided Pull-type percutaneous radiological gastrostomy (pull-type-PRG) with conventional percutaneous radiological gastrostomy (push-type-PRG): Clinical results in 253 patients. *Eur Radiol* 2011;21:2354-61.
- Shin JH, Park AW. Updates on percutaneous radiologic gastrostomy/gastrojejunostomy and jejunostomy. *Gut Liver* 2010;4:S25-31.
- Covarrubias DA, O'Connor OJ, McDermott S, Arellano RS. Radiologic percutaneous gastrostomy: Review of potential complications and approach to managing the unexpected outcome. *AJR Am J Roentgenol* 2013;200:921-31.
- Lorentzen T, Nolsøe CP, Adamsen S. Percutaneous radiologic gastrostomy with a simplified gastropexy technique under ultrasonographic and fluoroscopic guidance: Experience in 154 patients. *Acta Radiologica* 2007;48:13-9.
- Hicks ME, Surratt RS, Picus D, Marx MV, Lang EV. Fluoroscopically guided percutaneous gastrostomy and gastroenterostomy: Analysis of 158 consecutive cases. *AJR Am J Roentgenol* 1990;154:725-8.
- Given MF, Lyon SM, Lee MJ. The role of the interventional radiologist in enteral alimentation. *EurRadiol* 2004;14:38-47.
- Chavada G, El-Nayal A, Lee F, Webber SJ, Mcalindon M, Walsh T, *et al.* Evaluation of two different methods for per-oral gastrostomy tube placement in patients with motor neuron disease (MND): PIG versus PEG procedures (2010). *Amyotroph Lateral Scler* 2010;11:531-6.
- Given MF, Hanson JJ, Lee MJ. Interventional radiology techniques for provision of enteral feeding. *CardiovascInterventRadiol* 2005;28:692-703.
- Laasch HU, Wilbraham L, Bullen K, Marriott A, Lawrance JA, Johnson RJ, *et al.* Gastrostomy insertion: Comparing the options—PEG, RIG or PIG? *ClinRadiol* 2003;58:398-405.
- Kavin H, Messersmith R. Radiologic percutaneous gastrostomy and gastrojejunostomy with T-fastener gastropexy: Aspects of importance to the endoscopist. *Am J Gastroenterol* 2006;101:2155-9.
- Kim SY, Chung JW, Park DK, Kwon KA, Kim KO, Kim YJ, *et al.* Comparison of carbon dioxide and air insufflation during consecutive EGD and colonoscopy in moderate-sedation patients: A prospective double-blind randomized controlled trial. *GastrointestEndosc* 2017;85:1255-62.
- Tsukuda T, Fujita T, Ito K, Yamashita T, Matsunaga N. Percutaneous radiologic gastrostomy using push-type gastrostomy tubes with CT and fluoroscopic guidance. *AJR Am J Roentgenol* 2006;186:574-6.
- Lipp A, Lusardi G. A systematic review of prophylactic antimicrobials in PEG placement. *J ClinNurs* 2009;18:938-48.
- Mincheff TV. Metastatic spread to a percutaneous gastrostomy site from head and neck cancer: Case report and literature review. *JLS* 2005;9:466-71.
- Inaba Y, Yamaura H, Sato Y, Kashima M, Kato M, Inoue D, *et al.* Percutaneous radiologic gastrostomy in patients with malignant pharyngoesophageal obstruction. *Jpn J ClinOncol* 2013;43:713-8.
- Kasarskis EJ, Scarlata D, Hill R, Fuller C, Stambler N, Cedarbaum JM. A retrospective study of percutaneous endoscopic gastrostomy in ALS patients during the BDNF and CNTF trials. *J NeurolSci* 1999;169:118-25.
- Gregory S, Siderowf A, Golaszewski AL, McCluskey L. Gastrostomy insertion in ALS patients with low vital capacity: Respiratory support and survival. *Neurology* 2002;58:485-7.
- Thornton FJ, Fotheringham T, Alexander M, Hardiman O, McGrath FP, Lee MJ. Amyotrophic lateral sclerosis: Enteral nutrition provision – endoscopic or radiologic gastrostomy? *Radiology* 2002;224:713-7.
- Sarfaty M, Nefussy B, Gross D, Shapira Y, Vaisman N, Drory VE. Outcome of percutaneous endoscopic gastrostomy insertion in patients with amyotrophic lateral sclerosis in relation to respiratory dysfunction. *Amyotroph Lateral SclerFrontotemporalDegener* 2013;14:528-32.