

Prostatic melanosis

Hasan Gucer, Pelin Bagci

Department of Pathology, Recep Tayyip Erdogan University, School of Medicine, Rize, Turkey

Abstract

Prostatic melanosis is a very rare, benign lesion characterized by the presence of melanin in the epithelium of the prostate gland and stromal dendritic cells, requiring no additional treatment. It constitutes the melanocytic lesions of the prostate together with blue nevus and malignant melanoma. We present a case with prostatic melanosis because it is rarely seen and its distinction from malignant melanoma is clinicopathologically very important.

Key Words: Melanin, melanosis, prostate

Address for correspondence:

Dr. Hasan Gucer, Department of Pathology, Recep Tayyip Erdogan University, School of Medicine, 53100, Rize, Turkey.
E-mail: hasangucer@gmail.com

Received: 28.01.2013, **Accepted:** 28.04.2013

INTRODUCTION

The presence of melanin pigment in the prostate gland is a very rare histopathological finding. Melanosis, blue nevus, and malignant melanoma are lesions seen in the prostatic tissue, containing melanin pigment.^[1]

Melanosis is described as the presence of the melanin pigment in dendritic cells in the stroma and in the epithelium of the prostate gland. A total of 20 prostatic melanosis cases have so far been reported in the English literature.^[1]

CASE REPORT

A 60-year-old male patient admitted to the Urology Clinic with complaints of prostatism of 5 years duration. His physical examination revealed an enlarged prostate gland. His serum total prostate-specific antigen (PSA) level was measured 18 ng/ml. Patient was treated by transurethral resection of the prostate (TUR-P) based on a preliminary diagnosis of benign prostate hypertrophy.

TUR-P material consisted of dirty yellow irregular pieces of tissue with elastic consistency, weighting 13 g with a macroscopic volume of 40 cc. No black or dark-brown areas were observed.

Histopathologically, the presence of fusiform and round cells loaded with brown-black pigment in the prostatic stroma and similar pigment in the neighboring epithelial gland were prominent [Figures 1 and 2]. No cytological atypia, mitosis, or necrosis was seen. Histochemically, the pigment stained positively with Masson Fontana [Figure 3]. No reactions were observed with Luxol fast blue, Ehrlich Ziehl-Neelsen, and Prussian blue. While, immunohistochemically, pigment-loaded cells stained positively for S-100 [Figure 4], no positivity revealed for HMB-45 and Melan-A. The entire material was examined due to the high PSA level and presence of pigments, and no malignancies were found.

DISCUSSION

About 30 cases with blue nevi and 20 cases with melanosis have been reported since the first report of melanin pigment, named "blue nevus," in the prostate gland.^[1,2]

Melanocytic lesions of the prostate are classified under three types: Melanosis, blue nevus, and primary/metastatic malignant melanoma. While the presence of melanocytic cells in the prostatic stroma is described as blue nevus, the term melanosis is used when the melanin pigment is seen in the glandular cells and the stroma.^[1]

Access this article online	
Quick Response Code:	Website: www.urologyannals.com
	DOI: 10.4103/0974-7796.141010

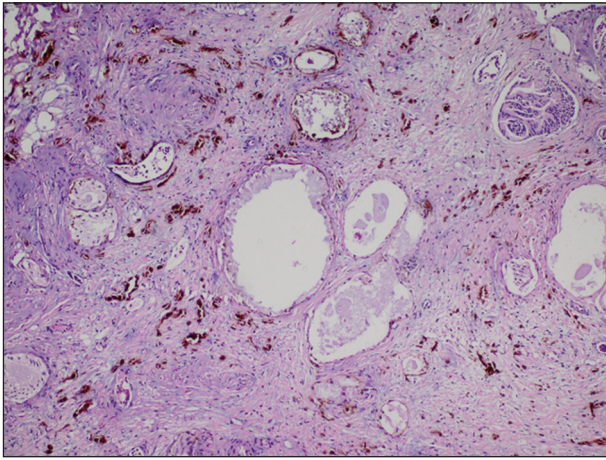


Figure 1: Brown-black pigment in the dendritic stromal cells and glandular epithelial cells (H and E, $\times 40$)

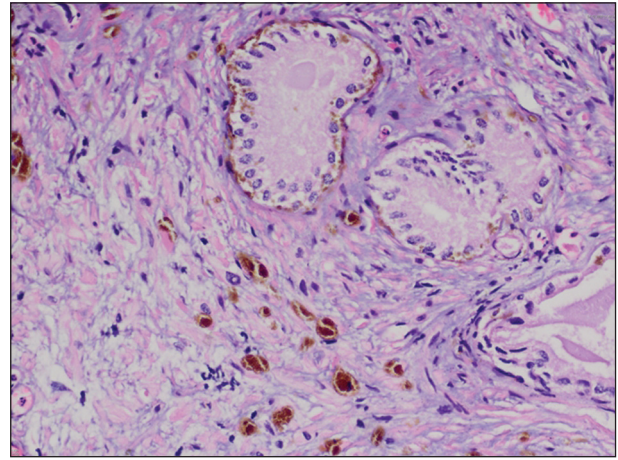


Figure 2: Brown-black pigment in the dendritic stromal cells and glandular epithelial cells (H and E, $\times 100$)

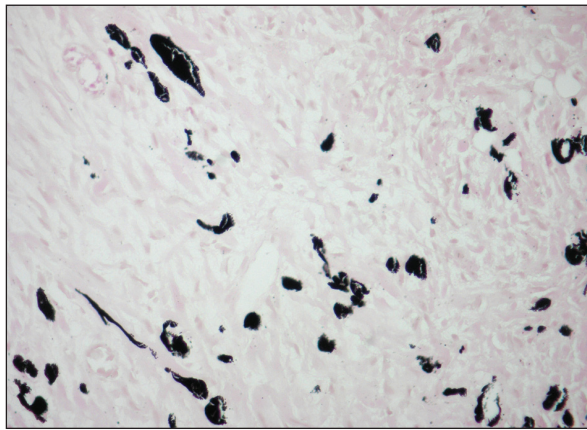


Figure 3: Masson Fontana reaction highlights melanin (MF, $\times 200$)

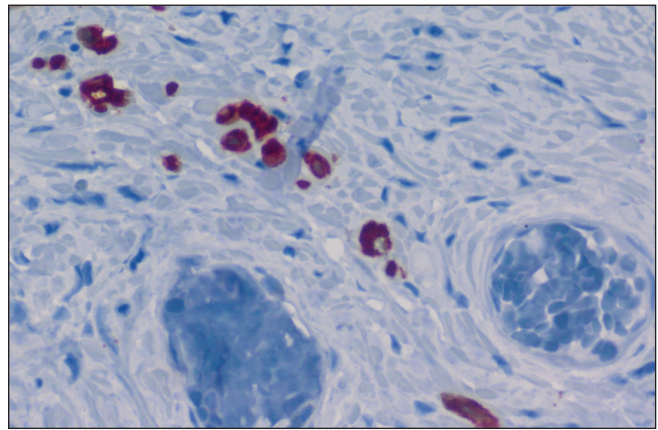


Figure 4: S-100 protein positivity in the stromal dendritic cells (S-100, $\times 400$)

Melanosis is an incidentally discovered finding, typically in elderly patients who were operated due to complaints associated with prostate hyperplasia. It can be detected in needle biopsy, TUR-P and prostatectomy materials and during autopsy. It is more common in the Caucasian race. They may very rarely present with prostatic adenocarcinoma. However, they do not cause any melanocytic or non-melanocytic malignancies.^[1,3,4]

During macroscopic examination, black-brown areas may be observed in the prostatic tissue.^[1] Histopathologically, dendritic cells loaded with brown-black pigment are observed in the prostatic stroma. In cases with melanosis, melanin pigment is present in the epithelial prostatic gland neighboring dendritic cells, unlike the blue nevus. The pigment stains black with Masson Fontana. Immunohistochemically, the stromal dendritic cells stain positively for S-100 protein, but negatively for HMB-45.^[1-5]

According to the commonly-accepted theory, the origin of the melanocytic lesions of prostate is the neural crest-derived

melanocytes, which are arrested in the prostate during their migration in the body. And according to another theory, these cells differentiate from Schwann cells.^[1] We consider that the intraepithelial melanin pigment observed in the melanosis was gained through secondary uptake from nearby dendritic cells. Named differently according to the localization of melanin pigment, blue nevus and melanosis can be considered as different stages of the same lesion. Blue nevus can even be described as the previous stage in the development of melanosis.

Among the most important differential diagnosis of melanosis and blue nevus is the primary/metastatic malignant melanoma because of its aggressive behavior.^[1,2,5] The primary melanoma of prostate is a rare tumor; it rapidly metastasizes and has a very worse prognosis.^[6] Observed due to the presence of a large number of pigments, the black color change can be noticed during macroscopic examination. Hypercellularity, cellular atypia, an increased number of mitosis, and necrosis are findings in favor of malignant melanoma. Positive HMB-

45 and Melan-A staining are also helpful to the diagnosis in favor of melanoma.^[1,2,5]

Melanosis can easily be differentiated from non-melanocytic pigmented lesions of the prostate containing hemosiderin and lipofuscin by morphological, histochemical, and immunohistochemical methods. Lipofuscin is a yellow-brown pigment with fine granular structure staining with Luxol fast blue, Sudan black B, and Ehrlich Ziehl-Neelsen. Hemosiderin is a golden pigment with a coarse granular structure accumulating in the macrophages and reacting with Prussian blue. And the melanin pigment stains positively with Masson Fontana.^[1,2,7]

As a result, known to be the benign melanocytic lesions of prostate, melanosis, and blue nevus are very rarely seen and they have to be differentially diagnosed from malignant melanoma when they are detected.

REFERENCES

1. Paner GP, Aron M, Hansel DE, Amin MB. Non-epithelial neoplasms of the prostate. *Histopathology* 2012;60:166-86.
2. Dailey VL, Hameed O. Blue nevus of the prostate. *Arch Pathol Lab Med* 2011;135:799-802.
3. Klock C, Gomes R, João M, Netto G. Prostate melanosis associated with acinar adenocarcinoma. *Int J Surg Pathol* 2010;18:379-80.
4. Furusato M, Matsumoto I, Kato H, Takahashi H, Kawashima Y, Wada T, *et al.* Prostatic carcinoma with melanosis. *Prostate* 1989;15:65-9.
5. Anderco D, Lazár E, Tában S, Miclea F, Dema A. Prostatic blue nevus. *Rom J Morphol Embryol* 2010;51:555-7.
6. Doublali M, Chouaib A, Khallouk A, Tazi MF, El Fassi MJ, Farih MH, *et al.* Primary malignant melanoma of prostate. *Urol Ann* 2010;2:76-7.
7. Brennick JB, O'Connell JX, Dickersin GR, Pilch BZ, Young RH. Lipofuscin pigmentation (so-called "melanosis") of the prostate. *Am J Surg Pathol* 1994;18:446-54.

How to cite this article: Gucer H, Bagci P. Prostatic melanosis. *Urol Ann* 2014;6:384-6.

Source of Support: Nil, **Conflict of Interest:** None.

Staying in touch with the journal

1) Table of Contents (TOC) email alert

Receive an email alert containing the TOC when a new complete issue of the journal is made available online. To register for TOC alerts go to www.urologyannals.com/signup.asp.

2) RSS feeds

Really Simple Syndication (RSS) helps you to get alerts on new publication right on your desktop without going to the journal's website. You need a software (e.g. RSSReader, Feed Demon, FeedReader, My Yahoo!, NewsGator and NewzCrawler) to get advantage of this tool. RSS feeds can also be read through FireFox or Microsoft Outlook 2007. Once any of these small (and mostly free) software is installed, add www.urologyannals.com/rssfeed.asp as one of the feeds.