

Alternate Management of an Anterior Maxillary Dentigerous Cyst in a Paediatric Patient

Lida Philip, Joel D'Silva, Elvita Martis, Selva Malathi

Department of Oral and Maxillofacial Surgery, AJ Dental College and Hospital, Mangalore, Karnataka, India

Abstract

The purpose of this article is to show alternate management of an anterior maxillary dentigerous cyst in a paediatric patient. An 8-year-old male child reported to the Department of Oral and Maxillofacial surgery with the chief complaint of swelling in the upper left side of the face for 2 months. Based on the clinical and radiological findings of cystic cavity along with impacted tooth, lesion was diagnosed as dentigerous cyst and surgical enucleation was planned under general anaesthesia. Dentigerous cysts mostly occur in the mandible and are prevalent between the second to fourth decades of life. The incidence of this cyst in children is less. We present here a case report of a paediatric patient with a rare occurrence of a large cyst in the maxillary anterior region, and the treatment outcome by surgical enucleation and preservation of the permanent tooth bud are discussed. The line of treatment for dentigerous cyst is enucleation and extraction of involved tooth. We recommend the alternative treatment option, which involves enucleation of cyst, and consider the conservation of the affected tooth bud in the view of making its eruption viable in future.

Keywords: Children, dentigerous cyst, enucleation, erupting tooth

INTRODUCTION

Dentigerous cyst is a developmental odontogenic cyst of the oral cavity that is usually associated with an unerupted, impacted or embedded tooth. Formation of this cyst has been attributed to the accumulation of fluid causing separation of dental follicle from around the crown of an unerupted tooth. Thus, this cyst is also known as follicular cyst. These cysts are usually prevalent between the second and fourth decades of life because they mostly occur in association with the secondary dentition. It is most commonly associated with an impacted mandibular third molar, followed by the maxillary canine and maxillary third molar.^[1] Treatment recommended for a dentigerous cyst is surgery and usually consists of enucleation and extraction of the teeth engulfed by it.^[2] In this case report, we present a rare occurrence of a dentigerous cyst in the anterior maxillary region in a paediatric patient accounting for an incidence rate of 9.1%. The uniqueness of this case stems from its novel line of treatment in removing the entire cystic pathology while simultaneously preserving the permanent tooth bud.

CASE REPORT

An 8-year-old male patient reported to the Department of Oral and Maxillofacial Surgery, with the chief complaint of swelling in the upper left side of the face for 2 months. Initially, the swelling was pea sized and gradually increased to its current size. On extraoral examination, the facial swelling was oval shaped measuring approximately 3 cm × 3 cm over the upper left side region [Figure 1a and b]. On palpation, the swelling was well defined, firm to hard consistency, non-tender with no local rise in temperature, non-pulsatile and non-fluctuant. On intraoral examination, obliteration of the labial vestibule and palatal mucosa was seen in relation to deciduous upper left canine.

Computed tomography (CT) revealed a unilocular radiolucency with well-defined borders in close proximity to left maxillary sinus along with radiopaque tooth structures suggestive of

Address for correspondence: Dr. Lida Philip,
Department of Oral and Maxillofacial Surgery, AJ Dental College and
Hospital, Mangalore, Karnataka, India.
E-mail: lidmijg87@gmail.com

Received: 06-04-2021 Revised: 13-08-2021 Accepted: 28-10-2021 Available Online: 23-06-2022

Access this article online

Quick Response Code:



Website:
www.afripaedurg.org

DOI:
10.4103/ajps.AJPS_51_21

This is an open access journal, and articles are distributed under the terms of the Creative Commons Attribution-NonCommercial-ShareAlike 4.0 License, which allows others to remix, tweak, and build upon the work non-commercially, as long as appropriate credit is given and the new creations are licensed under the identical terms.

For reprints contact: WKHLRPMedknow_reprints@wolterskluwer.com

How to cite this article: Philip L, D'Silva J, Martis E, Malathi S. Alternate management of an anterior maxillary dentigerous cyst in a paediatric patient. Afr J Paediatr Surg 2022;19:186-8.

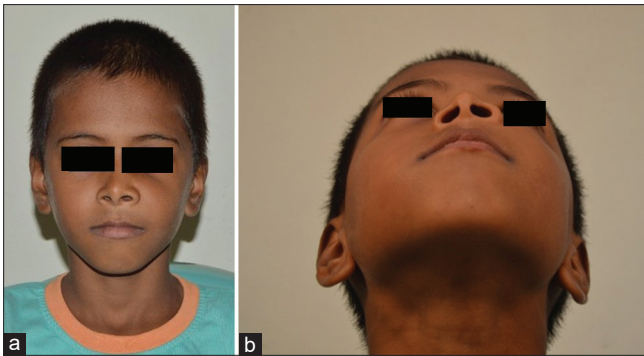

Figure 1: (a) Pre-operative clinical photographs showing facial swelling on the left side as seen in front view (b) pre-operative clinical photographs showing facial swelling on the left side as seen in worm's view

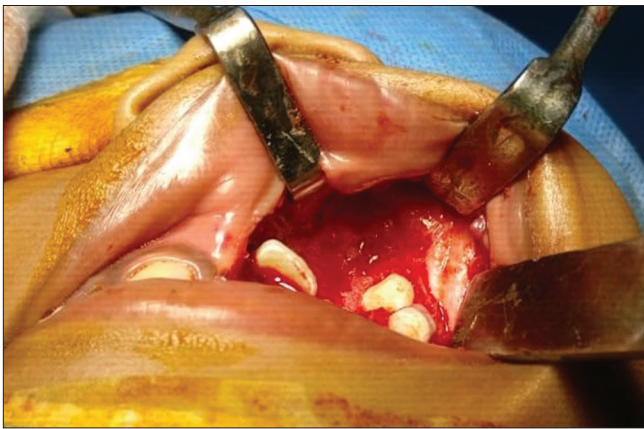


Figure 3: Intraoperative picture showing vestibular incision to expose cystic lesion

a cystic lesion with unerupted tooth [Figure 2a and b]. On aspiration, the fluid obtained was reported as negative for malignancy.

Based on the clinical and radiological findings, the lesion was diagnosed as dentigerous cyst of the maxilla in association with unerupted tooth and surgical enucleation was planned under general anaesthesia.

Following aseptic measures, an upper vestibular incision was given and tissue dissection done to expose the maxilla [Figure 3]. Careful stripping of cystic wall was done preserving the permanent tooth buds. Permanent tooth buds canine, pre-molars were preserved. Deciduous canine was left *in situ*.

The histological examination of the specimen showed a cystic lining along with a capsular tissue. The cystic lining consisted of 2–3 layers of cuboidal cells. Focal areas of the lining were seen proliferating into the underlying capsule associated with chronic inflammation along with odontogenic rests. The capsule showed haemorrhagic areas with chronic inflammation. All these were suggestive of an infected dentigerous cyst.

Healing was uneventful. The patient was reviewed up 3-month post-surgery with no recurrence of the lesion [Figure 4a and b].

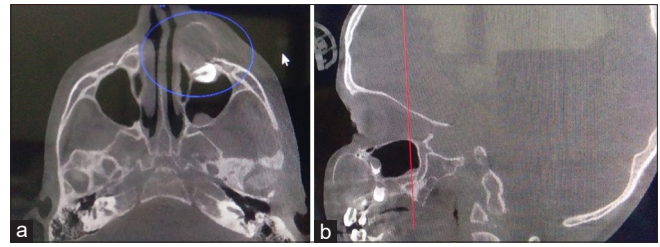


Figure 2: (a) Axial section of computed tomography (CT) scan of the face reveals well-defined unilocular radiolucency in close proximity to maxillary sinus along with impacted tooth (b) sagittal section of CT scan of the face reveals well-defined unilocular radiolucency in close proximity to maxillary sinus along with impacted tooth

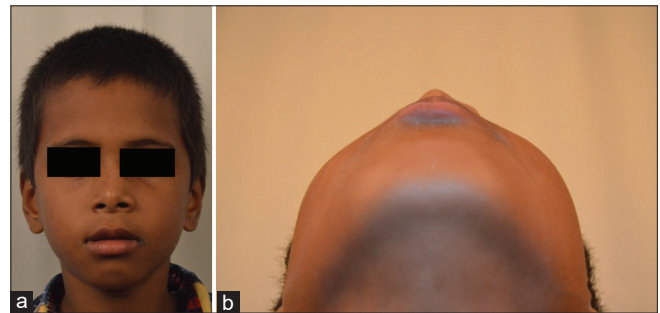


Figure 4: (a) Post-operative clinical photograph at 6 months reveals resolution of swelling as seen in front view (b) post-operative clinical photograph at 6 months reveals resolution of swelling as seen in worm's view

However, 4th-month post-surgery showed signs of ectopic eruption of the permanent tooth in relation to the left central incisor.

DISCUSSION

The pathogenesis of the dentigerous cyst is controversial. It has been suggested that the pressure exerted by an erupting tooth on the follicle may obstruct venous flow inducing accumulation of exudate between the reduced enamel epithelium and the tooth crown.^[3] The formation of developmental cysts in a growing child may be associated with profound developmental process which includes the growth of the maxillofacial skeleton and development of the primary and permanent dentition.^[4]

Dentigerous cysts have a male predilection at a ratio of 1.8:1^[5] and mostly occurring in the children and adolescents. The frequency of occurrence of dentigerous cyst was approximately 4% noted only from 8 years of age and above.^[6] The site of occurrence is more common in mandible than maxilla. In this case report, the male patient was below the age of 8 years and the cyst was in the anterior maxillary region which is rare and unique.

Cysts are asymptomatic until they attain considerable size or secondarily infected and present with symptoms such as swelling and pain. Thus, early detection and removal of the cysts are important to reduce morbidity. This can be done by

performing radiographic examinations in cases of un-erupted teeth. Panoramic radiograph may be a good option for this examination. However, in cases of extensive lesion, CT imaging becomes necessary.

From a clinical standpoint, the differential diagnosis of a dentigerous cyst should include other cystic lesions such as the odontogenic keratocyst, primordial cyst and odontogenic tumours such as ameloblastoma, ameloblastic fibroma and adenomatoid odontogenic tumour.^[7]

Dentigerous cysts usually appear as well-defined unilocular radiolucent areas involving the crown of unerupted teeth. While a normal follicular space is 3–4 mm, a dentigerous cyst can be suspected when the space is more than 5 mm.^[8] In our case, there was a large well-defined radiolucency in the anterior maxillary region along with radio-opaque structure suggestive of unerupted teeth.

The management of a dentigerous cyst varies depending upon the size, location, involvement of the surrounding structures and associated teeth. The treatment of choice for dentigerous cyst is enucleation along with extraction of the impacted teeth.^[2] The other surgical option in case of larger cysts or in paediatric patients is marsupialization which decreases morbidity.

Previous studies stated that thorough enucleation should never be compromised.^[9] Thus, extraction of the involved tooth is advocated during enucleation to decrease the chances of recurrence. In the paediatric age group, several studies concluded that marsupialization is a preferred method to preserve the tooth, thereby maintaining the function and aesthetics.^[10] The potential for eruption of the involved tooth bud occurs when root apex is open and root formation is incomplete.^[11]

In our case, we performed a complete enucleation of the cyst and simultaneously leaving the involved permanent tooth bud intact inside that eventually erupted ectopically in oral cavity. Orthodontic tooth movement will manage further correction of ectopic tooth in dental arch.

To conclude, early diagnosis and treatment of lesion in children are of utmost importance to obtain the best possible outcome.

Although the treatment should be as conservative as possible to avoid excessive morbidity, it is always best to be aggressive enough to prevent recurrence.

Declaration of patient consent

The authors certify that they have obtained all appropriate patient consent forms. In the form, the patient has given his consent for his images and other clinical information to be reported in the journal. The patient understands that name and initials will not be published and due efforts will be made to conceal identity, but anonymity cannot be guaranteed.

Financial support and sponsorship

Nil.

Conflicts of interest

There are no conflicts of interest.

REFERENCES

1. Shafer W, Hine M, Levy B, Rajendran R, Sivapathasundharam B. Cyst and tumors of odontogenic origin. Shafer's Textbook of Oral Pathology. 7th edition; Elsevier publications 2012. p. 259-301.
2. Dhupar A, Yadav S, Dhupar V, Mittal HC, Malik S, Rana P. Bi-maxillary dentigerous cyst in a non-syndromic child – Review of literature with a case presentation. *J Stomatol Oral Maxillofac Surg* 2017;118:45-8.
3. Harris M, Toller P. The pathogenesis of dental cysts. *Br Med Bull* 1975;31:159-63.
4. Bodner L. Cystic lesions of the jaws in children. *Int J Pediatr Otorhinolaryngol* 2002;62:25-9.
5. Shear M, Speigh P. Dentigerous cyst. In: *Cysts of Oral and Maxillofacial Region*. 4th edition: Blackwell Munksgaard; 2006. p 59-75.
6. Abdullah BH, Qader OA, Mussedi OS. Retrospective analysis of 1286 oral and maxillofacial biopsied lesions of Iraqi children over a 30 years period. *Pediatr Dent J* 2016;26:16-20.
7. Wood N, Goaz P. Pericoronal radiolucencies. In: *Differential Diagnosis of Oral and Maxillofacial Lesions*. 5th edition: Mosby; 1997. p. 250-66.
8. Batra P, Roychoudhury A, Balakrishnan P, Parkash H. Bilateral dentigerous cyst associated with polymorphism in chromosome 1qh+. *J Clin Pediatr Dent* 2004;28:177-81.
9. Kaban L. Dentoalveolar surgery. In: Kaban L, editor. *Pediatric Oral and Maxillofacial Surgery*. Philadelphia: Saunders; 1990.
10. Kirtaniya BC, Sachdev V, Singla A, Sharma AK. Marsupialization: A conservative approach for treating dentigerous cyst in children in the mixed dentition. *J Indian Soc Pedod Prev Dent* 2010;28:203-8.
11. Hyomoto M, Kawakami M, Inoue M, Kirita T. Clinical conditions for eruption of maxillary canines and mandibular premolars associated with dentigerous cysts. *Am J Orthod Dentofacial Orthop* 2003;124:515-20.