



OPEN ACCESS

CASE REPORT

Hypothalamic relapse of a cardiac large B-cell lymphoma presenting with memory loss, confabulation, alexia–agraphia, apathy, hypersomnia, appetite disturbances and diabetes insipidus

Natalia Ospina-García,¹ Gustavo C Román,² Belén Pascual,² Mary R Schwartz,³ Hector Alejandro Preti⁴

¹Department of Neurology, National University of Colombia, Bogota, Colombia

²Department of Neurology, Methodist Neurological Institute, Houston, Texas, USA

³Department of Pathology, Houston Methodist Hospital, Houston, Texas, USA

⁴Department of Medicine (Oncology), Houston Methodist Hospital, Houston, Texas, USA

Correspondence to

Professor Gustavo C Román, groman@houstonmethodist.org

Accepted 26 July 2018

SUMMARY

A 37-year-old Hispanic man with a right atrial intracardiac mass diagnosed as diffuse large B-cell lymphoma (DLBCL) was successfully treated with surgery and chemotherapy. During 4 years, several total-body positron emission tomography and MRI scans showed no extracardiac lymphoma. On year 5 after the cardiac surgery, patient presented with sleepiness, hyperphagia, memory loss, confabulation, dementia and diabetes insipidus. Brain MRI showed a single hypothalamic recurrence of the original lymphoma that responded to high-dose methotrexate treatment. Correction of diabetes insipidus improved alertness but amnesia and cognitive deficits persisted, including incapacity to read and write. This case illustrates two unusual locations of DLBCL: primary cardiac lymphoma and hypothalamus. We emphasise the importance of third ventricle tumours as causing amnesia, confabulation, behavioural changes, alexia–agraphia, endocrine disorders and alterations of the circadian rhythm of wakefulness–sleep secondary to lesions of specific hypothalamic nuclei and disruption of hypothalamic–thalamic circuits.

BACKGROUND

Primary cardiac lymphoma (PCL) is an extranodal non-Hodgkin's lymphoma exclusively located in the heart and/or pericardium. According to Maleszewski and Jaffe,¹ the term PCL is used when the tumour resides primarily in the heart or presents with predominant cardiac manifestations even when limited extracardiac involvement is present. PCL is a rare cardiac tumour accounting for 1.3% of all primary cardiac tumours.² In the patient reported here, the primary cardiac diffuse large B-cell lymphoma (DLBCL) was successfully treated with surgery and chemotherapy before it relapsed in the central nervous system (CNS) 5 years after completion of treatment. The CNS relapse of a PCL is extremely rare and, to our knowledge, of the nine such cases previously reported,^{3–10} none had involvement of deep midline diencephalic structures (table 1).

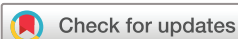Third ventricle tumours causing cognitive and behavioural disturbances are rarely described despite having important localising significance.

Lesions involving the hypothalamus may manifest clinically with memory deficits and confabulation, endocrine disorders, behavioural changes and alterations of the wakefulness–sleep circadian rhythm. We report a rare case of hypothalamic lymphoma and review the literature to emphasise the importance of dementia, amnesia, confabulation, apathy, abulia, alexia, agraphia and sleep disturbances as manifestations of a tumour localised in the medial diencephalon.

CASE PRESENTATION

In 2007, a 37-year-old Hispanic man presented with symptoms of haemodynamic cardiac compromise and was found to have a cardiac mass invading the right atrium and mediastinum. MRI of the chest (figure 1) showed a large right heart mass (8.4×7.4×7.6 cm) centred at the lateral aspect of the right heart near the atrioventricular plane extending inside the cardiac lumen and outside into the pericardial and epicardial fat. The tricuspid valve was deformed by the mass; there was no involvement of the interatrial and interventricular septum. In the resected tissue, the tumour extended up to the base of the tricuspid valve. The mass extended superiorly to the right lateral part of the aortic root and to the lateral aspect of the right ventricular outflow tract.

Initial 2-deoxy-2-(¹⁸F)fluoro-D-glucose (FDG-PET) scan showed normal tracer uptake in the brain, nasopharynx, oropharynx, larynx and adjacent structures, including the sternocleidomastoid muscles, without the presence of pathological lymph nodes in the neck. The patient underwent median sternotomy, atrial tumour debulking and tricuspid valve replacement. DLBCL was diagnosed and he completed eight cycles of chemotherapy (R-CHOP (rituximab, cyclophosphamide, doxorubicin, vincristine and prednisone)) followed by involved field radiotherapy. About 1 month after completing his radiation therapy, tumour recurrence in the mediastinum was found and he was reinduced with chemotherapy (R-ESHAP (rituximab, etoposide, solomedrol, cytarabine and platinum)) receiving two cycles followed by consolidative high-doses chemotherapy (BEAM (BiCNU carmustine, Etoposide, Ara-C cytarabine, melphalan)) and autologous stem cell support.



© BMJ Publishing Group Limited 2018. Re-use permitted under CC BY-NC. No commercial re-use. See rights and permissions. Published by BMJ.

To cite: Ospina-García N, Román GC, Pascual B, et al. *BMJ Case Rep* Published Online First: [please include Day Month Year]. doi:10.1136/bcr-2016-217700

Table 1 Reported cases of primary cardiac lymphoma with CNS relapse

Case no.	Authors	Date	Age (years)/Sex	Location/Time to CNS relapse
1	Kimura <i>et al</i> ³	1997	60/F	Multiple metastases/13 months
2	Montalbetti <i>et al</i> ⁴	1999	51/M	Meningeal/3 months
3	AlZeerah <i>et al</i> ⁵	2003	65/M	Multiple metastases/6 months
4	Bulum <i>et al</i> ⁶	2007	70/M	L frontal mass/2 months
5	Nishizawa <i>et al</i> ⁷	2010	68/F	Neurolymphomatosis/2 months
6	Jung <i>et al</i> ⁸	2014	62/M	R parahippocampal gyrus, thalamus, basal ganglia; ventricular ependyma/1 month
7	Montoro <i>et al</i> ⁹	2014	54/F	Fourth ventricle/2 months
8	Montoro <i>et al</i> ⁹	2014	59/F	L frontal, L parietal/1 month
9	Soon <i>et al</i> ¹⁰	2016	75/F	Neurolymphomatosis/10 months
10	Ospina-García <i>et al</i> [*]	2018	37/M	Third ventricle—hypothalamus/5years

*This report.

CNS, central nervous system; F, female; L, left; M, male; R, right.

The patient was followed for 4 years with several total-body FDG-PET, CT and MRI scans that showed no extracardiac location of the lymphoma and no evidence of disease recurrence after his bone marrow transplant. In 2012, 5 years after initial presentation of the lymphoma, the patient's family reported that for the past 3 months, he had exhibited marked memory deficits for recent events, severe daytime sleepiness and behavioural changes such as apathy, loss of interest, lack of energy and hyperphagia.

On examination, the patient was a 42-year-old obese man with normal vital signs. His level of arousal fluctuated with brief periods of alertness followed by intermittent sleep attacks. He knew his name but was disoriented to time and space. He spoke slowly, showed poor recall and confabulated. No focal neurological findings were present and no other neurological abnormalities were found. Lymphoma recurrence in the brain was suspected and CT scan demonstrated a mass in the third ventricle. Brain MRI confirmed a 21×26×25 mm uniform enhancing mass (figure 2) involving the anterior–inferior portion of the third ventricle and adjacent structures, including the hypothalamus, with suprasellar extension. There was no hydrocephalus.

The lymphoma in the heart and mediastinal lymph nodes resected in 2007 was a DLBCL. By flow cytometry, the lymphoma expressed CD10, CD19, CD20 and CD79b. There was kappa light chain restriction and the lymphoma was Epstein-Barr virus

(EBV) negative both by in situ hybridisation for EBV-encoded RNA and by immunohistochemistry for EBV latent membrane protein. In 2012, the brain biopsy pathology showed that the tumour was recurrent DLBCL. Flow cytometric immunophenotyping showed a monoclonal B-cell population positive for CD10, CD19 and CD20 with kappa light chain restriction. This immunophenotype is similar to the cardiac tumour and confirmed the cerebral relapse of the PCL.

The patient was successfully reinduced with high-dose methotrexate resulting in disappearance of the brain mass. Afterwards, on several occasions, he was admitted to the emergency room for treatment of electrolyte disturbances with hypernatraemia from diabetes insipidus. Desmopressin treatment optimised sodium levels and hydration, but despite the successful lymphoma treatment, his altered mental status persisted.

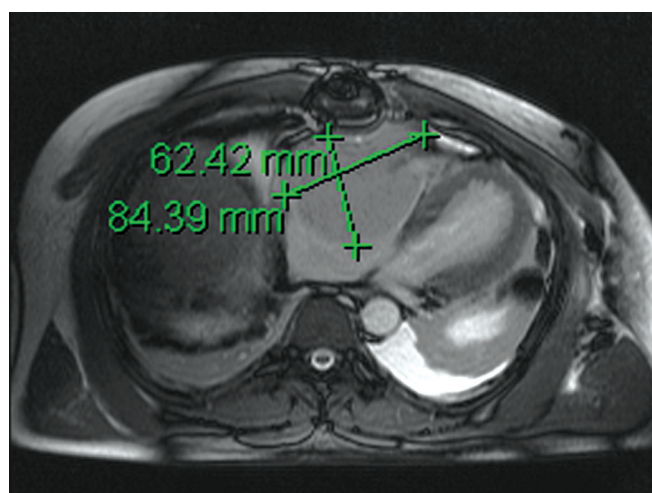


Figure 1 Chest MRI (unenhanced 15 February 2007) showing a large right heart mass extending inside the cardiac lumen and outside into the pericardial and epicardial fat. The tricuspid valve is deformed by the mass.

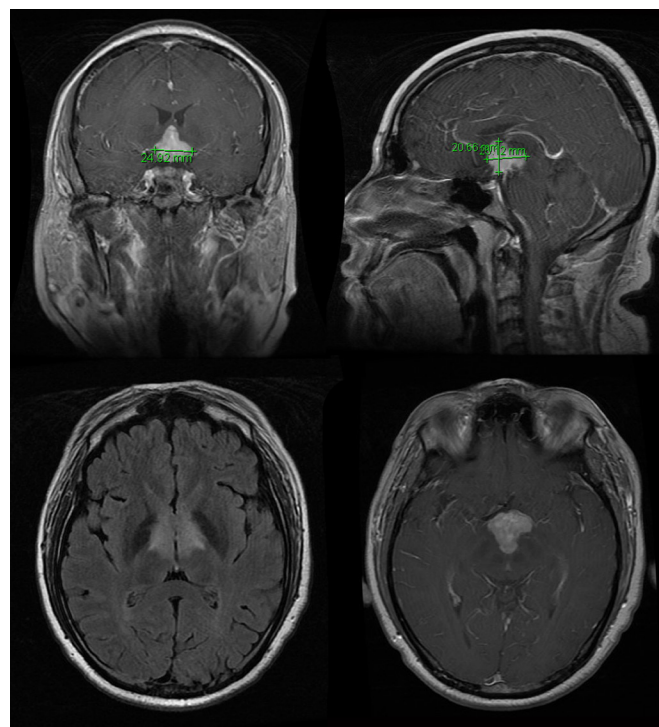


Figure 2 Brain MRI (gadolinium-enhanced 1 November 2012) showing a 21×26×25 mm enhancing mass involving the anterior inferior third ventricle and adjacent structures including suprasellar extension.

Table 2 Neuropsychological performance at initial treatment of the diencephalic tumour and 15 months later

Variable	At initial treatment	Fifteen months later
Dementia screening		
MMSE	4/30	24/30
Cognitive domains		
Memory		
FCSRT	5/96	46/96
Logical memory WMS-III		
Immediate recall	0/25	5/25
Delayed recall	0/25	0/25
Recognition	0/15	7/15
Rey Complex Figure Test—recall	0/18	4/18
Language		
Boston Naming Test	20/60	35/60
Verbal fluency (named in 30 s)		
Animals	4	9
Words starting with letter 'P'	1	4
Visuospatial function		
Rey Complex Figure Test—copy	0/18	18/18
Executive function, attention and speed of processing		
Trail Making Test		
Part A (sec)	300'	113'
Mental Control WMS-III	4/35	8/35
Clock Drawing Test	3/14	12/14
Cognitive fluctuation		
Fluctuation Inventory Scale	14/16	8/16
Other domains		
IADL	0/8	3/8
Geriatric Depression Scale	25/30	26/30
Neuropsychiatric Inventory	73/144	12/144

Data are presented as direct scores.

FCSRT, Free and Cued Selective Reminding Test; IADL, Instrumental Activities of Daily Living Scale; MMSE, Mini-Mental State Examination; WMS-III, Wechsler Memory Scale, Third Edition.

INVESTIGATIONS, TREATMENT AND OUTCOME

In 2013, we evaluated the patient at the Memory & Dementia Clinic of the Houston Methodist Neurological Institute due to persistent memory loss, confabulation, sleepiness, abulia, apathy and crying spells. Continuous electroencephalographic (EEG) recordings during the neuropsychological evaluation showed sleep attacks with fluctuating attention. Patient was disoriented to time, space and person. Spanish language evaluation revealed semantic paraphasias and word-finding difficulties. His main problem was the severe abnormality of verbal and visual memory, poor recall of recent events, episodic memory deficits and confabulations during the assessment (table 2). The neuropsychological performance indicated global cognitive loss and executive dysfunction consistent with moderate to severe dementia.

Neurological examination confirmed the changes in alertness, cognition and mental status. Visual fields and extraocular movements were normal, and there were no alterations of motor or sensory functions. Deep tendon reflexes and coordination were normal. MRI showed no evidence of the hypothalamic mass (figure 3). The patient presented apathy, depression and pseudobulbar crying spells; he received treatment with dextromethorphan–quinidine (Nuedexta) and sertraline with improvement of these symptoms. Obstructive sleep apnoea was

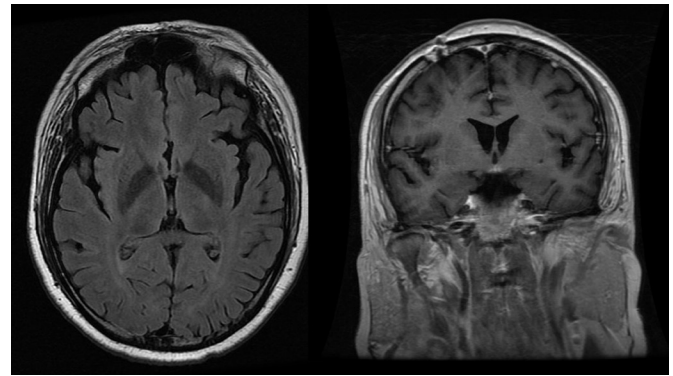


Figure 3 Brain MRI (gadolinium-enhanced 24 April 2014) showing no mass, mass effect or enhancing lesion within the brain parenchyma. There is minimal normal enhancement along the infundibulum. The previous hypothalamic mass has disappeared and no definite enhancing lesions were appreciated on this examination.

demonstrated and treated with nasal continuous positive airway pressure resulting in control of the excessive daytime sleepiness.

He returned 1 year later and his cognitive functions had improved; memory and learning difficulties persisted but confabulation was no longer evident. He was last seen in the clinic in 2017 (ie, 10 years after onset of cardiac symptoms and 5 years after the CNS relapse); at that time, there was no evidence of tumour recurrence. He had returned to gainful manual work despite the persistence of the amnesia and the fact that he had forgotten how to read and to write, notwithstanding speech and cognitive therapy.

DISCUSSION

According to the WHO,¹¹ DLBCL represents 25%–30% of adult non-Hodgkin lymphomas. PCL is a rare extranodal localisation and CNS dissemination is exceptional.^{1–10} The 2015 AFIP (Armed Forces Institute of Pathology) criteria¹² include cases of lymphoma presenting with cardiac manifestations, particularly if the bulk of disease is found in the heart or the pericardium. Thus, despite the mediastinal lymph node involvement in our case, the tumour was diagnosed as PCL. CNS relapses of primary cardiac DLBCL are rare and probably due to genetic factors, including dual translocations of *MYC*⁺ and *BCL2*⁺ (so-called ‘double-hit DLBCL’).¹³ In the case reported here, we present an in-depth analysis of the complex cognitive and behavioural symptoms manifested by this patient, providing clinicopathological correlations with relevant anatomic structures of thalamus and hypothalamus.¹⁴

Memory loss

In 1937, James W. Papez,¹⁵ described the basic memory circuit comprising the hippocampus and structures in the neighbourhood of the third ventricle including fornix, mammillary bodies, the mammillothalamic tract of Vicq-d’Azyr, as well as the anterior and medial thalamic nuclei. The subiculum and presubiculum in the hippocampal formation project to the anteromedial, anterodorsal and anteroventral thalamic nuclei as well as to the mammillary bodies via the fornix. From the mammillary bodies, the mammillothalamic tract provides input to the anterior thalamic complex which then projects to cingulate, orbitofrontal, retrosplenial and subicular areas.^{16 17} Injury to any of these structures can result in severe anterograde memory loss, affecting especially episodic and recognition memory.¹⁷ Left medial thalamic lesions cause verbal

memory deficits, while right-sided lesions result in loss of visuospatial memory.¹⁸

In the patient reported here, the tumour lesion in the walls of the third ventricle caused alterations primarily in episodic memory, severe learning impairment and difficulties with recall of both verbal and visual information, probably explaining the loss of the capacity to read and write without evidence of language disruption.¹⁹ These deficits correlate with the midline localisation of the lesion affecting bilaterally the fornix, without involvement of the mammillary bodies but perhaps with involvement of the anterior thalamic complex and dorsomedial nucleus.

In 1967, Georges de Morsier,²⁰ reported a similar case of amnesic syndrome in a patient with a hypothalamic glioma; the lesion was bilateral, involved the mammillary bodies and the fornix and had mesencephalic extension confirmed by neuropathology.²⁰ He reviewed the cognitive and clinical presentation in 38 cases of hypothalamic tumours from the literature including his case. Men predominated (58%) and the median age was 45.1 years (range, 19–62); 37% were older than 41 years. The tumours included craniopharyngiomas (58.2%), gliomas (13.9%), chromophobe adenomas (11.1%), ependymal cysts (5.6%), metastases (5.6%), eosinophilic adenomas (2.8%) and teratomas (2.8%). Duration of the symptom ranged from 2 to 8 years for teratomas, adenomas and ependymal cysts, and from weeks to months in the remaining lesions. According to de Morsier,²¹ the amnesic syndrome was present in 100% of the cases followed by: (1) behavioural problems, including manic changes and euphoria, lack of social inhibition, depression, anxiety, apathy and irritability (84.2%); (2) confabulation and false recognitions (53%); (3) excessive daytime somnolence (47.4%); (4) motor symptoms such as facial spasms, dysarthria, hypotonia, catalepsy and parkinsonism (36.8%); (5) hypersexuality or loss of libido (31.6%); (6) hyperphagia, obesity, polydipsia and polyuria (31.6%); and (7) visual hallucinations (18.4%) consistent with vivid dreams. With the exception of motor symptoms and hallucinations, all the other manifestations were present in our case.

Confabulation

In addition to amnesia, this patient had confabulation whereby he provided obviously false information in response to simple questions. Confabulation is a common symptom in acute Wernicke-Korsakoff syndrome and in patients with ruptured aneurysms of the anterior communicating artery implicating well-defined brain structures in the pathogenesis of this symptom. The neuropathology of acute alcoholic Wernicke's encephalopathy from thiamine (vitamin B₁) deficiency most frequently involves the mammillary bodies with presence of microhaemorrhages.²¹ In patients with Korsakoff amnesic syndrome—considered a chronic residual manifestation of Wernicke's encephalopathy—the neuroanatomical lesion that appears to account for the amnesia is damage to the anterior nucleus of the thalamus secondary to involvement of the mammillary bodies.²²

In this patient, there was no apparent damage to the mammillary bodies and both hippocampi were intact suggesting that the bilateral injuries of the fornix and minor involvement of the anterior thalamic nuclei were probably responsible for the amnesia and the transient confabulation. It has been postulated that confabulations occur when the preserved hippocampus receives distorted information from other areas of the brain, especially prefrontal medial and orbitofrontal areas or

their projections.²³ The latter structures are important for strategic retrieval that involves search processes and monitoring of the memories. It has been hypothesised that confabulations are produced by failures in retrieval process and selection of memories within a specific time and context.^{23 24}

Apathy, abulia, irritability

Apathy can be observed mainly with anterior cingulate damage although it may also occur with lesions in nucleus accumbens, ventral pallidum, ventral tegmental area and medial dorsal nucleus of the thalamus.²⁵ Disruption along the cortico-striatal-pallidal-thalamic-cingulum circuits produces akinetic mutism, abulia or apathy depending on the grade of severity of the dysfunction.²⁶ In our patient, the apathy, lack of self-initiated action, decreased responsiveness to stimuli and irritability could have resulted from disruption of thalamic projections to the cingulate cortex and to the orbitofrontal medial cortex. Nishio *et al*²⁷ studied patients with left anterior thalamic infarcts using combined FDG-PET and MRI stereotactic localisation; apathy was found in all cases, along with verbal memory impairment and language disturbances, in particular anomia and word-finding difficulties. FDG-PET showed decreased regional cerebral blood flow perfusion of the left anterior cingulate gyrus.²⁷ In contrast, right thalamic lesions leading to disruption of the right orbitofrontal circuit presented with irritability and socially unacceptable behaviours,²⁸ similar to those of frontal lobe syndrome.^{29 30}

Pseudobulbar affect

Our patient presented with crying spells and faulty control of emotional impulses; this syndrome is currently classified as pseudobulbar affect (PBA) and is thought to arise from disruption of corticobulbar and cerebellopontine pathways controlling emotional expression.³¹ In our case, disruption of projections from the anteromedial thalamus to orbitofrontal cortex could be responsible for the PBA.³² In general, lesions in subcortical segments of these anatomical systems by a tumour mass in the third ventricle often cause mixed syndromes because of the proximity of multiple subcortical structures involved in the different circuits.³² Dextromethorphan plus ultra-low-dose quinidine³³ reduced PBA and had a positive effect in our patient. Dextromethorphan³⁴ is an uncompetitive N-methyl-D-aspartate receptor antagonist, a sigma-1 receptor agonist and a serotonin reuptake inhibitor.

Loss of reading and writing ability: alexia–agraphia

Our patient lost the previously learnt capacity to read and write, and despite intense cognitive therapy, he has been unable to read; he cannot go beyond the letter B when trying to repeat the alphabet. In 2013, Barker *et al*,¹⁹ reported here a similar case in an 18-year-old man with a third ventricle colloid cyst who became symptomatic after a minor traumatic brain injury. The authors demonstrated that the cyst had splayed the fornix interfering with memory recall. As in our patient, in their case, there was no involvement of visual pathways nor of cortical areas usually implicated in alexia and agraphia such as lesions of the lingual gyrus or fusiform gyrus (respectively, medial and lateral occipitotemporal gyri) thought to mediate letter and word recognition. Given our patient's profound memory loss, this case would support the pathogenesis of some forms of alexia–agraphia from bilateral injury of fornix tracts in the third ventricle.

Table 3 Anatomical–clinical correlation of symptoms exhibited by patient with third ventricle (hypothalamic) relapse of cardiac large B-cell lymphoma

Anatomical structure*	Symptoms
Fornix (bilateral tracts) and projections to anterior thalamic nuclear complex and dorsomedial thalamic nucleus	Amnesia: episodic memory loss for verbal and visual information; learning impairment
Fornix and anterior thalamic complex	Confabulation
Thalamic projections to cingulate cortex and orbitofrontal medial cortex	Apathy, lack of self-initiated action
Thalamic projections to orbitofrontal cortex	Pseudobulbar affect, crying spells
Fornix tracts	Alexia–agraphia
Medial thalamus, anterior hypothalamic cholinergic and GABAergic neurons. Lateral hypothalamic neurons (orexin, melanin-concentrating)	Sleep attacks, alteration of circadian rhythm of wakefulness– sleep
Ventromedial hypothalamic nucleus, arcuate nucleus	Hyperphagia, alteration of appetite
Supraoptic and paraventricular nuclei, mediobasal hypothalamus (arginine vasopressin)	Diabetes insipidus responsive to desmopressin

*Nomenclature according to: Swaab DF. *The Human Hypothalamus: Basic and Clinical Aspects. Part I: Nuclei of the Human Hypothalamus. Handb Clin Neurol* 2003;79:1–597.

Sleep disturbances

Besides the cognitive and behavioural symptoms, our patient had important alterations in wakefulness with excessive daytime sleepiness resulting from diurnal sleep attacks demonstrated by prolonged EEG recording. Specific neuronal populations located in the basal forebrain and the hypothalamus control the regulatory mechanisms for the initiation and control of sleep–wake cycles, as well as for alternation between the different sleep stages.^{35 36} As mentioned earlier, almost half (47.4%) of the patients with third ventricle tumours and paramedian thalamic lesions have daytime hypersomnia.²⁰ In these cases, rapid-eye movement (REM) sleep is usually normal, but wakefulness, sleep spindling and delta sleep are all reduced, suggesting that the medial thalamus mediates wakefulness and promotion of non-REM sleep.³⁷ The anterior hypothalamic extension of the tumour in our case could have involved the cholinergic nucleus in the basal forebrain (anterior hypothalamic neurons) that are activated during REM sleep and wakefulness, promoting arousal and REM sleep. Histamine-producing and noradrenergic neurons promoting wakefulness are located in the posterior hypothalamus and in all likelihood were unaffected by the tumour in our case. In contrast, the nearby sleep-activator GABAergic neurons of the anterior hypothalamus were probably involved. Likewise, although we failed to quantify cerebrospinal fluid (CSF) levels of the wake-promoting neuropeptide orexin and melanin-concentrating hormone, given the severity of the sleep attacks, we postulate involvement of lateral hypothalamic neurons, a complex hub for integration of central and peripheral signals that regulate sleep.³⁸ The orexin neurons project at multiple levels of the sleep–wake regulatory system, stimulating ascending monoaminergic and cholinergic neurons, and the REM-off neurons.³⁸ Orexin neurons fire actively during waking and the orexin receptors are excitatory. Loss of orexin neurons induces daytime sleepiness; subjects fall asleep easily during pauses in stimulation. In narcolepsy, the typical REM-onset sleep, cataplexy and vivid dreams of REM sleep while awake are due to low CSF levels of orexin.³⁸

Control of appetite

Apart from the disturbances mentioned above, our patient had alterations in feeding behaviour, especially hyperphagia and weight gain. Localised hypothalamic lesions involving ventromedial hypothalamus (VMH) and arcuate nucleus have been associated with hyperphagia and obesity in humans. A neoplastic lesion involving the midline hypothalamus resulting

in bilateral destruction of the VMH area was reported as a cause of hyperphagia.³⁹ About 25%–45% of VMH neurons have glucoreceptors that are activated during feeding to initiate satiety and to decrease food intake. Additionally, arcuate nucleus pro-opiomelanocortin neurons activate VMH neurons.⁴⁰ Neuronal damage to either arcuate nucleus or VMH neurons may result in hypothalamic obesity.^{41 42}

Endocrine disturbances

The most common hypothalamic endocrine disturbance is diabetes insipidus due to inadequate production and release of the antidiuretic hormone arginine vasopressin.⁴³ Diabetes insipidus results in excretion of large volumes of diluted urine leading to hypernatraemia. In addition to polyuria, our patient also had abnormal blood glucose levels. These symptoms are the consequences of involvement of specific hypothalamic areas such as the supraoptic and paraventricular nuclei, and the mediobasal hypothalamus.⁴³ Currently, the patient requires desmopressin to maintain homeostasis of the electrolytic balance and needs strict glucose control.

In conclusion, we present the results of the complete evaluation and treatment of a patient with a primary cardiac lymphoma (DLBCL) that responded to surgical treatment and aggressive medical oncology therapy of the primary lesions in the heart and mediastinum but had a brain relapse 5 years later involving selectively the walls of the third ventricle.

Table 3 summarises the clinical–anatomical correlation of the symptoms. The CNS relapse presented as an advanced dementia manifested by profound memory loss, confabulation, alexia–agraphia, cognitive decline, plus a behavioural disorder with hyperphagia and obesity, profound apathy, depression and crying spells, in addition to sleep attacks and excessive daytime sleepiness. The DLBCL brain relapse responded completely to methotrexate. The patient has achieved a 10-year survival. The dementia has improved substantially, and the residual diabetes insipidus was controlled with desmopressin.

Prevention of CNS relapses of DLBCL is a current topic of high interest,^{13 44–46} but we emphasise here the importance of a high index of suspicion to document the neurological relapse of the lymphoma. This case illustrates the complexity of the clinical and pathological manifestations of a single patient with cardiac and hypothalamic DLBCL with a successful outcome resulting from surgical intervention, medical oncology, internal medicine and cognitive neurology treatments.

Learning points

- ▶ Small lesions in the hypothalamus have multiple cognitive, behavioural and endocrine manifestations, as well as disturbances of sleep–wake circadian rhythms and appetite.
- ▶ Neurological relapses of large B-cell lymphoma are treatable.
- ▶ Anatomical–clinical correlations are possible based on the functions of the different hypothalamic nuclei and the disruption of hypothalamic–thalamic circuits.

Contributors HAP designed the initial oncological treatment of the patient and successfully managed the relapses and the internal medicine complications. MRS performed the pathology studies of the cardiac and hypothalamic lesions. GCR evaluated the neurological complications, imaging results and sleep data, and directed the neuropsychiatric treatment. BP performed the neuropsychological evaluations. NO-G summarised the medical records, reviewed the literature and wrote the initial version of the paper in conjunction with GCR. All the authors approved the final manuscript.

Funding GCR research is funded by the Blanton Distinguished Endowed Chair and the Blanton-Wareing Family Fund NO-G was the recipient of a David Cabello International Scholarship from Houston Methodist Hospital.

Competing interests None declared.

Patient consent Next of kin consent obtained.

Provenance and peer review Not commissioned; externally peer reviewed.

Open access This is an open access article distributed in accordance with the Creative Commons Attribution Non Commercial (CC BY-NC 4.0) license, which permits others to distribute, remix, adapt, build upon this work non-commercially, and license their derivative works on different terms, provided the original work is properly cited, appropriate credit is given, any changes made indicated, and the use is non-commercial. See: <http://creativecommons.org/licenses/by-nc/4.0/>.

REFERENCES

- 1 Maleszewski JJ, Jaffe ES, *et al* Cardiac lymphomas. In: Travis WD, Brambilla E, Burke AP, Marx A, Nicholson AG, . *WHO classification of tumors of the lung, pleura, thymus and heart*. 4th edn. Lyon: IARC Press, 2015:340–1.
- 2 Petrich A, Cho SI, Billett H. Primary cardiac lymphoma: an analysis of presentation, treatment, and outcome patterns. *Cancer* 2011;117:581–9.
- 3 Kimura T, Yoshizu H, Hatori N, *et al*. [Surgical treatment for primary cardiac malignant lymphoma]. *Nihon Kyobu Geka Gakkai Zasshi* 1997;45:607–10.
- 4 Montalbetti L, Della Volpe A, Airaghi ML, *et al*. Primary cardiac lymphoma. A case report and review. *Minerva Cardioangiol* 1999;47:175–82.
- 5 AlZeerah MA, Singh R, Jarrous A. Large B-cell lymphoma of the atria. *Tex Heart Inst J* 2003;30:74–5.
- 6 Bulum J, Banfić L, Strozzi M, *et al*. Primary cardiac lymphoma presenting as atrial flutter and total heart block. *Heart Vessels* 2007;22:52–4.
- 7 Nishizawa M, Yamashita K, Nakamoto Y, *et al*. Neurolymphomatosis as a manifestation of relapsed primary cardiac lymphoma. *Int J Hematol* 2010;92:679–80.
- 8 Jung YH, Woo IS, Ko YJ, *et al*. A case of primary cardiac lymphoma showing isolated central nervous system relapse. *Clin Lymphoma Myeloma Leuk* 2014;14:e31–3.
- 9 Montoro J, Mattia L, Bertazzoni P, *et al*. Primary cardiac lymphoma with isolated parenchymal central nervous system relapse: report of two cases and review of the literature. *Ecancermedicalscience* 2014;8:474.
- 10 Soon G, Ow GW, Chan HL, *et al*. Primary cardiac diffuse large B-cell lymphoma in immunocompetent patients: clinical, histologic, immunophenotypic, and genotypic features of 3 cases. *Ann Diagn Pathol* 2016;24:40–6.
- 11 Swerdlow SH, Campo E, Harris NL, *et al*. *WHO classification of tumours of haematopoietic and lymphoid tissues*. Lyon, France: International Agency for Research on Cancer, 2017.
- 12 Burke A, Tavora FR, Maleszewski JJ, *et al*. Tumors of the heart and great vessels. Chapter 17, hematologic tumors of the heart and pericardium. In: *AFIP atlas of tumor pathology. Fourth series, fascicle 22*. Silver Spring, MD: American Registry of Pathology, 2015:337–59.
- 13 Savage KJ, Slack GW, Mottok A, *et al*. Impact of dual expression of *MYC* and *BCL2* by immunohistochemistry on the risk of CNS relapse in DLBCL. *Blood* 2016;127:2182–8.
- 14 Swaab DF. The human hypothalamus: basic and clinical aspects. Part II: Neuropathology of the human hypothalamus and adjacent brain structures. Chapter 19: tumors. *Handb Clin Neurol* 2004;80:51–89.
- 15 Papez JW. A proposed mechanism of emotion. 1937. *J Neuropsychiatry Clin Neurosci* 1995;7:725–43.
- 16 Aggleton JP, Saunders RC. The relationships between temporal lobe and diencephalic structures implicated in anterograde amnesia. *Memory* 1997;5:49–72.
- 17 Aggleton JP, Dumont JR, Warburton EC. Unraveling the contributions of the diencephalon to recognition memory: a review. *Learn Mem* 2011;18:384–400.
- 18 Van der Werf YD, Jolles J, Witter MP, *et al*. Contributions of thalamic nuclei to declarative memory functioning. *Cortex* 2003;39:1047–62.
- 19 Barker LA, Morton N, Romanowski CA, *et al*. Complete abolition of reading and writing ability with a third ventricle colloid cyst: implications for surgical intervention and proposed neural substrates of visual recognition and visual imaging ability. *BMJ Case Rep* 2013;2013:bcr2013200854.
- 20 de Morsier G. Gliome hypothalamique avec syndrome amnésique de Korsakoff. Le problème de la mémoire. [Hypothalamic glioma with Korsakoff's amnesic syndrome. The problem of memory]. *Ann Méd Psychol* 1967;125:177–228.
- 21 Kril JJ, Harper CG. Neuroanatomy and neuropathology associated with Korsakoff's syndrome. *Neuropsychol Rev* 2012;22:72–80.
- 22 Harding A, Halliday G, Caine D, *et al*. Degeneration of anterior thalamic nuclei differentiates alcoholics with amnesia. *Brain* 2000;123(Pt 1):141–54.
- 23 Dalla Barba G, Boisse MF. Temporal consciousness and confabulation: is the medial temporal lobe "temporal"? *Cogn Neuropsychiatry* 2010;15:95–117.
- 24 Gilboa A, Moscovitch M. The cognitive neuroscience of confabulation: a review and a model. In: Baddeley AD, ed. *The handbook of memory disorders*. New York: John Wiley & Sons, 2002:315–42.
- 25 Marin RS. Apathy: concept, syndrome, neural mechanisms, and treatment. *Semin Clin Neuropsychiatry* 1996;1:304–14.
- 26 Marin RS, Wilkosz PA. Disorders of diminished motivation. *J Head Trauma Rehabil* 2005;20:377–88.
- 27 Nishio Y, Hashimoto M, Ishii K, *et al*. Neuroanatomy of a neurobehavioral disturbance in the left anterior thalamic infarction. *J Neurol Neurosurg Psychiatry* 2011;82:1195–200.
- 28 Bogousslavsky J, Ferrazzini M, Regli F, *et al*. Infarction of the right thalamus. Syndrome with paramedian manic delirium and frontal-like. *J Neurol Neurosurg Psychiatry* 1988;51:116–9.
- 29 Alexander MP, Stuss DT. Disorders of frontal lobe functioning. *Semin Neurol* 2000;20:427–38.
- 30 Rosen HJ, Allison SC, Schauer GF, *et al*. Neuroanatomical correlates of behavioural disorders in dementia. *Brain* 2005;128:2612–25.
- 31 Parvizi J, Anderson SW, Martin CO, *et al*. Pathological laughter and crying: a link to the cerebellum. *Brain* 2001;124:1708–19.
- 32 Parvizi J, Coburn KL, Shillcutt SD, *et al*. Neuroanatomy of pathological laughing and crying: a report of the American Neuropsychiatric Association Committee on Research. *J Neuropsychiatry Clin Neurosci* 2009;21:75–87.
- 33 Pattee GL, Wymer JP, Lomen-Hoerth C, *et al*. An open-label multicenter study to assess the safety of dextromethorphan/quinidine in patients with pseudobulbar affect associated with a range of underlying neurological conditions. *Curr Med Res Opin* 2014;30:2255–65.
- 34 Choi DW, Peters S, Viseskul V. Dextropropranolol and levorphanol selectively block N-methyl-D-aspartate receptor-mediated neurotoxicity on cortical neurons. *J Pharmacol Exp Ther* 1987;242:713–20.
- 35 Bonnavion P, Mickelsen LE, Fujita A, *et al*. Hubs and spokes of the lateral hypothalamus: cell types, circuits and behaviour. *J Physiol* 2016;594:6443–62.
- 36 Saper CB, Scammell TE, Lu J. Hypothalamic regulation of sleep and circadian rhythms. *Nature* 2005;437:1257–63.
- 37 Bassetti C, Mathis J, Gugger M, *et al*. Hypersomnia following paramedian thalamic stroke: a report of 12 patients. *Ann Neurol* 1996;39:471–80.
- 38 Scammell TE, Nishino S, Mignot E, *et al*. Narcolepsy and low CSF orexin (hypocretin) concentration after a diencephalic stroke. *Neurology* 2001;56:1751–3.
- 39 Celesia GG, Archer CR, Chung HD. Hyperphagia and obesity. Relationship to medial hypothalamic lesions. *JAMA* 1981;246:151–3.
- 40 King BM. The rise, fall, and resurrection of the ventromedial hypothalamus in the regulation of feeding behavior and body weight. *Physiol Behav* 2006;87:221–44.
- 41 Bechtold DA, Loudon AS. Hypothalamic clocks and rhythms in feeding behaviour. *Trends Neurosci* 2013;36:74–82.
- 42 Brown JA, Woodworth HL, Leininger GM. To ingest or rest? Specialized roles of lateral hypothalamic area neurons in coordinating energy balance. *Front Syst Neurosci* 2015;9:9.
- 43 Robertson GL. Diabetes insipidus: differential diagnosis and management. *Best Pract Res Clin Endocrinol Metab* 2016;30:205–18.
- 44 Kridel R, Dietrich PY. Prevention of CNS relapse in diffuse large B-cell lymphoma. *Lancet Oncol* 2011;12:1258–66.
- 45 Ferreri AJ. Risk of CNS dissemination in extranodal lymphomas. *Lancet Oncol* 2014;15:e159–69.
- 46 Kanemasa Y, Shimoyama T, Sasaki Y, *et al*. Central nervous system relapse in patients with diffuse large B cell lymphoma: analysis of the risk factors and proposal of a new prognostic model. *Ann Hematol* 2016;95:1661–9.

Copyright 2018 BMJ Publishing Group. All rights reserved. For permission to reuse any of this content visit <http://group.bmj.com/group/rights-licensing/permissions>.
BMJ Case Report Fellows may re-use this article for personal use and teaching without any further permission.

Become a Fellow of BMJ Case Reports today and you can:

- ▶ Submit as many cases as you like
- ▶ Enjoy fast sympathetic peer review and rapid publication of accepted articles
- ▶ Access all the published articles
- ▶ Re-use any of the published material for personal use and teaching without further permission

For information on Institutional Fellowships contact consortiasales@bmjgroup.com

Visit casereports.bmj.com for more articles like this and to become a Fellow