

Appendiceal hemangioma, mimicking acute appendicitis in a 17-year-old girl

Bitā Geramizadeh, Amin Niakan, Nadjmeh Zolmadjdi, Mahsa Marzban
Department of Pathology, Transplant Research Center, Shiraz University of Medical Sciences, Shiraz, Iran

Abstract

Epithelial tumors of appendix are not so common, and mesenchymal tumors of the appendix are even less common. Capillary hemangioma of the appendix is an extremely rare event and to the best of our knowledge only 4 cases have been reported in the English literature so far. In this case report we want to explain our experience with an extremely rare occurrence of capillary hemangioma of appendix in a 17-year-old girl presented with right lower quadrant pain that was operated with the clinical impression of acute appendicitis. The patient has been operated as a routine appendectomy with a completely uneventful postoperative period.

Introduction

Hemangioma is a tumor or autonomous new growth and formation of vessels or proliferation of the vessel walls.¹ Vascular anomalies are divided into two categories: vascular tumors, which include hemangiomas, and vascular malformations.²

Hemangiomas are true neoplasms of endothelial cells and should be differentiated from vascular malformations which are localized defects of vascular morphogenesis.³

Historically benign vascular tumors have been classified according to the type of fluid they contained as hemangioma (blood-containing lesion) and lymphangioma (lymph-containing lesion) and to the size of the vascular channels as capillary (small diameter vascular channels) and cavernous (large diameter vascular channels). Another classification has been based on biological characteristics, physical findings and natural history that differentiate vascular lesions with endothelial cell proliferation (example hemangioma) from lesions with structural anomalies (vascular malformations).⁴

As a whole, visceral vascular tumors are composed of hemangioma, lymphangioma, hemolymphangioma, hemangioendothelioma, hemangiopericytoma, hemangioblastoma and

angiosarcoma. Hemangiomas are vascular tumors composed of blood vessels lined by endothelial cells. Visceral hemangiomas can be found in various organs including the brain, parotid, thorax, liver, spleen, adrenal, retroperitoneum and gastrointestinal tract, in isolation, or with synchronous cutaneous lesions.⁵

Capillary hemangioma may occur anywhere in the body, however hemangioma of the appendix is an extremely rare event and to the best of our knowledge only 4 cases have been reported in the English literature so far, 2 of which have been in the meso of appendix^{1,4} and the other 2 cases have been diagnosed to be multiple hemangiomas associated with liver and rectal involvement.^{5,6} All of the previously reported cases have presented with hemorrhagic complications, anemia and abdominal pain.⁴ Here in we report an extremely rare occurrence of isolated appendiceal hemangioma preoperatively diagnosed as acute appendicitis.

Case Report

A 17-year-old adolescent girl referred to the emergency room with the chief complaint of right lower quadrant (RLQ) pain. In physical examination RLQ tenderness was detected. She was a healthy young lady with no other abnormality and physical examination was completely unremarkable, *i.e.* heart rate, respiratory rate and temperature were all normal and blood pressure was 125/85.

Laboratory findings were as follows: white blood cell count: 13,400/mL, platelet count: 262,000/mL, and hemoglobin: 14.4 g/L. Prothrombin time was also normal. Urine analysis was unremarkable. Abdominopelvic ultrasonography was also within normal limit.

Observing the patient for 2 hours showed clinical findings highly in favor of acute appendicitis, *i.e.* rebound tenderness, pain on percussion, rigidity, guarding, and RLQ tenderness were present. Also there was tenderness on palpation in the RLQ over the McBurney point, so the patient was operated and appendectomy has been performed for her.

After surgery, she had an uneventful postoperative period and discharged in 48 hours.

The removed appendix has been sent to the pathology department. Gross examination showed small brownish discoloration with congestion in the wall of appendix, otherwise it was completely normal looking (Figure 1). Pathologic sections showed small capillary hemangioma, under the appendiceal mucosa and between the layers of muscle in the appendiceal wall (Figure 2).

Abdominopelvic sonography and computed tomography (CT) scan after the operation

Correspondence: Bitā Geramizadeh, Department of Pathology, Transplant Research Center, Shiraz University of Medical Sciences, PO Box 71345-1864, Shiraz, Iran.
E-mail: geramib@gmail.com

Key words: Appendix; capillary hemangioma; acute appendicitis.

Contributions: the authors contributed equally.

Conflict of interest: the authors declare no potential conflict of interest.

Received for publication: 18 September 2015.

Revision received: 12 January 2016.

Accepted for publication: 26 January 2016.

This work is licensed under a Creative Commons Attribution NonCommercial 4.0 License (CC BY-NC 4.0).

©Copyright B. Geramizadeh et al., 2016

Licensee PAGEPress, Italy

Rare Tumors 2016; 8:6208

doi:10.4081/rt.2016.6208

were completely normal. Chest and brain CT scan were also normal. The patient was re-examined after the diagnosis of appendiceal hemangioma, *i.e.* in the skin and liver or gastrointestinal tract, however no hemangioma was found in this patient.

Now, after 6 months, she is doing well and completely symptom-free.

Discussion and Conclusions

Hemangiomas only account for approximately 0.3% of all gastrointestinal tumors.⁶ However appendiceal hemangiomas are extremely rare. There are only 4 previously reported cases. Two of them have been in the mesentery of appendix,^{1,3} and two others have been in the appendix associated with rectal and liver hemangiomas.^{4,5}

Table 1 shows the characteristics of the appendiceal hemangiomas reported in the English literature so far.

As Table 1 shows the most common presenting sign and symptoms have been anemia and abdominal pain.^{4,5} Hemangioma in the gastrointestinal (GI) tract is most commonly part of a diffuse disease and mostly accompanied with hemangiomas in other parts of the body such as liver and rectum.¹

Appendiceal hemangioma is most commonly of cavernous type; however one of the previous cases has been mixed capillary and cavernous type of this tumor.⁵

Our case is unique in multiple aspects; first

Table 1. Characteristics of the previous cases of appendiceal hemangioma in comparison to current case.

Author	Year	Sex	Age, years	Presenting symptom	Location	Type
Harned ³	1974	M	37	Rectal bleeding	Appendix and rectum	Cavernous
Hanatae ²	1995	M	48	Abdominal mass	Mesentery of appendix	Cavernous
Benevento ⁴	2003	F	34	Chronic abdominal pain	Appendix and liver	Mixed capillary and cavernous
Parker ¹	2009	M	32	Abdominal pain	Mesentery of appendix and ileum	Cavernous
Current case	2015	F	17	RLQ pain	Appendix	Capillary

RLQ, right lower quadrant.

of all it has been isolated in appendix, it means that thorough examination failed to show any evidence of other organ involvement, also it was of pure capillary type, which has not been reported in the appendix. Also this case has

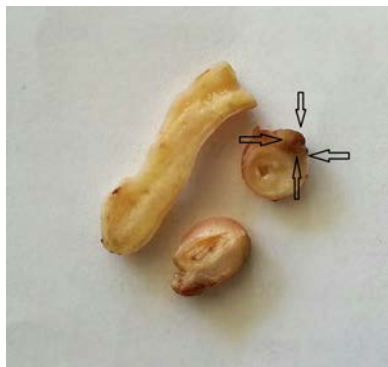


Figure 1. The gross of the resected specimen shows the brownish discoloration in the wall of appendix.

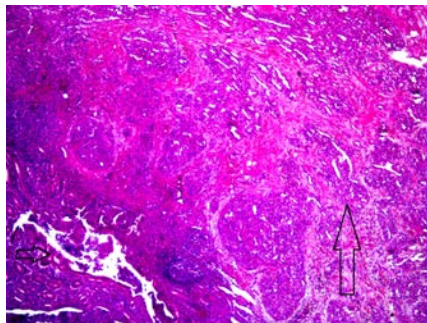


Figure 2. Microscopic sections show the capillary hemangioma in the wall of appendix (hematoxylin and eosin, 100 \times).

been operated with the clinical impression of acute appendicitis and it was only after evaluation of the pathologic specimen that hemangioma has been detected.

We think that hemangioma of appendix by itself has been harmless and innocent, however after engorgement, it could cause obstruction of the lumen mimicking sign and symptoms of acute appendicitis, because we didn't find any inflammation in the lumen and wall of appendix. Our case has been an incidental finding after operation, however with preoperative diagnosis of visceral hemangioma, there are various treatment options. Radiotherapy has no place in the management of these tumors. Similarly, chemotherapy, rarely affects these lesions; therefore the only option is surgical excision. Alternatively, embolization of the feeding vessel, causing spontaneous regression of vascular tumors has been described. On the other hand, the positive impact of IFN- γ in suppressing vascular tumors of brain, soft tissue, and liver has been shown in several investigations, and substantial regression of vascular tumors by this drug has also been reported. Not only does IFN- γ have an antitumor effect, but it can also inhibit endothelial cell motility, and tumor-induced angiogenesis.^{7,8}

As a conclusion, hemangioma of appendix has rarely been reported; it can be easily missed if the pathology specimen won't be examined precisely. This lesion is most commonly associated with other organ involvement; so this report is to emphasize the importance of precise examination of a simple specimen such as appendix not to miss lesions such as small hemangiomas.

References

1. Parker WT, Harper JG, Rivera DE, et al. Mesenteric cavernous hemangioma involving small bowel and appendix: a rare presentation of a vascular tumor. *Am Surg* 2009;75:811-6.
2. Noshier JL, Murillo PG, Liszewski M, et al. Vascular anomalies: a pictorial review of nomenclature, diagnosis and treatment. *World J Radiol* 2014;6:677-92.
3. Mondal U, Henkes N, Henkes D, Rosenkranz L. Cavernous hemangioma of adult pancreas: a case report and literature review. *World J Gastroenterol* 2015;21:9793-802.
4. Hanatae F, Mizuno Y, Murakami T. Venous hemangioma of the mesoappendix: report of a case and a brief review of the Japanese literature. *Surg Today* 1995;25:962-4.
5. Harned RK, Dobry CA, Farley GE. Cavernous hemangioma of the rectum and appendix: report of a case. *Dis Colon Rectum* 1974;17:759-62.
6. Benevento A, Boni L, Dionigi G, et al. Multiple hemangiomas of the appendix and liver. *J Am Coll Surg* 2003;197:860-1.
7. Nishiyama N, Mori H, Kobara H, et al. Bleeding duodenal hemangioma, morphologic changes and endoscopic mucosal resection. *World J Gastroenterol* 2012;18:2872-6.
8. Geramizadeh B, Banani A, Foroutan HR, et al. Malignant epithelioid hemangioendothelioma of the bladder: the first case report in a child. *J Pediatr Surg* 2009;44:1443-5.