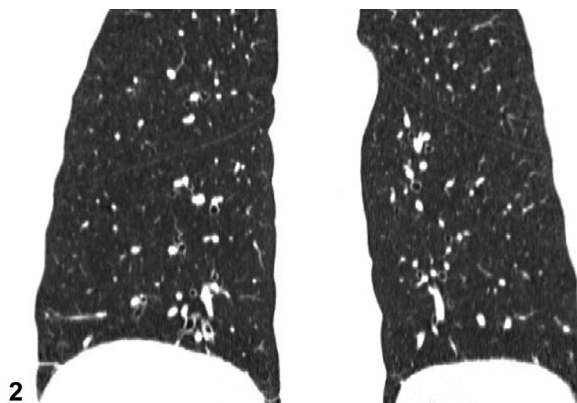
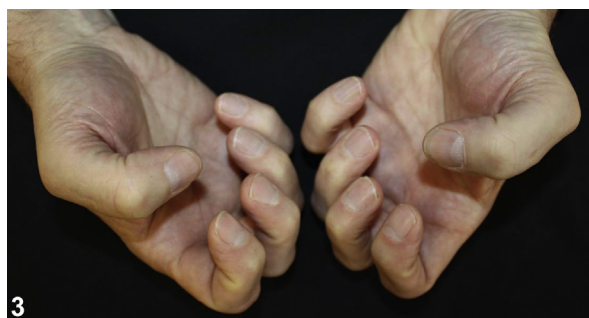
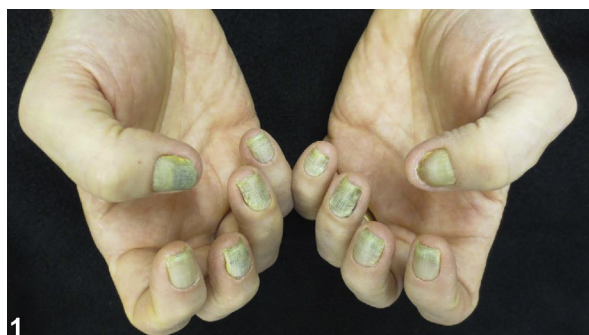
Nail changes, lymphedema, and respiratory symptoms



Mike Wang, BS,^a and Oscar R. Colegio, MD, PhD^{a,b}
New Haven, Connecticut and Buffalo, New York



A 59-year-old man presented to our clinic with a 2.5-year history of progressive painful yellow discoloration and deformation of the fingernails (Fig 1) and toenails, accompanied by lower extremity lymphedema. The nail changes developed at the proximal nailfold and progressed distally. He concurrently had a history of recurrent sinusitis and a chronic cough. See Fig 2 for the chest computed tomography scan. Immunologic workup and nail fungal cultures were unrevealing. The patient was started on therapy, with complete resolution of nail signs and symptoms at 2 years (Fig 3).

Question 1: What is the most likely diagnosis?

- A. Chronic paronychia
- B. Nail lichen planus
- C. Nondermatophyte mold onychomycosis
- D. Onychomadesis secondary to steal syndrome
- E. Yellow nail syndrome (YNS)

From the Department of Dermatology, Yale University School of Medicine^a and the Department of Dermatology, Roswell Park Comprehensive Cancer Center.^b

Funding sources: None.

Conflicts of interest: None disclosed.

Correspondence to: Oscar R. Colegio, MD, PhD, Roswell Park Transplant Dermatology Clinic, Roswell Park Comprehensive Cancer Center, Buffalo, NY 14263. E-mail: oscar.colegio@roswellpark.org.

JAAD Case Reports 2019;5:773-5.
2352-5126

© 2019 by the American Academy of Dermatology, Inc. Published by Elsevier, Inc. This is an open access article under the CC BY-NC-ND license (<http://creativecommons.org/licenses/by-nc-nd/4.0/>).

<https://doi.org/10.1016/j.jidcr.2019.06.010>

Answers:

A. Chronic paronychia – Incorrect. Chronic paronychia is a condition most likely caused by contact reaction to irritants and most commonly affects adult women. It is unlikely to affect all digits, as is the case in this patient.

B. Nail lichen planus – Incorrect. Nail lichen planus presents with a distinct set of clinical findings, which include nail thinning, longitudinal ridging and fissuring, and dorsal pterygium. None of these findings were present in this patient.

C. Nondermatophyte mold onychomycosis – Incorrect. Onychomycosis typically begins distally and spreads proximally, as opposed to this case in which nail symptoms began at the proximal nail-fold. Proximal onychomycosis is uncommon and typically affects those with severely compromised immune systems.

D. Onychomadesis secondary to steal syndrome – Incorrect. Vascular steal caused by an arteriovenous fistula can lead to unilateral, single-limb nail changes. The nail changes seen in this patient are bilateral and affect both the fingers and toes.

E. YNS – Correct. First described in 1964, YNS is a rare disorder characterized by a constellation of signs and symptoms predominated by thickened yellow nail discoloration and deformation, respiratory manifestations, and lymphedema. The underlying systemic mechanism is unknown. A recent case-control study found marked lymphatic insufficiency in YNS patients.¹ However, in the largest case series currently available, lymphedema was present in only 63% of patients, suggesting that a lymphatic phenotype is not necessary in YNS.²

Question 2: The chest computed tomography scan (Fig 2) showed mild bronchiectasis in this patient, which is commonly associated with this condition. What other common association in this condition necessitates a respiratory workup for urgent management?

- A.** Chronic cough
- B.** Chronic sinusitis
- C.** Interstitial lung disease
- D.** Lung carcinoma
- E.** Pleural effusions

Answers:

A. Chronic cough – Incorrect. Present in this patient and one of his earliest presenting symptoms, chronic cough, which occurs in more than half the patients (56%), is the most common respiratory manifestation of YNS.² However, chronic cough does not require urgent management.

B. Chronic sinusitis – Incorrect. Present in this patient and a source of distress for him, chronic sinusitis is a common respiratory manifestation of YNS that does not require urgent management.²

C. Interstitial lung disease – Incorrect. YNS is rarely associated with connective tissue and autoimmune disorders,^{2,3} which can present with interstitial lung disease.

D. Lung carcinoma – Incorrect. There are suggestions that YNS may be a paraneoplastic phenomenon, and cases of YNS associated with lung malignancies have been documented; however, this association is rare.³

E. Pleural effusions – Correct. Often the most dangerous component of YNS and the one requiring the most urgent management, such as surgery, pleurodesis, or medical management with octreotide, pleural effusions occur in approximately half of patients with YNS and are often recurrent.^{2,4}

Question 3: What treatment would be the most effective in treating this condition?

- A.** Oral biotin supplementation
- B.** Oral doxycycline
- C.** Oral itraconazole alone
- D.** Oral vitamin E with pulsed oral itraconazole
- E.** Topical 0.05% betamethasone dipropionate cream

Answers:

A. Oral biotin supplementation – Incorrect. Biotin supplementation is a part of the treatment for onychoschizia. One case of successful treatment of YNS using biotin has been documented, although this has not been replicated.⁵

B. Oral doxycycline – Incorrect. Systemic antibiotics are used in the treatment of acute paronychia. However, the use of tetracyclines, such as doxycycline can rarely lead to photo-onycholysis, which can present with nail changes similar to YNS.

C. Oral itraconazole alone — Incorrect. Oral itraconazole monotherapy is the standard of treatment for nondermatophyte mold onychomycosis and is less effective than oral vitamin E and itraconazole combination therapy for the treatment of YNS.⁴

D. Oral vitamin E with pulsed oral itraconazole — Correct. Used to great effect in this patient (Fig 3), oral vitamin E (1200-1600 U/d) with pulsed oral itraconazole (400 mg/d for 1 week per month) is found to have approximately a 50% response rate in patients with YNS.⁴

E. Topical 0.05% betamethasone dipropionate cream — Incorrect. Topical high-potency steroids are the treatment of choice for chronic paronychia but not YNS.

Abbreviation used:

YNS: yellow nail syndrome

REFERENCES

1. Cousins E, Cintolesi V, Vass L, et al. A case-control study of the lymphatic phenotype of yellow nail syndrome. *Lymphat Res Biol.* 2018;16:340-346.
2. Maldonado F, Tazelaar HD, Wang CW, Ryu JH. Yellow nail syndrome: analysis of 41 consecutive patients. *Chest.* 2008;134:375-381.
3. Vignes S, Baran R. Yellow nail syndrome: a review. *Orphanet J Rare Dis.* 2017;12:42.
4. Kurin M, Wiesen J, Mehta AC. Yellow nail syndrome: a case report and review of treatment options. *Clin Respir J.* 2017;11:405-410.
5. Nordkild P, Kromann-Andersen H, Struve-Christensen E. Yellow nail syndrome—the triad of yellow nails, lymphedema and pleural effusions. A review of the literature and a case report. *Acta Med Scand.* 1986;219:221-227.