

CASE REPORT

doi: 10.5455/medarh.2014.68.289-290

Published online: 31/07/2014
Published print: 08/2014Med Arh. 2014 Aug; 68(4): 289-290
Received: May 20th 2014 | Accepted: June 05th 2014
© AVICENA 2014

Cyst of the Canal of Nuck in a Two Year Old Girl

Edin Husaric, Nesad Hotic, Amir Halilbasic, Senada Husaric, Emir Rahmanovic, Sanimir Suljendic

Pediatric Clinic Tuzla, University Clinical Center Tuzla, Tuzla, Bosnia and Herzegovina

Corresponding author: Edin Husaric, MD Pediatric Clinic Tuzla, University Clinical Center Tuzla, Tuzla, Bosnia and Herzegovina. Phone: +387 61 194 187; Email: ehusaric@hotmail.com

ABSTRACT

The canal of Nuck is analogous to a patent processus vaginalis in a male, which normally loses its communication to the peritoneal cavity within the first year of life. Failure of obliteration of this tract can result in a hydrocele. We present a rare case of a 2-year-old girl with left-sided groin swelling, diagnosed as inguinal hernia. Patient underwent surgical exploration and establishes definitive diagnosis as cyst of the canal of Nuck.

Keywords: Canal of Nuck, hydrocele, processus vaginalis.

1. INTRODUCTION

The canal of Nuck is analogous to a patent processus vaginalis in a male, which normally loses its communication to the peritoneal cavity within the first year of life. Failure of obliteration of this tract can result in a hydrocele. (1).

Cyst of the canal of Nuck is an uncommon disorder in a female child. There is no information about this disease in textbooks of pediatric surgery and pediatric gynecology. Searching in English literature, via Pub Med and Scopus, we have found that so few cases have been reported that most of them are cases reports in women. In general, radiological findings have been discussed. This disease called hydrocele of the canal of Nuck, cyst of the canal of Nuck and female hydrocele, is accepted equivalent of the spermatic cord cyst (encysted hydrocele) occurring in boys (2, 3, 4, 5, 6, 7).

We present a rare case of a 2-year-old girl with left-sided groin swelling over a year, diagnosed as hydrocele of canal of Nuck

In this article, we have presented our patient suffering from cyst of the canal of Nuck.

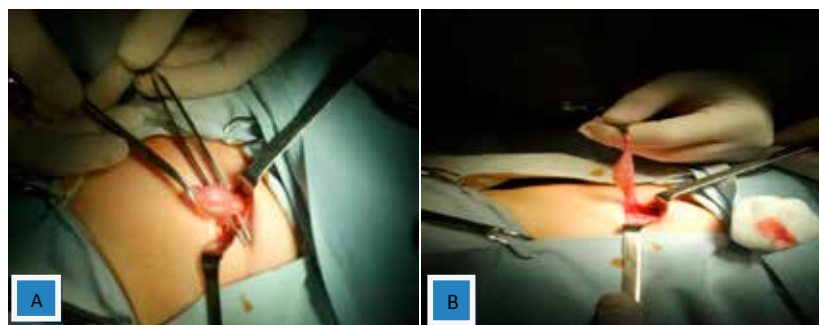
2. CASE REPORT

A 2-year-old girl presented to clinic with a tender palpable swelling in the left inguinal region. On detailed history, the swelling had changed in size from time to time. On physical examination, the swelling was tender, easy to reduce. Patient underwent surgical exploration of the swelling through a left inguinal skin crease incision. After usually dissection through skin, subcutaneous tissues, Scarpa's fascia, and external oblique aponeurosis, the inguinal canal was exposed. The cystic swelling

of the cord was identified and isolated. The swelling was confirmed to be an encysted hydrocele of cord with no evidence of associated inguinal hernia (Figure 1). After excision of hydrocele, the fibrous connection toward the deep inguinal ring was suture ligated and rest of the wound was closed in layers. Postoperative recover of patient was uneventful.

3. DISCUSSION

Hydroceles are common in children, especially in boys. But hydrocele of the canal of Nuck is an uncommon clinical presentation. Although the exact process is unclear, it is generally agreed that obliteration of the processus vaginalis occurs only after the seventh month of gestation, thus accounting for the higher incidence of inguinal hernias in the premature infant. Although not clearly defined, there is a known heredity factor associated with the occurrence of hernias that is more frequent in twin gestations and in infants who have a family history of hernia (7). Swelling of the inguinal region in a female may result from a number of conditions, including inguinal hernia, tumor (lipoma, leiomyoma, sarcoma), cyst, abscess, lymphadenopathy, or hydrocele of the canal of Nuck (8).

**Figure 1.** Cyst of the canal of Nuck—operative finding (A-view from above; B-lateral view)

Hydrocele of the canal of Nuck is an unusual diagnosis. In women, a round ligament is attached to the uterus close to the origin of the fallopian tubes, and the extension of the parietal peritoneum follows the round ligament as it passes to the inguinal canal through the internal ring. This evagination of the parietal peritoneum, named the canal of Nuck, is known as the female counterpart of the processus vaginalis in men. Normally this peritoneal evagination undergoes obliteration soon after birth in both sexes. If it remains completely patent, it forms an avenue for an indirect inguinal hernia. Partial proximal obliteration with a patent distal portion causes a cyst of the canal of Nuck (9).

There are three types of a hydrocele of canal of Nuck. The most common type is one with no communication with peritoneal cavity forming an encysted hydrocele along the tract of descent, from the inguinal ring to the vulva. Second type results when there is a persistent communication with the peritoneal cavity. A third type is a combination of the two as a result of the inguinal ring constricting the hydrocele like a belt so that part is communicating and part is enclosed, giving this the name of hour glass type. However, any of these types of hydroceles are extremely rare in females (1).

The differential diagnosis for an inguinal mass in a female includes indirect hernia, lymphadenopathy, Cold abscess, Bartholin's cyst, post-traumatic hematoma, rarely cystic lymphangioma, neuroblastoma metastasis in groin and ganglion (10, 11).

4. CONCLUSION

A hydrocele of the canal of Nuck though rare should be considered in the differential diagnosis in young females presenting with an inguinal swelling. Establishing a definitive diagnosis on clinical examination is challenging. Surgical exploration is critical for final diagnosis.

CONFLICT OF INTEREST: NONE DECLARED.

REFERENCES

1. Janssen K, Klinkner D, Kumar T. Encysted Hydrocele of Canal of Nuck. A Case Report With Review of Literature. *J Surg Tech Case Rep.* 2011; 3(2): 97-98.
2. Akkoyun I, Kucukosmanoglu I, Yalinkilinc E. Cyst of the canal of nuck in pediatric patients. *North Am J Med Sci.* 2013; 5: 353-356.
3. Kim SH, Seo IY, Cho HJ, Ku1 YM, Kim KH, Ahn CH. et al. Hydrocele of the Canal of Nuck. *J Korean Surg Soc.* 2008; 74: 396-398.
4. Park SJ, Lee HK, Hong HS, Kim HC, Kim DH, Park JS. et al. Hydrocele of the canal of Nuck in a girl: Ultrasound and MR appearance. *Br J Radiol.* 2004; 77: 243-244.
5. Choi YM, Lee GM, Yi JB, Yoon KL, Shim KS, Bae CW. et al. Two cases of female hydrocele of the canal of nuck. *Korean J Pediatr.* 2012; 55: 143-146.
6. Huang CS, Luo CC, Chao HC, Chu SM, Yu YJ, Yen JB. The presentation of asymptomatic palpable movable mass in female inguinal hernia. *Eur J Pediatr.* 2003; 162: 493-495.
7. De Meulder F, Wojciechowski M, Hubens G, Ramet J. Female hydrocele of the canal of Nuck: a case report. *Eur J Pediatr.* 2006; 165: 193-194.
8. Anderson CC, Broadie TA, Mackey JE, Kopecky KK. Hydrocele of the canal of Nuck: ultrasound appearance. *Am Surg.* 1995; 61: 959-961.
9. Ozel A, Kirdar O, Halefoglu AM, Erturk SM, Karpat Z, Lo Russo G, et al. Cysts of the canal of Nuck: Ultrasound and magnetic resonance imaging findings. *J Ultrasound.* 2009; 12: 125-127.
10. Poenaru D, Jacobs DA, Kamal I. Unusual findings in the inguinal canal: A report of four cases. *Pediatr Surg Int.* 1999; 15: 515-516.
11. Pandit SK, Rattan KN, Budhiraja S, Solanki RS. Cystic lymphangioma with special reference to rare sites. *Indian J Pediatr.* 2000; 67: 339-341.