



Nasopharyngeal abscess causing inspiratory dyspnoea in a domestic cat

Annie Slater , Raquel del Solar and Jennifer Raj

Journal of Feline Medicine and Surgery Open Reports
1–4

© The Author(s) 2023

Article reuse guidelines:

sagepub.com/journals-permissions

DOI: 10.1177/20551169231178448

journals.sagepub.com/home/jfmsopenreports

This paper was handled and processed by the European Editorial Office (ISFM) for publication in *JFMS Open Reports*



Abstract

Case summary An 11-month-old female domestic shorthair cat presented with a 24 h history of inspiratory dyspnoea, abnormal upper respiratory tract sounds, gagging, retching and making exaggerated swallowing motions. Retroflexed nasopharyngoscopy revealed a large, right-sided nasopharyngeal mass that was seen to exude purulent material and a possible small foreign body when pressure was applied with forceps. Thorough expression of the mass alleviated clinical signs. Cytology revealed septic neutrophilic inflammation, and a *Pasteurella* species with no noted antimicrobial resistance was cultured. The cat was discharged with oral antibiotics and analgesia and made a full recovery, with no recurrence of clinical signs at the 6-month follow-up.

Relevance and novel information Abscess formation in the nasopharyngeal region has not been previously reported in cats, to the authors' knowledge. The cause of the abscess was suspected to be a foreign body, but other aetiologies could not be fully excluded. This case demonstrates that nasopharyngeal abscesses are a rare but potentially significant differential diagnosis for upper respiratory tract obstruction in cats.

Keywords: Pharynx; nasopharynx; abscess; airway obstruction; retroflexed nasopharyngoscopy; stridor

Accepted: 10 May 2023

Case description

An 11-month-old female neutered domestic shorthair cat presented to the referral centre with a 24 h history of dyspnoea, abnormal upper respiratory tract sounds, gagging, retching and making exaggerated swallowing motions.

Initial investigations at the primary care practice included a complete blood count and biochemistry blood tests, the results of which were unremarkable. A dorsoventral and left lateral thoracic radiograph showed no abnormalities, nor did visual examination of the oral cavity under general anaesthesia.

Clinical examination at the referral centre revealed increased inspiratory effort with upper respiratory tract stertor and an extended-neck stance (Figure 1). The cat was frequently making exaggerated swallowing motions and had a relatively low heart rate given its degree of stress at 140 beats per minute (bpm). No murmur was detected, and an electrocardiogram showed sinus rhythm. Examination of the nares and oral cavity was

unremarkable. Retropulsion of the globes was bilaterally symmetrical. No abnormalities were detected on abdominal palpation or palpation of peripheral lymph nodes. Rectal temperature was 38.5°C. Body condition score was appropriate at 4/9, with a weight of 3.1 kg. The rest of the physical examination was unremarkable.

The clinical signs and physical examination findings localised the respiratory tract obstruction to the nasopharynx, with a foreign body or polyp considered most likely, and neoplasia possible but less likely due to signalment and onset. Laryngeal or nasal diseases remained differential diagnoses but were considered less likely.

Southfields Veterinary Specialists (part of Linnaeus Veterinary), Basildon, UK

Corresponding author:

Annie Slater MA, VetMB, MRCVS, Southfields Veterinary Specialists (part of Linnaeus Veterinary), Cranes Point, Gardiners Ln S, Basildon SS14 3AP, UK
Email: annie.slater@southfields.co.uk





Figure 1 Extended-neck stance seen on presentation

It was suggested that a CT scan be performed, followed by potential endoscopy. However, owing to cost limitations, the decision was made to prioritise endoscopy over cross-sectional imaging. The cat was anaesthetised. A premedication of 0.3 mg/kg ketamine, 0.03 mg/kg medetomidine and 0.3 mg/kg methadone was given intravenously, and the cat was induced with propofol and maintained on oxygen and isoflurane. The larynx, tonsils, teeth, gingiva, tongue and hard palate were all examined and found to be of normal appearance. Otoscopic examination was unremarkable.

Retroflexed nasopharyngoscopy was performed using a gastroscope (outer diameter 3.7 mm; Karl Storz). Nasopharyngoscopy revealed a large, right-sided rostral nasopharyngeal mass that was causing obstruction of the ipsilateral choana (Figure 2). It was smooth, broad-based and non-pedunculated with a single cream-coloured spot caudally and centrally.

Pressure was gently applied with forceps, and the mass was seen to exude macroscopically purulent material. The mass was expressed to drain as much material as possible from the suspected abscess, which appeared much reduced in size by the end of the procedure. A single small piece of black material was also seen within the purulent material and noted as a possible foreign body. Grab biopsies of the wall of the mass were taken in case they were needed for histology, and this also provided extra drainage sites for the purulent fluid. Biopsy forceps were also used to obtain a sample of the purulent fluid for cytology and culture. The oral cavity and oropharynx were flushed and cleaned at the end of the procedure to remove any residual purulent material.

The cat made a good anaesthetic recovery, with an immediate reduction of clinical signs, and no further dyspnoea or stertor noted the following morning. Follow-up heart rates were in the range of 180–188 bpm.

Cytology of the purulent material showed large numbers of degenerate neutrophils, with a mixed bacterial population consisting of pleomorphic rods and some cocci (Figure 3). The cat was treated with amoxicillin and

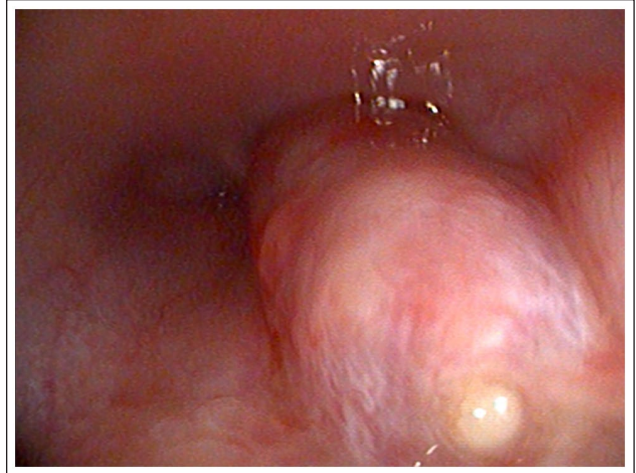


Figure 2 Retroflexed nasopharyngoscopy. Appearance of the nasopharyngeal mass

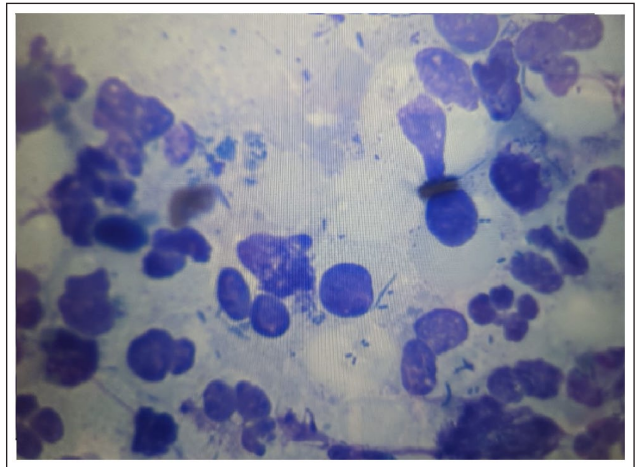


Figure 3 Cytological appearance of purulent material, Diff-Quick stain

clavulanic acid (16 mg/kg PO q12h for 2 weeks) and gabapentin for analgesia (8 mg/kg PO q8h for 3 days) and made a full recovery. Buprenorphine (0.02 mg/kg IV q8h) was also given for the first 24 h during hospitalisation for additional pain relief. A 14-day antibiotic course was used empirically in this case, as being a novel presentation, there is no established recommended duration of treatment; it is possible that a shorter course of antibiotics may have been sufficient. The combination of amoxicillin and clavulanic acid was chosen for its broad spectrum of action, as a neutrophil and mixed bacterial population had been confirmed on cytology. Culture was sent to confirm susceptibility, which revealed profuse growth of a *Pasteurella* species, with no antimicrobial resistance noted. A non-steroidal anti-inflammatory drug may have been useful for its analgesic and anti-inflammatory effect but was not given as the owner

reported the cat had been given a steroid injection by the referring veterinarian (which could not be verified with the referring veterinary surgeon at the time). Histology samples were not sent as there were no further concerns and cost was a limiting factor. These were kept on hold in case they were required in future. The cat was reported to be well at 1 month and at the 6-month telephone follow-up with the owner, with no recurrence of clinical signs. Repeat nasopharyngoscopy was not performed due to complete resolution of clinical signs and financial restraints but would be recommended should any relapse of clinical signs occur.

Discussion

This case represents the first reported case of a nasopharyngeal abscess causing upper respiratory signs in a cat, as far as the authors are aware. Inspiratory dyspnoea more broadly is a relatively common presenting complaint in cats, with reported causes including stenotic nares, nasopharyngeal polyps, rhinitis, neoplasia, laryngeal disease and tracheal lesions.¹

The upper respiratory tract clinical signs described in this case were typical of nasopharyngeal disease.² The bradycardia was presumed to be a vagally mediated effect of the space-occupying mass in the nasopharynx as heart rates increased to 180–188 bpm on anaesthetic recovery after abscess expression.

Retroflexed nasopharyngoscopy was chosen as the main diagnostic, and potentially therapeutic, technique in this case. It allows direct visualisation, sampling and intervention in the nasopharynx,³ and in this case aided alleviation of clinical signs through abscess expression. As a cause for the clinical signs had been detected, funds were limited and no further specific nasal signs (eg, sneezing, nasal discharge) had been observed, anterior rhinoscopy was not performed.

Further diagnostics were unable to be performed due to financial restrictions. Cross-sectional imaging (CT scan) was offered and would have allowed a better assessment of the extent of the lesion, including its association with surrounding structures. CT characteristics have also been shown to have some value in differentiating types of nasopharyngeal tumour,⁴ and so may have also aided in providing aetiologic and prognostic information. In addition, submission of the biopsy samples would have enabled further distinction between different potential aetiologies.

Nasopharyngeal obstruction in domestic cats has several possible causes, with neoplastic masses (especially lymphosarcoma) and nasopharyngeal polyps having been reported as the most important significant causes.^{5,6} Nasopharyngeal abscess formation has not been previously reported in domestic cats to our knowledge. A literature search performed using the PubMed and

OVID databases showed no relevant results. However, we note with interest a recently published case of partial airway obstruction in a cat caused by a pharyngeal dermoid cyst, which was removed surgically.⁷

The cause of the abscess in this case was suspected to be a foreign body, but other aetiologies, including penetrating trauma, tooth root abscess or underlying neoplasia, have also been reported in feline upper respiratory tract disease⁸ and cannot be completely excluded. However, given the lack of ongoing signs and lack of visual abnormalities to the hard palate and teeth, these other aetiologies were considered less likely.

While the literature in cats is lacking, nasopharyngeal abscesses are a documented phenomenon in humans. In humans, reported causes include oesophageal balloon dilation,⁹ repeated nasopharyngeal swabs¹⁰ and neoplasia.¹¹

Pasteurella species are known to be oral commensals in cats, and are often associated with opportunistic infection in pyothorax, skin wounds and subcutaneous abscesses in these species.^{12,13} Its association with this abscess is likely to have been opportunistic, and secondary to an unknown inciting cause. However, future recurrence may be possible if the aetiology was, for example, an acute infection of an existing neoplasia.

Conclusions

We report the first known case of nasopharyngeal abscessation causing upper respiratory tract obstruction in a cat. Nasopharyngeal abscess should therefore be considered as a differential diagnosis for upper respiratory tract signs in cats.

Conflict of interest The authors declared no potential conflicts of interest with respect to the research, authorship, and/or publication of this article.

Funding The author(s) disclosed receipt of the following financial support for the research, authorship, and/or publication of this article: Linnaeus Veterinary Limited supported the costs of the Open Access publication charges.

Ethical approval The work described in this manuscript involved the use of non-experimental (owned or unowned) animals. Established internationally recognised high standards ('best practice') of veterinary clinical care for the individual patient were always followed and/or this work involved the use of cadavers. Ethical approval from a committee was therefore not specifically required for publication in *JFMS Open Reports*. Although not required, where ethical approval was still obtained, it is stated in the manuscript.

Informed consent Informed consent (verbal or written) was obtained from the owner or legal custodian of all animal(s) described in this work (experimental or non-experimental

animals, including cadavers) for all procedure(s) undertaken (prospective or retrospective studies). For any animals or people individually identifiable within this publication, informed consent (verbal or written) for their use in the publication was obtained from the people involved.

ORCID ID Annie Slater  <https://orcid.org/0000-0003-3398-8142>

Jennifer Raj  <https://orcid.org/0000-0002-8413-9995>

References

- 1 Swift S, Dukes-McEwan J, Fonfara S, et al. **Aetiology and outcome in 90 cats presenting with dyspnoea in a referral population.** *J Small Anim Pract* 2009; 50: 466–473.
- 2 Reed N and Gunn-Moore D. **Nasopharyngeal disease in cats: 1. Diagnostic investigation.** *J Feline Med Surg* 2012; 14: 306–315.
- 3 Sobel DS. **Upper respiratory tract endoscopy in the cat: a minimally invasive approach to diagnostics and therapeutics.** *J Feline Med Surg* 2013; 15: 1007–1017.
- 4 Bouyssou S, Hammon GJ and Eivers C. **Comparison of CT features of 79 cats with intranasal mass lesions.** *J Feline Med Surg* 2021; 23: 987–995.
- 5 Hunt GB, Perkins MC, Foster SF, et al. **Nasopharyngeal disorders of dogs and cats: a review and retrospective study.** *Compendium* 2002; 24: 184–200.
- 6 Allen HS, Broussard J and Noone K. **Nasopharyngeal diseases in cats: a retrospective study of 53 cases (1991–1998).** *J Am Anim Hosp Assoc* 1999; 35: 457–461.
- 7 Koch L, Csebi P, Lipnik K, et al. **Pharyngeal dermoid cyst causing partial upper airway obstruction in a cat.** *JFMS Open Rep* 2022; 8. DOI: 10.1177/20551169221122853.
- 8 Quimby J and Lappin M. **Feline focus: update on feline upper respiratory diseases: introduction and diagnostics.** *Compend Contin Educ Vet* 2009; 31: E1–E7.
- 9 Lau WH, Chang WC, Tsuei YS, et al. **Nasopharyngeal gangrenous abscess with skull base extension caused by Escherichia coli after esophageal dilatation for esophageal reconstruction.** *Surg Neurol Int* 2010; 1: 56. DOI: 10.4103/2152-7806.69383.
- 10 Lapeyre M, Coupez E, Ghelis N, et al. **Pharyngeal abscess: a rare complication of repeated nasopharyngeal swabs.** *Intensive Care Med* 2021; 47: 612–613.
- 11 Fitzgerald DC. **Nasopharyngeal abscess and facial paralysis as complications of petrous apicitis: a case report.** *Ear Nose Throat J* 2001; 80: 305–312.
- 12 Lloret A, Egberink H, Addie D, et al. **Pasteurella multocida infection in cats: ABCD guidelines on prevention and management.** *J Feline Med Surg* 2013; 15: 570–572.
- 13 Walker AL, Jang SS and Hirsh DC. **Bacteria associated with pyothorax of dogs and cats: 98 cases (1989–1998).** *J Am Vet Med Assoc* 2000; 216: 359–363.