

## Bilateral monosymptomatic optic neuritis following *Mycoplasma pneumoniae* infection: A case report and literature review

Wei-Yu Chiang, Hsiu-Mei Huang

Herein, we report the clinical findings, treatment choice, and clinical course of a rare case of *Mycoplasma pneumoniae* (*M. pneumoniae*) infection with the sole manifestation of optic neuritis (ON). To the best of our knowledge, this is the first case presenting monosymptomatic visual loss without papillitis, neurological symptoms, and abnormal findings on brain imaging. Related articles about ON after *M. pneumoniae* infection were reviewed to summarize the clinical presentation, possible mechanisms, clinical survey, treatment, and prognosis of this condition. We propose that a *Mycoplasma* profile is necessary in children who present with ON, especially when this condition is accompanied by prodromal symptoms of the respiratory tract infection.

Access this article online

Website:

www.ijo.in

DOI:

10.4103/0301-4738.136236

Quick Response Code:



**Key words:** Bilateral, monosymptomatic optic neuritis, *Mycoplasma pneumoniae*, retro-bulbar optic neuritis

The *Mycoplasma pneumoniae* (*M. pneumoniae*) pathogen can cause atypical pneumonia that is occasionally accompanied by extrapulmonary infections. Ocular manifestations other than conjunctivitis are uncommon.<sup>[1]</sup> *M. pneumoniae* infection with optic neuritis (ON) as the only presentation is relatively rare. We describe the case of an 8-year-old boy who developed monosymptomatic ON following *M. pneumoniae* infection along with the clinical findings, treatment approach, management, and prognosis. In addition, the literature on ocular and central nervous system (CNS) manifestations associated with this pathogen were collected and summarized to provide essential information about such cases.

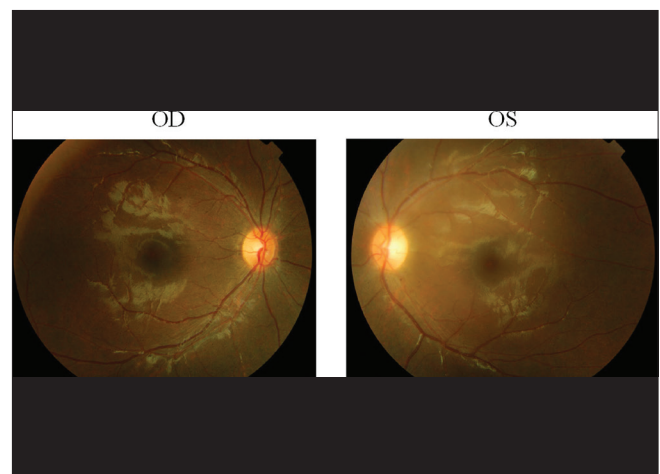
### Case Report

An 8-year-old boy with the underlying condition of prematurity had normal developmental milestones. He presented with sudden onset, profoundly blurred vision (oculus uterque [OU]) accompanied by prodromal symptoms of upper respiratory infection.

Initial ocular examination revealed that his best-corrected visual acuity (BCVA) had deteriorated to light perception only (oculus dexter [OD])/hand motion (HM) at 70-80 cm (oculus sinister [OS]), a fixed and dilated pupil (6.0 mm), and normal fundus appearance [Fig. 1]. Pediatric neurologists did not find neurological symptoms or signs. A visual field (VF) examination could not be performed because of severe visual loss. Optic

coherence tomography [Fig. 2] revealed that the retinal nerve fiber layer thicknesses were within the normal range. The visual evoked potential (VEP) [Fig. 3] showed severe prolonged latency (OU). The brain magnetic resonance image (MRI) did not show a brain lesion nor optic nerve enhancement in the T1-weighted image with contrast. Laboratory analyses revealed a high *Mycoplasma*-IgM titer (+, >75 BU/mL) in his blood, but the glucose (62 mg/dL) and total protein (18.6 mg/dL) levels in his cerebrospinal fluid (CSF) were within normal limits. Based on the profile above, bilateral ON associated with *M. pneumoniae* infection was suspected.

A pulse steroid therapy of intravenous methylprednisolone (750 mg/day) was given for 3 days followed by oral prednisolone (10 mg/day). However, because the BCVA persisted at HM (OU) after the 3-day pulse therapy, an intravenous immunoglobulin (1 g/kg-day) was prescribed for 2 days. After the

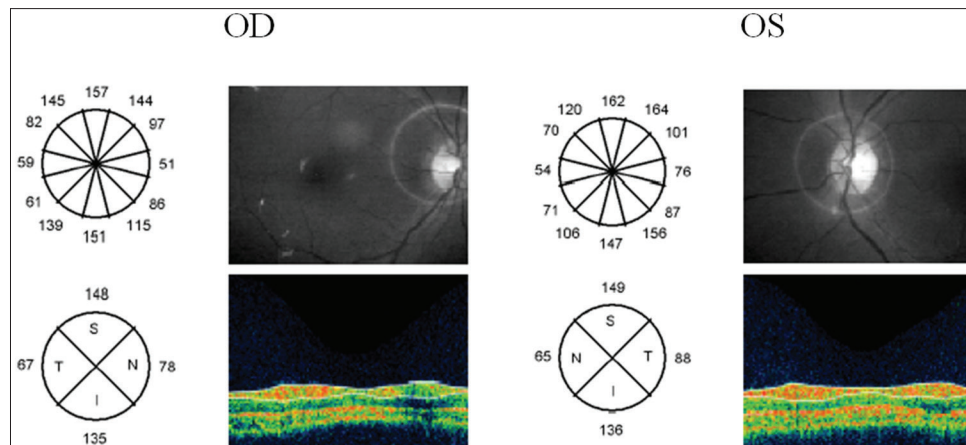


**Figure 1:** Color fundus did not reveal papillitis or an active retinal lesion

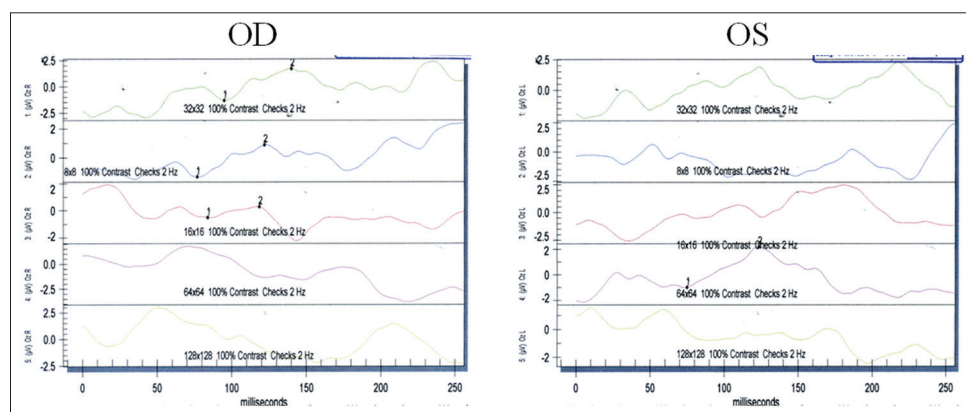
Department of Ophthalmology, Kaohsiung Chang Gung Memorial Hospital and Chang Gung University College of Medicine, Kaohsiung, Taiwan

**Correspondence to:** Dr. Hsiu-Mei Huang, Department of Ophthalmology, No. 123, Dapi Rd., Niasong Dist., Kaohsiung City 83301, Taiwan (R.O.C.). E-mail: sammy1013@adm.cgmh.org.tw

**Manuscript received:** 07.03.13; **Revision accepted:** 03.03.14



**Figure 2:** Disc optical coherence tomography (OCT). Disc OCT revealed normal bilateral disc appearance and nerve fiber layer thickness



**Figure 3:** Visual evoked potential (VEP). Pattern VEP showed a severely prolonged latency and aberrant waves

3-day pulse therapy, the initially fixed and dilated pupil (size, 6.0 mm) responded to light (size, 3.5 mm), but a relative afferent pupillary defect (RAPD) was still noted in the right eye. His BCVA improved to 12/20 (OD), 6/20 (OS) and the VF [Fig. 4a] showed a severely constricted VF with a central tunnel (OD)/inferior arcuate VF defect (OS) 2 weeks after pulse therapy. His visual outcome dramatically improved with a BCVA of 20/20 (OD), 20/20 (OS) and an improved VF result 7 weeks after treatment [Fig. 4b], and these factors improved further at 15 weeks after treatment [Fig. 4c].

## Discussion

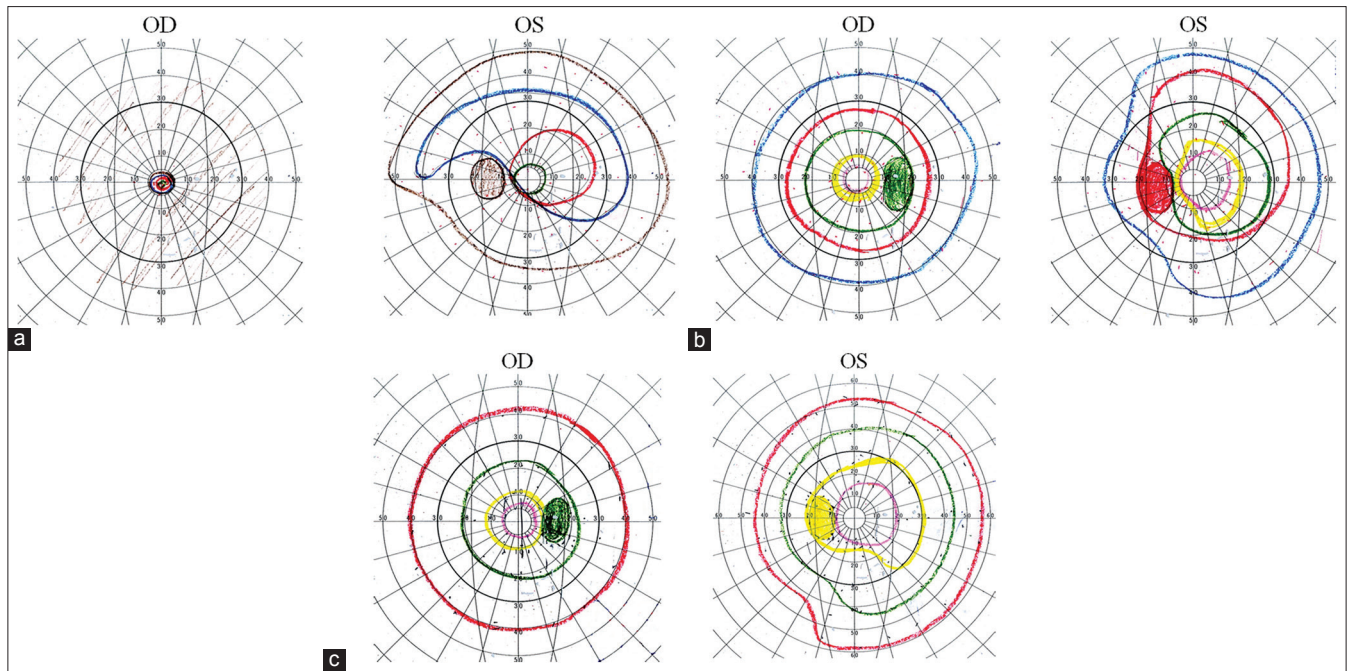
ON, which is strongly associated with multiple sclerosis, infectious causes should be given a high priority in young patients. A review article indicated that specific infectious pathogens such as measles, mumps, chickenpox, rubella, brucella, pertussis, mononucleosis, and Epstein-Barr virus have been reported for pediatric ON; furthermore, this review proposed that postinfectious ON is the result of an autoimmune reaction to the infection.<sup>[2]</sup>

Bilateral involvement with profound visual loss is more common in ON in children than in adults.<sup>[2,3]</sup> Symptoms may include RAPD, headache, eye pain, or bilateral papillitis.<sup>[2,4]</sup> The VEP signal may initially present as an absent or diminished amplitude, with a more abnormal latency than is observed in adults.<sup>[2]</sup>

*M. pneumoniae* is an atypical pathogen that mainly causes respiratory infection and is among the most

important bacterial causes of “atypical” community-acquired pneumonia with overall prevalence of 22.7%.<sup>[5]</sup> However, *M. pneumoniae* is also responsible for extrapulmonary symptoms. The most common extrapulmonary complications of *M. pneumoniae* are neurological,<sup>[6]</sup> such as encephalitis, myelitis, and central white matter disease.<sup>[7]</sup> It may also show ocular involvement such as conjunctivitis, third or sixth nerve palsies, homonymous hemianopia, nystagmus, anterior uveitis, and very rarely, optic neuropathy.<sup>[1]</sup> Although the primary diagnosis of *M. pneumoniae*-associated disease is based on clinical presentation, elevated immunoglobulin titers in the serum are an acceptable diagnostic confirmation in clinical practice.<sup>[6]</sup>

Due to the rare incidence of ON associated with *M. pneumoniae* infection, we reviewed articles about ON after *M. pneumoniae* infection published from 1998 to 2011 [Table 1]. In total, five patients with *M. pneumoniae*-induced ON reported in the available literature.<sup>[1,6-9]</sup> The following characteristics were noted: All cases had prodromal symptoms of respiratory tract infection,<sup>[1,6-9]</sup> only two ON cases occurred in children;<sup>[9,8]</sup> four cases had bilateral profound visual loss<sup>[1,6-8]</sup>, one case had a VF defect of disclosed marked restriction,<sup>[6]</sup> four cases did not have a light reflex;<sup>[6,1,9,8]</sup> three cases had papillitis,<sup>[6,1,9]</sup> and two cases had abnormal MRI findings.<sup>[1,9]</sup> Compared to the patients listed in Table 1, our patient was the first to present with monosymptomatic visual loss without papillitis, neurological symptoms, and an abnormal MRI; furthermore, papillitis is



**Figure 4:** Visual field (VF) after treatment. Initially 2 weeks after treatment (a), a VF defect was noted with a severely constricted VF with a central tunnel (oculus dexter)/inferior arcuate VF defect (oculus sinister). Progressive improvement was noted 7 weeks after treatment (b) and 15 weeks after treatment (c)

**Table 1: Literature review of *M. pneumoniae*-induced optic neuritis with clinical manifestations**

Case report	Age/gender	Ophthalmic symptoms	Neurological symptoms	VA	Pupil/light reflex	Optic disc change	CNS image change
Ginestal <i>et al.</i> <sup>[6]</sup>	69-year-old male	Bilateral visual loss	Frontal headache	OD: 2/70 OS: 2/200	OU: No light reflex	OU: Optic papillitis	Brain MRI: Normal
Milla <i>et al.</i> <sup>[1]</sup>	37-year-old female	Bilateral visual loss, eye pain while moving	Frontal headache	OD: HM OS: LP	OU: Fixed mydriasis, no light reflex	OU: Optic papillitis	Brain MRI: Left periventricular white focal lesion
Bae <i>et al.</i> <sup>[9]</sup>	7-year-old male	Left blurry vision	Sleepy	OS: LP	OS: Sluggish with afferent pupillary defect	OS: Optic papillitis	Brain MRI: Symmetric lesions over putamen, pallidum, thalamus, tegmentum; a lesion on left optic nerve; a lesion on right cerebellum
Candler and Dale, <i>et al.</i> <sup>[8]</sup>	8-year-old male	Bilateral visual loss	Consciousness change, loss of speech	OD: 2/20 OS: CF	OU: Fixed mydriasis, no light reflex	None	Brain MRI: Normal
Pfausler <i>et al.</i> <sup>[7]</sup>	53-year-old male	Bilateral visual loss	Tetraparesis with areflexia, loss of proprioceptive sensitivity	OU: LP(-)	Not mentioned	Not mentioned	Cervial MRI: Normal
Our case	8-year-old male	Bilateral visual loss	None	OD: LP OS: HM	OU: Fixed mydriasis, no light reflex	None	Brain MRI: Normal

*Mycoplasma pneumoniae*, OU: Oculus uterque, OD: Oculus dexter, OS: Oculus sinister, ON: Optic neuritis, VA: Visual acuity, VF: Visual field, CNS: Central nervous system, HM: Hand motion, LP: Light perception, CF: Counting finger, MRI: Magnetic resonance image

the common presentation of ON in children, but our patient presented with retro-bulbar form.

Direct invasion of the CNS and a postinfectious immune response are among the suggested mechanisms of *M. pneumoniae* extrapulmonary complications.<sup>[8]</sup> Another study suggested an autoimmune mechanism because antibodies to myelin and neural tissue have been detected in some cases and

the removal of these antibodies by plasmapheresis ameliorated neurological symptoms.<sup>[7]</sup>

The ON treatment trial<sup>[10]</sup> suggests intravenous administration of methylprednisolone followed by oral prednisolone for a fast recovery and low recurrence, but no effect on final visual outcome. Although the management of ON is well-described in adults, evidence-based, prospective

clinical data on its management and treatment in a pediatric population is scarce.<sup>[4]</sup> The current treatment of pediatric ON, consisting of 3-5 days of intravenous methylprednisolone (4-30 mg/kg·day) followed by oral corticosteroid.<sup>[4]</sup> The alternative treatment includes intravenous administration of immunoglobulin and plasmapheresis while being refractory to corticosteroid. However, the effect of immunomodulation on visual recovery has not been established. As for our patient, improvement could not be recognized as the attribution to steroid or immunoglobulin therapy.

Regarding the prognosis of pediatric ON, visual recovery is excellent in most cases, especially in younger children (<6 years of age).<sup>[3]</sup> In our patient, the clinical course of ON presumably due to *M. pneumoniae* infection was recovery of the pupil response to light 3 days after pulse therapy and an improvement of the VA to the normal range in 7 weeks; however, the VF defect persisted 2 months after ON onset.

## Conclusion

*Mycoplasma* infection-induced monosymptomatic ON is rare. Evaluation of anti-*Mycoplasma* antibodies (IgM and IgG) and a CNS survey (MRI and CSF study) should be performed routinely when ON is suspected, especially in children. Immunomodulatory therapy may be considered after a poor response to methylprednisolone pulse therapy. The visual outcome was favorable in our case with recovery of visual acuity 2 months after treatment.

## References

1. Milla E, Zografos L, Pigué B. Bilateral optic papillitis following *Mycoplasma pneumoniae* pneumonia. *Ophthalmologica* 1998;212:344-6.
2. El-Dairi MA, Ghasia F, Bhatti MT. Pediatric optic neuritis. *Int Ophthalmol Clin* 2012;52:29-49.
3. Brady KM, Brar AS, Lee AG, Coats DK, Paysse EA, Steinkuller PG. Optic neuritis in children: Clinical features and visual outcome. *J AAPOS* 1999;3:98-103.
4. Bonhomme GR, Mitchell EB. Treatment of pediatric optic neuritis. *Curr Treat Options Neurol* 2012;14:93-102.
5. Hardy RD. Infections due to mycoplasmas. In: Longo DL, editor. *Harrison's Principles of Internal Medicine*. 18<sup>th</sup> ed. New York: McGraw-Hill Medical; 2012. p. 1417-20.
6. Ginestal RC, Plaza JF, Callejo JM, Rodríguez-Espinosa N, Fernández-Ruiz LC, Masjuán J. Bilateral optic neuritis and Guillain-Barré syndrome following an acute *Mycoplasma pneumoniae* infection. *J Neurol* 2004;251:767-8.
7. Pfausler B, Engelhardt K, Kampf A, Spiss H, Taferner E, Schmutzhard E. Post-infectious central and peripheral nervous system diseases complicating *Mycoplasma pneumoniae* infection. Report of three cases and review of the literature. *Eur J Neurol* 2002;9:93-6.
8. Candler PM, Dale RC. Three cases of central nervous system complications associated with *Mycoplasma pneumoniae*. *Pediatr Neurol* 2004;31:133-8.
9. Bae JW, Kim HJ, Chang GY, Kim EJ. Combined Striatum, Brain Stem, and Optic Nerve Involvement due to *Mycoplasma pneumoniae* in an Ambulatory Child. *Case Rep Neurol* 2011;3:109-12.
10. Beck RW, Cleary PA, Anderson MM Jr, Keltner JL, Shults WT, Kaufman DI, *et al.* A randomized, controlled trial of corticosteroids in the treatment of acute optic neuritis. The Optic Neuritis Study Group. *N Engl J Med* 1992;326:581-8.

**Cite this article as:** Chiang W, Huang H. Bilateral monosymptomatic optic neuritis following *Mycoplasma pneumoniae* infection: A case report and literature review. *Indian J Ophthalmol* 2014;62:724-7.

**Source of Support:** Nil. **Conflict of Interest:** None declared.