

Intramedullary Tuberculoma of the Conus Medularis in an Immunocompetent Young Adult with no Pulmonary Tuberculosis, the Challenges of Diagnosis and Management: A Case Report and Review of Literature

Abstract

Background and Objective: Intramedullary tuberculoma (IMT) of the conus medullaris is an extremely rare tumour that constitutes a diagnostic and management challenge in a resource-limited setting. We report a case of conus medullaris, IMT in a young immunocompetent, patient with no prior clinical features of pulmonary or extra-pulmonary tuberculosis. **Case Summary:** The patient presented with six months history of progressive and persistent mid back pain and slight weakness of both lower limbs of 3 months duration. Physical examination revealed a well-nourished man with power of 3/5 and hyperreflexia on both lower limbs. Chest radiograph and other investigations for tuberculosis were negative. Magnetic resonance imaging (MRI) of the lumbosacral spine showed fusiform expansion of the conus medullaris, with a well circumscribed, ring enhancing, intramedullary mass straddle between T12 and L1. Patient had gross total resection with no intraoperative monitoring assistance and no post-operative worsening of neurological function. Histology showed granulomatous lesion with central caseation in keeping with a tuberculoma. Patient was commenced on post-operative anti-tuberculous therapy with physiotherapy, with full motor recovery at six months post-surgical intervention and anti-tuberculous therapy. **Conclusion:** Intramedullary tuberculoma can be considered as one of the differential diagnoses of intradural, intramedullary tumour of the conus, even in immunocompetent individual with no clinical features of tuberculosis.

Keywords: *Conus medullaris, intra-medullary, intra-operative monitoring, tuberculoma*

Key Messages: *We present a patient with intramedullary tuberculoma of the conus medullaris in an immunocompetent young patient with no clinical features of pulmonary or extra-pulmonary tuberculosis, who had Gross Total Resection with preserved neurological function.*

Introduction

Tuberculous disease of the central nervous system (CNS) commonly presents as tuberculous meningitis, which is also the most common form of spinal intradural tuberculosis.^[1-5] The occurrence of spinal intramedullary tuberculoma (IMT) is an uncommon disease, with roughly 171 cases having been reported to date, and the most favoured site of IMT is the thoracic spine.^[2,5-8] The condition occurs in relatively young patients and is often associated with extra-spinal tuberculous disease or in immunosuppressed disease state.^[2,5-7] Intramedullary location of conus medullaris tuberculoma is extremely rare, and in immunocompetent patients with no

clinical features or history of tuberculosis, such diagnosis could be difficult, more also that Magnetic resonance imaging (MRI) features of the lesion vary considerably depending on the stage of disease.^[5,9] The rare nature of this disease in the conus medullaris and the lack of specific clinical and imaging features make the pre-operative diagnosis of this benign disease a daunting task, despite its potential for excellent recovery with adequate treatment. This is the drive for continuing awareness of this disease entity, as such, it should be considered among the differential diagnosis of intradural, intramedullary tumour of the conus medullaris, even in immunocompetent individuals with no clinical features of tuberculosis.^[3,6,10]

This is an open access journal, and articles are distributed under the terms of the Creative Commons Attribution-NonCommercial-ShareAlike 4.0 License, which allows others to remix, tweak, and build upon the work non-commercially, as long as appropriate credit is given and the new creations are licensed under the identical terms.

For reprints contact: reprints@medknow.com

How to cite this article: Alfin JD, Akpa PO, Shilong DJ, Bot GM, Nwibo OE, Kyesmen AI, *et al.* Intramedullary tuberculoma of the conus medullaris in an immunocompetent young adult with no pulmonary tuberculosis, the challenges of diagnosis and management: A case report and review of literature. *J West Afr Coll Surg* 2023;13:113-7.

Jeneral Dumura Alfin,
Philip Ojile Akpa¹,
Danaan Joseph Shilong,
Gyang Markus Bot,
Onyemaechi Ereke Nwibo,
Nanapan Isa Kyesmen,
Shina Abidemi Olalere,
Nenkimum Dirting Bakwa,
Innocent Emmanuel¹

*Division of Neurosurgery,
Departments of Surgery,
¹Anatomic Pathology and
Forensic Medicine, Jos
University Teaching Hospital,
Jos, Nigeria*

Received: 19-Sep-2022

Accepted: 19-Dec-2022

Published: 20-Mar-2023

Address for correspondence:

*Dr. Jeneral Dumura Alfin,
Division of Neurosurgery,
Department of Surgery, Jos
University Teaching Hospital,
Jos, Plateau State, Nigeria.
E-mail: jeneralalfin@gmail.com*

Access this article online

Website:

www.jwacs-jcoac.com

DOI: 10.4103/jwas.jwas_201_22

Quick Response Code:



We share our experience of conus medullaris IMT in an immunocompetent young patient who had no clinical features of pulmonary or extra-pulmonary tuberculosis, who had gross total microsurgical excision, with preserved neurological function in a setting with no intra-operative neuro-monitoring (IOM), in order to illustrate the diagnostic dilemmas and management challenges of this potentially curable disease in a resource-limited setting.

Case Summary

The patient is a 28-year-old, male immunocompetent patient, who was referred to the neurosurgery clinic with a 6 months history of progressive and persistent mid back pain, worst at night and a history of slight weakness of both lower limbs of 3 months duration with no clinical history suggestive

of pulmonary or extra-pulmonary tuberculosis. Physical examination revealed a preserved, well-nourished young man with good muscle tone and preserved power on both lower limbs, but has a brisk hyperreflexia. Motor function of the lower limbs deteriorated, while patient was undergoing laboratory and radiological evaluation to power of 3/5 in all muscle groups of both lower limbs. But had preserved sensation, as well as bowel and bladder sphincteric functions.

Plain chest radiograph, complete blood count, mantoux skin test, and erythrocyte sedimentation rate were within normal limits, and not suggestive of tuberculosis. MRI of the lumbosacral spine showed fusiform expansion of the conus medullaris [Figure 1], with a well circumscribed, ring enhancing, intramedullary mass straddle between T12 and L1 [Figure 2].

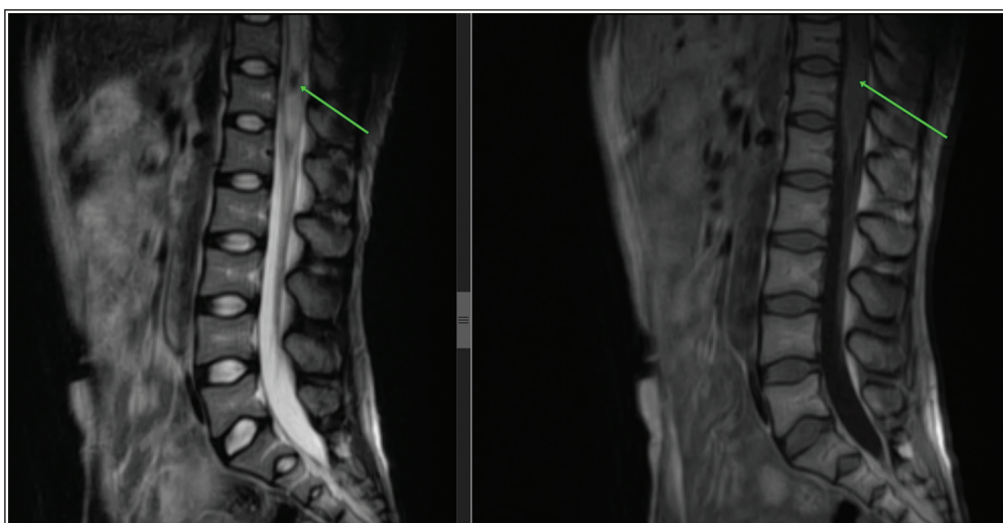


Figure 1: Non contrast, T2 and T1 magnetic resonance imaging of the thoracolumbar spine; showing a hypo-intense lesion straddle between T12 and L1, with surrounding oedema on a mid-sagittal TW2 magnetic resonance imaging, while iso-intense fusiform dilatation of the conus is seen on TW1 magnetic resonance imaging (green arrows)

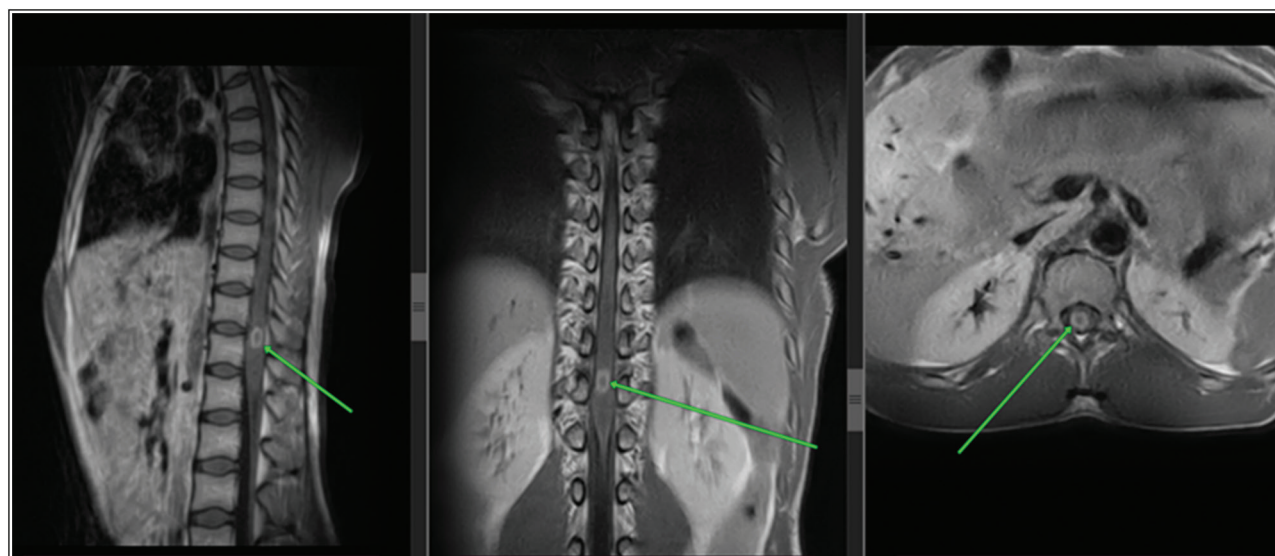


Figure 2: T1 gadolinium-enhanced magnetic resonance imaging of the thoracolumbar spine, showing a well define, ring enhancing, intramedullary mass straddle between T12 and L1 (green arrows)

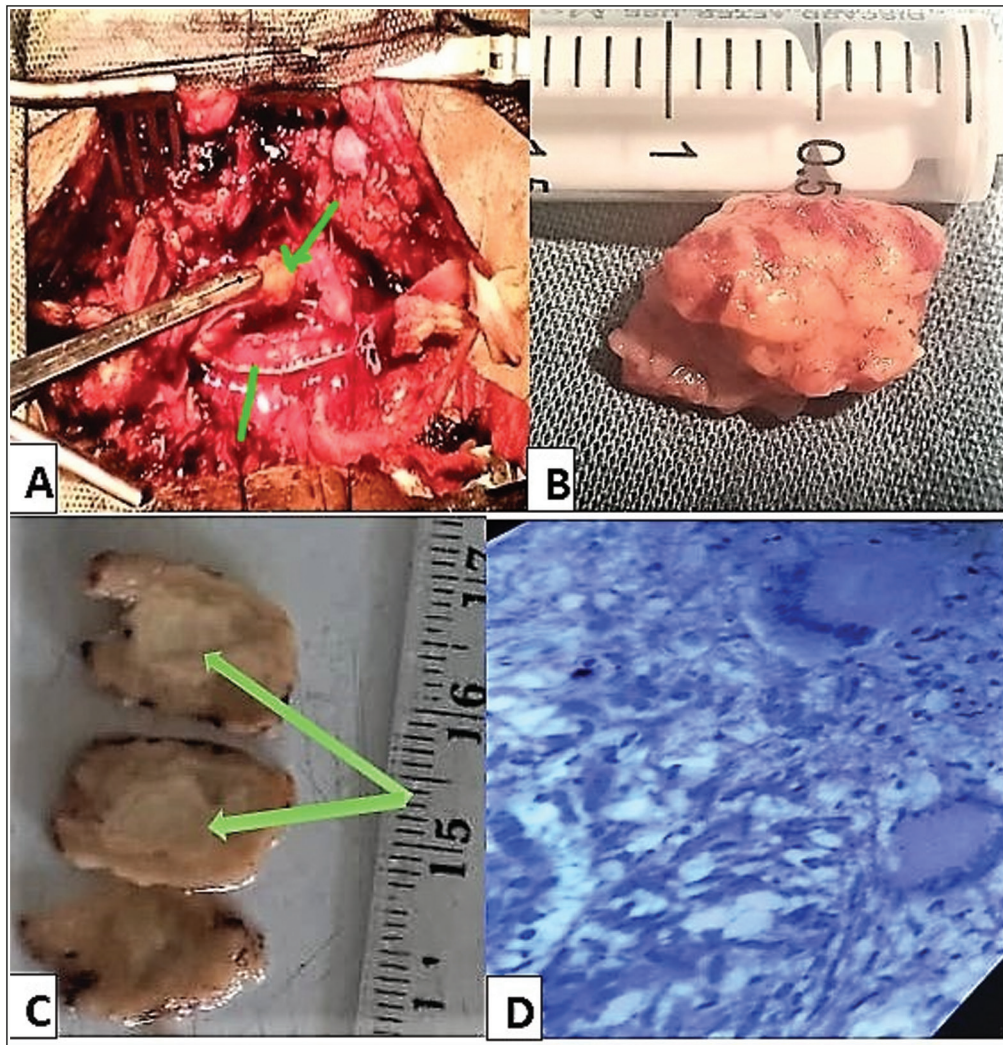


Figure 3: (a) The green arrows above showing tumour and the arrow below showing dura edge on the left. (b) Showing completely excised tumour. (c) Green arrow central area of caseation. (d) Histology showing granulomatous lesion

Patient had complete tumour resection through the dorsal root entry zone after a T12 and L1 laminectomy. Despite the lack of IOM assistance, the patient had no post-operative worsening of neurological function. Histology showed granulomatous lesion with central caseation in keeping with a tuberculoma [Figure 3].

Patient was commenced on immediate post-operative quadruple anti-tuberculous therapy with Rifampin, Isoniazid, Ethambutol, and Pyrazinamide, in the intensive phase for two months. Isoniazid and Rifampicin were continued for additional 10 months, with physiotherapy. At 24 hours post-surgery, his motor function on both lower limbs were 3/5, and at 6 months post-surgery, patient is asymptomatic and power has improved to 5/5 on both lower limbs.

Discussion

Tuberculosis (TB) constitutes a global health threat, and Nigeria is among the countries with a high TB, TB/HIV

and DR-TB burden globally, with an estimated 460,000 cases of tuberculosis occurring annually in the country.^[11] CNS involvement results from haematogenous spread from a primary focus, commonly, the lungs, and only about 0.5–2% of patients with extra-pulmonary TB have CNS involvement.^[3,4,12,13]

Cranial tuberculous meningitis, intracranial tuberculomas, and Pott's disease are the most frequent forms of CNS TB, with tuberculous spondylitis and arachnoiditis being the most common forms seen in the spine.^[1,2,7] The brain, to spinal cord involvement ratio is approximately 42.3:1, and correlates very well to brain and spinal cord weight ratio, and their blood supplementation ratio as well.^[4,12-14] The presence of isolated spinal intramedullary tuberculomas (IMT), without corresponding bony and meningeal involvement is very rare, right from when it was first reported by Abercrombie in 1828, there are only about 171 cases in the literature to date and mostly involves the thoracic spinal cord.^[2,5-8] However, intramedullary

tuberculoma of the conus medullaris is extremely rare, with only about 15 cases reported to date in the English literature to the best of our knowledge, and none reported in our country.^[1-4,12,15-24]

Making a clinical diagnosis of conus medullaris IMT, based on the patient's symptoms is very difficult, because of the varied presentation from the different case report in the literature, as a result a high index of suspicion is required to consider IMT as a differential of conus medullaris tumour.^[1-4,12,15-24] Just as it is, in the index patient, where it was difficult to make a clinical diagnosis. Earlier publications and review of literatures, reported that the clinical presentations of these disease, are not distinct from those of any other intramedullary mass lesion of the conus medullaris, thus making a clinical diagnosis a major challenge.^[2,25] Although associated past, or concurrent history of tuberculosis, HIV or other malignancy elsewhere in the body was reported in more than half of patients in the review by Chotmongkol *et al.*, and other authors reported similar findings where patients with IMT had previously suffered from tuberculous meningitis.^[2,4,14,26,27] Our patient was a well-nourished, young adult, with no comorbidities or previous history of exposure to TB, this makes it difficult to consider IMT a possible cause of his neurological fall out.

In these circumstances, MRI is the optimal method of investigation, as it is both sensitive and noninvasive.^[2] The MRI appearance of IMT was first described by Rhoton *et al.*, and further descriptions of the MRI features of this lesion, with the different stages of the tuberculoma formation (noncaseating, caseating with a solid centre, and caseating with a liquid centre) were published by numerous authors.^[4,10,13,14,28] The MRI appearance in our patient was suggestive of a solid caseating tuberculoma which appeared as iso-intense on T1-weighted imaging, with hypointense centre on T2-weighted image [Figure 1]. However, these findings on MRI are not pathognomonic of IMT especially in the conus medullaris, and in most of these literatures, the diagnosis of IMT was made histopathologically after biopsy or resection of the lesion.^[2,4,10,13,14,28] Several other diagnostic adjunct have been used to diagnose tuberculous infection of the CNS; acid fast bacillus staining and cerebro spinal fluid culture, deoxyribonucleic acid genomic amplification using the polymerase chain reaction, high levels of cerebro spinal fluid adenosine deaminase, the presence of extraneural tuberculosis foci elsewhere in the body, and responsiveness to antituberculous therapy.^[2,29-31] But none of these investigations are specific enough for establishing or confirming the diagnosis of spinal tuberculosis, non the less, a conus medullaris IMT.

There are no established guidelines or consensus on the medical and surgical protocols to be employed in the management of spinal IMT. Medical therapy, using the combination of; isoniazid, rifampicin, pyrazinamide, and ethambutol or streptomycin in the intensive phase

(two to three months), followed by a combination of isoniazid and rifampicin in the continuation phase 10 to 16 months remains the mainstay of treatment of CNS tuberculomas generally. This also applies to IMT's if the diagnosis can be made before surgical intervention, and several authors have shown that patients managed with medical therapy alone had significant improvement or full recovery.^[2,3,12,15-17,19,20,22] Surgical biopsy or excision is necessary to confirm the diagnosis and extirpate the IMT, when clinical or radiological diagnosis is uncertain, or where there is poor response to medical management with progressive neurological deterioration during medical treatment, or enlargement of the lesions with mass effect on a follow-up MRI.^[2,4,19,32]

In our patient, clinical and radiological diagnoses were a challenge, being a young patient with no immunosuppression, no previous or current history of tuberculosis, with supportive investigation not suggestive of TB, and the patient having progressive neurological deterioration. We had no option but to embark on surgical excision. And despite not having intraoperative monitoring, which is recommended for excision of spinal intramedullary tumours, we used a low current bipolar diathermy without intraoperative paralysis of the patient, employing the principles of meticulous microsurgical dissection, we had a complete excision of the lesion (Figure 3). Our patient made a good recovery, with no new neurological deficit at 24 hours post operatively, with complete return of power and function at six months of follow-up and antituberculous medications.

Conclusion

Tuberculoma of the conus medullaris is a rare tumour; however, it should be considered as a differential diagnosis of intramedullary tumours even in patients with no significant risk for tuberculosis. Complete surgical resection, with good outcome is possible, when meticulous microsurgical dissection and preservation of neural element are done, especially in the setting with no IOM.

Acknowledgements

Our sincere appreciation to Dr OP Binitie and Prof BT Ugwu for their fatherly counsel and guide in the preparation of this manuscript.

Financial support and sponsorship

Nil.

Conflicts of interest

There are no conflicts of interest.

References

1. Suzer T, Coskun E, Tahta K, Bayramoğglu H, Düzcan E. Intramedullary spinal tuberculoma presenting as a conus tumor: A case report and review of the literature. *Eur Spine J* 1998;7:168-71.

2. Chotmongkol V, Wanitpongpun C, Phuttharak W, Khamsai S. Intramedullary conus medullaris tuberculoma: a case report and review of the literature. *Infect Dis Rep* 2021;13:82-8.
3. Dehoux E, Awada A, Palkar V. Urinary retention revealing a tuberculoma of the conus medullaris in a patient with intracranial tuberculoma: Case report. *Spinal Cord* 1996;34:630-2.
4. Kemaloglu S, Gur A, Nas K, Cevik R, Buyukbayram H, Saraç A. Intramedullary tuberculoma of the conus medullaris: Case report and review of the literature. *Spinal Cord* 2001;39:498-501.
5. Yusuf AS, Adeleke NA, Babalola OM, Wahab KW, Oyebanji LO, Ahmed AB, *et al.* Intramedullary tuberculoma of thoracic spinal cord in an apparently healthy Nigerian: Case report. *J West Afr Coll Surg* 2015;5:90-7.
6. MacDonell AH, Baird RW, Bronze MS. Intramedullary tuberculomas of the spinal cord: Case report and review. *Rev Infect Dis* 1990;12:432-9.
7. Sharma MC, Arora R, Deol PS, Mahapatra AK, Sinha AK, Sarkar C. Intramedullary tuberculoma of the spinal cord: A series of 10 cases. *Clin Neurol Neurosurg* 2002;104:279-84.
8. Ju HB, Guo DM, Chen FF. Intramedullary cervical tuberculoma: A case report with note on surgical management. *Int Surg* 2015;100:133-6.
9. Thirunavukarasu SC, Ramachandrappa A. A rare case of intramedullary tuberculoma: Complete resolution after medical treatment and role of magnetic resonance imaging in diagnosis and follow-up. *Asian J Neurosurg* 2012;7:223-6.
10. Ratliff JK, Connolly ES. Intramedullary tuberculoma of the spinal cord case report and review of the literature. *J Neurosurg Spine* 1999;90:125-8.
11. Federal Ministry of Health Nigeria (FMoH). National Tuberculosis Catastrophic Cost Survey: Report of the National Survey to Determine the Proportion of TB Patients and their Households Experiencing Catastrophic Cost due to TB. 2017 Nigeria: Abuja; 2017.
12. Choksey MS. A conus tuberculoma mimicking an intramedullary tumor: A case report and review of the literature. *Br J Neurosurg* 1989;3:117-22.
13. Rhoton EL. Intramedullary spinal tuberculoma. *Neurosurgery* 1988;22:733-6.
14. Citow JS. Intramedullary tuberculoma of the spinal cord: Case report. *Neurosurgery* 1994;35:327-30.
15. Bradbury PG, Davis CJF. Conus tuberculoma responding to chemotherapy. *Ann Neurol* 1980;7:392-3.
16. Sie LT, Linssen WH. Isolated intramedullary tuberculosis presenting as a conus tumor. *Clin Infect Dis* 1994;19:549-50.
17. Parmar H, Shah J, Patkar D, Varma R. Intramedullary tuberculomas. MR findings in seven patients. *Acta Radiol* 2000;41:572-7.
18. Tureyen K. Tuberculoma of the conus medullaris: Case report. *Neurosurgery* 2002;50:651-3.
19. Jaiswal AK, Jaiswal S, Gupta SK, Gautam VKS, Kumar S. Intramedullary tuberculoma of the conus. *J Clin Neurosci* 2006;1:870-2.
20. Skoglund TS, Nilsson D. Tumor of the conus medullaris treated with antituberculous therapy. *Clin Neurol Neurosurg* 2007;109:192-4.
21. Maamar M, El Quessar A, El Fatemi N, El Hassani MR, Chakir N, Jiddane M. Intramedullary tuberculoma: A case report. *Radiography* 2007;13:251-4.
22. Lawler M, Zulu S, Archary M, Govender V. Intramedullary conus medullaris tuberculoma in an HIV-infected child: An unusual immune reconstitution inflammatory syndrome response. *S Afr J Epidemiol Infect* 2013;2:69-71.
23. Sharoff LM, Unnikrishnan R, Jagani N. Isolated conus medullaris tuberculoma mimicking a tumor: A rare case report. *ANZ J Surg* 2017;87:E218-9.
24. Jaiswal M, Gandhi A, Purohit D, Mittal RS. Concurrent multiple intracranial and intramedullary conus tuberculoma: A rare case report. *Asian J Neurosurg* 2017;12:331-3.
25. Ebner FH, Roser F, Acioly MA, Schoeber W, Tatagiba M. Intramedullary lesions of the conus medullaris: Differential diagnosis and surgical management. *Neurosurg Rev* 2009;32:287-300.
26. Compton JS, Dorsch NWC. Intradural extramedullary tuberculoma of cervical spine. Case report. *J Neurosurg* 1984;60:200-3.
27. Kalita J, Mistra UK. Intramedullary cervical tuberculoma. *Spinal Cord* 1999;37:297-8.
28. Trivedi R, Saksena S, Gupta RK. Magnetic resonance imaging in central nervous system tuberculosis. *Indian J Radiol Imag* 2009;19:256-65.
29. Feres MC, Martino MCD, Maldijian S, Batista F, Gabriel Júnior A, Tufik S. Laboratorial validation of an automated assay for the determination of adenosine deaminase activity in pleural fluid and cerebrospinal fluid. *J Bras Pneumol* 2008;34:1033-9.
30. Perry MD, White PL, Ruddy M. Potential for use of the Seegene Anyplex MTB/NTM real-time detection assay in a regional reference laboratory. *J Clin Microbiol* 2014;52:1708-10.
31. Parny IF, Johnson ES, Allen PB. "Idiopathic" cranial hypertrophic pachymeningitis responsive to antituberculous therapy: Case report. *Neurosurgery* 1997;41:965-71.
32. Li H, You C, Yang Y, He M, Cai B, Wang X, *et al.* Intramedullary spinal tuberculoma: Report of three cases. *Surg Neurol* 2006;65:185-8.