

A Case of Tyrosinemia Type III with Status Epilepticus and Mental Retardation

Abstract

Tyrosinemia type III is an autosomal recessive disorder caused by the deficiency of 4-hydroxyphenylpyruvate dioxygenase (4-HPPD). It is characterized by elevated levels of blood tyrosine and massive excretion of its derivatives into the urine. Clinical findings of tyrosinemia type III include neurological symptoms and mental retardation. Only a few patients presenting with this disease have been described, and the clinical phenotype remains variable and unclear. We present a case, who was admitted to the hospital at the age of 4 months for recurrent seizures. Two months later, she was admitted again with status epilepticus. Laboratory data showed increased level of tyrosine in the blood. She was treated with a diet low in tyrosine and phenylalanine and anamix formula that leading to catch-up growth and improvement of her symptoms. Plasma tyrosine level dropped to normal values. In any child who presents with the neurologic symptom, some rare diagnosis like tyrosinemia type III should be considered.

Keywords: Mental retardation, status epilepticus, tyrosinemia type III

Introduction

Tyrosinemia type III is a rare disorder. Only a few patients have been described. Tyrosine is a precursor of dopamine, norepinephrine, epinephrine, melanin, and thyroxine.^[1] This autosomal recessive disease is caused by the deficiency of 4-hydroxyphenylpyruvate dioxygenase^[2-4] that is mainly expressed in neurons, neutrophils, kidney, and liver cells.^[5] It catalyzes the reaction of 4-hydroxyphenylpyruvic acid to homogentisic acid [Figure 1].^[6,7]

The disease is characterized by increased level of blood tyrosine and massive excretion of its derivatives into the urine.^[8] Excessive NO release can also participate in neuronal damage.^[2] Age of presentation is from 1 to 17 months.^[1] The clinical phenotype remains variable and unclear.^[5]

Neurological symptoms include developmental delay, behavioral disturbance, seizures, microcephaly, ataxia, tremor, hypotonia, absent deep tendon reflexes,^[2,5,9,10] here, we present a case of tyrosinemia type III with status epilepticus.

Case Report

This patient was a 21-month-old girl, who was born at term with birth weight 2250 g

This is an open access article distributed under the terms of the Creative Commons Attribution-NonCommercial-ShareAlike 3.0 License, which allows others to remix, tweak, and build upon the work non-commercially, as long as the author is credited and the new creations are licensed under the identical terms.

For reprints contact: reprints@medknow.com

and head circumference 33 cm following a pregnancy with polyhydramnios. The patient had no perinatal problem. She was the second child of No consanguineous parents. The first sibling was a 4-year-old boy who is healthy and normally developed. She was admitted to Pediatric Emergency Department at 4 months of age for recurrent seizure. Two months later she was admitted again with status epilepticus. Her seizure controlled with antiepileptic drugs. We did not find any reason for status epilepticus in routine lab tests, cerebrospinal fluid analysis; brain computed tomography scan, brain magnetic resonance imaging, and blood gas analysis. All of them were normal.

Metabolic investigations showed increased level of tyrosine in the blood (737 $\mu\text{mol/l}$ and 915 $\mu\text{mol/l}$) in 2 consecutive time, (normal range 88–204 $\mu\text{mol/l}$). The levels of 4-hydroxyphenyl lactic acid (1710 mmol/mol creatinine with normal <5.3) and 4-hydroxyphenyl pyruvic acid (2184 mmol/mol creatinine with normal <4.9) in the urine were elevated, without marked elevation of succinylacetone. Kidney and liver functions were normal. Clinical findings and biological abnormalities were suggestive of tyrosinemia type III and were treated with

How to cite this article: Najafi R, Mostofizadeh N, Hashemipour M. A Case of Tyrosinemia Type III with Status Epilepticus and Mental Retardation. *Adv Biomed Res* 2018;7:7.

Received: February, 2015. **Accepted:** April, 2015.

Reza Najafi^{1,2},
Neda Mostofizadeh³,
Mahin
Hashemipour⁴

From the ¹Department of Pediatric Endocrinology and Metabolism, Ilam University of Medical Sciences, Ilam, ²Endocrine and Metabolism Research Center, University of Medical Sciences, ³Department of Pediatric Endocrinology, Endocrine and Metabolism Research Center, ⁴Child Growth and Development Research Center, Isfahan University of Medical Sciences, Isfahan, Iran

Address for correspondence:
Dr. Neda Mostofizadeh,
Endocrine and Metabolism
Research Center, Isfahan
University of Medical Sciences,
Isfahan, Iran.
E-mail: nmostofizadeh@yahoo.com

Access this article online

Website: www.advbiores.net

DOI: 10.4103/2277-9175.223740

Quick Response Code:



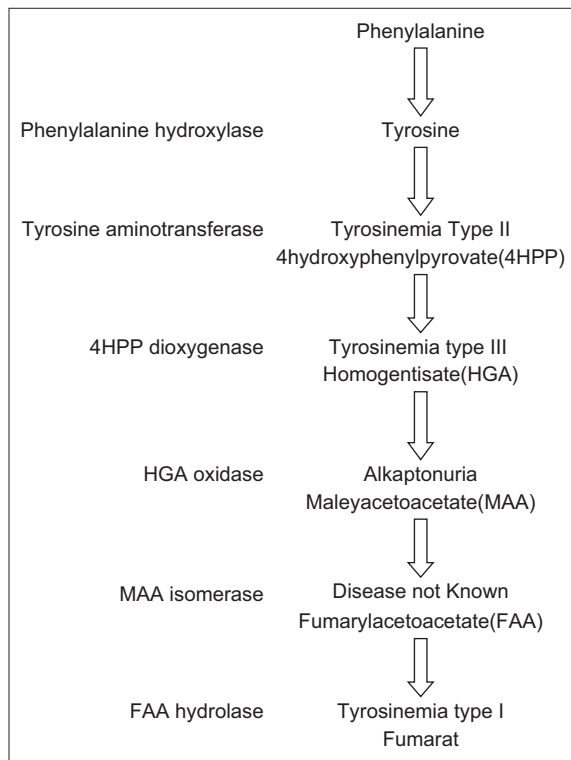


Figure 1: Tyrosine metabolism pathway

a diet low in tyrosine, phenylalanine, and anamix formula plus ascorbic acid supplementation (50 mg/day in two doses) that leading to catch-up growth and improvement of her symptoms. Plasma tyrosine level dropped to normal values. Now her mental status is mildly delayed.

Discussion

To our knowledge, only a few patients presenting with this disease have been described in the literature, and none of them presented with status epilepticus.

Most of the reported patients have had neurological symptoms after the neonatal period while others detected by neonatal screening have been asymptomatic. Like our patient all have had normal liver and renal function and none has skin or eye abnormalities.^[11]

The most common long-term complication is intellectual impairment, found in 75% of patients. In 2008, a patient with tyrosinemia type III was described with autism and mental retardation.^[11] Mild hypertyrosinemia may be offered as typical clinical features of the disease.^[8]

Asymptomatic infants with 4-HPPD deficiency have been identified by neonatal screening for hypertyrosinemia.^[1] Our patient presented with seizure and status epilepticus, and neurological abnormalities. Similar to our patient Endo *et al.* reported a patient with seizure, mental retardation, and neurological abnormalities. In another study, Cerone *et al.* reported a patient with intermittent ataxia.^[3]

The high tyrosine concentration in an otherwise normal amino acid profile has been found in patients presenting with neurological symptoms.^[12]

The diagnosis is suspected in children with sustained moderate increases in plasma levels of tyrosine (typically 350–700 $\mu\text{mole/L}$ on a normal diet) and massive excretion of its derivatives, 4-hydroxyphenyl pyruvic acid, 4-hydroxyphenyl lactic, and 4-hydroxyphenyl acetic acid into in urine.^[1] One of the important factors for definitive diagnosis is genetic study or assay the activity of a 4-HPPD enzyme in liver biopsy.^[1] That is what we could not do it and can be a limitation of our study.

In 2001 on a review of 13 patients, five were detected by neonatal screening, two of which were free of any symptoms, with a normal development at 13 months, and 5.4 years, respectively, following a low tyrosine and phenylalanine diet; the three other patients showed mild intellectual impairment. Eight out of 13 patients were diagnosed after the neonatal period because of neurologic signs, that one of them showing a normal development at the age of 17 years,^[13] in contrast to our patient that the first neurological signs were started at 4 months of age. Clinical and biochemical findings in patients with a 4-HPPD deficiency in previous and present studies illustrated in Table 1.

In favor of our patient long-term treatment with a tyrosine-restricted diet led to control of seizure disorder.

In the last reported cases, improvement of signs, symptoms, and psychomotor function were observed with a restricted diet.^[5] However, D'Eufemia *et al.* reported that their patient showed normal psychomotor development and no clinical signs in spite of a normal diet.^[2]

In our patient, mild mental retardation remained, similar to the reported case by Heylen *et al.*^[5] Their patient's language skills and autistic behavior improved by using a tyrosine-restricted diet while no changes were made in the mental retardation.^[5]

The effects of therapeutic interventions by using a low-protein diet are still unknown, and it is not yet clear whether lowering plasma tyrosine levels is able to alter the natural history of the disease in spite of this fact that it is recommended to treat these patients with a tyrosine- and phenylalanine-restricted diet.^[5]

As treatment with 2-(2-nitro-4-trifluoromethylbenzoyl)-1,3-cyclohexanedione (NTBC) in patients with tyrosinemia type I shifts the metabolic block from fumarylacetoacetate hydrolase to p-hydroxyphenylpyruvate dioxygenase or from tyrosinemia type I to tyrosinemia type III, treatment with NTBC must be supplemented by dietary treatment with a phenylalanine- and tyrosine-reduced diet, which is the rational approach to treatment in tyrosinemias type II and III.^[14] NTBC do not approve for the treatment of

Table 1: Clinical and biochemical findings in patients with 4-HPPD deficiency

Studies	Endo <i>et al.</i> ^[8]	Giardini <i>et al.</i> ^[10]	Preece <i>et al.</i> ^[15]	Cerone <i>et al.</i> ^[3]	Heylen <i>et al.</i> ^[5]	Present case
Clinical and biochemical findings						
Sex	Male	Female	Female	Male	Male	Female
First symptom (months)	1	17	8	8	Neonatal screening	4
Neurological abnormalities	Seizures	Intermittent ataxia	No	Abnormal behavior	Neonatal screening	Status epilepticus
Mental retardation	Not reported	No	Yes	Yes	No	Yes
Liver dysfunction	No	No	No	No	No	No
Metabolic acidosis	No	No	No	No	No	No
Eye skin lesions	No	No	No	No	No	No
Plasma tyrosinemia	640	624	355–520	532	398–665	737–915
Phenolic aciduria	Yes	Yes	Yes	Yes	Yes	Yes
4-HPPD activity	5%	Undetectable	Low	Very low	-	-
Follow-up	Accident death	Alive	Alive-well	Alive-retarded	Alive-well	Alive-mildly retarded

4-HPPD: 4- Hydroxyphenylpyruvate dioxygenase

tyrosinemia type III, for this reason, we did not apply it in our patient.

Declaration of patient consent

The authors certify that they have obtained all appropriate patient consent forms. In the form the patient(s) has/have given his/her/their consent for his/her/their images and other clinical information to be reported in the journal. The patients understand that their names and initials will not be published and due efforts will be made to conceal their identity, but anonymity cannot be guaranteed.

Financial support and sponsorship

Nil.

Conflicts of interest

There are no conflicts of interest.

References

- Grant A, Rezvani I. Tyrosinemia. In: Kliegman RM, Behrman RE, Genson HB, Stanton BF, editors. Nelson Textbook of Pediatrics. 19th ed. Philadelphia: Saunders; 2011.
- D'Eufemia P, Finocchiaro R, Celli M, Raccio I, Properzi E, Zicari A. Increased nitric oxide release by neutrophils of a patient with tyrosinemia type III. *Biomed Pharmacother* 2009;63:359-61.
- Cerone R, Holme E, Schiaffi no MC, Caruso U, Maritano L, Romano C. Tyrosinemia type III: Diagnosis and ten-year follow-up. *Acta Paediatr* 1997;86:1013-5.
- Scott CR. The genetic tyrosinemias. *Am J Med Genet C Semin Med Genet* 2006;142C:121-6.
- Heylen E, Scherer G, Vincent MF, Marie S, Fischer J, Nassogne MC.

- Tyrosinemia Type III detected via neonatal screening: Management and outcome. *Mol Genet Metab* 2012;107:605-7.
- Lindstedt S, Holme E, Lock EA, Hjalmarson O, Strandvik B. Treatment of hereditary tyrosinaemia type I by inhibition of 4-hydroxyphenylpyruvate dioxygenase. *Lancet* 1992;340:813-7.
- Nakamura K, Tanaka Y, Mitsubuchi H, Endo F. Animal models of tyrosinemia. *J Nutr* 2007;137:1556S-60.
- Endo F, Kitano A, Uehara I, Nagata N, Matsuda I, Shinka T, *et al.* Four-hydroxyphenylpyruvic acid oxidase deficiency with normal fumarylacetoacetase: A new variant form of hereditary hypertyrosinemia. *Pediatr Res* 1983;17:92-6.
- Awata H, Endo F, Matsuda I. Structure of the human 4-hydroxyphenylpyruvic acid dioxygenase gene (HPD). *Genomics* 1994;23:534-9.
- Giardini O, Cantani A, Kennaway NG, D'Eufemia P. Chronic tyrosinemia associated with 4-hydroxyphenylpyruvate dioxygenase deficiency with acute intermittent ataxia and without visceral and bone involvement. *Pediatr Res* 1983;17:25-9.
- Ellaway CJ, Holme E, Standing S, Preece MA, Green A, Ploechl E, *et al.* Outcome of tyrosinaemia type III. *J Inher Metab Dis* 2001;24:824-32.
- Holme E. Disorders of tyrosine degradation. In: Blau N, Duran M, Blaskovics M, Gibson K, editors. *Physician's Guide to the Laboratory Diagnosis of Metabolic Diseases*. 2nd ed. Berlin: Chapman and Hall; 1996.
- Tahiroglu AY, Mungan NÖ, Firat S, Avci A. Autism symptoms related to tyrosinaemia type III: A case report. *Turk J Endocrinol Metab* 2008;12:55-6.
- Hoffmann GF, Engelmann G. Liver disease. In: Hoffmann F, Zschocke J, Nyhan W, editors. *Inherited Metabolic Diseases, A Clinical Approach*. Heidelberg: Springer; 2010.
- Preece MA, Rylance GW, MacDonald A, Green A, Gray RGF. A new case of tyrosinemia type III detected by neonatal screening. *J Inher Metab Dis* 1996;19 Suppl 1:32.