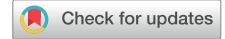

Acute Interstitial Nephritis in Tuberculosis-Associated Immune Reconstitution Inflammatory Syndrome



Claudia L. Do Vale¹, Saraladevi Naicker² and Christopher K. Lippincott³

¹Department of Nephrology, Mediclinic Morningside, Johannesburg, South Africa; ²Department of Internal Medicine, University of the Witwatersrand, Johannesburg, South Africa; and ³Division of Infectious Diseases, Department of Medicine, The Johns Hopkins University School of Medicine, Baltimore, Maryland, USA

Correspondence: Claudia Do Vale, Department of Nephrology, Mediclinic Morningside, Corner Hill and Rivonia Road, Morningside, Johannesburg, Gauteng, South Africa 2057. E-mail: cdovale@mwebbiz.co.za; or Christopher Lippincott, The Johns Hopkins Hospital, 600 North Wolfe Street Carnegie Building #338, Baltimore, Maryland 21287, USA. E-mail: christopher.lippincott@jhmi.edu

Received 5 September 2021; revised 30 November 2021; accepted 6 December 2021; published online 13 December 2021

Kidney Int Rep (2022) 7, 920–923; <https://doi.org/10.1016/j.ekir.2021.12.008>

© 2021 International Society of Nephrology. Published by Elsevier Inc. This is an open access article under the CC BY-NC-ND license (<http://creativecommons.org/licenses/by-nc-nd/4.0/>).

INTRODUCTION

Acute kidney injury (AKI) in hospitalized individuals is associated with increased length of hospitalization and mortality.^{1,2} The high burden of HIV infection in South Africa (adult prevalence rate of 19.1%)³ may be complicated by AKI, where HIV-infected patients have an increased incidence of AKI compared with HIV-uninfected patients.² HIV infection and AKI in South Africa are likely further complicated by the high burden of tuberculosis (TB) (615 per 100,000 population).⁴ In a South African cohort, 26% of HIV-infected patients presenting with AKI were coinfecting with TB compared with 2% in the uninfected group.¹ The high HIV-TB coinfection rates in South Africa (58% among incident TB cases)⁴ increase the risk of disseminated TB, including urogenital TB.⁵

TB-immune reconstitution inflammatory syndrome (TB-IRIS) contributes to 87% of deaths in the first 3 months after combination antiretroviral therapy (cART) initiation in South Africa.⁶ In HIV-infected patients with recently or undiagnosed TB, *Mycobacterium tuberculosis* (MTB) infection and IRIS can manifest as AKI directly, as seen in urogenital TB, or indirectly, as seen in IRIS. Urogenital TB is a chronic infection of the kidneys, urinary tract, and genital tract by MTB, with the kidneys the primary infection site.⁷ Diagnosis is often delayed owing to nonspecific symptoms, insidious progression, and lack of physician awareness.⁷ Urogenital TB in HIV-infected individuals may manifest dramatically as IRIS, a complication of cART with inflammatory-mediated organ dysfunction secondary to the restoration of a

pathogen-specific immune response.^{8,9,S1–S3} Acute interstitial nephritis in TB-IRIS has been rarely described in the literature and previously never reported in Africa.⁹ We present 8 patients with HIV-TB coinfection who presented with IRIS and AKI secondary to TB-IRIS in Johannesburg, South Africa, the largest case series to date.

CASE PRESENTATION

All 8 patients lived within the greater Johannesburg area and presented for hospital admission from October 1, 2013, to January 31, 2015. Seven patients were evaluated at Helen Joseph Hospital, with 1 case admitted to Charlotte Maxeke Johannesburg Academic Hospital. All patients presented for hospital admission within 3 months of cART initiation (median [interquartile range (IQR)] = 27 [17–49] days). The median (IQR) age was 36 (36–38) years, and 5 patients (62.5%) were male. All were initiated on tenofovir, emtricitabine, and efavirenz as a fixed-dose combination tablet. At initiation of treatment, 7 patients had normal serum creatinine with a normal estimated glomerular filtration rate. One patient had an estimated glomerular filtration rate between 30 and 40 ml/min per 1.73 m². The median (IQR) baseline CD4 T-cell (CD4) count was 38 (23–69) cells/mm³ (Table 1).

All patients presented with nonspecific clinical symptoms such as dyspnea, generalized body weakness and vomiting. Three patients were encephalopathic, and 6 patients had a severe high anion gap metabolic acidosis. Physical examination was unremarkable in all but 1 patient, who demonstrated cervical, axillary, and

Table 1. Demographics, laboratory, and kidney biopsy results of the patients

Case number	1	2	3	4	5	6	7	8
Sex	Male	Male	Male	Male	Female	Female	Male	Female
Age	39	37	33	36	44	36	36	36
Original CD4 (cells/mm ³)	96	23	60	29	23	94	47	2
Admission CD4 (cells/mm ³)	164	129	74	71	Not done	203	32	74
Days on cART regimen	27	69	42	17	26	14	8	114
Admission viral load (copies/ml)	1931	11,449	Not done	72,087	<40	Not done	Not done	26
CRP (mg/l)	89	257	204	245	160	48	100	129
Baseline creatinine (μmol/l)	82	57	75	54	91	174	90	60
Baseline creatinine (mg/dl)	0.93	0.65	0.85	0.61	1.03	1.97	1.02	0.68
Admission creatinine (μmol/l)	1136	1182	1370	1097	2169	821	429	264
Admission creatinine (mg/dl)	12.85	13.37	15.50	12.41	24.54	9.29	4.85	2.99
Urine PCR (g/mmol creatinine)	0.621	0.08	0.467	0.161	0.313	0.25	0.09	Not done
Urine leucocytes	90,000	6000	63,000	13,000	3000	750,000	10,800	4,000
Urine erythrocytes	90,000	0	43,000	4000	1000	0	216,000	scanty
Urine culture	<i>E coli</i>	Nil	Nil	Nil	Nil	<i>C. freundii</i>	<i>E. coli</i>	Nil
Urine LAM	+	Not done	–	–	Not done	Not done	Not done	Not done
Sputum Xpert MTB/RIF	+	+	–	+	+	+	+	–
Bone marrow	MTB	Not done	Not done	MTB	Not done	Not done	Not done	Not done
TB blood culture	–	Not done	MTB	MTB	MAC	Not done	–	Not done
FNA:TB culture	Not done	Not done	Not done	Not done	Not done	Not done	+	Not done
Kidney biopsy	GIN	Not done	Not done	Not done	Not done	IN	GIN	GIN AFB +
TB-IRIS	Paradoxical	Paradoxical	Paradoxical	Paradoxical	Unmasking	Paradoxical	Paradoxical	Unmasking
Corticosteroids	Yes	Yes	Yes	Yes	Yes	Yes	No	No
Outcome	NKF	NKF	NKF	NKF	NKF	NKF	Demised	Lost to F/U

AFB, acid-fast bacilli on Ziehl-Neelsen staining; *C. freundii*, *Citrobacter freundii*; cART, combined antiretroviral therapy; CRP, C-reactive protein; *E. coli*, *Escherichia coli*; F/U, follow-up; FNA, fine needle aspirate; GIN, granulomatous interstitial nephritis; IN, interstitial nephritis; MTB, *Mycobacterium tuberculosis*; NKF, normal kidney function; TB-IRIS, tuberculosis-immune reconstitution inflammatory syndrome; urine LAM, urine lipoarabinomannan test; urine PCR, urine protein-to-creatinine ratio.

inguinal lymphadenopathy. All patients were afebrile with normal urine output on presentation.

On admission, laboratory investigation in all patients revealed normocytic, normochromic anemia, elevated alkaline phosphatase and gamma glutamyl transpeptidase, elevated C-reactive protein (median [IQR] 160 [115–225] mg/l), and estimated glomerular filtration rate <20 ml/min per 1.73 m². The median (IQR) CD4 count was 74 (73–147) cells/mm³. Three patients had hyperkalemia. All patients had a normal serum calcium and phosphate. No patient had glycosuria. Five patients had sterile pyuria on admission. Three patients had bacterial urinary tract infections diagnosed by urine culture on admission. After appropriate antibiotics, patients had sterile urine cultures, but the pyuria persisted. All patients were proteinuric, with 3 demonstrating nephrotic range proteinuria.

Pulmonary TB was confirmed via positive Xpert MTB/RIF on sputum in 6 patients. Of the remaining 2 patients, 1 grew MTB on blood culture, while the other demonstrated granulomata with acid-fast bacilli on kidney biopsy. Three patients had culture-confirmed disseminated TB. Six patients were diagnosed with paradoxical TB-IRIS, and 2 were diagnosed with unmasking TB-IRIS. All patients were diagnosed with TB-IRIS by the primary management team based on

their clinical presentation, inflammatory markers, change in HIV viral load, change in CD4 count, and a positive laboratory diagnosis of MTB.

Four patients had kidney biopsies performed, with 3 biopsies revealing a granulomatous interstitial nephritis (Figure 1). Of those, 1 was positive for acid-fast bacilli on Ziehl-Neelsen stain. The fourth biopsy revealed an interstitial nephritis. None had histologic findings of tenofovir-induced nephrotoxicity.

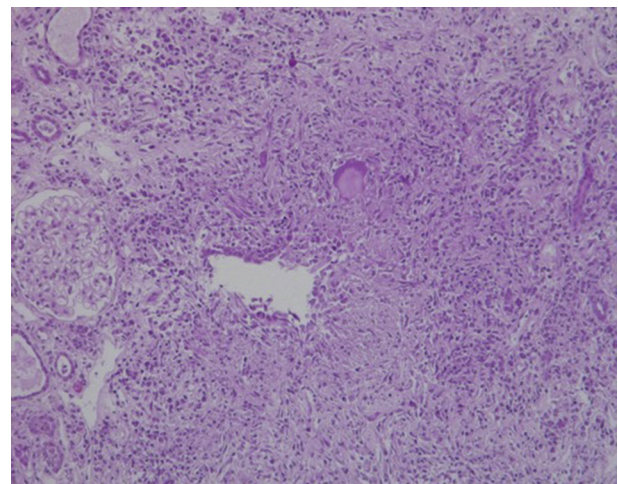


Figure 1. Interstitial-based granuloma, with a giant cell, impinging on a tubular profile.

All patients were supported with i.v. fluids on admission. Antiretrovirals were continued in all 8 patients; however, tenofovir was replaced with another nucleoside reverse-transcriptase inhibitor in all patients. A total of 5 patients required acute hemodialysis for <1 week because of uremic encephalopathy and refractory hyperkalemia. Six patients were initiated on prednisone (1 mg/kg/d) on diagnosis of TB-IRIS. Two patients did not receive corticosteroids. The first was diagnosed with urogenital TB-IRIS on kidney biopsy and did not return for clinical follow-up. Unfortunately, the second patient died from complications of hyperkalemia. An autopsy was not authorized. Among the 6 patients receiving corticosteroids, 5 had normal kidney function before hospital discharge, and the sixth had normalized within 3 months of discharge.

DISCUSSION

We have described 8 patients with AKI in the setting of TB-IRIS, of which all 4 with biopsies had evidence of interstitial nephritis, and 3 of these 4 had evidence suggestive of urogenital TB. The incidence of urogenital TB and AKI secondary to TB-IRIS of the kidney in HIV coinfecting patients is rarely described, particularly in Africa. Five previous cases, 4 adult and 1 pediatric case, have been published, all from low HIV-TB coinfection settings.^{8,9,S1-S3} There was a male predominance (80%), with a mean age of 41 years. The time from initiation of cART to presentation varied in a similar distribution to our patients but with a slightly longer median of 39 days. The CD4 count for all 4 adult patients was <100 cells/mm³ at initiation, and the pediatric case had a CD4 count of 227 cells/mm³. The pediatric patient and 1 adult patient had a previous diagnosis of TB and presented as a paradoxical IRIS. A total of 3 patients were on a tenofovir-based regimen, and the remainder were on zidovudine, lamivudine, and lopinavir/ritonavir. One patient had MTB identified on urine culture. Four patients had a granulomatous interstitial nephritis on kidney biopsy, and 1 patient had an interstitial nephritis, similar to our patients. Only 1 patient had their cART stopped, and all had a good clinical response after they were initiated on prednisone 1mg/kg/d for a few weeks followed by a tapering dose. All had normal kidney function a year later.

All of our cases as well as the 3 published patients,^{9,S2,S3} who had been initiated on tenofovir, had tenofovir nephrotoxicity excluded as a cause for the AKI. None had clinical features of a proximal tubulopathy associated with Fanconi syndrome nor any histologic features of tenofovir-associated nephrotoxicity on kidney biopsy.

Whereas the previous cases have been published as unusual or rare events, our collection of cases suggest this may be occurring more frequently in South Africa. In a South African study characterizing causes of death on antiretroviral therapy, 87% of deaths were due to mycobacterial infections, mainly MTB, in the early cART (7–90 days) death group—with 85% of those cases diagnosed postmortem as having TB-IRIS. Of those, 46% were found to have granulomatous inflammation of the kidney, and 31% had antemortem kidney failure.^{S4}

Urogenital TB presents significant diagnostic challenges. Of patients with granulomatous inflammation on kidney biopsy, in the aforementioned autopsy study, mycobacterial infection was not clinically suspected in 67% of patients at the time of death.^{S4} Currently, diagnosis is based on identification of acid-fast bacilli in the urine through Ziehl-Neelsen staining or mycobacterial culture, both of which have limited sensitivity.⁷ Urine culture is particularly hindered by a long turn-around time and a wide variation in sensitivity due to sporadic bacilluria.⁷ Urine polymerase chain reaction techniques appear to be promising; however, there is marked variation in the sensitivity, which appears to be affected by sporadic bacilluria. Thus, multiple samples or a 24-hour urine collection may improve diagnosis.^{S5} Kidney biopsy may assist with diagnosis. Typical biopsy findings demonstrate a tubulointerstitial nephritis and granuloma formation with or without the presence of acid-fast bacilli.^{S6}

Diffuse interstitial nephritis has been described as a separate entity of urogenital TB.^{S7} These cases differ from the typical presentation of urogenital TB as voiding symptoms and radiographical changes are not present and the bacillus can rarely be found in the urine.^{S7} The difficulty in proving definite kidney parenchymal TB infection is further complicated in immunodeficient patients as granulomas tend to be diffuse and poorly formed with infrequent caseous necrosis.^{S6} On some biopsies, the only finding is a tubulo-interstitial nephritis.^{S6} In this setting, it is suggested that kidney dysfunction is from both infection and immunologic kidney injury, and the diagnosis is confirmed if the kidney function starts to improve with a combination of anti-TB treatment and corticosteroids.^{S6}

To accurately reflect the pathophysiological spectrum of kidney injury in these patients, we propose the term TB-IRIS interstitial nephritis (TIIN). Autopsy studies suggest that TIIN may be common in high-burden HIV-TB coinfection settings, such as South Africa. This diagnosis encompasses urogenital TB in the setting of TB-IRIS and TB-IRIS where urogenital TB has not been definitively diagnosed. TIIN should be considered in all HIV-infected patients who have

Table 2. Teaching points

1	TIIN should be considered in HIV-infected patients recently initiated on cART who present with a sudden deterioration in kidney function.
2	TIIN has nonspecific symptoms and is difficult to diagnose.
3	Kidney biopsy may reveal a diffuse interstitial nephritis with or without granuloma formation.
4	TIIN treatment is widely accessible and consists of antituberculosis treatment and systemic corticosteroids.
5	Normalization of kidney dysfunction is common when TIIN is diagnosed and treated in a timely manner.

cART, combined antiretroviral therapy; TIIN, tuberculosis-immune reconstitution inflammatory syndrome interstitial nephritis.

recently been initiated on cART in high-burden TB settings when presenting with a sudden deterioration in kidney function—regardless of the cART regimen that was initiated. TIIN treatment (TB treatment, i.v. fluids, and systemic corticosteroids) is widely accessible in South Africa, and normalization of kidney dysfunction is common when TIIN is diagnosed in a timely manner.

CONCLUSION

Clinicians, especially those in high prevalence HIV-TB coinfection settings, should identify patients at risk for TB-IRIS and TIIN and actively monitor their kidney function—predominantly in the first 4 months after cART initiation. Guidance or guidelines for diagnosis of TIIN are needed, and improved diagnostic testing for urogenital TB will be critical. Further studies should clarify whether kidney dysfunction is due to infection, immunologic injury, or a combination and assess diagnostics, incidence, appropriate management, and longitudinal outcomes of TIIN. The main teaching points are found in Table 2.

DISCLOSURE

All the authors declared no competing interests.

PATIENT CONSENT

This was a retrospective record review, and it was not possible to contact the patients. Ethics approval for the

study was obtained from the University of the Witwatersrand Human Research Ethics Committee (Medical), clearance certificate number M150264.

SUPPLEMENTARY MATERIAL

Supplementary File (PDF)

Supplementary References.

REFERENCES

- Vachiat AI, Musenge E, Wade S, Naicker S. Renal failure in HIV-positive patients—a South African experience. *Clin Kidney J.* 2013;6:584–594. <https://doi.org/10.1093/ckj/sft128>
- Izzedine H, Baumelou A, Deray G. Acute renal failure in HIV patients. *Nephrol Dial Transplant.* 2007;22:2757–2762. <https://doi.org/10.1093/ndt/gfm404>
- UNAIDS. UNAIDS report on the global AIDS epidemic. *UNAIDS*; 2020. <https://aids2020.unaids.org/report>. Accessed October 6, 2021.
- World Health Organization. Global tuberculosis report 2020: executive summary. World Health Organization. <https://www.who.int/publications-detail-redirect/9789240013131>. Accessed October 6, 2021.
- Shafer RW, Kim DS, Weiss JP, Quale JM. Extrapulmonary tuberculosis in patients with human immunodeficiency virus infection. *Medicine (Baltimore).* 1991;70:384–397. <https://doi.org/10.1097/00005792-1991111000-00004>
- Murdoch DM, Venter WD, Feldman C, Van Rie A. Incidence and risk factors for the immune reconstitution inflammatory syndrome in HIV patients in South Africa: a prospective study. *AIDS.* 2008;22:601–610. <https://doi.org/10.1097/QAD.0b013e3282f4a607>
- Figueiredo AA, Lucon AM. Urogenital tuberculosis: update and review of 8961 cases from the world literature. *Rev Urol.* 2008;10:207–217.
- Izzedine H, Brocheriou I, Martinez V, Deray G. Immune reconstitution inflammatory syndrome and acute granulomatous interstitial nephritis. *AIDS.* 2007;21:534–535. <https://doi.org/10.1097/QAD.0b013e32802c7bce>
- Salliot C, Guichard I, Daugas E, Lagrange M, Verine J, Molina JM. Acute kidney disease due to immune reconstitution inflammatory syndrome in an HIV-infected patient with tuberculosis. *J Int Assoc Phys AIDS Care (Chic).* 2008;7:178–181. <https://doi.org/10.1177/1545109708320683>