

# Solitary Osteochondroma of the Skull Base: A Case Report and Literature Review

Hiroki Hongo<sup>1</sup> Soichi Oya<sup>1</sup> Atsushi Abe<sup>2</sup> Toru Matsui<sup>1</sup>

<sup>1</sup>Department of Neurosurgery, Saitama Medical Center, Saitama Medical University, Saitama, Japan

<sup>2</sup>Department of Radiology, Saitama Medical Center, Saitama Medical University, Saitama, Japan

Address for correspondence Soichi Oya, MD, PhD, Department of Neurosurgery, Saitama Medical Center, Kamoda 1981, Kawagoe, Saitama, 350-8550, Japan (e-mail: sooya-ky@umin.ac.jp).

J Neurol Surg Rep 2015;76:e13–e17.

## Abstract

We report a case of an osteochondroma in the posterior clinoid process that occurred in a 43-year-old man with trochlear nerve palsy. Although the potential preoperative diagnoses based on computed tomography and magnetic resonance imaging included other intracranial tumors such as calcified meningioma, thallium-201 single-photon emission computed tomography effectively differentiated osteochondroma from those possibilities. Via an orbitozygomatic approach, a subtotal resection was achieved with a good relief of symptoms. Twenty-two cases of solitary osteochondromas in the skull base have been reported that have demonstrated little risk of recurrence or malignant transformation. However, surgery for skull base osteochondromas does carry a significant risk with a reported mortality > 10%. Although some previous reports advocate complete resection as the only curative method for skull base osteochondromas, the risks of total resection should be weighed against the chance for recurrence; our review of the literature demonstrated a relatively high mortality and an extremely low incidence of recurrence.

## Keywords

- ▶ abducens nerve palsy
- ▶ bone tumor
- ▶ osteochondroma
- ▶ posterior clinoid
- ▶ skull base

## Introduction

An osteochondroma is a benign tumor composed of mature hyaline cartilage with focal ossification.<sup>1</sup> It constitutes 10 to 15% of all bone tumors and 20 to 50% of benign bone tumors<sup>2</sup> and is frequently found at the epiphysis of long bones such as the distal femur, proximal tibia, and proximal humerus. However, intracranial osteochondromas are relatively rare, and the literature consists only of sporadic case reports.<sup>1,3–23</sup> We report a rare case of an intracranial osteochondroma of the posterior clinoid process that caused right abducens nerve palsy along with a review of the literature.

## Case Report

A 43-year-old man with no past medical history developed diplopia 3 years ago. He consulted an ophthalmologist, who

found no ophthalmologic disease. Because the symptom gradually subsided over several months, he was treated conservatively. Approximately 18 months after the onset, his diplopia recurred; this time, it did not subside and gradually deteriorated. He developed a continuous medial excursion of the right eye. He visited a general hospital, where he was diagnosed with right abducens nerve palsy. Magnetic resonance (MR) images obtained at the hospital revealed an intracranial mass in the right skull base region, and he was referred to our hospital. A detailed neurologic examination on the initial visit revealed complete abducens nerve palsy with no other cranial nerve deficit. He had no muscle weakness or sensory disturbance. A noncontrast computed tomography scan demonstrated a 3.0 × 2.5 × 2.5 cm well-circumscribed extra-axial mass lesion in the right posterior clinoid that contained numerous irregular calcified spots (→Fig. 1A, B). The lesion was located in the right posterior clinoid process of

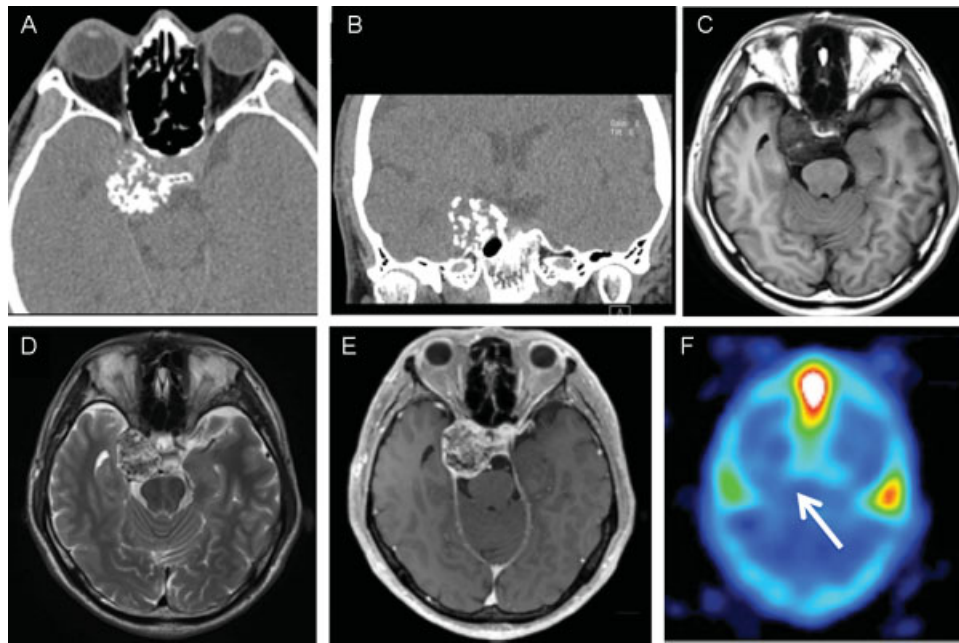
received  
March 20, 2014  
accepted after revision  
June 30, 2014  
published online  
March 2, 2015

DOI <http://dx.doi.org/10.1055/s-0034-1387189>.  
ISSN 2193-6366.

© 2015 Georg Thieme Verlag KG  
Stuttgart · New York

License terms





**Fig. 1** (A, B) Preoperative computed tomograms showing a mass with atypical patterns of calcification in the skull base. (C) Axial T1-weighted magnetic resonance (MR) imaging demonstrating a mass in the right posterior clinoid with low intensity. (D) Axial T2-weighted MR imaging depicting a mass with heterogeneous intensity. (E) Axial T1-weighted MR imaging with gadolinium showing a mass with heterogeneous enhancement. (F) The mass demonstrated an extremely low uptake on thallium-201 single-photon emission computed tomography.

the sphenoid bone and caused the destruction of the petrous apex of the temporal bone. MR imaging showed that the lesion had heterogeneous signals of intermediate to low intensity on the T1-weighted images (►Fig. 1C) and of low to high intensity on the T2-weighted images (►Fig. 1D). The T1-weighted images with gadolinium enhancement showed strong enhancement of the noncalcified areas (►Fig. 1E). The dural tail sign was not apparent, and there was no perifocal edema. Cerebral angiography showed no tumor stain or arterial stenosis. Thallium-201 single-photon emission computed tomography (SPECT) revealed an extremely low uptake for meningothelial tumors. The preoperative differential diagnosis included meningioma, cavernous hemangioma with intralésional calcification, miscellaneous osteomatous lesions, sarcoma, fibrous dysplasia, and metastasis.

To relieve the abducens nerve palsy and make a definitive diagnosis, a surgical resection via right orbitozygomatic craniotomy was performed while monitoring the extraocular muscles. The right optic nerve, right internal carotid artery, and medial right incisura of the tentorium were exposed by opening the proximal sylvian fissure. The surface of tentorium bulged upward significantly (►Fig. 2A). The tentorium was cut, and the tumor was readily identified; it mildly adhered to the oculomotor nerve. Because the tumor was composed of white brittle tissue with multiple small calcified masses, we removed it piecemeal (►Fig. 2B). There was a substantial amount of bleeding from the cavernous sinus, but it was controlled with a small piece of Gelfoam. Intraoperative frozen sections were unavailable because the specimen was essentially calcified; nevertheless, we were convinced the lesion was benign rather than malignant from our intraoperative findings. Therefore, we intentionally left the thin tumor capsule to prevent the leakage of blood from the

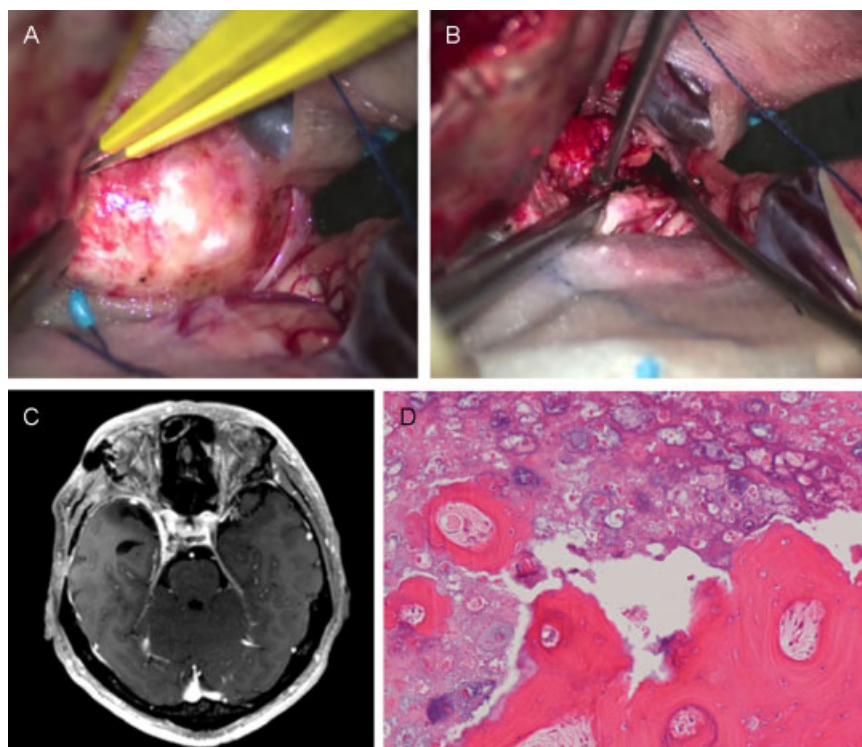
cavernous sinus to the prepontine cistern. Although the trochlear and abducens nerves were not found inside the tumor and the oculomotor nerve was preserved anatomically, we were unable to detect extraocular muscle movement during the intraoperative monitoring probably because of compression to the nerves by the surgical manipulation.

Postoperative MR images confirmed near total resection (►Fig. 2C). The pathologic findings demonstrated that the mass was macroscopically composed of bone and white substantial tissue like cartilage. On microscopic findings, there was bony tissue including bone marrow, trabecular bone, and fragments of hyaline cartilage comprising clusters of benign mature and degenerating chondrocytes with foci of irregular calcification and ossification (►Fig. 2D). The bone marrow was occupied by adipose tissue and fibrosis. These findings were consistent with the characteristics of osteochondroma.

Right oculomotor nerve palsy was newly observed after surgery, and the palsy completely resolved in 4 months. Although the abducens nerve palsy had persisted for > 18 months preoperatively, there was evidence of an almost full recovery at the 12-month follow-up after surgery.

## Discussion

Osteochondromas are benign tumors composed of mature hyaline cartilage with focal ossification.<sup>1</sup> It is the most common tumor of the bone arising in any part of the body, but it is rare in the skull.<sup>17</sup> We conducted a comprehensive literature search using the online database and identified 22 cases of osteochondromas of the skull including our case (►Table 1). Nineteen of the 22 patients (86.4%) were men. Eleven cases (50.0%) arose in the skull base, whereas the



**Fig. 2** (A) Intraoperative photograph showing the tumor covered by the tentorium. (B) The tumor was composed of brittle small calcified particles and hemorrhagic soft tumor components. (C) Postoperative T1-weighted magnetic resonance image with gadolinium demonstrating subtotal resection of the tumor. (D) Photomicrograph showing that the tumor consisted of bony tissue including bone marrow, trabecular bone, and benign hyaline cartilage. Original magnification:  $\times 100$ .

others were found in the convexity and the falx. Three cases including ours occurred in the posterior clinoid. As shown in **Table 1**,  $\sim 80\%$  of the osteochondromas in the skull base presented with focal cranial nerve deficits depending on the regions affected by the tumor, whereas non-skull base osteochondromas frequently caused epilepsy and headache as an initial symptom. Apart from visual disturbances, abducens nerve palsy was the most common cranial nerve deficit among skull base osteochondromas. This is probably related to the origin of the tumor cells, the cartilage rests in the synchondrosis.<sup>1</sup> As shown in **Table 1**, skull base osteochondromas frequently arise in the parasellar region including the posterior clinoid and the middle cranial fossa, which is close to the confluence where the sphenopetrosal, sphenoccipital, and petro-occipital synchondroses meet.<sup>12,19</sup> We therefore speculate that the abducens nerve palsy is most frequently observed in skull base osteochondromas because the nerve runs closer to these synchondroses than other cranial nerves.

Some previous reports mentioned that osteochondroma can mimic meningioma.<sup>1,12,15,22</sup> Osteochondromas are usually heterogeneously enhanced on T1-weighted images with gadolinium,<sup>12,14,18,21</sup> indicating that contrast-enhanced MR images are not useful in completely discerning osteochondroma from meningiomas. Angiography has a diagnostic value because osteochondroma appears as avascular masses.<sup>1,8–11,16,17,20,23–25</sup> In our experience, the findings of an extremely low uptake on thallium-201 SPECT were useful

in differentiating osteochondroma from other intracranial tumors such as meningioma.

As for treatment, complete surgical removal is considered the only curative treatment for extracranial osteochondromas.<sup>2,22</sup> Venkata et al mentioned that skull base osteochondromas may recur from incomplete resection.<sup>22</sup> However, although gross total resection was achieved in only 11 of 23 cases (47.8%), only two recurrent cases (8.7%) have been reported in the literature.<sup>23,26</sup> In addition, in our literature search, we did not find any reports of malignant transformation of solitary intracranial osteochondroma except for one case reported in 1935.<sup>26</sup> The incidence of malignant transformation from a solitary osteochondroma in other parts of the body was  $< 1\%$ , whereas that from multiple osteochondromas was reported as 0.5 to 5%.<sup>26</sup> Based on these facts, skull base osteochondromas are basically benign lesions, especially for solitary lesions; the risks of radical resection should be carefully weighed against the future risk of recurrence or malignant transformation. When a small asymptomatic bony lesion showed similar radiologic characteristics, a conservative management strategy could be used. Skull base osteochondromas are often located close to critical structures such as the internal carotid artery, the cavernous sinus, and the cranial nerves. Given that the mortality after surgery occurred in three patients (13.6%) in the literature,<sup>4,13,19</sup> subtotal or even partial resections can be an important option to relieve the symptoms and achieve good long-term tumor control.

**Table 1** Summary of cases of intracranial osteochondroma

Authors, Year	Age, Sex	Location	Size (cm)	Symptoms, cranial nerve deficits	Treatment	Improvement of symptoms	Follow-up (months)	Recurrence
Alpers, 1935	49, M	Convexity	ND	Epilepsy	Multiple operations	No	68	Yes (chondrosarcoma)
Forsythe, 1947	51, M	Convexity	ND	Headache	Removed in a piecemeal fashion	Yes	6	ND
Richards, 1960	49, M	Sella turcica	ND	Visual disturbance	PR	Yes	ND	ND
Herskowitz, 1973	57, F	Convexity	ND	Gait disturbance, memory disturbance	GTR	Yes	6	ND
Ito, 1974	24, M	Posterior clinoid	6	CN6	PR	NA <sup>a</sup>	NA <sup>a</sup>	NA <sup>a</sup>
Himuro, 1977	52, M	Parasellar region	ND	Visual disturbance	PR	No	1	ND
Ikeda, 1980	41, M	Parasellar region	ND	CN6	STR	No	ND	ND
Matz, 1981	20, M	Convexity	8	Headache, vomiting, Visual disturbance	GTR	No	3	ND
Yamaguchi, 1983	24, M	Middle fossa	2	CN9, 10, 11 left hemiparesis	Multiple operations	No	45	Yes
Crawford, 1987	48, M	Falx	ND	Headache, gait disturbance	GTR	Yes	3	ND
Hatayama, 1989	15, M	Parasellar region	ND	CN5, CN6	STR	Yes	ND	ND
Masuyama, 1994	28, F	Convexity	5	Epilepsy	GTR	Yes	1	ND
Sato, 1996	38, M	Posterior clinoid	4	Epilepsy	PR	ND	ND	ND
Nagai, 1998	45, F	Convexity	4.5	Headache	GTR	Yes	ND	ND
Haddad, 1998	25, M	Convexity	6	Epilepsy	GTR	Yes	12	No
Lin, 2002	15, M	Falx	14	Headache, epilepsy, sleep apnea	GTR	Yes	36	No
Omalu, 2003	53, M	Falx	8	Epilepsy	GTR	NA <sup>a</sup>	NA <sup>a</sup>	NA <sup>a</sup>
Bonde, 2007	20, M	Petrous bone	ND	Hemiplegia, CN 10	PR	NA <sup>a</sup>	NA <sup>a</sup>	NA <sup>a</sup>
Inoue, 2009	29, M	Sella turcica	ND	Headache, visual disturbance	STR	Yes	60	No
Somerset, 2010	33, F	Convexity	9.5	Headache, hemiplegia	GTR	ND	ND	ND
Venkata, 2011	24, M	Convexity	7	Headache, epilepsy	GTR	Yes	ND	No
Lotfinia, 2012	73, M	Foramen magnum	ND	Quadriparesis, headache	GTR	Yes	18	No
Present case	43, M	Posterior clinoid	3	CN6	STR	No	6	No

Abbreviations: CN, cranial nerve; GTR, gross total resection; NA, not applicable; ND, no data available; PR, partial resection; STR, subtotal resection.  
<sup>a</sup>Death due to postoperative complications.

## Conclusion

Intracranial osteochondromas are rare but should be included in the differential diagnosis of intracranial extra-axial tumors demonstrating atypical patterns of calcification. Thallium-201 SPECT might be useful in differentiating osteochondromas from other intracranial tumors. Although the long-term treatment outcome of intracranial osteochondromas is still unknown because of the scarcity of previous data, the risk of the goal of total resection should be carefully weighed against the chance of recurrence given the benign nature of the disease.

## References

- Somerset HL, Kleinschmidt-DeMasters BK, Rubinstein D, Breeze RE. Osteochondroma of the convexity: pathologic-neuroimaging correlates of a lesion that mimics high-grade meningioma. *J Neurooncol* 2010;98(3):421–426
- Murphey MD, Choi JJ, Kransdorf MJ, Flemming DJ, Gannon FH. Imaging of osteochondroma: variants and complications with radiologic-pathologic correlation. *Radiographics* 2000;20(5):1407–1434
- Beck DW, Dyste GN. Intracranial osteochondroma: MR and CT appearance. *AJNR Am J Neuroradiol* 1989;10 (5, Suppl):S7–S8
- Bonde V, Srikant B, Goel A. Osteochondroma of basi-occiput. *Neurol India* 2007;55(2):182–183
- Crawford SC, Cornell SH, Franken EA. General case of the day. Intracranial osteochondroma. *Radiographics* 1987;7(6):1178–1180
- Forsythe RW, Baker GS, et al. Intracranial osteochondroma. *Proc Staff Meet Mayo Clin* 1947;22(17):350–356
- Haddad GF, Haddad FS, Zaatari G. Dural osteochondroma: case report, review of the literature and proposal of a new classification. *Br J Neurosurg* 1998;12(4):380–384
- Hatayama T, Sekiya T, Suzuki S, Iwabuchi T. A case of intracranial osteochondroma: its MR images [in Japanese]. *No Shinkei Geka* 1989;17(11):1063–1066
- Herskowitz A, el-Gammal T. Supratentorial cartilaginous tumors. (A report of 2 cases). *Dis Nerv Syst* 1973;34(7):384–388
- Himuro H, Suzuki H, Takeyama E, Jinbo M, Kitamura K. A case of intracranial osteochondroma [in Japanese]. *No Shinkei Geka* 1977;5(10):1079–1083
- Ikeda Y, Shimura T, Higuchi H, Nakazawa S, Sugisaki Y. Intracranial osteochondroma—case report [in Japanese]. *No Shinkei Geka* 1980;8(3):263–269
- Inoue T, Takahashi N, Murakami K, Nishimura S, Kaimori M, Nishijima M. Osteochondroma of the sella turcica presenting with intratumoral hemorrhage. *Neurol Med Chir (Tokyo)* 2009;49(1):37–41
- Ito U, Hashimoto K, Inaba Y. Osteochondroma of the posterior clinoid process. Report of a case with special reference to its histogenesis. *Acta Neuropathol* 1974;27(4):329–335
- Lin WC, Lirng JF, Ho DMT, et al. A rare giant intracranial osteochondroma. *Zhonghua Yi Xue Za Zhi (Taipei)* 2002;65(5):235–238
- Lotfinia I, Vahedi P, Tubbs RS, Gavame M, Vahedi A. Basioccipital bone osteochondroma growing into the foramen magnum. *Surg Neurol Int* 2012;3:21
- Mashiyama S, Sakurai Y, Kayama T, Nishino A, Jokura H. A case of intracranial osteochondroma originating with psychomotor epilepsy [in Japanese]. *No Shinkei Geka* 1994;22(2):165–168
- Matz S, Israeli Y, Shalit MN, Cohen ML. Computed tomography in intracranial supratentorial osteochondroma. *J Comput Assist Tomogr* 1981;5(1):109–115
- Nagai S, Yamamoto N, Wakabayashi K, et al. Osteochondroma arising from the convexity dura mater. Case illustration. *J Neurosurg* 1998;88(3):610
- Omalu BI, Wiley CA, Hamilton RL. February 2003: a 53-year-old male with new onset seizures. *Brain Pathol* 2003;13(3):419–420, 423
- Richards WW, Thompson MC. Suprasellar osteochondroma with chiasmal syndrome. *Arch Ophthalmol* 1961;65:437–441
- Sato K, Kodera T, Kitai R, Kubota T. Osteochondroma of the skull base: MRI and histological correlation. *Neuroradiology* 1996;38(1):41–43
- Venkata RI, Kakarala SV, Garikaparthi S, Duttaluru SS, Parvatala A, Chinnam A. Giant intracranial osteochondroma: a case report and review of the literature. *Surg Neurol Int* 2011;2:118
- Yamaguchi T, Wada S, Matsukado Y. Intracranial giant osteochondroma with unusual clinical features [in Japanese]. *No Shinkei Geka* 1983;11(2):181–184
- Bakdash H, Alksne JF, Rand RW. Osteochondroma of the base of the skull causing an isolated oculomotor nerve paralysis. Case report emphasizing microsurgical techniques. *J Neurosurg* 1969;31(2):230–233
- Fon G, Sage MR. Osteochondroma of the clivus. *Australas Radiol* 1979;23(1):46–53
- Alpers BJ. Cerebral osteochondroma of dural origin. *Ann Surg* 1935;101(1):27–37
- Bovée JV, Hogendoorn PCW. Multiple osteochondromas. In *World Health Organization classification of tumours. Pathology and genetics of tumours of soft tissue and bone*. Edited by: Fletcher CDM, Unni KK and Mertens F. Lyon, IARC Press; 2002: 360–362