

Case Report: Report of a Novel Bilateral Variation of Sciatic and Inferior Gluteal Nerve: A Case Study



Rahim Golmohammadi¹ , Ali Delbari^{1*} 

1. Department of Anatomical Sciences, Cellular and Molecular Research Center, School of Medicine, Sabzevar University of Medical Sciences, Sabzevar, Iran.



Citation: Golmohammadi, R., & Delbari, A. (2021). Report of a Novel Bilateral Variation of Sciatic and Inferior Gluteal Nerve: A Case Study. *Basic and Clinical Neuroscience*, 12(3), 421-426. <http://dx.doi.org/10.32598/bcn.2021.1900.1>

doi <http://dx.doi.org/10.32598/bcn.2021.1900.1>



Article info:

Received: 13 Jun 2019

First Revision: 10 Jul 2019

Accepted: 19 Apr 2020

Available Online: 01 May 2021

Keywords:

Sciatic nerve, Inferior gluteal nerve, Anatomic variation

ABSTRACT

Introduction: The sciatic nerve is the thickest nerve of the sacral plexus which innervates many muscles and vast areas of the skin of the lower limb. It leaves the pelvis via the greater sciatic foramen, emerges into the gluteal region by passing under the piriformis muscle, and descends beneath the gluteus maximus to divide into its terminal branches; the tibial and common peroneal nerve at the superior angle of the popliteal fossa. In some cases, the sciatic nerve divides into the tibial and common peroneal nerves at a higher level and one of them or both passes through or over the piriformis muscle.

Case Presentation: We find an interesting bilateral variation of sciatic nerve accompanying a very thick inferior gluteal nerve on the right side and unusual route and branching of tibial and common peroneal nerves on the left side.

Conclusion: As in conditions like intramuscular injections, gluteal surgeries, and piriformis syndrome such variations may increase the risk of injury, it is important for the medical team to be aware of them. In this paper, by reporting many variations in a cadaver, we emphasize the importance of anatomical variations, especially for surgeons and nurses.

* Corresponding Author:

Ali Delbari, PhD.

Address: Department of Anatomical Sciences, Cellular and Molecular Research Center, School of Medicine, Sabzevar University of Medical Sciences, Sabzevar, Iran.

Tel: +98 (51) 44018414

E-mail: alidel.del@gmail.com

Highlights

- Bilateral multiple variations of the sciatic nerve in a male cadaver.
- Tibial and common peroneal nerves had their own epineurium emerging in the gluteal region.
- Existence of a very thick inferior gluteal nerve in Rt. Side.
- The inferior gluteal nerve was a branch of the common fibular nerve.
- The route of common fibular N. was more vertical as it didn't cross the neck of the fibula.

Plain Language Summary

Like a car repairman who needs to know all the parts to repair a car, a doctor needs to know the human body well to diagnose and treat diseases. The science that studies the structure of the body is Anatomy. It is true that medical students take a large number of anatomy courses, but what they learn is the structure of the body in the majority of people. The bad news is that there are differences in the anatomy of some people. In anatomy this is called anatomic variation. Physicians, especially surgeons, should be aware of anatomic variations in addition to normal human anatomy. Awareness of anatomical variations is very important. For example, the surgeon may cut a large artery or nerve, thinking that there is no such structure in the course of his or her surgery, or a nurse may inject in a nerve and paralyze the patient. Anatomists encounter variations while dissecting the cadaver and must report them to prevent medical errors. In this article, we have reported an interesting case of sciatic nerve variation, which is the largest nerve in the body, to inform surgeons and nurses about the existence of this variation and to remind them again that when performing any surgery and injection, etc., note such variations as well.

1. Introduction

Sciatic nerve is the longest and thickest nerve in the human body, and it originates from the sacral plexus. After forming in the pelvis, it runs through the buttock and down the lower extremity. Sciatic nerve innervates nearly the whole skin of the leg and the muscles of the back of the thigh, and those of the leg and foot. It is orientated from the spinal nerves of L4-S3 and contains fibers from both the anterior and posterior divisions of the lumbosacral plexus.

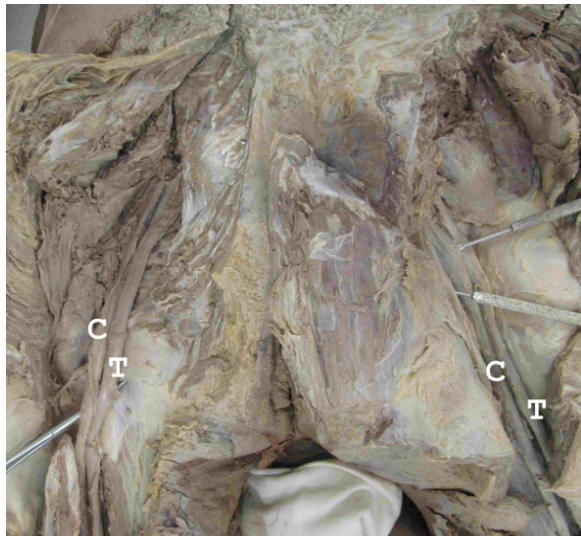
Usually, the fibers unite to form a single nerve in front of the piriformis muscle. This muscle originates between the anterior sacral foramina on the anterolateral surface of the sacrum and exits the pelvis through the greater sciatic foramen to insert on the greater trochanter of the femur. Piriformis is used as a landmark in this region for muscles and neurovascular structures.

Sciatic nerve leaves the pelvis through the greater sciatic foramen and enters into the gluteal region by passing under piriformis. The inferior gluteal nerve and vessels, the internal pudendal vessels, and the pudendal nerve are

located medial to this nerve. The nerve descends beneath the gluteus maximus muscle, between the greater trochanter of the femur and ischial tuberosity to reach the back of the thigh. Usually, at the superior angle of the popliteal fossa, sciatic nerve divides into two terminal branches: the tibial nerve and the common peroneal nerve.

Tibial nerve passes through the popliteal fossa to enter the posterior compartment of the leg. The common fibular nerve descends obliquely along the lateral side of the popliteal fossa to the head of the fibula and winds around the head of the fibula.

Numerous anatomical variations have been reported both in the course and distribution of this nerve (Adibatti & Sangeetha, 2014; Anbumani, Thamarai Selvi & Anthony Ammal, 2015; Berihu & Debeb, 2015; Brooks et al., 2011; Desalegn & Tesfay, 2014; Patel, Shah, Vora, Zalawadia & Rathod, 2011; Saritha, Praveen Kumar & Supriya, 2012). For instance, it passes completely under the piriformis in the majority of the population, but in a small portion of cases, the tibial or common peroneal nerve passes through or over the muscle (Lewis, Jurak, Lee, Lewis & Gest, 2016). Such variations are signifi-



NEURSCIENCE

Figure 1. Bilateral variation of sciatic nerve

C: Common peroneal nerve; T: Tibial nerve.

cant in gluteal surgeries and in conditions called piriformis syndrome (Natsis et al., 2014).

On the other hand, the gluteal region is a frequently used area for intramuscular injections, and in the case of sciatic variations, the risk of nerve injury is noticeably higher, especially when intramuscular injections are applied for the treatment of piriformis syndrome (Akdemir Ozisik, Toru, Cem Denk, Taskiran & Gundogmus, 2014; Siddiq, Khasru & Rasker, 2014). In this syndrome, the drug is directly injected into the piriformis muscle to reduce patients' pain.

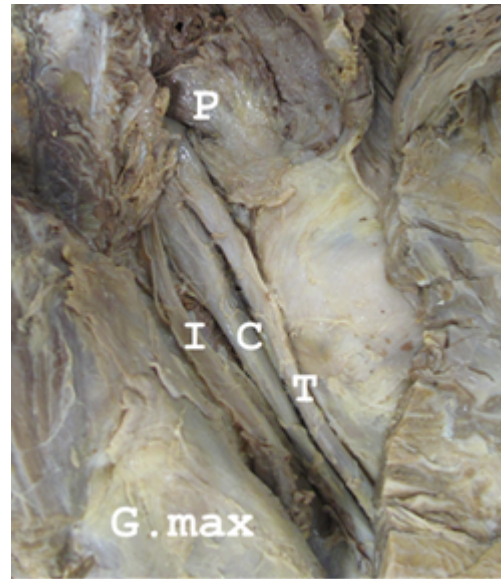
2. Case Presentation

In this paper, we report an interesting bilateral multiple variations of the sciatic nerve in a male cadaver (Figure 1).

On both sides, the sciatic nerve was divided into its terminal branches in the pelvis, and the tibial nerve and common peroneal nerve had their epineurium emerging in the gluteal region.

In the right lower limb, the most interesting variation was the existence of a third thick nerve medial to terminal branches of the sciatic nerve, which was nearly equivalent in diameter with tibial and common peroneal nerve (Figure 2).

Judging from its termination in the gluteus maximus muscle, it was the inferior gluteal nerve. The inferior gluteal nerve is the main motor nerve of the gluteus



NEURSCIENCE

Figure 2. Right gluteal region

P: Piriformis muscle; I: Inferior gluteal nerve; C: Common peroneal nerve; T: Tibial nerve; G.max: Gluteus maximus.

maximus muscle, which arises from the dorsal branches of the ventral rami of L5, S1, and S2 sacral nerves.

In the left lower limb, these variations were detected:

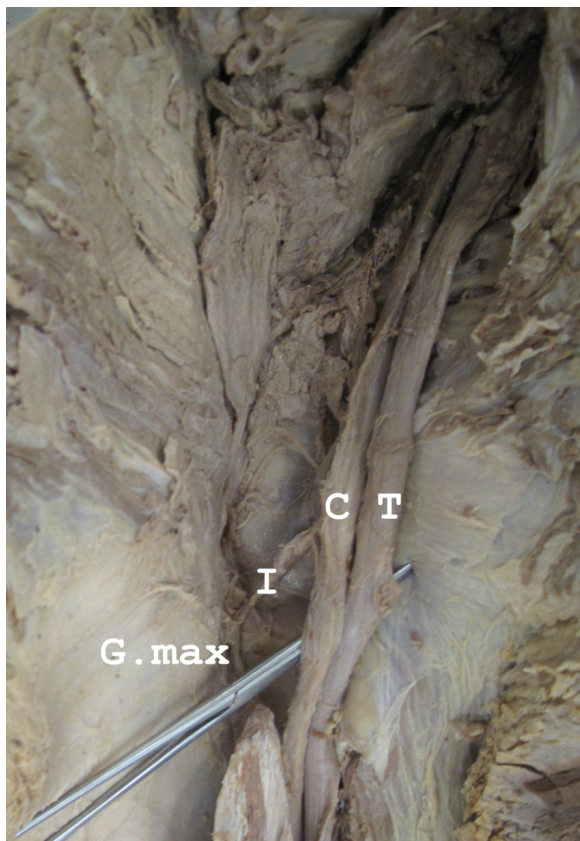1. Tibial and common peroneal nerves passed over the piriformis muscle to reach the gluteal region (Figure 3).

2. The inferior gluteal nerve was a branch of the common fibular nerve (Figure 3). Interestingly this nerve on the left side was remarkably thinner than its counterpart on the other side.

3. The route of the common fibular nerve was more vertical and it did not cross the head and neck of the fibula and reached the lateral aspect of the leg nearly 5 cm below the head of the fibula (Figure 4).

3. Discussion

Researchers have reported many variations of the sciatic nerve and the relationship between this nerve and the piriformis muscle. Ignoring these variations can cause irreparable damages to patients. SU Rao et al. reported that sciatic nerve in 16% (8 limbs of 50 dissected lower limbs) of cases bifurcates at a higher level (in the gluteal region after emerging below the piriformis [7 limbs] or at lower one-third of the back of the thigh [1 limb]). Other studies reported this type of variation 13.7% (Gabielli, Olave, Mandiola & Rodrigues, 1997), 4% (Ugrenović et al., 2005), 20.9% (Pokorný, Jahoda, Veigl, Pinskerová



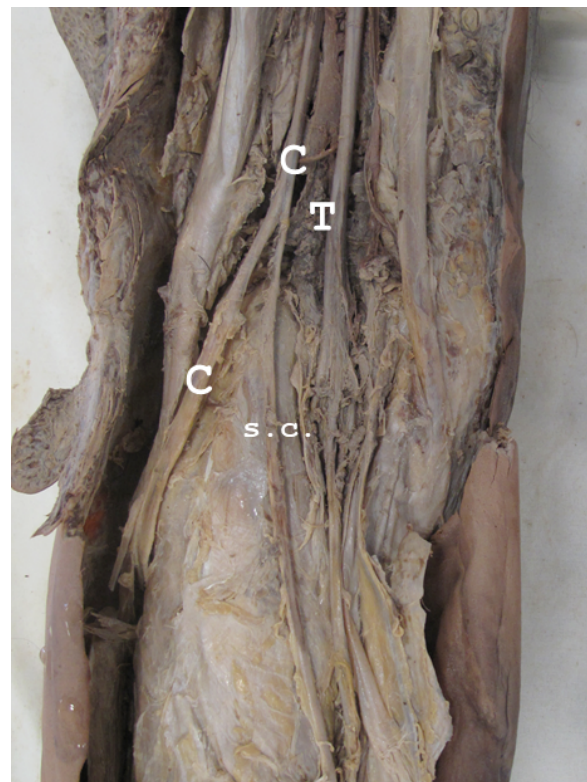
NEURSCIENCE

Figure 3. Left gluteal region

I: Inferior gluteal nerve; C: Common peroneal nerve; T: Tibial nerve; G.max: Gluteus maximus.

& Sosna, 2006), 16.3% (Prakash et al., 2010), 48% (Güvençer, Iyem, Akyer, Tetik & Naderi 2009), 20.1% (Ogeng'o, El-Busaidy, Mwika, Khanbhai & Munguti, 2011), 8% (Adibatti & Sangeetha, 2014), 18% (Anbumani et al., 2015), and 31.66% (Budhiraja et al., 2016). In Bryan Jason Bergsteed study, 170 South African cadavers (340 lower limbs) were dissected to assess anatomical variations in relation to the piriformis and sciatic nerve bifurcation among the South African population. She reported that in 21.4% of cases, sciatic nerve bifurcation has not occurred in the popliteal fossa (Bergsteed, 2019). These studies show that this type of variation ranges from 4% to 48%, suggesting that race can play a unique role in anatomic variations.

Another anatomic variation in the more clinically important region is the relationship of the sciatic nerve with the piriformis muscle. Beaton and Anson classified six variants regarding the anatomical relationship between these two structures: type 1, an undivided sciatic nerve below the piriformis muscle (normal course); type 2, a divided sciatic nerve passing through and below the



NEURSCIENCE

Figure 4. Posterior aspect of left lower limb (middle part)

C: Common peroneal nerve; T: Tibial nerve; s.c.: sural communicating branch

piriformis muscle; type 3, a divided nerve passing above and below an undivided muscle; type 4, an undivided sciatic nerve passing through the piriformis muscle; type 5, a divided nerve passing through and above the muscle heads; and finally type 6, the undivided sciatic nerve passes above the piriformis muscle (Beaton & Anson, 1938). The right and left sides of the present case can be considered as subgroups of types 1 and 6, respectively. Types 1, 2, and 3 have been reported frequently in literature. The other types are rarer (less than 1% of the populations studied) (Tomaszewski et al., 2016). Types 5 and 6 were only hypothesized and not seen in Beaton and Anson's study sample.

In the present case, the high division of the sciatic nerve was observed both in the right and left sides. Besides, on the right side, there was a thick inferior gluteal nerve medial to terminal branches of sciatic nerves that its diameter was nearly equal to the tibial and common peroneal nerve. However, the injury of the inferior gluteal nerve is rare but often happens as a complication of posterior approach in hip replacement. Indeed, such a thick inferior gluteal nerve increases the risk of nerve injury during such procedures.

On the left side, tibial and common peroneal nerves have emerged above the piriformis muscle. We know that intramuscular injection is an essential procedure for administering a variety of medications (Ramtahal, Ramlakhan & Singh, 2006), and unfortunately, injury to the sciatic nerve is a worldwide problem resulting from a misplaced intramuscular injection in the gluteal region (Mishra & Stringer, 2010). In the present case that the emerging point of the sciatic nerve parts in the gluteal region is nearer to the safe area of muscular injection, the risk of nerve injury increases noticeably, and such variations are very important clinically. On the other hand, local injection to piriformis is used to manage piriformis syndrome (Benzon, Katz, Benzon & Iqbal, 2003). If such a variation exists in a candidate for this treatment, the risk of nerve damage is very high.

The other variation in the left side was the vertical route of the common fibular nerve (It did not cross the head and neck of the fibula and reached the lateral aspect of the leg nearly 5 cm below the fibular head). Although such a route reduces the nerve injuries due to proximity of head and neck of fibula, it increases the risk of its cutting in upper leg surgeries.

Although some of these variations, like division of sciatic nerve in the pelvis, are more common, and some are relatively rare, a collection of these variations in a single cadaver is unique and has not been reported ever.

4. Conclusion

Medical students, as future physicians and nurses, learn in gross anatomy classes a general description of the human body, and soon, they will diagnose and treat all patients based on this knowledge. It is often overlooked that anatomy is a description of most people's bodies and not all of them. In the case of the gluteal region, what students learn about the sciatic nerve and its relation with piriformis muscle may be quite different from what they will experience in the clinic and operating room. Anatomical variations of the sciatic nerve, at least partly, contribute to some injuries to the gluteal region by the medical team. So having up-to-date knowledge of anatomical variations of the region is necessary to reduce this type of injury.

This case report indicates that peripheral nerve distribution patterns may be different to a great extent from what students learn as normal anatomy of the human body. This concept can promote the vision of our future physicians, nurses, and other medical team members in selecting better diagnostic and therapeutic procedures for

patients. Finally, medical progress needs more accurate knowledge of the human body variations to improve diagnosis and therapeutic management (Khanday, 2019).

Ethical Considerations

Compliance with ethical guidelines

This study was approved by the Ethics Committee of Sabzevar University of Medical Sciences (Code: IR.MEDSAB.REC.1399.038).

Funding

This research did not receive any grant from funding agencies in the public, commercial, or non-profit sectors.

Authors' contributions

Both authors equally contributed to preparing this article.

Conflict of interest

The authors declared no conflict of interest.

References

- Adibatti, M., & Sangeetha, V. (2014). Study on variant anatomy of sciatic nerve. *Journal of Clinical & Diagnostic Research*, 8(8), AC07-9 [DOI:10.7860/JCDR/2014/9116.4725]
- Akdemir Ozisik, P., Toru, M., Cem Denk, C., Taskiran, O. O., & Gundogmus, B. (2014). CT-guided piriformis muscle injection for the treatment of piriformis syndrome. *Turkish Neurosurgery*, 24(4), 471-7. [DOI:10.5137/1019-5149.JTN.8038-13.1]
- Anbumani, T. L., Thamarai Selvi, A., & Anthony Ammal, S. (2015). Sciatic nerve and its variations: An anatomical study. *International Journal of Anatomy and Research*, 3(2), 1121-7. [DOI:10.16965/ijar.2015.175]
- Beaton, L. E., & Anson, B. J. (1938). The sciatic nerve and the piriformis muscle: Their interrelation a possible cause of coccygodynia. *The Journal of Bone & Joint Surgery*, 20(3), 686-8. https://journals.lww.com/jbjsjournal/Citation/1938/20030/THE_SCIATIC_NERVE_AND_THE_PIRIFORMIS_MUSCLE__12.aspx
- Benzon, H. T., Katz, J. A., Benzon, H. A., & Iqbal, M. S. (2003). Piriformis syndrome: Anatomic considerations, a new injection technique, and a review of the literature. *Anesthesiology*, 98(6), 1442-8. [DOI:10.1097/00000542-200306000-00022]
- Bergsteedt, B. J. (2019). The sciatic nerve division in the gluteal region in a South African population: An anatomical study [MSc. thesis]. Stellenbosch: Stellenbosch University. https://scholar.sun.ac.za/bitstream/handle/10019.1/105909/bergssteedt_sciatic_2019.pdf?sequence=2&isAllowed=y

- Berihu, B. A., & Debeb, Y. G. (2015). Anatomical variation in bifurcation and trifurcations of sciatic nerve and its clinical implications: In selected university in Ethiopia. *BMC Research Notes*, 8, 633. [DOI:10.1186/s13104-015-1626-6]
- Brooks, J. B. B., Silva, C. A. C., Soares, S. A., Kai, M. R., Cabral, R. H., & Fragoso, Y. D. (2011). [Anatomical variations of the sciatic nerve in a group of Brazilian cadavers (Portuguese-English)]. *Revista Dor*, 12(4), 332-6. [DOI:10.1590/S1806-00132011000400009]
- Budhiraja, V., Rastogi, R., Jain, S. K., Sharma, N., Garg, R., & Nafees, H. (2016). Variant relation of the sciatic nerve to the piriformis muscle: A cadaveric study from North India. *Revista Argentina de Anatomía Clínica*, 8(1), 38-42. [DOI:10.31051/1852.8023.v8.n1.14206]
- Desalegn, M., & Tesfay, A. (2014). Variations of sciatic nerve its exit in relation to piriformis muscle in the Northern Ethiopia. *International Journal of Pharma Sciences and Research*, 5(12), 953-6. <http://www.ijpsr.info/docs/IJPSR14-05-12-002.pdf>
- Gabrielli, C., Olave, E., Mandiola, E., & Rodrigues, C. F. S. (1997). [Inferior gluteal nerve course associated to the high division of the sciatic nerve (Spanish)]. *Revista Chilena de Anatomía*, 15(1), 79-83. [DOI:10.4067/S0716-98681997000100012]
- Güvençer, M., Iyem, C., Akyer, P., Tetik, S., & Naderi, S. (2009). Variations in the high division of the sciatic nerve and relationship between the sciatic nerve and the piriformis. *Turkish Neurosurgery*, 19(2), 139-44.
- Khanday, Sh. (2019). Anatomical variations in the human body: Exploring the boundaries of normality [PhD. dissertation]. Kingston upon Thames: Kingston University. <https://eprints.kingston.ac.uk/id/eprint/43956/>
- Lewis, S., Jurak, J., Lee, Ch., Lewis, R., & Gest, T. (2016). Anatomical variations of the sciatic nerve, in relation to the piriformis muscle. *Translational Research in Anatomy*, 5, 15-9. [DOI:10.1016/j.tria.2016.11.001]
- Mishra, P., & Stringer, M. D. (2010). Sciatic nerve injury from intramuscular injection: A persistent and global problem. *International Journal of Clinical Practice*, 64(11), 1573-9. [DOI:10.1111/j.1742-1241.2009.02177.x]
- Natsis, K., Totlis, T., Konstantinidis, G. A., Paraskevas, G., Piagkou, M., & Koebeke, J. (2014). Anatomical variations between the sciatic nerve and the piriformis muscle: A contribution to surgical anatomy in piriformis syndrome. *Surgical and Radiologic Anatomy*, 36(3), 273-80. [DOI:10.1007/s00276-013-1180-7]
- Ogeng'o, J. A., El-Busaidy, H., Mwika, P. M., Khanbhai, M. M., & Munguti, J. (2011). Variant anatomy of sciatic nerve in a black Kenyan population. *Folia Morphologica*, 70(3), 175-9.
- Patel, Sh, Shah, M., Vora, R., Zalawadia, A., & Rathod, S. P. (2011). A variation in the high division of the sciatic nerve and its relation with piriformis muscle. *National Journal of Medical Research*, 1(2), 27-30. <https://www.researchgate.net/publication/303223379>
- Pokorný, D., Jahoda, D., Veigl, D., Pinskerová, V., & Sosna, A. (2006). Topographic variations of the relationship of the sciatic nerve and the piriformis muscle and its relevance to palsy after total hip arthroplasty. *Surgical and Radiologic Anatomy*, 28(1), 88-91. [DOI:10.1007/s00276-005-0056-x]
- Prakash, Bhardwaj, A. K., Devi, M. N., Sridevi, N. S., Rao, P. K., & Singh, G. (2010). Sciatic nerve division: A cadaver study in the Indian population and review of the literature. *Singapore Medical Journal*, 51(9), 721-3.
- Ramtahal, J., Ramlakhan, Sh., & Singh, Kh. (2006). Sciatic nerve injury following intramuscular injection: A case report and review of the literature. *Journal of Neuroscience Nursing*, 38(4), 238-40. [DOI:10.1097/01376517-200608000-00006]
- Saritha, S., Praveen Kumar, M., & Supriya, G. (2012). Anatomical variations in the bifurcation of the sciatic nerve, a cadaveric study and its clinical implications. *Anatomy & Physiology: Current Research*, 2(5), 1000111. <https://www.longdom.org/open-access/anatomical-variations-in-the-bifurcation-of-the-sciatic-nerve-a-cadaveric-study-and-its-clinical-implications-2161-0940.1000111.pdf>
- Siddiq, M. A. B., Khasru, M. R., & Rasker, J. J. (2014). Piriformis syndrome in fibromyalgia: Clinical diagnosis and successful treatment. *Case Reports in Rheumatology*, 2014, 893836. [DOI:10.1155/2014/893836]
- Tomaszewski, K. A., Graves, M. J., Henry, B. M., Popieluszko, P., Roy, J., & Pękala, P. A., et al. (2016). Surgical anatomy of the sciatic nerve: A meta-analysis. *Journal of Orthopaedic Research*, 34(10), 1820-7. [DOI:10.1002/jor.23186]
- Ugrenović, S., Jovanović, I., Krstić, V., Stojanović, V., Vasović, L., & Antić, S., et al. (2005). [The level of the sciatic nerve division and its relations to the piriform muscle (Bosnian)]. *Vojnosanitetski Pregled*, 62(1), 45-9. [DOI:10.2298/VSP0501045U]