


CASE REPORT

Azathioprine-induced severe myelosuppression accompanied by massive hair loss and painful oral ulcer in an autoimmune hepatitis patient with *NUDT15* minor variant: A case report

Yu Takeuchi¹ | Hidenao Noritake¹  | Moe Matsumoto¹ | Masahiro Umemura¹ | Maho Yamashita¹ | Kensuke Kitsugi¹ | Shingo Takatori¹ | Kazuyoshi Ohta¹ | Jun Ito¹ | Shin Shimoyama¹ | Akira Kaysuya² | Chiaki Maruyama² | Kensuke Fukuchi² | Satoshi Dohtan³ | Hiroe Sakata⁴ | Kazuhito Kawata¹

¹Division of Hepatology, Department of Internal Medicine, Hamamatsu University School of Medicine, Hamamatsu, Japan

²Department of Dermatology, Hamamatsu University School of Medicine, Hamamatsu, Japan

³Department of Hematology, Hamamatsu University School of Medicine, Hamamatsu, Japan

⁴Department of Dentistry and Oral and Maxillofacial Surgery, Hamamatsu University School of Medicine, Hamamatsu, Japan

Correspondence

Hidenao Noritake, 1-20-1, Handayama, Higashi-ku, Hamamatsu, Shizuoka 431-3192, Japan.

Email: noritake@hama-med.ac.jp

Funding information

None

Abstract

This report highlights azathioprine-induced severe myelosuppression in the patient with *NUDT15* minor variant. This case report is particularly instructive because several typical symptoms are the clues to this critical adverse drug reaction.

KEYWORDS

agranulocytosis, allopurinol, alopecia, stomatitis, thiopurine

1 | INTRODUCTION

Nudix hydrolase 15 (NUDT 15) gene polymorphism impacts severe myelosuppression even in autoimmune hepatitis patients treated with azathioprine. Massive hair loss and painful oral ulcers allowed early diagnosis of the critical adverse reactions.

Azathioprine (AZA) is a part of the standard therapy for autoimmune hepatitis (AIH); however, there are critical adverse effects of AZA, including acute and severe myelosuppression. The genetic polymorphism of nudix hydrolase 15 (*NUDT15*) has been proposed as predictive of adverse drug reactions of AZA in inflammatory bowel

disease (IBD) patients. However, the impact of this genetic variant on AIH is unclear. We herein report the case of an AIH patient—with a homogeneous variant of the minor allele of *NUDT 15*—who presented with severe myelosuppression induced by AZA, massive hair loss, and painful oral ulcer, which allowed the diagnosis of an adverse drug reaction.

2 | CASE REPORT

A 65-year-old woman who was serologically and histologically diagnosed with AIH at 49 years old had been

This is an open access article under the terms of the Creative Commons Attribution-NonCommercial-NoDerivs License, which permits use and distribution in any medium, provided the original work is properly cited, the use is non-commercial and no modifications or adaptations are made.

© 2021 The Authors. *Clinical Case Reports* published by John Wiley & Sons Ltd.

receiving ursodeoxycholic acid (UDCA) and prednisolone (PSL) treatment. She also took allopurinol because of hyperuricemia. The PSL dose was commenced at 30 mg per day (0.6 mg per kg per day) and was gradually tapered. After reducing PSL to 6.0 mg per day, combination therapy with 50 mg of AZA (1 mg per kg body weight) was commenced. Three weeks after AZA administration, she noticed massive hair loss (Figure 1), stomatitis (Figure 2), and purpura (Figure 3). Blood examination revealed agranulocytosis, macrocytic anemia, thrombocytopenia, and inflammation. She was therefore hospitalized for further examination and medical treatment. The details of the laboratory test were as follows (Table 1): white blood cell count = 840/ μ l, neutrophil = 2.5%, eosinophil = 2.0%, basophil = 0.0%, lymphocyte = 95.5%, hemoglobin = 10.9 g/dl, platelet count = 9.0×10^4 / μ l, blood urea nitrogen (BUN) = 21.7 mg/dl, creatinine = 1.20 mg/dl, uric acid = 3.9 mg/dl, total protein = 7.5 g/dl, albumin = 4.3 g/dl, total bilirubin = 0.5 mg/dl, lactate dehydrogenase (LD) = 147 U/L, aspartate aminotransferase (AST) = 19 U/L, alanine aminotransferase (ALT) = 11 U/L, alkaline phosphatase (ALP) = 58 U/L, gamma-glutamyl transpeptidase (GGT) = 25 U/L, cholinesterase = 34.2 U/L, prothrombin time = 140%, IgG = 1082 mg/dL, C-reactive protein (CRP) = 12.44 mg/dL, and anti-nuclear antibody (ANA) = 40 times. Nevertheless, chest X-ray and abdominal computed tomography findings were normal, serial bacterial cultures were negative, and she was afebrile. Cefepime (CFPM) was administered because of the inflammatory reaction and neutropenia. The pathological findings of the skin biopsy from purpura on the lower leg showed no sign of vasculitis. Bone marrow findings showed abundant adipose tissue with less than 10% of cellular components, a few granulocytes, and erythroblast-like cells, but no megakaryocytes.

Given the clinical course and these results, the severe hematological toxicity and other physical findings were

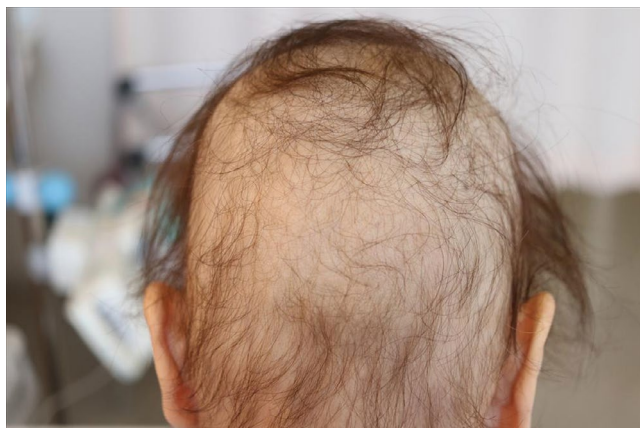

FIGURE 1 Picture of the patient's head with massive hair loss on day three of hospitalization

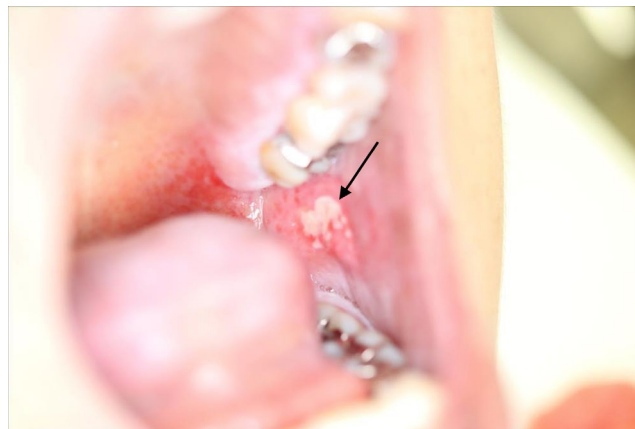

FIGURE 2 Picture of oral ulcers (arrow) of the patient on the day of hospitalization

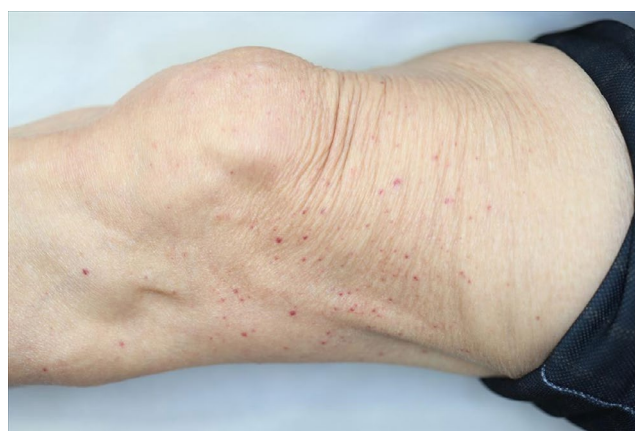

FIGURE 3 Picture of multiple erythematous lesions (arrow) on the patient on the day of hospitalization

considered drug-induced. Accordingly, allopurinol and AZA were discontinued, and daily injections of granulocyte colony-stimulating factor (G-CSF) were commenced. Fifteen days of continuous G-CSF injections were necessary for severe neutropenia recovery. Platelet transfusion was necessary twice during hospitalization because of thrombocytopenia. Profound stomatitis allowed only a small intake of a liquid diet, and morphine hydrochloride was used for pain control. CRP rebounded after falling to a low level once on day six of admission; consequently, CFPM was switched to doripenem (DRPM), and CRP went down again. Ultimately, 16 days of antibiotic and morphine hydrochloride administration were needed. She was subsequently discharged from the hospital on day 32 of admission with 600 mg of UDCA and 6 mg of PSL. However, recovery from stomatitis took six weeks and that from alopecia took six months. After investigating the genetic polymorphism of nudix hydrolase 15 (*NUDT15*, rs116855232), which is known to be predictive of AZA toxicity, it was revealed that she had the homozygous

TABLE 1 Laboratory data on admission

Complete blood count			Biochemistry			Immunology		
WBC	840	/ μ l	BUN	21.7	mg/dl	IgG	1082	mg/dl
Neu	2.5	%	Crt	1.20	mg/dl	IgA	117	mg/dl
Eos	2.0	%	UA	3.9	mg/dl	IgM	115	mg/dl
Bas	0.0	%	T. Bil	0.5	mg/dl	Anti-nuclear Antibody	1:40	
Lym	95.5	%	AST	19	U/L			
Mon	0.0	%	ALT	11	U/L			
RBC	360	10^4 / μ l	LDH	147	U/L			
Hb	10.9	g/dl	ALP	58	U/L			
Ht	32.1	%	GGT	25	U/L			
MCV	89	fl	TP	7.5	g/dl			
MCH	30.3	pg	ALB	4.3	g/dl			
MCHC	34.0	%	Ferritin	269	ng/ml			
PLT	9.0	10^4 / μ l	CRP	12.44	mg/dl			

variant in which arginine at position 139 of the protein was replaced with cysteine. Figure 4 summarizes the clinical course.

3 | DISCUSSION

Our case strongly indicated two clinically significant issues regarding AZA treatment for AIH patients. First, *NUDT 15* minor variant can cause severe myelosuppression induced by AZA even in AIH patients. Second, massive hair loss and oral ulcers allow early diagnosing of this critical adverse drug reaction.

The *NUDT 15* minor variant can cause AZA-induced severe myelosuppression even in AIH patients. AIH is a common chronic liver disease. Immune-mediated and inflammatory liver diseases of uncertain cause can potentially progress to cirrhosis and liver failure unless proper immunosuppressive treatment is performed.¹ AZA is a part of this first-line immunosuppressive therapy^{1,2} whose metabolic substance exerts an immunosuppressive effect by inhibiting the biosynthesis of nucleic acids.³ Before treatment, assessment of thiopurine S-methyltransferase (TPMT) activity and the genetic polymorphism of *NUDT15* are recommended to predict the adverse drug reaction risk of AZA.^{1,4} AZA is a prodrug of 6-mercaptopurine (6-MP) which TPMT catalyzes, and the enzyme activity of TPMT is based on genotypes.⁵ However, the evaluation of TPMT activity is considered useless for Japanese patients compared with Westerners because the frequencies of gene polymorphisms vary in different ethnic groups.⁶ Japanese individuals rarely carry the risk alleles.⁷ In contrast, the mutation of codon 139 in the *NUDT15* gene from arginine (Arg) to cysteine (Cys) has been recently reported

to be strongly associated with thiopurine-induced cytotoxicity with high sensitivity and specificity regardless of race.⁸⁻¹⁰ The *NUDT15* enzyme partly participates in the metabolism of AZA,^{3,8} and the enzyme activity is determined by the variants of the genetic polymorphism.^{3,11} Consequently, the unfavorable cytotoxic effects, including myelosuppression via inhibition of nucleic acid biosynthesis, are also strongly determined by the enzyme activity of *NUDT15*. The risk allele incidence is higher in Asians than in Europeans.¹² This mutant homozygous is found in 1% of the Japanese population.¹³ However, almost all of these precedent studies were based on cohorts of patients with inflammatory bowel disease, and only a few studies with AIH patients. Therefore, our case received the standard dose of AZA for three weeks although she only tolerated 8% of the usual amount of mercaptopurine because of a homozygous risk allele in the *NUDT15* gene.¹⁴ This significantly shows the impact of AZA treatment on AIH patients with the mutant homozygous allele of *NUDT 15*.

Second, massive hair loss and oral ulcers allow early diagnosis of this critical adverse drug reaction. Early detection of severe myelosuppression is essential because the risk of death among patients who develop AZA-induced myelotoxicity is estimated at 0.94%.¹⁵ However, this adverse reaction usually occurs within a few weeks of starting the drug.¹⁶ It is difficult to detect early unless there are frequent blood examinations. Severe early hair loss is recognized as the other typical AZA-induced adverse reaction in patients with *NUDT15* R139C.¹⁷ In contrast, little has been reported regarding severe oral ulcers as an adverse reaction of AZA. However, a similar case of AZA-induced severe pancytopenia with stomatitis¹⁸ was reported; hence, the oral mucosal reaction can also be considered as AZA-related. Both reactions are subjective;

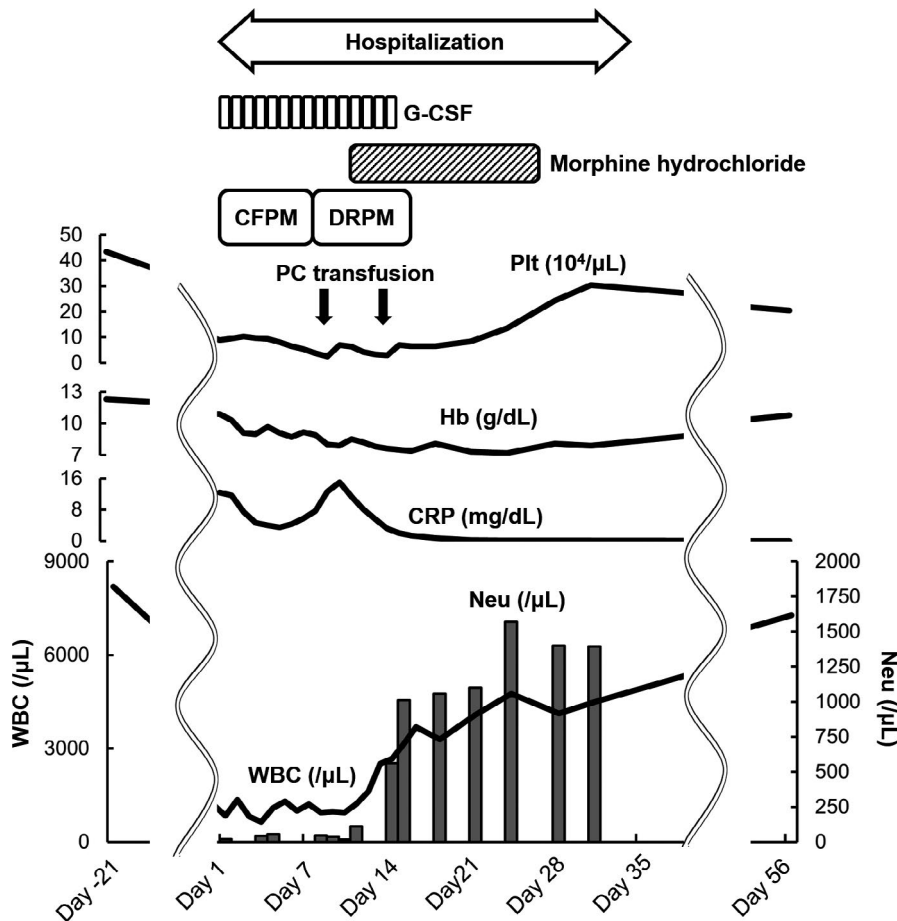


FIGURE 4 Clinical course and laboratory features of the patient. CFPM, cefepime; CRP, C-reactive protein; G-CSF, granulocyte colony-stimulating factor; DRPM, Doripenem; Hb, hemoglobin; Neu (right-hand side), neutrophil; PC, platelet concentrate; Plt, platelet; WBC, white blood cell (left-hand side)

thus, massive hair loss and oral ulcers allow early diagnosis of critical adverse reaction of AZA.

Another critical factor of our case is a drug interaction between AZA and allopurinol, which is in a class of medications called xanthine oxidase inhibitors. The blood concentration of AZA is elevated when administrated with xanthine oxidase inhibitor, which is a metabolic enzyme of 6-MP, and the adverse effects are exacerbated by the competitive drug interaction.^{19,20} Hence, a potential risk with the co-administration of these two drugs has been reported^{21,22}

In conclusion, the risk allele of the *NUDT 15* gene predicts severe myelosuppression even in AIH patients treated with AZA. Massive hair loss and stomatitis are clues to this critical adverse drug reaction.

ACKNOWLEDGMENTS

We would like to thank Enago (www.enago.com) for the English language review. Published with written consent of the patient.

CONFLICT OF INTEREST

All authors declare no conflict of interest in connection with the current study.

AUTHOR CONTRIBUTIONS

Yu Takeuchi and Hidenao Noritake: Physician of the patient and major writer of the manuscript. Moe Matsumoto and Masahiro Umemura: Physician of the patient. Maho Yamashita and Kensuke Kitsugi: Interpretation of data. Shingo Takatori and Kazuyoshi Ohta: Provision help with manuscript writing. Jun Ito and Shin Shimoyama: Provision help with graphics. Akira Kaysuya, Chiaki Maruyama, and Kensuke Fukuchi: Dermatologist of the patient. Satoshi Dohtan: Hematologist of the patient. Hiroe Sakata: Oral surgeon of the patient. Kazuhito Kawata: Manuscript revision and gave the final approval for submission. All the authors contributed to the critical review of the paper.

ETHICAL APPROVAL

The written consent was obtained from the patient ahead of submission.

DATA AVAILABILITY STATEMENT

The data that support the findings of this study are available from the corresponding author, HN, upon reasonable request.

ORCID

Hidenao Noritake  <https://orcid.org/0000-0003-3649-5335>

REFERENCES

- Mack CL, Adams D, Assis DN, et al. Diagnosis and Management of Autoimmune Hepatitis in Adults and Children: 2019 Practice Guidance and Guidelines From the American Association for the Study of Liver Diseases. *Hepatology*. 2020;1-52. doi:https://doi.org/10.1002/hep.31065
- Lohse AW, Chazouillères O, Dalekos G, et al. EASL clinical practice guidelines: autoimmune hepatitis. *J Hepatol*. 2015;63(4):971-1004. doi:https://doi.org/10.1016/j.jhep.2015.06.030
- Karran P, Attard N. Thiopurines in current medical practice: molecular mechanisms and contributions to therapy-related cancer. *Nat Rev Cancer*. 2008;8(1):24-36. doi:https://doi.org/10.1038/nrc2292
- European Association for the Study of the Liver. The European Association for the study of liver. EASL clinical practice guidelines: autoimmune hepatitis. *J Hepatol*. 2015;63:971-1004.
- Relling MV, Gardner EE, Sandborn WJ, et al. Clinical pharmacogenetics implementation consortium guidelines for thiopurine methyltransferase genotype and thiopurine dosing. *Clin Pharmacol Ther*. 2011;89(3):387-391. doi:https://doi.org/10.1038/clpt.2010.320
- Collie-Duguid ESR, Pritchard SC, Powrie RH, et al. The frequency and distribution of thiopurine methyltransferase alleles in Caucasian and Asian populations. *Pharmacogenetics*. 1999;9(1):37-42. doi:https://doi.org/10.1097/00008571-199902000-00006
- Takatsu N, Matsui T, Murakami Y, et al. Adverse reactions to azathioprine cannot be predicted by thiopurine S-methyltransferase genotype in Japanese patients with inflammatory bowel disease. *J Gastroenterol Hepatol*. 2009;24(7):1258-1264. doi:https://doi.org/10.1111/j.1440-1746.2009.05917.x
- Kakuta Y, Kinouchi Y, Shimosegawa T. Pharmacogenetics of thiopurines for inflammatory bowel disease in East Asia: prospects for clinical application of NUDT15 genotyping. *J Gastroenterol*. 2018;53(2):172-180. doi:https://doi.org/10.1007/s00535-017-1416-0
- Kakuta Y, Kawai Y, Okamoto D, et al. NUDT15 codon 139 is the best pharmacogenetic marker for predicting thiopurine-induced severe adverse events in Japanese patients with inflammatory bowel disease: a multicenter study. *J Gastroenterol*. 2018;53(9):1065-1078. doi:https://doi.org/10.1007/s00535-018-1486-7
- Walker GJ, Harrison JW, Heap GA, et al. Association of Genetic Variants in NUDT15 with Thiopurine-Induced Myelosuppression in Patients with Inflammatory Bowel Disease. *JAMA-J Am Med Assoc*. 2019;321(8):753-761. doi:https://doi.org/10.1001/jama.2019.0709
- Schaeffeler E, Jaeger SU, Klumpp V, et al. Impact of NUDT15 genetics on severe thiopurine-related hematotoxicity in patients with European ancestry. *Genet Med*. 2019;21:2145-2150. doi:https://doi.org/10.1038/s41436
- Walker RW, Belbin GM, Sorokin EP, et al. A common variant in PNPLA3 is associated with age at diagnosis of NAFLD in patients from a multi-ethnic biobank. *J Hepatol*. 2020;72(6):1070-1081. doi:https://doi.org/10.1016/j.jhep.2020.01.029
- Yang SK, Hong M, Baek J, et al. A common missense variant in NUDT15 confers susceptibility to thiopurine-induced leukopenia. *Nat Genet*. 2014;46(9):1017-1020. doi:https://doi.org/10.1038/ng.3060
- Moriyama T, Nishii R, Perez-Andreu V, et al. NUDT15 polymorphisms alter thiopurine metabolism and hematopoietic toxicity. *Nat Genet*. 2016;48(4):367-373. doi:https://doi.org/10.1038/ng.3508
- Gisbert JP, Gomollón F. Thiopurine-induced myelotoxicity in patients with inflammatory bowel disease: A Review. *Am J Gastroenterol*. 2008;103(7):1783-1800. doi:https://doi.org/10.1111/j.1572-0241.2008.01848.x
- Kim GA, Lee HC, Choe J, et al. Association between non-alcoholic fatty liver disease and cancer incidence rate. *J Hepatol*. 2018;68(1):140-146. doi:https://doi.org/10.1016/j.jhep.2017.09.012
- Kakuta Y, Naito T, Onodera M, et al. NUDT15 R139C causes thiopurine-induced early severe hair loss and leukopenia in Japanese patients with IBD. *Pharmacogenomics J*. 2016;16(3):280-285. doi:https://doi.org/10.1038/tpj.2015.43
- Jensen CH, Tiu J, Catalanotti JS. Azathioprine-induced pancytopenia with normal TPMT activity presenting with HSV oral ulcers. *BMJ Case Rep*. 2018;bcr-2018-225209. doi:https://doi.org/10.1136/bcr-2018-225209
- Logan JK, Wickramaratne Senarath Yapa S, Harinstein L, et al. Drug interaction between febuxostat and thiopurine antimetabolites: a review of the FDA adverse event reporting system and medical literature. *Pharmacotherapy*. 2020;40(2):125-132. doi:https://doi.org/10.1002/phar.2362
- Geary RB, Day AS, Barclay ML, Leong RWL, Sparrow MP. Azathioprine and allopurinol: A two-edged interaction. *J Gastroenterol Hepatol*. 2010;25(4):653-655. doi:https://doi.org/10.1111/j.1440-1746.2010.06254.x
- Kennedy DT, Hayney MS, Lake KD. Azathioprine and allopurinol: The price of an avoidable drug interaction. *Ann Pharmacother*. 1996;30(9):951-954. doi:https://doi.org/10.1177/106002809603000906
- Raman GV, Sharman VL, Lee HA. Azathioprine and allopurinol: a potentially dangerous combination. *J Intern Med*. 1990;228(1):69-71. doi:https://doi.org/10.1111/j.1365-2796.1990.tb00195.x

How to cite this article: Takeuchi Y, Noritake H, Matsumoto M, et al. Azathioprine-induced severe myelosuppression accompanied by massive hair loss and painful oral ulcer in an autoimmune hepatitis patient with *NUDT15* minor variant: A case report. *Clin Case Rep*. 2021;9:e04696. <https://doi.org/10.1002/ccr3.4696>