



Calciophylaxis and Ulcerative Lesions of Bilateral Nipple–Areolar Complex Due to Alcoholic Liver Disease

Anamika Jha¹ Shreya Shrivastav² Akhilesh K. Kasyap³

¹Department of Radiology, Institute of Medicine, Tribhuvan University Teaching Hospital, Maharajgunj, Kathmandu, Nepal

²Department of Pathology, Institute of Medicine, Tribhuvan University Teaching Hospital, Maharajgunj, Kathmandu, Nepal

³Department of Gastroenterology and Hepatology, Grande International Hospital, Dhapasi, Kathmandu, Nepal

Address for correspondence Anamika Jha, MD, Department of Radiology, Institute of Medicine, Tribhuvan University Teaching Hospital, Maharajgunj, Kathmandu 44600, Nepal (e-mail: dranamikakasyap@gmail.com).

Indian J Radiol Imaging 2022;32:142–144.

Abstract

When faced with eczematous lesions involving the nipple–areolar complex (NAC), Paget’s disease is assumed to be the diagnosis, anything else being considered a “Zebra” necessitating its exclusion on pathology. A middle-aged lady presented with synchronous asymmetrical ulceration of bilateral NAC with pleomorphic calcifications on mammography and simultaneous extensive vascular calcification in bilateral breasts that suggested systemic cause. Calciophylaxis is a rare diagnosis occurring usually due to underlying end-stage renal disease or hyperparathyroidism. There are very few case reports of calciophylaxis due to alcoholic liver disease and no cases to the best of our knowledge involving NAC. We report an extremely rare case of breast and NAC calciophylaxis due to alcoholic liver disease, highlighting need to consider benign etiology when bilateral involvement is present.

Keywords

- ▶ breast
- ▶ calciophylaxis
- ▶ nipple–areolar complex
- ▶ Paget’s disease

Key Messages

Calciophylaxis of any cause can lead to ulcerations, necrosis, and extremely rarely may present with sole breast involvement. Benign etiology and systemic cause need to be considered when bilateral nipple–areolar complex (NAC) disease is present. Tissue diagnosis is necessary to confirm the diagnosis.

more often due to benign etiology with Paget’s disease reported extremely rarely.² We discuss an extremely rare case with calciophylaxis due to underlying liver disease and sole breast involvement as benign NAC ulceration. Few cases of breast parenchymal involvement by calciophylaxis in end-stage renal disease patients have been reported; however, to the best of our knowledge, there are no cases due to underlying liver disease.

Introduction

Calciophylaxis is a rare condition with obstruction of the small and intermediate dermal arteries, leading to necrosis and ulceration of skin.¹ Bilateral eczematous lesions of NAC are

Case History

A 33-year-old thin lady was referred for mammogram from dermatology outpatient department with a history of itching, pain, ulcers, and reddish black crust formation involving

published online
May 1, 2022

DOI <https://doi.org/10.1055/s-0041-1739385>.
ISSN 0971-3026.

© 2022. Indian Radiological Association. All rights reserved.
This is an open access article published by Thieme under the terms of the Creative Commons Attribution-NonDerivative-NonCommercial-License, permitting copying and reproduction so long as the original work is given appropriate credit. Contents may not be used for commercial purposes, or adapted, remixed, transformed or built upon. (<https://creativecommons.org/licenses/by-nc-nd/4.0/>)
Thieme Medical and Scientific Publishers Pvt. Ltd., A-12, 2nd Floor, Sector 2, Noida-201301 UP, India

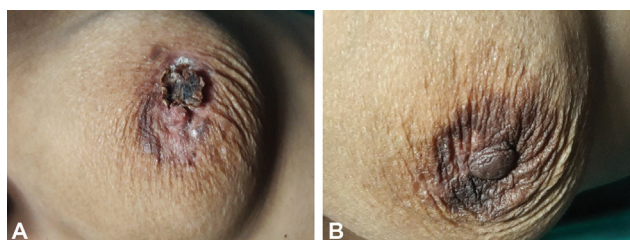


Fig. 1 Reddish black plaques and ulcerations in bilateral nipple–areolar complex, more severe in A (left side) than B (right side).

bilateral NAC, more on the left side (►Fig. 1) of 2 months duration, which was diagnosed as eczema. She was referred for imaging in view of persistent nonhealing ulcers. She did not have any other skin lesions or ulcers. Other than excess daily alcohol consumption for several years, there was no significant personal, family, or medical history.

Sonogram was nonspecific with subareolar thickening; there was no increase in vascularity and echogenic foci consistent with calcification. Her mammogram showed bilateral extensive vascular calcifications and subareolar thickening with pleomorphic microcalcification, more pronounced on the left side, appearing almost sheet like (►Fig. 2). The left nipple was not well visualized in profile in any view. Contrast-enhanced magnetic resonance imaging was normal except mild areolar enhancement and any other parenchymal lesions or in situ carcinoma were ruled out.

Considering the bilateral NAC involvement and extensive vascular calcification, systemic cause was sought and common causes of calciophylaxis, that is, hyperparathyroidism or renal disease, were ruled out. So, provisional diagnosis of Paget’s disease of breast was made and a wedge biopsy of the left areolar lesion was obtained. The pathological findings showed intact keratinized stratified squamous epithelium with ulceration, fibrinoid necrosis, and dense neutrophilic infiltrate that suggested ulcerative lesion with no features of malignancy. Following the histological diagnosis as inflammatory lesion, she was treated conservatively. About 8 months later, she presented in the emergency with anasarca and abdominal distension. Investigations revealed elevated transaminases (raised aspartate aminotransferase:

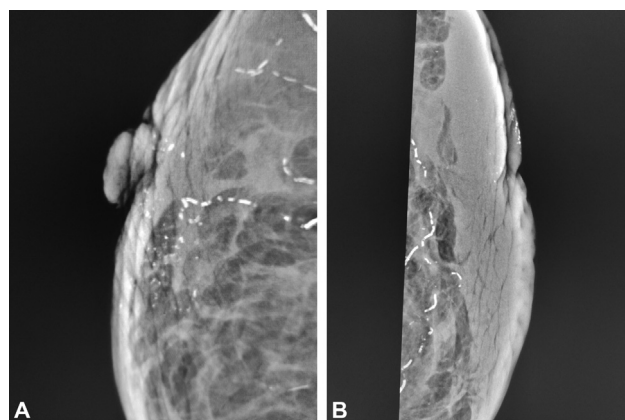


Fig. 3 Follow-up limited mammogram after 8 months, with patient in sitting position. Right (A) and left (B) craniocaudal views show diffuse subcutaneous edema and significant reduction in left areolar calcification.

alanine aminotransferase ratio) and bilirubin suggestive of alcoholic liver disease. There was gross ascites, mild bilateral pleural effusion without significant changes in liver echotexture or outline on sonography. She was managed for the acute deterioration and put on treatment for alcoholic liver disease. During the course of management in hospital, limited follow-up mammogram was done with patient in sitting position, obtaining only the craniocaudal images that showed subcutaneous edema, significant resolution of the NAC calcifications with left nipple not seen in profile (►Fig. 3). So, final diagnosis of calciophylaxis of the breasts due to alcoholic liver disease with benign ulceration of NAC, likely accentuated due to related intractable pruritus was made.

Discussion

Calciophylaxis is a rare condition that usually occurs in cases with end-stage renal disease due to obliteration of the small and intermediate sized dermal arteries and resultant ulceration. The usual sites of involvement are legs, buttocks, and abdomen with breast involvement being rare.¹ The lesions tend to be inflammatory with erythema, induration, and

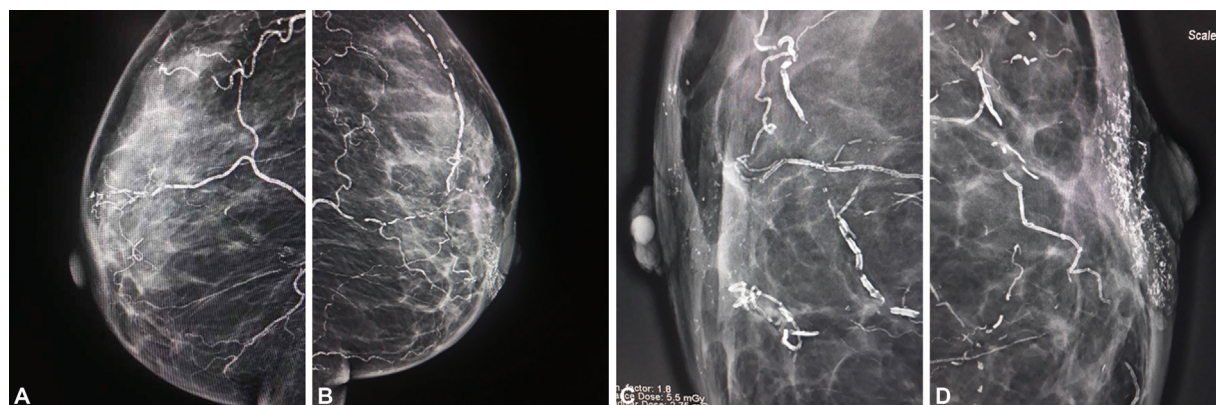


Fig. 2 Mammogram mediolateral oblique views (right [A] and left [B]) show extensive vascular calcification. Magnified craniocaudal views (right [C] and left [D]) show pleomorphic microcalcification, notable sheet like pattern, more pronounced in left areolar region. Left nipple is not well seen.

painful black-gray necrosis. Few cases of calciphylaxis in such patients involving the breast parenchyma have been reported previously.^{3,4} These tend to mimic malignancy when they present with large ulcers and biopsy is necessary to avoid undue surgeries. Uncommonly such calcification can occur due to nonrenal causes like hyperparathyroidism, liver disease, underlying malignancy, and diabetes mellitus, and is called nonuremic calciphylaxis.^{5,6} There are rare case reports of mammary calciphylaxis occurring in patients post coronary artery bypass graft and on chemotherapy.^{7,8}

While evaluating NAC calcifications, it is necessary to rule out artifacts due to application of cream or talc simulating more ominous causes of pleomorphic calcification.⁹ This can be avoided by informing the patient and requesting to wipe their breasts and axilla before the mammogram.

Skin calcifications, which may develop in Montgomery glands or hair follicles are identified by their characteristic round shapes with lucent centers that can further be confirmed on tangential views.¹⁰ Other entities like cutaneous horn and coarse calcifications due to fat necrosis secondary to trauma or previous surgery stand out due to their typically benign appearance.¹¹ Fibrocystic changes as a cause of malignant looking nipple calcifications on mammography have also been reported.¹²

Eczema, ulcers, and itching of NAC are assumed to be due to Paget's disease and should be excluded with tissue diagnosis especially when the patient does not respond to initial treatment for dermatitis. Paget's disease of breast accounts for 1 to 3% of all breast malignancies and is invariably associated with underlying masses or ductal carcinoma in situ. Ductal carcinomas may extend to involve the ducts converging at the nipple and go in to involve the contiguous epithelium of the nipple. There are extremely few reports of bilateral synchronous Paget's disease without underlying breast cancer in literature.^{2,13}

To conclude, calciphylaxis should be considered as a differential for atypical bilateral breast or NAC ulceration, reddish black crusts, and calcification along with severe parenchymal vascular calcification on mammography. This case highlights that benign etiology and systemic cause need to be considered when evaluating bilateral NAC lesions. Biopsy is necessary to rule out Paget's disease and confirm pathological diagnosis to avoid unnecessary surgery.

Authors' Contribution

Anamika Jha was involved in conceptualization, definition of intellectual contents, literature search, manuscript

preparation, and manuscript editing and review. Shreya Shrivastav was involved in conceptualization, definition of intellectual contents, literature search, and manuscript editing and review. K Akhilesh Kasyap was involved in literature search, manuscript preparation, and manuscript editing and review. Anamika Jha has provided guarantee for this manuscript.

Conflicting Interest

None.

References

- Novotny AG, Simpson AB, Kral MA, et al. Calciphylaxis of the postmenopausal female breast: an uncommonly encountered mimic of carcinoma. *Case Rep Pathol* 2017;2017:4541620. Doi: 10.1155/2017/4541620
- Xie B, Zheng H, Lan H, Cui B, Jin K, Cao F. Synchronous bilateral Paget's disease of the breast: a case report. *Oncol Lett* 2012;4(01): 83–85
- Buscher K, Gabriëls G, Barth P, Pavenstädt H. Breast pain in a patient on dialysis: a rare manifestation of calcific uraemic arteriopathy. *BMJ Case Rep* 2015;2015:bcr2014207946. Doi: 10.1136/bcr-2014-207946
- Thornton JJ, Dolph J. Breast necrosis: calciphylaxis a rare cause. *Can J Plast Surg* 2008;16(03):165–167
- Jeong HS, Dominguez AR. Calciphylaxis: controversies in pathogenesis, diagnosis and treatment. *Am J Med Sci* 2016;351(02): 217–227
- Nigwekar SU, Kroshinsky D, Nazarian RM, et al. Calciphylaxis: risk factors, diagnosis, and treatment. *Am J Kidney Dis* 2015;66(01): 133–146
- Campanino PP, Tota D, Bagnera S, et al. Breast calciphylaxis following coronary artery bypass grafting completely resolved with total parathyroidectomy. *Breast J* 2010;16(05):544–547
- Goyal S, Huhn KM, Provost TT. Calciphylaxis in a patient without renal failure or elevated parathyroid hormone: possible aetiological role of chemotherapy. *Br J Dermatol* 2000;143(05): 1087–1090
- Hogge JP, Palmer CH, Muller CC, et al. Quality assurance in mammography: artifact analysis. *Radiographics* 1999;19(02): 503–522
- Da Costa D, Taddese A, Cure ML, Gerson D, Poppiti R Jr, Esserman LE. Common and unusual diseases of the nipple-areolar complex. *Radiographics* 2007;27(1, Suppl 1):S65–S77
- Thornton CM, Hunt SJ. Sebaceous adenoma with a cutaneous horn. *J Cutan Pathol* 1995;22(02):185–187
- Chi NTB. Case report: Malignant-type calcification of the nipple with histologic correlation. *Radiol Case Rep* 2019;15(01):82–84
- Lim HS, Jeong SJ, Lee JS, et al. Paget disease of the breast: mammographic, US, and MR imaging findings with pathologic correlation. *Radiographics* 2011;31(07):1973–1987