

# Incomplete Form of Shone Complex in an Adult Congenital Heart Disease Patient

Beatrice Chia-Hui Shih, M.D., Jae Hong Lim, M.D., Jooncheol Min, M.D.,  
Eung Re Kim, M.D., Jae Gun Kwak, M.D., Ph.D., Woong-Han Kim, M.D., Ph.D.

*Department of Pediatric Thoracic and Cardiovascular Surgery, Seoul National University Children's Hospital,  
Seoul National University College of Medicine, Seoul, Korea*

Shone complex is a rare congenital disorder that involves 4 obstructive lesions of the left heart, as follows: parachute mitral valve, supra-avalvular mitral ring, subaortic stenosis, and coarctation of the aorta. Incomplete forms with 2 or 3 of these lesions in adult patients have been rarely reported in the literature, meaning that insufficient general data exist concerning the surgical strategy and clinical follow-up. Herein, we report the case of a 31-year-old woman with a diagnosis of incomplete form of Shone complex with parachute mitral valve and coarctation of the aorta who underwent successful single-stage surgical repair.

**Key words:** 1. Shone's complex  
2. Bicuspid aortic valve  
3. Parachute mitral valve  
4. Extraanatomic bypass  
5. Aortic coarctation

## Case report

A 31-year-old woman was referred to the department of cardiology with a chief complaint of palpitations and systolic hypertension of 190 mm Hg. Careful history-taking revealed that she had been diagnosed with parachute mitral valve with mild mitral regurgitation (MR) at age 15. She voluntarily stopped outpatient follow-up a year later, as no significant symptoms developed. At age 24, she was referred to a cardiologist again due to hypertension of the upper extremities. At this time, coarctation of the aorta (COA) was suspected; surgical correction was therefore recommended, but she refused to undergo an operation. It was 7 years later that she was referred to Seoul National University Children's Hospital with

a suspected diagnosis of an incomplete form of Shone complex, with mitral regurgitation and severe COA. A written informed consent was obtained from the patient.

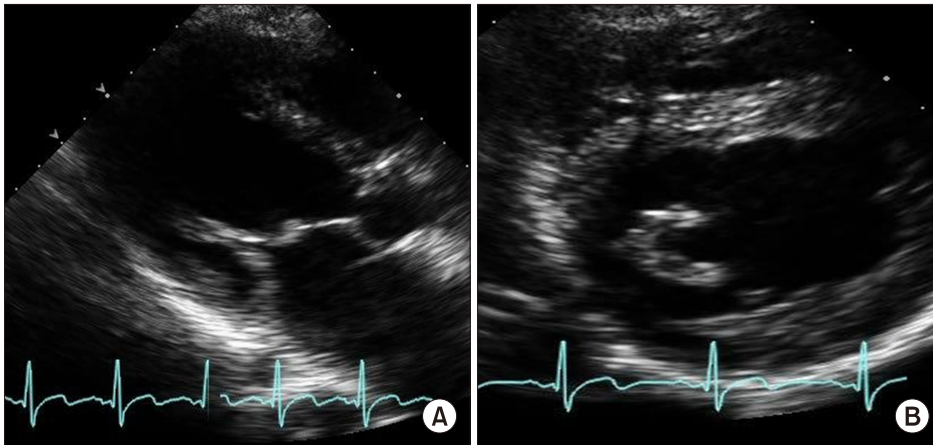
The patient showed a significant discrepancy in blood pressure (BP) between the upper and lower extremities, with an upper-limb BP of 153/84 mm Hg and a lower-limb BP of 103/72 mm Hg. She had no signs of clubbing or cyanosis. Upon auscultation, grade 1 systolic and grade 1 diastolic murmur was heard at the apex, and grade 3 short continuous murmur extended to her back. An electrocardiogram (ECG) depicted a heart rate of 90 beats/min, normal sinus rhythm, and biventricular hypertrophy with left atrial enlargement. Chest radiography showed a right hilar opacity due to a markedly enlarged left atrium,

Received: August 1, 2018, Revised: November 30, 2018, Accepted: December 3, 2018, Published online: April 5, 2019

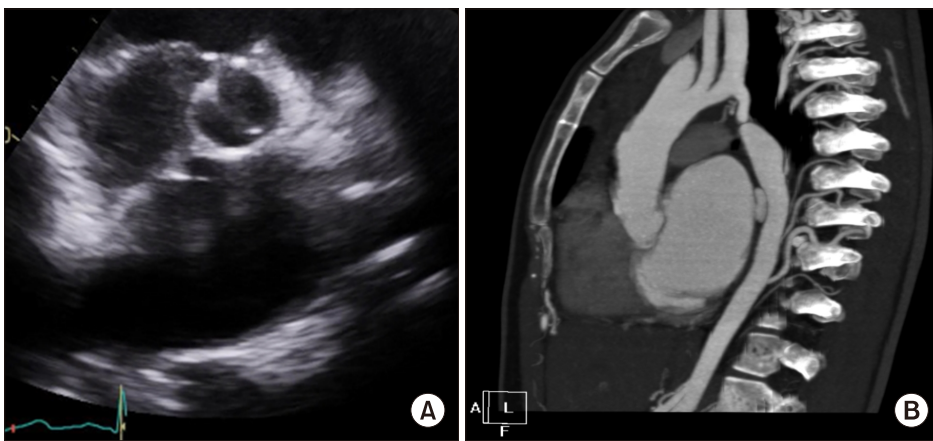
Corresponding author: Woong-Han Kim, Department of Thoracic and Cardiovascular Surgery, Seoul National University Hospital, Seoul National University College of Medicine, 101 Daehak-ro, Jongno-gu, Seoul 03080, Korea  
(Tel) 82-2-2072-3637 (Fax) 82-2-3672-3637 (E-mail) [woonghan@snu.ac.kr](mailto:woonghan@snu.ac.kr)

© The Korean Society for Thoracic and Cardiovascular Surgery. 2019. All right reserved.

© This is an open access article distributed under the terms of the Creative Commons Attribution Non-Commercial License (<http://creativecommons.org/licenses/by-nc/4.0>) which permits unrestricted non-commercial use, distribution, and reproduction in any medium, provided the original work is properly cited.



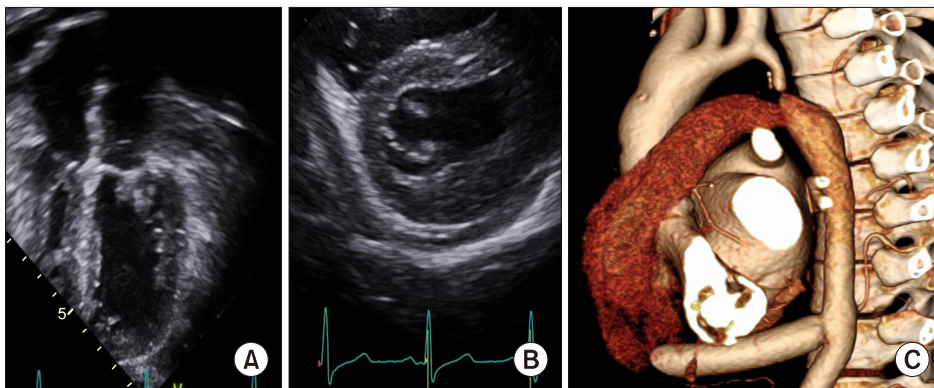
**Fig. 1.** (A) Parasternal long-axis view showing typical parachute deformity of the mitral valve. (B) Transthoracic short-axis view showing thickened chordae inserting into a single papillary muscle.



**Fig. 2.** (A) Transthoracic short-axis view showing the bicuspid aortic valve. (B) Computed tomography angiography showing the hypoplastic descending aorta and the nearly pinpoint coarctation of the aorta, juxtaductal to the left subclavian artery.

probably attributable to MR. Transthoracic echocardiography revealed a parachute-like asymmetric mitral valve with mild stenosis, yielding a transvalvular pressure gradient (PG) of 8.02 mm Hg with a peak velocity of 1.9 m/sec (Fig. 1A). Moderate regurgitation with a  $dP/dt$  of 2,805 mm Hg/sec was observed with focal prolapse of the leaflets and at the anterolateral commissure, suggesting the possibility of valve repair. The anterior and posterior leaflets were both thickened and protruded with a dome-like shape into the left ventricle, causing mitral inflow obstruction. Short bridging chordae from the anterior and posterior mitral leaflets were identified, converging together before insertion into a single solid papillary muscle (Fig. 1B). The aortic valve showed bicuspid morphology, in which the right coronary cusp and left coronary cusp were conjoined without a raphe (Fig. 2A). There was no stenosis or regurgitation across the valvular level. Both the left

ventricle and left atrium showed hypertrophy and marked enlargement, with an area of 36.83 cm<sup>2</sup>. Left ventricular function was normal, with an ejection fraction of 69.4%. The descending aorta was diffusely hypoplastic, in comparison to the ascending aorta, with a diameter of 0.83 mm. The ascending aorta was 2.01 cm in diameter, the proximal aortic arch was 1.05 cm in diameter, and the right subclavian artery was enlarged to 1.4 cm in diameter. The aortic annulus and aortic sinus were within normal ranges. There was no subaortic stenosis. Computed tomography (CT) and angiography demonstrated COA just distal to the origin of the left subclavian artery, with near total occlusion and a pinpoint opening of 0.22 cm (Fig. 2B). The descending thoracic aorta (DTA) was diffusely hypoplastic compared to the ascending aorta, and extensive secondary collateral artery hypertrophy within the mediastinum could be seen, a feature attributable to long-standing COA. All



**Fig. 3.** (A) Transthoracic apical 4-chamber view showing good mitral coaptation after mitral valve repair. (B) Short-axis view showing the split state of the papillary muscles. (C) Three-dimensional reconstruction of computed tomography angiography showing the patent and non-stenotic extra-anatomic bypass graft at the distal part anastomosing to the descending thoracic aorta.

laboratory data were within normal limits.

Based on the cardiac lesions observed in this patient, she was diagnosed with an incomplete form of Shone complex. The patient refused to undergo mitral valve replacement and to take anticoagulation or antiplatelet medications. Moreover, the patient planned marriage and pregnancy after the operation. Therefore, considering her childbearing age and because focal mitral prolapse favored repair over replacement, mitral valve repair and coarctoplasty were planned. Under general anesthesia, standard monitoring, and full median sternotomy, cannulation was performed and cardiopulmonary bypass (CPB) was established.

After full CPB had been established, the heart was retracted cephalic and superiorly using a Deaver retractor, and the retrocardiac DTA was localized by palpation. The posterior pericardium was then incised longitudinally over the aorta, just above the diaphragm level. A curved vascular clamp was used for end-to-side distal anastomosis of a 14-mm Hemashield Dacron patch (Maquet, Kehler Strasse, Germany) to the DTA using a 5-0 Prolene continuous suture. After the distal anastomosis was completed, the graft was directed to the right lateral pericardial sac, anterior to the inferior vena cava and lateral to the right atrium, and was anastomosed end-to-end to the right lateral aspect of the ascending aorta using a 5-0 Prolene continuous suture. All vascular clamps were released, and after confirming that blood flow from the ascending aorta to the DTA via the extra-anatomic graft was patent, root cannulation was performed, followed by aortic cross-clamping (ACC) and the administration of antegrade cardioplegic solution. Mitral valve exploration was done via atrial

septotomy; the mitral valve was dysplastic and the thickened leaflets were asymmetrically attached to a single papillary muscle via short chordae. After a meticulous saline test, mitral valve repair was done by splitting the solid papillary muscle and forming artificial chordae to the anterior leaflet. Unilateral annuloplasty and a coaptation suture were done at the anterolateral commissure. After the saline test, the preoperatively observed mitral regurgitation and prolapse were confirmed to have been corrected. After rewarming and de-airing, the patient was uneventfully weaned from the CPB machine. Post-CPB intraoperative transesophageal echocardiography revealed mild MR with a mean PG of 7 mm Hg and good ventricular function, and sinus rhythm was maintained. The total CPB time was 213 minutes and the total ACC time was 68 minutes.

The patient stayed in the intensive care unit for 1 day and on postoperative day 4 complained of sudden palpitations. An ECG showed atrial fibrillation with a rapid ventricular response; therefore, she was given intravenous amiodarone, digoxin, and a beta-blocker for rate control. On postoperative day 5, cardioversion was performed with 100 J and normal sinus rhythm was attained. She was discharged on postoperative day 9 with good clinical status and sustained sinus rhythm. The postoperative upper-limb BP was 87/50 mm Hg and the lower-limb BP was 93/50 mm Hg. She was seen again 2 weeks later, at our outpatient clinic, with a good general condition and maintained sinus rhythm. After 3 more serial outpatient follow-up visits at 1-month intervals, she no longer needed antiarrhythmic drugs or diuretics. Currently, she is taking only an anti-hypertensive medication along with aspirin. Regular

echocardiography and ECG have shown good ventricular function, mild MR (mean PG, 5 mm Hg), and sinus rhythm, and follow-up CT angiography also confirmed a patent extra-anatomic bypass with good distant flow (Fig. 3).

## Discussion

In 1963, Shone et al. [1] first described a developmental complex that includes multilevel obstruction due to parachute deformity of the mitral valve, supralvalvular mitral ring, subaortic stenosis, and COA. Since then, individuals with some, but not all, of the entities of the complex are referred to as having an incomplete or partial form of Shone complex. Although complete Shone complex in children is well recognized in the literature, there are few case reports of the complex diagnosed in adults. Moreover, the partial forms—characterized by 2 or 3 of the obstructive components—have rarely been reported in adults [2-4].

Variability in the clinical presentation and severity of individual lesions make appropriate management challenging, and the surgical techniques and outcomes in adult patients have not been as well investigated as in infant patients. Previous studies on Shone complex have largely focused on outcomes in infancy. Adult cases are predominantly limited to case reports, and Shone complex in adults is acknowledged as an under-recognized clinical entity [2]. The patient in our case was not diagnosed with an incomplete form of Shone complex in childhood; instead, she was only diagnosed with parachute mitral valve during adolescence. Had she undergone a thorough evaluation, COA could have been identified earlier and repair would have been possible earlier in life. Although it was fortunate that she did not have complications related to long-standing arch hypoplasia, aortic stenosis, or regurgitation, this case shows that when patients with parachute mitral valve deformity are first encountered, a thorough evaluation of other accompanying left-sided heart lesions must be undertaken.

In addition to the difficulty in determining the diagnosis, the surgical strategies for Shone complex are also challenging. In many previous studies, most patients with pediatric Shone complex underwent initial coarctation repair, followed by valve replacement or

repair. Concomitant repair of other intracardiac lesions were also done in several cases, but none underwent extra anatomic bypass for repair of arch hypoplasia, as in our case [5,6]. Extra-anatomic bypass via the posterior pericardium reduced the operative time, enabled avoiding of the unnecessary dissection of the extensively developed collateral vessels, and allowed simultaneous repair of the mitral valve [7]. To our knowledge, this is the first case of concomitant mitral repair and extra-anatomic bypass of COA in an adult patient with an incomplete form of Shone complex.

In conclusion, previous reports in the literature have described children who underwent coarctoplasty or repair in early childhood or in a staged operation, but our report is unique in that it describes a case of an incomplete form of Shone complex first diagnosed in adulthood. To date, this is the first account of concomitant repair of COA and the mitral valve via an extra-anatomic bypass graft and mitral repair in an adult. This case underscores that Shone complex is a rare and under-recognized diagnostic entity and that an aggressive diagnostic evaluation must be undertaken for patients who present with even trivial mitral valve pathology, as they could have other obstructive lesions of the left outflow tract. Only after thoroughly addressing this constellation of anomalies can appropriate reparative techniques be applied, and as in our case, replacement must be reserved when feasible for situations in which repair fails.

## Conflict of interest

No potential conflict of interest relevant to this article was reported.

## ORCID

Beatrice Chia-Hui Shih: <https://orcid.org/0000-0001-9211-0853>  
Jae Hong Lim: <https://orcid.org/0000-0002-4371-9686>  
Jooncheol Min: <https://orcid.org/0000-0001-9446-4903>  
Eung Re Kim: <https://orcid.org/0000-0002-9532-7502>  
Jae Gun Kwak: <https://orcid.org/0000-0002-6375-1210>  
Woong-Han Kim: <https://orcid.org/0000-0003-2837-7929>

## References

1. Shone JD, Sellers RD, Anderson RC, Adams P Jr, Lillehei CW, Edwards JE. *The developmental complex of "parachute mitral valve," supra-auricular ring of left atrium, subaortic stenosis, and coarctation of aorta.* Am J Cardiol 1963;11:714-25.
2. Aslam S, Khairy P, Shohoudi A, et al. *Shone complex: an under-recognized congenital heart disease with substantial morbidity in adulthood.* Can J Cardiol 2017;33: 253-9.
3. Prunier F, Furber AP, Laporte J, Geslin P. *Discovery of a parachute mitral valve complex (Shone's anomaly) in an adult.* Echocardiography 2001;18:179-82.
4. Shehatha JS, Taha AY, Mirza AJ. *Late Shone complex: a case report and literature review.* J Egypt Soc Cardiothorac Surg 2018;26:133-5.
5. St Louis JD, Bannan MM, Lutin WA, Wiles HB. *Surgical strategies and outcomes in patients with Shone complex: a retrospective review.* Ann Thorac Surg 2007;84:1357-62.
6. Grimaldi A, Vermi AC, Ho SY, et al. *Surgical outcome of partial Shone complex.* Interact Cardiovasc Thorac Surg 2012;14:440-4.
7. Connolly HM, Schaff HV, Izhar U, Dearani JA, Warnes CA, Orszulak TA. *Posterior pericardial ascending-to-descending aortic bypass: an alternative surgical approach for complex coarctation of the aorta.* Circulation 2001;104(12 Suppl 1):1133-7.