



Sleeping with the enemy: case reports of *Ornithonyssus bursa* (Berlese, 1888) (Mesostigmata: Macronyssidae) causing human dermatitis in Brazil

Ricardo Bassini-Silva^{1,2} · Ana Carolina Castro-Santiago³ · Ana Cláudia Calchi² · Livia Perles² · Julia Carvalho Takatsu¹ · Isabel D. C. C. Alencar⁴ · Ronald Ochoa⁵ · Ashley P. G. Dowling⁶ · Karin Werther² · Marcos Rogério André² · Darci Moraes Barros-Battesti² · Fernando de Castro Jacinavicius¹

Received: 21 May 2022 / Accepted: 28 June 2022 / Published online: 8 July 2022
© The Author(s), under exclusive licence to Springer-Verlag GmbH Germany, part of Springer Nature 2022

Abstract

Ornithonyssus bursa, known as the “tropical fowl mite,” is a hematophagous mite of domestic and wild birds, which occasionally bites humans. Accidental bites on humans occur mainly when abandoned bird nests are close to homes or when people are handling parasitized birds. In the present study, we describe five case reports of bites on humans and new records of localities for this species. Based on the material examined, we provide morphological and molecular characterizations for this species herein.

Keywords Tropical fowl mite · Human parasitism · Avian-mite dermatitis · Molecular analysis

Section Editor: Van Lun Low

✉ Ricardo Bassini-Silva
ricardo.bassini@gmail.com

Ana Carolina Castro-Santiago
ana_carolinacsantiago@hotmail.com

Ana Cláudia Calchi
ana.calchi@hotmail.com

Livia Perles
liviaperlesvet@gmail.com

Julia Carvalho Takatsu
takatsujulia@gmail.com

Isabel D. C. C. Alencar
idcalencar@gmail.com

Ronald Ochoa
ron.ochoa@usda.gov

Ashley P. G. Dowling
adowling@uark.edu

Karin Werther
karin.werther@unesp.br

Marcos Rogério André
mr.andre@unesp.br

Darci Moraes Barros-Battesti
barros.battesti@gmail.com

Fernando de Castro Jacinavicius
fcjacinavicius@gmail.com

- 1 Laboratório de Coleções Zoológicas, Instituto Butantan, São Paulo, SP, Brazil
- 2 Departamento de Patologia, Reprodução e Saúde Única, Faculdade de Ciências Agrárias e Veterinárias-UNESP, Jaboticabal, SP, Brazil
- 3 Departamento de Medicina Veterinária Preventiva e Saúde Animal, FMVZ-USP, São Paulo, SP, Brazil
- 4 Instituto Federal de Educação, Ciência e Tecnologia do Espírito Santo, Vitória, ES, Brazil
- 5 Systematic Entomology Laboratory, United States Department of Agriculture, Agricultural Research Service, Beltsville, MD, USA
- 6 Department of Entomology & Plant Pathology, University of Arkansas, Fayetteville, AR, USA

Introduction

The genus *Ornithonyssus* Sambon 1928 (Mesostigmata: Macronyssidae) consists of hematophagous mites that are ectoparasites of birds and small mammals, but are known to bite humans as well (Radovsky 2010).

The species *Ornithonyssus bacoti* (Hirst, 1913), *Ornithonyssus sylviarum* (Canestrini and Fanzago, 1877), and *Ornithonyssus bursa* (Berlese, 1888) are noted for their problems in public health around the world (Varma 1993; Mullen and Durden 2018; Cafiero et al. 2018). These three species have been associated to human bites, causing dermatitis, known as gamasoidosis or avian-mite dermatitis (Wambier and Wambier 2012).

In Brazil, the species that has been most frequently reported as a cause of this dermatitis is *O. bursa*, popularly known as the tropical fowl mite (Bassini-Silva et al. 2019). This species primarily inhabits bird nests and has become a concern to people in areas where birds roost on the roofs and eaves of homes, schools, hospitals, and office buildings (Haag-Wackernagel and Bircher 2005; Bassini-Silva et al. 2019; Cafiero et al. 2018). Nests become unoccupied shortly after the end of the bird's reproductive period, whereupon the starving mites move into buildings through windows, doors, and vents, biting any occupants they encounter (Oliveira et al. 2012; Bassini-Silva et al. 2019; Mesquita-Sousa et al. 2020).

The first reported case of avian-mite dermatitis caused by *O. bursa* in Brazil was in the Viamão Municipality, Rio Grande do Sul state (Ribeiro et al. 1992). Subsequently, other cases were reported and compiled by Bassini-Silva et al. (2019) to the south and southeast regions of Brazil and to the northeast of the country by Mesquita-Sousa et al. (2020) and Takatsu et al. (2021).

Here, we report five new cases of human avian-mite dermatitis caused by *O. bursa*, in new localities. Morphological and molecular characters for *O. bursa* are included, as well as a comparison was made with the main similar species, *O. sylviarum*.

Materials and methods

Material collection and identification

There have been several bites in humans caused by mites during the last few years including during the period of COVID-19-mandated restrictions. These records are based only on cases reported by people that collected the material and delivered in the animal reception system of the Instituto Butantan, São Paulo, Brazil, at which point, the

mites were handed over to the Acarological Collection of the Instituto Butantan, São Paulo, Brazil (IBSP), for examination and identification.

All specimens were stored in alcohol and a portion of the material was slide-mounted with Hoyer's medium for the identification according to Walter and Krantz (2009) and Barros-Battesti et al. (2021). The slide-mounted specimens were identified following Guimarães et al. (2001); Denmark and Cromroy (2003), and Radovsky (2007).

The images of *O. bursa* were performed using a Leica microscope DM4000B. Extended focal range images were compiled with the Leica Application Suite version 2.5.0 software at the IBSP collection. While the images of *O. sylviarum* were made using a ZEISS Axioskop 2 DIC and Phase Contrast microscope, with an attached ZEISS AxioCam ICc 5 digital camera. Extended focal range images were processed with the AxioVision SE64 Rel. 4.9.1 SP1 software at the Systematic Entomology Laboratory (BARC-USDA-ARS), Beltsville, MD, USA.

SEM micrograph of *O. bursa* was made using the low-temperature scanning electron microscopy (LT-SEM), while the SEM micrograph of *O. sylviarum* was made using the Hitachi TM3030Plus Tabletop scanning electron microscope (SEM) equipped with a Deben (UK) Coolstage at the US Department of Agriculture, Electron and Confocal Microscopy Unit, Beltsville, MD, following Dowling et al. (2010); Bolton et al. (2014); and Skvarla et al. (2021)

Molecular analysis

Part of the material stored in alcohol was submitted to DNA extraction following the manufacturer's protocols of the DNeasy Blood & Tissue Kit. The mites were individually placed in an Eppendorf microtube and punctured in the idiosomal region with a sterile needle. After the DNA extraction, the mites were recovered, slide-mounted, and accessioned as vouchers into the IBSP Collection.

In order to make the molecular identification, a conventional PCR (cPCR) targeting a ~ 500-pb fragment of the 18S rDNA ribosomal gene was performed using the primers Mite18S-1F (3'-ATATTGGAGGGCAAGTCTGG-5') and Mite18S-1R (3'-TGGCATCGTTTATGGTTAG-5') described by Otto and Wilson (2001). In addition, another PCR targeting a ~ 400-pb fragment of the 16S rDNA mitochondrial gene was performed using the following primers: 16S + 1: 3'-CTGCTCAATGATTTTTTAAATTGCTGTGG-5' and 16S - 1: 3'-CCGGTCTGAACTCAGATCAAGT-5' as described by Mangold et al. (1998). Negative (Milli-Q water free of DNA) and positive controls were used for each reaction. All PCRs were performed by a Mastercycler Gradient (Eppendorf® California, USA). PCR products with concentrations higher than 20 ng/μl were selected and purified with

ExoSap-IT (GE Healthcare Pittsburgh, PA). Sanger sequencing of the samples was performed in the “Centro de Pesquisa sobre Genoma Humano e Células Tronco do Instituto de Biociências da USP.” Obtained sequences were assembled with Sequencing Analysis 5.3.1 software and submitted to BLAST analysis (Altschul et al. 1990) in order to infer similarities with other mites available in GenBank. Different haplotypes were visually discriminated after an alignment using the CLUSTAL W algorithm (Thompson et al. 1994) implemented in Geneious R11 (Kearse et al. 2012).

Results

Morphological characterization

All specimens collected from humans had the following characteristics: *st3* setae inside the posterior corners of the sternal shield, common posterior margin of the dorsal shield with four pairs of setae, and without invaginations on the lateral distal margin of the dorsal shield (Figs. 1A, B; 2 and 3A). These characters are compatible with *O. bursa*. For comparison, we examined material identified by us as

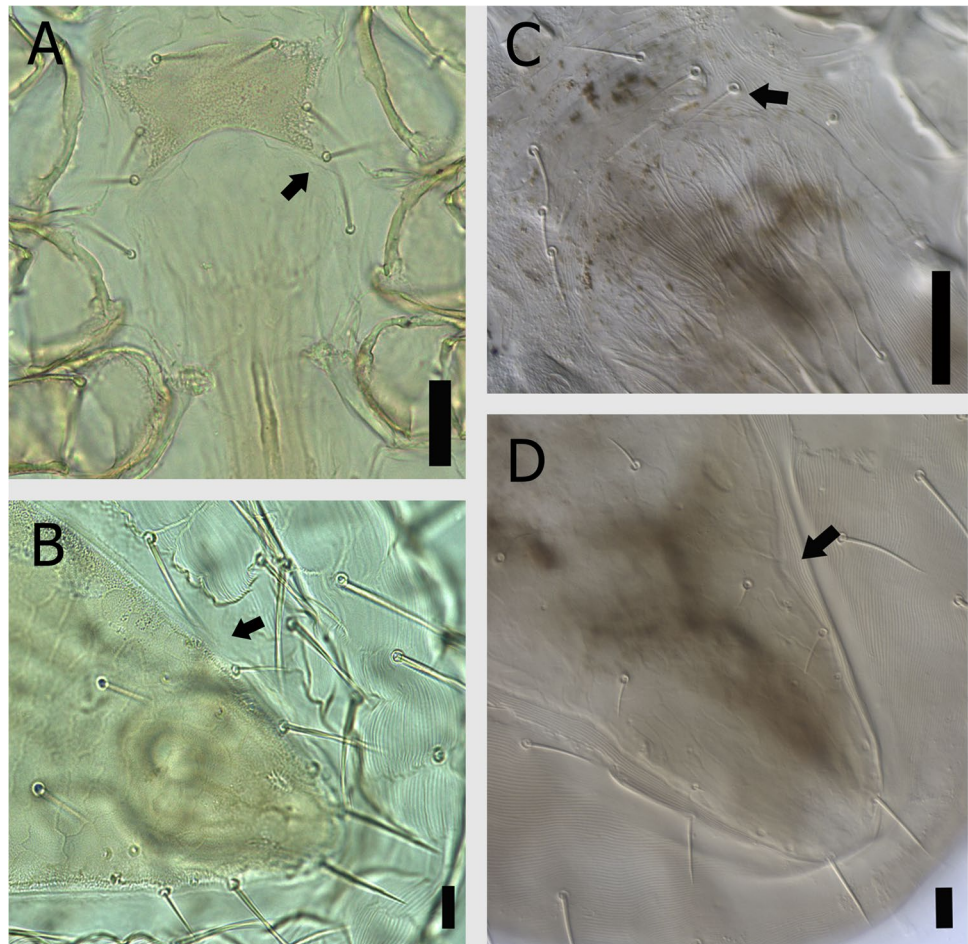
O. sylviarum collected from Ohio state, USA, parasitizing a barn swallow, *Hirundo rustica* L., 1758 (Passeriformes: Hirundinidae), and compared it with the material collected in Brazil. Unlike what was said above about *O. bursa*, *O. sylviarum* has *st3* setae outside the posterior corners of the sternal shield and the posterior margin of the dorsal shield with four pairs of setae with invaginations on the lateral borders (Figs. 1C, D and 3B). For Fig. 4, we obtained consent from all patients to publish the photos, as long as their identity was not revealed.

Molecular characterization

The recently collected material from these case reports was submitted to DNA extraction and, consequently, to cPCR targeting the molecular characterization genes (18S and 16S). We obtained a sequence of the 18S gene (GenBank accession number: OM569488) and two sequences of the 16S gene (GenBank accession number: OM569615 and OM569616). All these sequences came from the lot under the number IBSP 16,569.

BLAST comparisons of these sequences showed 99.12% (453/457-bp) of identity with homologous sequences from

Fig. 1 Comparative images of *Ornithonyssus bursa* and *Ornithonyssus sylviarum*. *O. bursa*—**A** *st3* setae inside the posterior corners of the sternal shield; **B** posterior-lateral of the dorsal shield without invaginations; *O. sylviarum*—**C** *st3* setae outside the posterior corners of the sternal shield; **D** posterior-lateral margin of the dorsal shield with invaginations. The black arrows show the *st3* setae and the different lateral distal margin of the dorsal shield. Scales: **A** and **C** 20 μ m, **B** and **D** 50 μ m



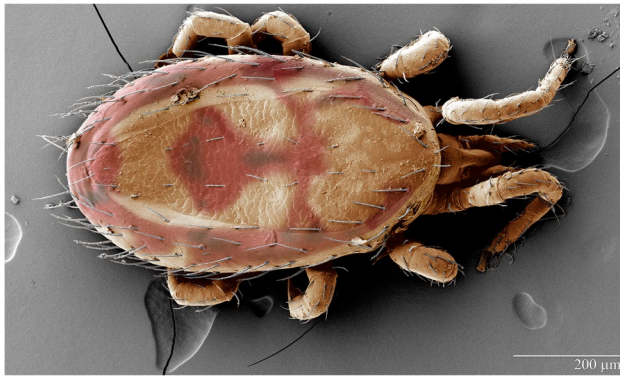


Fig. 2 Colorized LT-SEM image of the dorsal side of *Ornithonyssus bursa*

O. bursa (MT176123.1) for the gene 18S and 99.72% (362/363-bp) of identity with homologous sequences from *O. bursa* (MK131058.1) for the gene 16S.

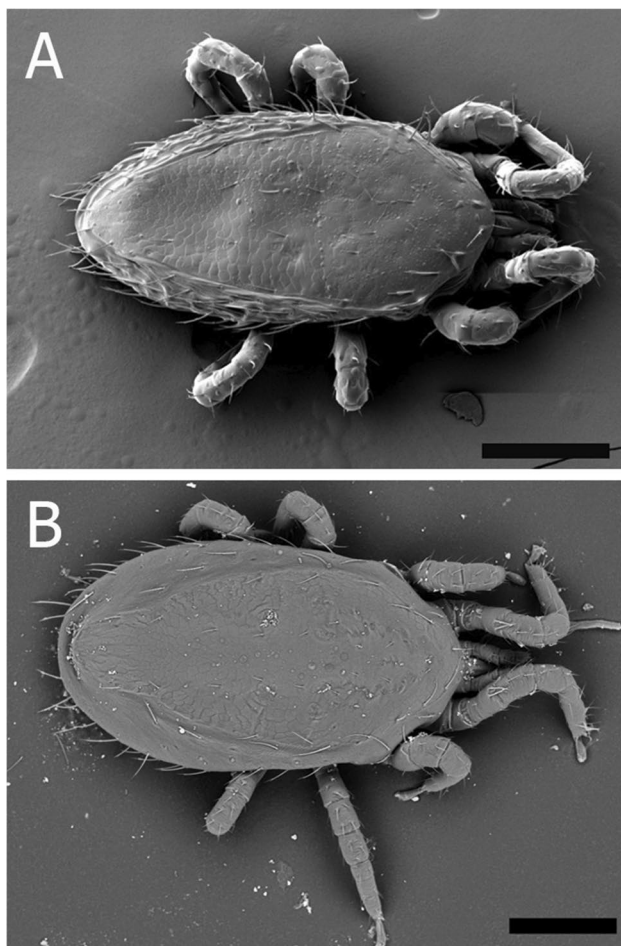


Fig. 3 *Ornithonyssus* spp. **A** LT-SEM image of the dorsal side of *Ornithonyssus bursa*; **B** table top image of the dorsal side of *Ornithonyssus sylviarum*. Scale: **A** 200 μm, **B** 150 μm

Case reports

Case 1

A 66-year-old woman, residing in an apartment on the top floor (4th floor), located in the Jardim Arpoador neighborhood, São Paulo City, São Paulo State, Brazil (46° 47' 08" W, 23° 35' 56" S), contacted the Zoonosis Control Center in the city of São Paulo. She informed them that she had lesions on her skin, resulting from the bite of mites, based on the photos of her wounds which appeared consistent with a mite bite (Fig. 4A). She was instructed to send the collected specimens to the animal reception system of the Instituto Butantan, which has one of the more complete medical and veterinary acarological collections in Latin America, to identify the specimens collected by her. The material collected on November 25, 2019, was identified as *O. bursa* and deposited under access number IBSP 16,242. The patient reported that rock doves, *Columba livia* Gmelin, 1789 (Columbiformes: Columbidae), built nests in the cracks between the wall and the roof, and when the birds left the nests, the mite infestation occurs in her apartment. She observed the mites in the house's rooms, walking on windows, doors, pillows, sheets, and blankets. The bites occurred on the chest, legs, and thighs, mainly during the night, while the woman was resting (Fig. 4A). She reported that it was possible to feel the mites walking on her face. The bites develop intense allergic reactions for 5 and 6 days and itch a lot. A topical corticosteroid with anti-inflammatory action was administered to relieve itching and inflammation. After this period, the allergy ceased without leaving marks. She mentioned that her cats' behaviors were not affected by the presence of mites and were possibly not bitten despite the massive infestation.

Case 2

During the COVID-19 pandemic, a family of 10 people isolated themselves for a few months in a country-house located at the Ortizes neighborhood, Piedade municipality, São Paulo State, Brazil (47° 21' 30" W, 23° 42' 05" S), during which time, they sustained numerous bites. In this case, plain-breasted ground-dove, *Columbina minuta* (Linnaeus, 1766) (Columbiformes: Columbidae), built nests in the house roof lining, and few days after the arrival of the family, they observed that the birds abandoned these nests (Fig. 5). Soon after members of the family felt mites walking on their skin and were bitten, causing itchy and erythematous papules on their skins. The lesions occurred on their backs, legs, waists, and arms (Fig. 4B) at night while resting on their beds and sofa. Mites were eliminated from the environment by daily cleaning with a vacuum cleaner and washing the walls and floors with soap and water for an

Fig. 4 Dermatitis caused by *Ornithonyssus bursa* on the persons that related the case reports. **A** Case 1—bites on the legs; **B** Case 2—bites in the region close to the armpits; **C** Case 3—detailed image of the bite and symptoms demonstrated on the skin; **D** Case 4—bites on the belly and upper region; **E** Case 5—reddish region developed after the bite. The black arrows show the location of the bites caused by *O. bursa*

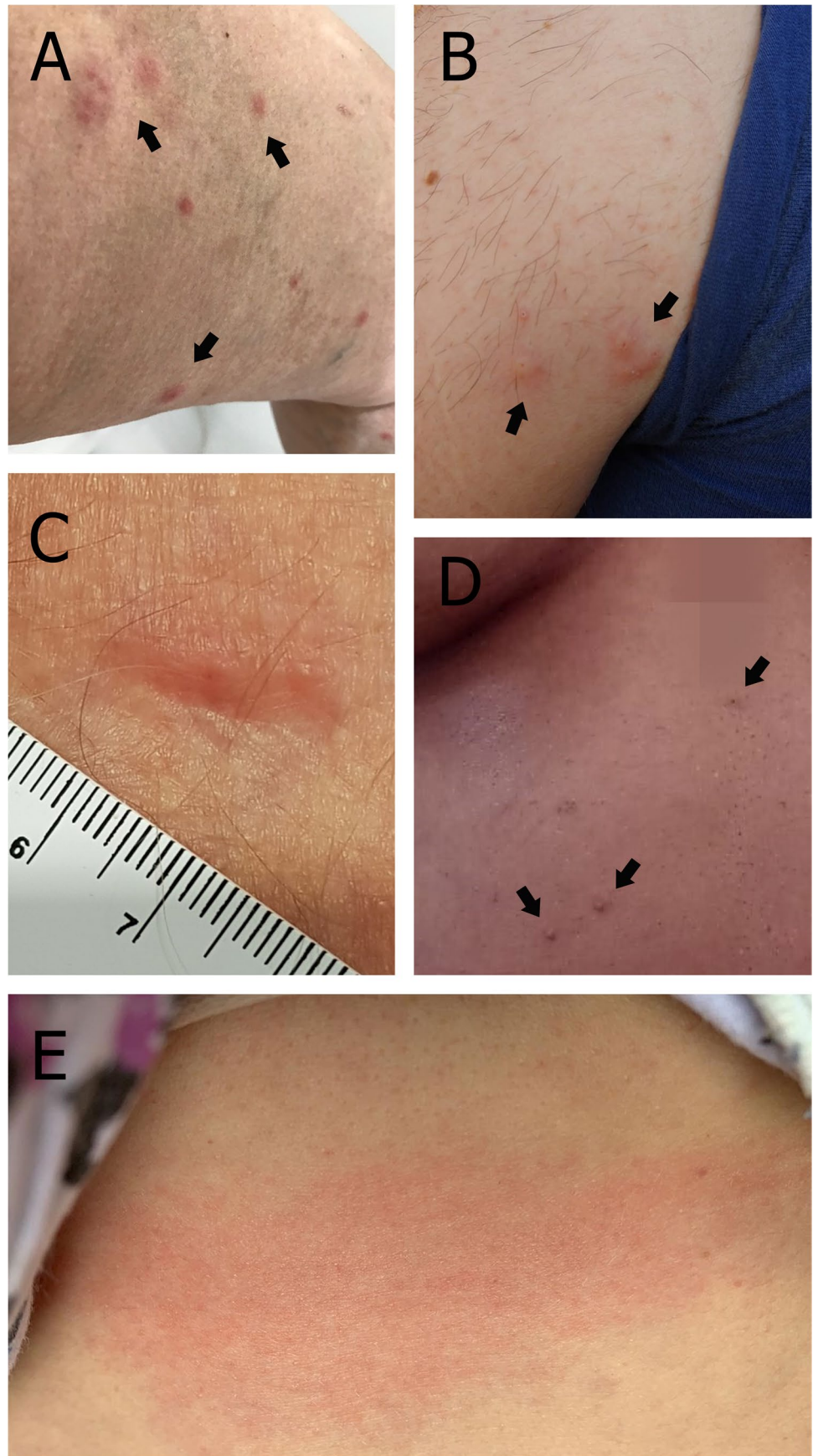




Fig. 5 Abandoned nest built in the house roof lining

entire week. The bites caused intense itching and resulted in large areas of inflamed skin lasting approximately 7 days. The patients used topical corticosteroids to relieve the itching. Two hundred specimens of *O. bursa* were collected by one member of the family on March 25, 2021, and sent to the Instituto Butantan where they were slide-mounted, voucher accession number IBSP 16,569.

Case 3

One of the co-authors noticed a mite in one of the rooms at her residence in the Jaboticabal City, São Paulo State, Brazil; she realized the mite was out of place and collected it in 70% alcohol for identification. Later the mite was identified as *O. bursa*. Her 94-year-old father reported that after he went to bed, he felt very itchy during the night. On June 06, 2021, upon arising, he had several bites on his neck, armpit, and groin regions. During that week, the co-author found more mites walking through another room, located exactly under the room where her father slept. The wounds became small sores with reddish regions spread across the skin and were painful (Fig. 4C). Topical corticosteroids were used to treat the symptoms, and within 2 days, the redness and itching disappeared. Initially, the possibility

of mosquito bites was raised, but this idea was discarded after the mite was identified. Following this finding, the role of parasitic mites associated with birds was considered because there was an abandoned bird's nest next to her father's window, three feet from where he slept. The nest was built by thrushes in the previous year and later reused by pigeons. Thrush nests are particularly characterized by having very little or no twigs in their construction. They prefer a more solid base, using plants, long sticks with branches of leaves, moist soil, and moss. In comparison, pigeon's nests are made exclusively with twigs and have a more unstable base. On this occasion, it seems the pigeon took advantage of an existing nest, building a nest of sticks/twigs on top of thrush's nest to lay its eggs. Based on the first finding in the room below the bedroom, as well as the reports of bites on the man, a general cleaning with water and soap of the room was carried out to remove any possible mites that could be present. The nest that had been kept for years was removed. The co-author reports that just getting close to the nest with her hand, the mites were already trying to reach her. It was also known there was another thrush's nest on the roof on the other side of the house which the family decided to remove, and in the act of removing it, the presence of mites was noted. In addition to removing the nests and general cleaning, steam was used where the nests were and throughout the bedroom. The mattress was removed and placed in the sun for a couple of days; afterwards, they reported that the mites could no longer be detected.

Case 4

During the Brazilian winter, around the first week of July 2021, a 25-year-old woman living in an apartment on the eighth floor in the Jaboticabal City, São Paulo State, Brazil, reported several reddish bites on the chest and abdomen skin that presented mild itching. Three days later, she felt an intensification of the bites during the night while she slept and the next day went to the city's emergency room; there she received an injection of anti-histaminic medication to relieve the intensity of the itching. After 2 weeks of treating her with a topical anti-histaminic, the itching subsided and the bites had healed although leaving papule lesions on her chest and arms (Fig. 4D). The woman was not able to collect the mites in her apartment, but shortly before the first symptoms, an employee of the university that the woman works brought in a pigeon's nest infested with the mite *O. bursa* packed in a plastic bag and left it in the work area. It is believed that these mites may have escaped from the plastic bag and come into contact with the woman's belongings such as her cell phone and backpack and thus taken into her apartment.

Case 5

A 36-year-old female biologist contacted the Butantan Institute's Laboratory of Zoological Collection (LCZ) for advice on a possible mite infestation. In the first week of January 2021, she reported many tiny whitish-yellow mites in an improvised home office in her 10th floor apartment in Serra City, Espírito Santo, Brazil (20° 13' 12" S, 40° 15' 32" W). The mites were observed on a medium-density fiberboard (MDF) background of a painting that was leaning against the sill below a window. After observing these mites, the woman cleaned the MDF and the associated furniture including placing camphor in the drawer of the table where she worked. However, in the days following, while working in the home office, she began to notice an intense and acute itching in various regions of her body, especially around her upper abdomen, neck, and breasts (Fig. 4E). She experienced increased discomfort in areas where she saw more than one mite; five mites were observed in one of the worst instances. Soon after removing the specimens, however, the acute discomfort ceased leaving only the redness. Interestingly, the woman's husband showed no similar symptoms, possibly because he had physically returned to work and did not access the home office. The woman began an intense cleaning process and to collect mites she found on her body or other objects. She took a picture of one of the mites with microscopy equipment and published the image in Acarology groups, mainly on Facebook. One of these groups alerted her that the pictured mite could possibly be associated with bird nests. Coincidentally some weeks earlier, a couple of palm tanagers, *Thraupis palmarum* (Wied, 1821) (Passeriformes: Thraupidae), began to visit her apartment. They began appearing two to three times a day on the windowsill facing the sun, especially the one in the kitchen where she and her husband began to offer bananas to the birds. The tanagers were also seen on the window of the home office room. It was through the Acarology group that someone indicated the Instituto Butantan that could receive the material and proceed with the identification and advice on the protocols to be adopted. In accordance with this advice, she collected some mites and sent them directly to the Instituto Butantan. It should be noted that while the locality of a potential tanager nest could not be confirmed, it was suspected there could be one associated with air conditioning equipment on the wall outside her apartment. Additionally, there was a known nest in the air conditioning equipment next door.

Discussion

As already discussed by Bassini-Silva et al. (2019), the correct separation of the species *O. bursa* and *O. sylviarum* is always necessary, mainly since these species are often confused in the literature and both can cause

the same dermatitis in birds and humans. In the present study, we have the opportunity to examine recent material of both species, providing comparative images for both species illustrating the main characters to separate them (Denmark & Cromroy 2003; Di Palma et al. 2012; Bassini-Silva et al. 2019), which are the different shape of the distal region of the dorsal shield and the presence of two or three pairs of setae inside the sternal shield (Figs. 1, 2, 3).

Nowadays, the number of reported cases of *O. bursa* bites in humans increased in South America (Bassini-Silva et al. 2019; Mesquita-Sousa et al. 2020; Briceño et al. 2021; Takatsu et al. 2021). We expect that due to increasing awareness, the number of reports in association with *O. bursa* will continue to rise.

Regarding the mites biting humans, all of the bites occurred at night in accordance with Radovsky (2010) that the mites are nocturnal. The five cases reported in the present study occurred in southeastern Brazil, four in the São Paulo State and one in Espírito Santo State. The south and southeast regions of Brazil have the highest frequency of human mite interactions; the frequency is lower in the northeast region with only two records so far (Mesquita-Sousa et al. 2020; Takatsu et al. 2021), and this may just be a result of under reporting.

The localities of Piedade Municipality and the Espírito Santo State are new records for *O. bursa*, and the possible associations of this species with the bird species, *C. minuta* and *T. palmarum*, are also new to science. These case reports help us know the biology and behavior of *O. bursa*, the accurate distribution in Brazil, and associations with different groups of birds of this species.

The recent material collected was submitted to DNA extraction, and we were able to obtain sequences of the gene 18S, as already reported by Bassini-Silva et al. (2019), and the first 16S gene sequences from *O. bursa* collected in Brazil. When we compare our 18S sequence with the sequences that are present in GenBank, our sequence is 98.96% (GenBank accession number: FJ91185), similar to the sequence that was obtained in the study made by Dowling and O'Connor (2010), as well as 97.11% (GenBank accession number: MG966210) and 99.12% (GenBank accession number: MT176123), similar when compared with the sequences obtained in the studies made by Bassini-Silva et al. (2019) and Briceño et al. (2021), respectively. They pointed out that the genetic variability of the studied region of the 18S and the geographic distance could explain the genetic differences. We reinforce the idea that a comparative study of different populations of *O. bursa* needs to be conducted to understand the fundamental divergence that this species has since different Brazilian populations of this mite have a divergence of almost 3%.

Acknowledgements To Gabrielle Ribeiro de Andrade and Maria Cristina Ferreira do Rosário from the Laboratório de Coleções Zoológicas, Instituto Butantan; Andrew Ulsamer and Debra Creel from the Systematic Entomology Laboratory, USDA, for technical contribution; Valeria Castilho Onofrio, for giving access to Acari Collection of the Instituto Butantan; and The Smithsonian Natural History Museum and National Agricultural Library (NAL-USDA), SEL-USDA, for support and assistance with specimens and references. Mention of trade names or commercial products in this publication is solely for purpose of providing specific information and does not imply recommendation or endorsement by the USDA; USDA is an equal opportunity provider and employer.

Author contribution RB-S, JCT, and FCJ examined and slide-mounted the material. RB-S, RO, APGD, DMB-B, and FCJ performed the study and confirmed the identification of the mites. ACC-S, ACC, LP, IDCCA, KW, and MRA made the field observations, collected samples, and helped in writing the case reports. RO and APGD revised the English of the manuscript; RB-S, MRA, DMB-B, and FCJ wrote and edited the manuscript.

Funding This work was supported by the Conselho Nacional de Desenvolvimento Científico e Tecnológico under the Grant CNPq no. 402575/2021–0 (FCJ), as well as by the Fundação de Amparo à Pesquisa do Estado de São Paulo under Grant FAPESP no. 2017/01416–7 (RB-S), 2018/24667–8 (RB-S), 2020/11755–6 (RB-S), 2021/06758–9 (ACC-S), 2020/07826–5 (ACC), 2019/15150–4 (LP), 2021/02295–4 (JCT), and 2019/19853–0 (FCJ), and the Conselho Nacional de Desenvolvimento Científico e Tecnológico for the Productivity Grant to MRA (CNPq Process #302420/2017–7) and DMB-B (CNPq Process #303802/2021–9). Besides that, this study was financed in part by the Coordenação de Aperfeiçoamento de Pessoal de Nível Superior—Brasil (CAPES)—Finance Code 001.

Data availability The data supporting the findings of this study are available within the article. All material used is housed at the Acarological Collection of Butantan Institute (IBSP) and is publicly available for examination.

Declarations

Ethics approval Not applicable.

Consent to participate and consent for publication Not applicable.

Conflict of interest The authors declare no competing interests.

References

Altschul SF, Gish W, Miller W, Myers EW, Lipman DJ (1990) Basic local alignment search tool. *J Mol Biol* 215:403–410

Barros-Battesti DM, Jacinavicius FC, Bauchan G, Bassini-Silva R (2021) Chapter 24: techniques for studies on Acariformes. In: Barros-Battesti DM, Machado RZ, André MR (Eds.), *Brazilian ectoparasite fauna of veterinary importance, Volume 1, Mite fauna of veterinary importance: Acariformes*. Jaboticabal, CBPV, p 294–303

Bassini-Silva R, Jacinavicius FC, Hernandes FA, Ochoa R, Bauchan GR, Dowling APG, Barros-Battesti DM (2019) Dermatitis in humans caused by *Ornithonyssus bursa* (Berlese 1888) (Mesostigmata: Macronyssidae) and new records from Brazil. *Rev Bras Parasitol Vet* 28(1):134–139

Bolton SJ, Klompen H, Bauchan GR, Ochoa R (2014) A new genus a species of Nematolycidae (Acari: Endeostigmata). *J Nat Hist* 48:1359–1373

Briceño C, Yévenes K, Larraechea M, Sandoval-Rodríguez A, Silveira de la Fuente MC, Fredes F, Hidalgo H, Alcayaga V, Oyarzún-Ruiz P, Munita C, González-Acuña D (2021) First record of *Ornithonyssus bursa* (Berlese, 1888) (Mesostigmata: Macronyssidae) parasitizing invasive monk parakeets in Santiago, Chile. *Braz J Vet Parasitol* 30(1):e024020

Cafiero MA, Viviano E, Lomuto M, Raele DA, Galante D, Castelli E (2018) Dermatitis due to Mesostigmatic mites (*Dermanyssus gallinae*, *Ornithonyssus [O] bacoti*, *O sylviarum*) in residential settings. *J Ger Soc Dermatol* 16(7):904–906

Denmark HA, Cromroy HL (2003) Tropical Fowl Mite, *Ornithonyssus bursa* (Berlese) (Arachnida: Acari: Macronyssidae) (Fact Sheet EENY-297). Gainesville: University of Florida Institute of Food and Agricultural Sciences. Available online at: <https://edis.ifas.ufl.edu/in575>

Di Palma A, Giangaspero A, Cafiero MA, Germinara GS (2012) A gallery of the key characters to ease identification of *Dermanyssus gallinae* (Acari: Gamasida: Dermanyssidae) and allow differentiation from *Ornithonyssus sylviarum* (Acari: Gamasida: Macronyssidae). *Parasit Vectors* 5(1):104

Dowling APG, Bauchan GR, Ochoa R, Beard JJ (2010) Scanning electron microscopy vouchers and genomic data from an individual specimen: maximizing the utility of delicate and rare specimens. *Acarologia* 50:479–485

Guimarães JH, Tucci EC, Barros-Battesti DM (2001) Ectoparasitos de importância veterinária. São Paulo, Editora Plêiade-FAPESP, pp 218

Haag-Wackernagel D, Bircher AJ (2005) Ectoparasites from feral pigeons affecting humans. *Dermatol* 220:82–92

Kearse M, Moir R, Wilson A, Stones-Havas S, Cheung M, Sturrock S, Buxton S, Cooper A, Markowitz S, Duran C, Thierer T, Ashton B, Meintjes P, Drummond A (2012) Geneious basic: an integrated and extendable desktop software platform for the organization and analysis of sequence data. *Bioinform* 28:1647–1649

Mangold AJ, Bargues MD, Mas-Coma S (1998) Mitochondrial 16S rDNA sequences and phylogenetic relationships of species of *Rhipicephalus* and other tick genera among Metastriata (Acari: Ixodidae). *Parasitol Res* 84(6):478–484

Mesquita-Sousa D, Viegas-Melo D, Martins TF, Monteiro SG, Faccini JLH, Labruna MB, Barros-Battesti DM, Bassini-Silva R, Soares AMS, Costa-Junior LM, Luz HR (2020) An overview of gamasoidosis caused by *Ornithonyssus bursa* (Mesostigmata: Macronyssidae) in Brazil and new case records. *Int J Acarol* 46(7):568–573

Mullen G, Durden L (2018) *Medical and Veterinary Entomology*, 3rd Edn. Academic Press, pp 792

Oliveira CB, Tonin AA, Monteiro SG (2012) Parasitismo do ácaro *Ornithonyssus bursa* em humanos no Sul do Brasil. *Acta Sci Vet* 40:1091

Otto JC, Wilson KJ (2001) Assessment of the usefulness of ribosomal 18S and mitochondrial COI sequences in Prostigmata phylogeny. In: Halliday RB, Walter De, Proctor HC, Norton RA, Colloff J eds. CSIRO Publishing, *Proceedings of the 10th International Congress Melbourne*, pp 100–109

Radovsky FJ (2007) A new species of *Ornithonyssus* (Acari: Macronyssidae) in western North America and a review of Nearctic species. *Int J Acarol* 33(3):223–229

Radovsky FJ (2010) Revision of genera of the parasitic mite family Macronyssidae (Mesostigmata: Dermanyssoidea) of the world. Indira Publishing House, West Bloomfield, pp 170

Ribeiro VLS, Moojen V, Telles APD (1992) Caso clínico: *Ornithonyssus bursa*: parasito de aves causando acariases cutâneas em humanos no Rio Grande do Sul. *Brasil an Bras Dermatol* 67(1):31–34

- Skvarla MJ, Ochoa R, Ulsamer A, Amrine JJr, (2021) The eriophyid mite *Aculops ailanthi* Lin, Jin, & Kuang, 1997 (Acariformes: Prostigmata: Eriophyidae) from tree-of-heaven in the United States – new state records and morphological observations. *Acarologia* 61(1):121–127
- Takatsu JC, Bassini-Silva R, Moura AP, Batista AIV, Dias GF, Pereira JS, Dowling APG, Jacinavicius F (2021) Unusual association between *Ornithonyssus bursa* (Berlese, 1888) (Mesostigmata: Macronyssidae) and *Parabuteo unicinctus* (Temminck, 1824) (Accipitriformes: Accipitridae) in Paraíba state Brazil. *Entomol Commun* 3:ec03038
- Thompson JD, Higgins DG, Gibson TJ (1994) CLUSTAL W: improving the sensitivity of progressive multiple sequence alignment through sequence weighting, positions-specific gap penalties and weight matrix choice. *Nucleic Acids Res* 22:4673–4680
- Varma MGR (1993) Ticks and mites (Acari). In: Lane RP, Crosskey RW (eds) *Medical insects and arachnids*. Chapman & Hall, London, pp 597–658
- Wambier CG, Wambier SP (2012) Gamasoidosis illustrated – from the nest to dermoscopy. *An Bras Dermatol* 87:926–927
- Walter DE, Krantz GW (2009) Chapter 7- collecting, rearing, and preparing specimens. In: Krantz GW, Walter DE (eds) *A manual of acarology*. Tech University Press, Lubbock, pp 83–96

Publisher's note Springer Nature remains neutral with regard to jurisdictional claims in published maps and institutional affiliations.