


# Revisiting Vascular Contraindications for Transoral Robotic Surgery for Oropharyngeal Cancer

Philippe Gorphe, MD, MSc ; Anne Auperin, MD, PhD; Jean-François Honart, MD, MSc;  
Jean Ton Van, MD; Sophie El Bedoui, MD, MSc; François Bidault, MD, MSc;  
Stéphane Temam, MD, PhD; Frédéric Kolb, MD, PhD; Quentin Qassemyar, MD, PhD

**Objective:** We analyzed the outcomes for patients with a retropharyngeal internal carotid artery (ICA) who underwent a transoral robotic surgery (TORS) procedure involving a cervical-transoral robotic oropharyngectomy course with free flap reconstruction.

**Methods:** Patients were included in the prospective multicentric trial NCT02517125. These patients were scheduled to undergo surgery for an oropharyngeal localization. By pre-operative CT scan and MRI it was determined that they had a retropharyngeal internal carotid artery.

**Results:** Three patients had a retropharyngeal ICA: a patient with a 35 mm synovial sarcoma of the tonsillar fossa, a patient with a T2N2b squamous-cell carcinoma (SCC) of the glossotonsillar sulcus, and a patient with a T3N0 SCC of the tonsillar fossa in a previously irradiated field. These patients encountered neither preoperative nor postoperative complications.

**Conclusions:** In our experience, TORS for oropharyngeal cancers appears to be feasible in patients with a retropharyngeal ICA, provided that the procedure has been adapted for complex situations.

**Level of evidence:** 4.

## INTRODUCTION

Transoral robotic surgery (TORS) for resection of pharyngeal tumors using the da Vinci Surgical System was first described in 2006 by Weinstein and O'Malley, after which it became rapidly adapted worldwide as an alternative to open approaches as well as to primary radiotherapy for some authors.<sup>1-6</sup> The use of the da Vinci Robot for T1 and T2 lesions was approved by the FDA in 2009, and in light of the limited size of the resection in these indications most teams allow the surgical defect to heal by secondary intentions given the good oncologic and functional outcomes that have been reported.<sup>2,7-9</sup> However, the presence of either a retropharyngeal internal carotid artery (ICA) or a vascular proximity that is likely to result in an intraoperative exposure of the carotid bulb or the ICA were initially proposed to be contraindications for TORS due to the

risk of a catastrophic vascular injury.<sup>2,10</sup> We have developed a cervical-transoral robotic oropharyngectomy approach with free flap reconstruction in our center, as a refined procedure for salvage oropharyngectomy that ensures vascular safety and optimal quality of deep margins.<sup>11</sup> We first perform dissection of the carotid artery in the parapharyngeal space through the neck approach, after which en bloc resection of the parapharyngeal space is completed in combination with the transoral robotic surgery.<sup>11</sup> The absence of complications in our experience led us to successfully extend the indications for this refined procedure to patients with a retropharyngeal ICA. In this paper we review the treatment of patients with a retropharyngeal ICA who underwent a TORS procedure. We describe the postoperative outcomes, with the aim of demonstrating the preoperative safety and feasibility of this surgical application.

## MATERIALS AND METHODS

### Patients

Patients amenable to transoral robotic oropharyngectomy in our institution are included in the still ongoing NCT02517125 phase II multicentric prospective non-randomized trial "evaluation of the contribution of transoral robotic-assisted surgery using da Vinci Xi for Head and Neck tumors" (n°ID-RCB 2015-A00173-43).<sup>12</sup> Its purpose is to evaluate TORS using the da Vinci Xi Surgical System Robot by prospectively assessing perioperative outcomes, postoperative functional results, and oncologic results. Early results regarding the feasibility and technical specificities have been published previously.<sup>12</sup> Patients included are over 18 years of age and have been treated for a histologically proven neoplasm for which the resectability has been assessed by clinical and

This is an open access article under the terms of the Creative Commons Attribution-NonCommercial-NoDerivs License, which permits use and distribution in any medium, provided the original work is properly cited, the use is non-commercial and no modifications or adaptations are made.

From the Department of Head and Neck Oncology (P.G., S.T.), the Department of Statistics (A.A.), the Department of Plastic and Reconstructive Surgery (J.-F.H., F.K., Q.Q.), and the Department of Radiology (F.B.), Gustave Roussy, Université Paris-Saclay, Villejuif, France; and the Department of Head and Neck Oncology, Oscar Lambret, Lille, France.

Editor's Note: This Manuscript was accepted for publication 1 March 2018.

Send correspondence to Dr. Philippe Gorphe, Department of Head and Neck Oncology, Gustave Roussy, 14 rue Edouard Vaillant, 94800 Villejuif, France. Email: Philippe.gorphe@gustaveroussy.fr

DOI: 10.1002/liv.2.152

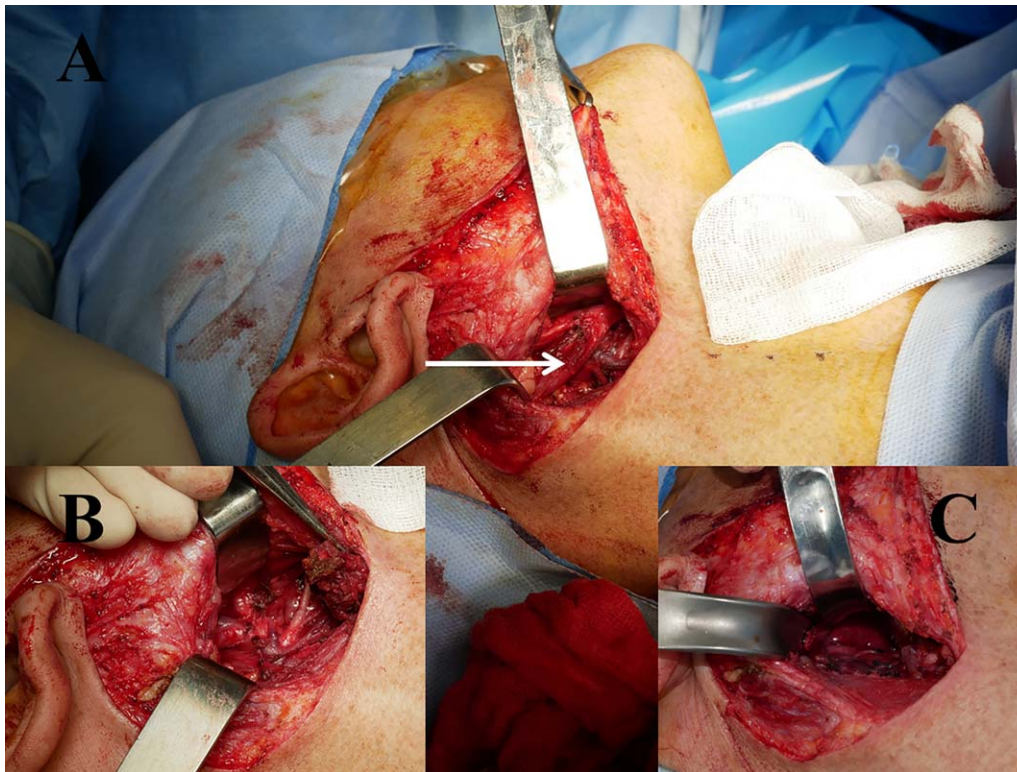


Fig. 1. Surgical neck approach for the cervical-transoral robotic oropharyngectomy procedure. After completion of the neck dissection, the posterior belly of the digastric muscle and the stylo-hyoid muscle (A, white arrow) are resected (B). The dissection of the internal carotid artery (ICA) can then readily be performed in the retrostyloid space (C), then followed along the retropharyngeal loop, and adhesions are removed. The ICA is gently pulled out, back into the parapharyngeal space, and covered with a dry white gauze pad. The procedure is continued with the transoral robotic approach.

radiological examinations. Patients with posttherapeutic progression or an early recurrence (<6 months) after a failure of radiotherapy are excluded to date. Transoral access to the tumor and the expected feasibility of transoral robotic surgery are evaluated during the initial endoscopy under general anesthesia by the senior robotic surgeon investigator using dedicated retractors. The treatment strategy is then confirmed by a head and neck oncology multidisciplinary team meeting and the patient then undergoes an inclusion consultation. The patient's consent is formally obtained, they are provided with an information leaflet, and the procedure is explained to them in person.

The patients selected for the present subgroup study underwent TORS for an oropharyngeal localization, and by preoperative computed tomography (CT) scan and magnetic resonance imaging (MRI) it was determined that they had a retropharyngeal ICA. A cervical-transoral robotic oropharyngectomy with free flap reconstruction was scheduled. A preoperative Doppler ultrasound examination of the neck vessels confirmed the suitability of microsutures for a free flap reconstruction. Patients were informed of the risk of preoperative conversion to a nonrobotic open procedure, in case of difficulty with ensuring the carotid safety.

### Procedure

We previously described and published the surgical technique for the cervical-transoral oropharyngectomy with free flap reconstruction.<sup>11</sup> After neck dissection, the posterior belly of the digastric muscle and the stylohyoid muscle are removed (Fig. 1A,B). Dissection along both the external and internal carotid arteries is then performed in the parapharyngeal space

(Fig. 1C). The internal carotid artery (ICA) is readily dissected into the retropharyngeal space and freed from adhesions and fascias. It is important to continue the dissection of the ICA above the upper part of the arterial loop until its upward turn in the parapharyngeal space. It allows the ICA to be handled carefully with a gauze pad and gently moved outward so as to be pulled out of the retropharyngeal space. A dry gauze pad is placed as high as possible on the anterior and medial sides of the ICA, a Betadin pad is placed in the neck incision, and the operative field is covered with a sterile drape. The transoral robotic oropharyngectomy is then performed according to the original surgical technique described by Weinstein and O'Malley. However, the opening of the constrictors at this stage gives immediate access to the parapharyngeal space, which has already been dissected. Therefore, the deep pole of the parotid gland can be observed immediately. The gauze pad covering the ICA can readily be identified in the surgical field (Fig. 2). As the deep margins of the resection have already been optimally dissected during the neck approach, the transoral procedure is greatly facilitated and much less onerous for the surgeon. After completion of the oropharyngeal resection with frozen sections if necessary, the size and shape of the defect that needs to be reconstructed are measured directly via the transoral route and the robot is removed.

A thin fasciocutaneous free flap is then harvested and the skin paddle is tailored to fit the defect. We have harvested a thin anterolateral thigh flap in most cases of free flap reconstruction after TORS to date (16 out of 18 patients), because of the reduced morbidity of the donor site while allowing for a very thin paddle when dissected in the plane of the superficial fascia.<sup>13</sup> The flap is inserted through the mouth and sutured to



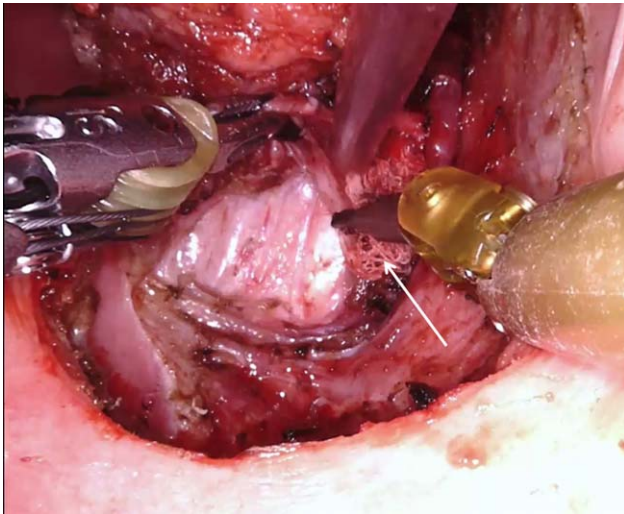

Fig. 2. Transoral robotic approach in the cervical-transoral robotic oropharyngectomy procedure. The opening of the pharyngeal constrictors shows the dry gauze pad (white arrow) that covers the internal carotid artery pulled out of the surgical field. The complete resection can be performed without any vascular danger, and the surgical bed is covered with a fasciocutaneous free flap reconstruction.

the soft palate transorally “by hand,” after which the pedicle vessels are passed through the surgical pharyngotomy. The neck incision is reopened and microanastomoses are performed as usual. Naturally, all gauze pads are removed. Toward the

end of the procedure, the robot is reinstalled to finish the transoral suture of the skin paddle, and the neck is closed.

## RESULTS

### *Patients and Preoperative Assessments*

Three patients with a retropharyngeal ICA underwent a cervical-transoral robotic oropharyngectomy with free flap reconstruction at our institution (Fig. 3 and 4). Their characteristics are listed in Table I. All of the patients had a preoperative CT scan and MRI of the head and neck regions, a chest CT scan, and a positron emissions tomography (PET) scan. The reported measurements were obtained from the head and neck CT scan. Patient number 3 had been treated 10 years prior with induction chemotherapy (two cycles of docetaxel, cisplatin, and fluorouracil) followed by concurrent chemoradiotherapy (weekly carboplatin) for a p16-positive stage T2N2cM0 squamous cell carcinoma of the ipsilateral tonsillar fossa. Of note, he now presented with a p16-negative oropharyngeal cancer and received just one cycle of induction chemotherapy only due to grade IV toxicity.

### *Preoperative Courses*

All of the patients underwent an oropharyngeal resection via a cervical-transoral robotic approach, as described above in the Materials and Methods section. In all of the patients, the resection of both the posterior

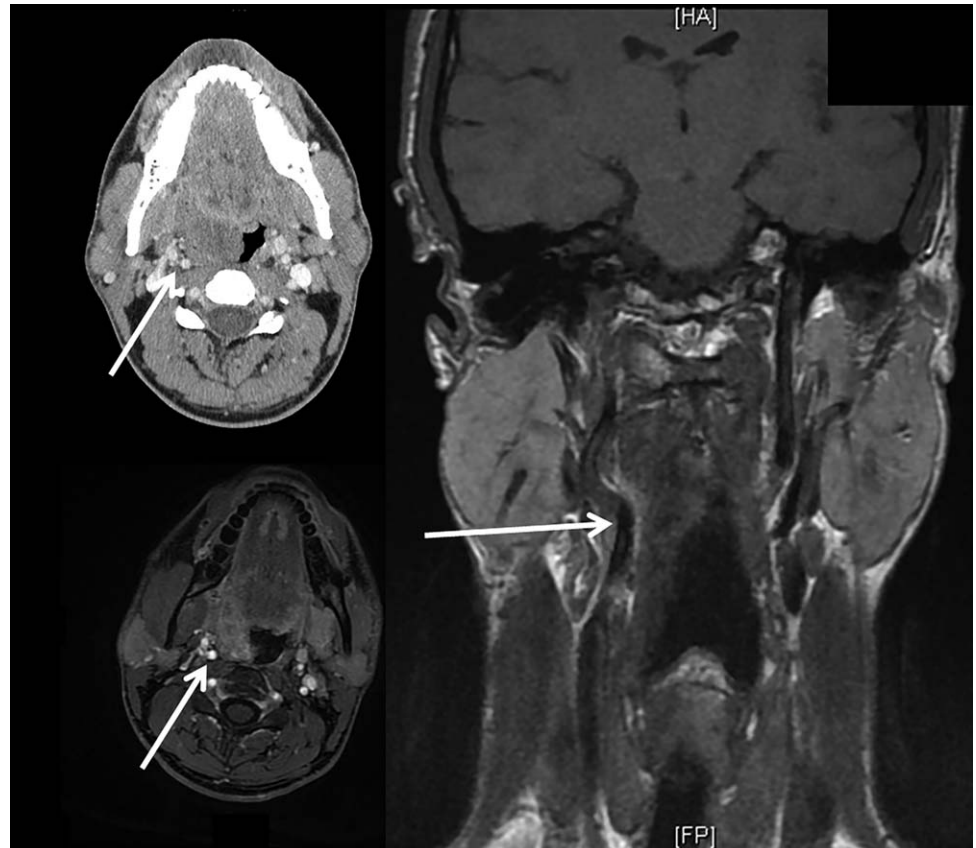


Fig. 3. Preoperative MRI and CT scan of patient number 2, who presented with a 35-mm synovial sarcoma of the right tonsillar fossa. The internal carotid artery (ICA) formed a retropharyngeal loop that made contact with the deep limits of the tumor (white arrow). The patient underwent neoadjuvant chemotherapy followed by a complete transoral robotic surgery (TORS) resection via a cervical-transoral robotic approach with a free flap reconstruction.

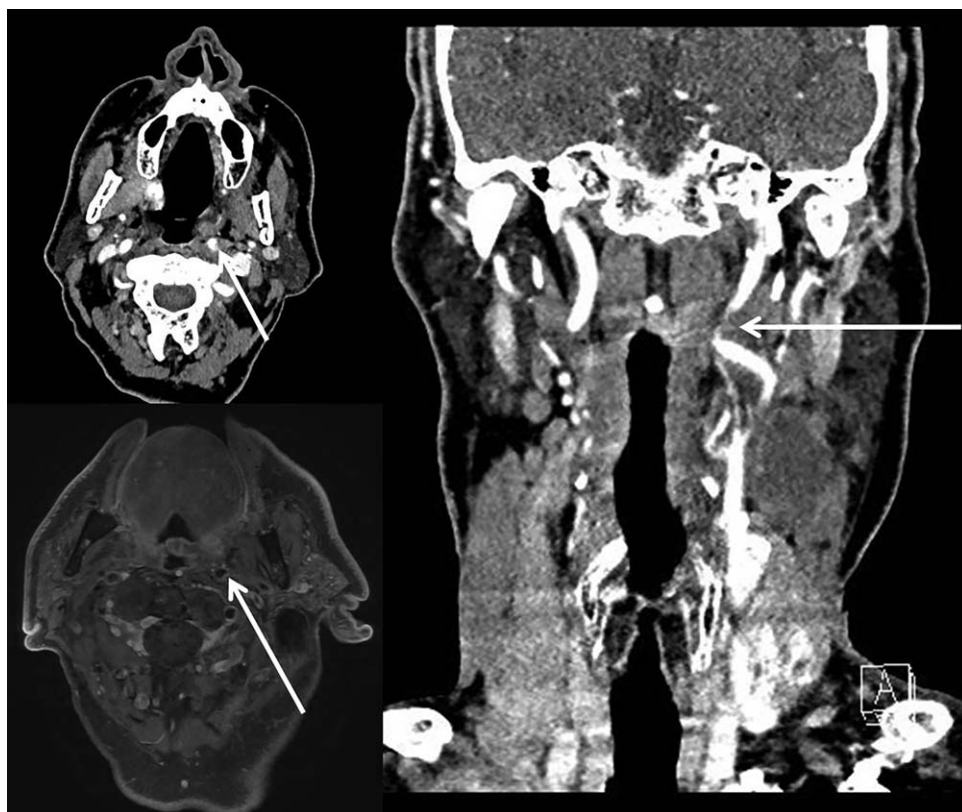


Fig. 4. Preoperative MRI and CT scan of patient number 1, who presented with a T2N2b squamous cell carcinoma of the left glosso-tonsillar sulcus. The internal carotid artery (ICA) formed a retropharyngeal loop that was in close proximity to the posterior limits of the tumor (white arrow). The patient underwent a complete transoral robotic surgery (TORS) resection via a cervical-transoral robotic approach with a free flap reconstruction.

belly of the digastric muscle and the stylohyoid muscle could readily be achieved and it allowed for dissection of the entire retropharyngeal carotid loop, which was gently pushed out into the parapharyngeal space without presenting any difficulty. In all of the patients, dissection of the external carotid artery could be readily performed up to its entry into the parotid gland. No prophylactic ligation of anterior arterial vessels (that is, the thyroid artery, lingual artery, or facial artery) was necessary for patients 2 and 3, whereas we deemed it preferable to tie the lingual artery in patient 1. Only lingual veins had to be ligatured in all patients. In all three of the patients we harvested a thin anterolateral thigh (ALT) free flap. We performed arterial anastomoses using the facial artery (n = 2) or the superior thyroid artery (n = 1), and venous anastomoses using the thyrolinguo-facial venous trunk in all of the patients.

### Postoperative Courses

A respiratory infection without hypoxemia occurred at day 3 after the surgery for patient 1, and it resolved quickly with antibiotics. This was the only complication in all three of the patients, who resumed complete oral intake soon after the surgery (Table I).

### DISCUSSION

We were able to show that TORS can be used in patients with a retropharyngeal internal carotid artery (ICA) without leading to complications, even in a previously irradiated surgical field, provided that the procedure has

been adapted for complex situations. In our opinion, the cervical-transoral robotic approach as well as the coverage by a free flap tailored to fit the defect were key aspects for a successful surgical procedure with permanent vascular safety.

A surgical approach for oropharyngeal cancer must provide surgeons with a sufficient exposure for both state-of-the-art tumor removal with safe dissection, and experience-based reconstruction that restores a satisfactory level of functions. The usual transmandibular lip-split open approach is associated with a high-quality direct visualization of oropharyngeal structures as well as the associated parapharyngeal dissection, thus permitting the surrounding nerves and vessels to be preserved as much as possible depending on the resection required.<sup>14,15</sup> However, this large open approach is associated with high rates of postoperative morbidity, which is higher still when the surgery is performed in a previously irradiated field. Infections, disfiguring scars, loss of oral continence, exposure of fixation materials, osteitis and osteonecrosis, mandibular pseudo-arthrosis, dental displacement with malocclusion, difficulties with swallowing, long-term tracheotomy, and persistent enteral nutrition are not uncommon.<sup>14,16</sup> The association of a transcervical and a transoral approach to reduce the morbidity of the surgery has already been described by several authors for resection of oropharyngeal cancers, with successful reconstruction by fasciocutaneous free flaps such as radial forearm free flaps.<sup>17</sup> To date, such limited approaches have been shown to provide good oncologic and functional results when performed in selected patients and by experienced surgeons.<sup>17</sup> Nevertheless, the

TABLE I.  
 Characteristics of Three Patients with a Retropharyngeal Internal ICA Who Underwent a TORS Procedure in Our Study via a Cervical-Transoral Robotic Approach with a Free Flap Reconstruction.

Characteristics		Patient 1	Patient 2	Patient 3
Tumor	Localization	Left glossotonsillar sulcus	Right tonsillar fossa (palatine tonsil)	Left tonsillar fossa (palatopharyngeal arch)
	Histology	p16-negative squamous-cell carcinoma	synovial sarcoma	p16-negative squamous cell carcinoma
	Irradiated field	no	no	Yes
	AJCC 7th edition Stage	T2N2bM0	NA	T3N0M0
	Maximum tumor thickness (mm)	11	21	12
	Maximum tumor size (mm)	24	35	45
Preoperative CT scan	Distance from deep tumor margin to the ICA (mm)	13	1	8
	Distance from middle to the ICA (mm)	12	15	18
Treatment	Neoadjuvant chemotherapy	no	Ifosfamid and doxorubicin, 3 cycles	Docetaxel, cisplatin, and fluorouracil 1 cycle
	Surgical procedure	Cervical-transoral oropharyngectomy	Cervical-transoral oropharyngectomy	Cervical-transoral oropharyngectomy
	Free flap	Thin ALT flap	Thin ALT flap	Thin ALT flap
	Postoperative radiotherapy	yes	yes	No
Postoperative outcomes	Potoperative complications	Respiratory infection treated with antibiotics	no	no
	Decannulation	d11	d5	d5
	Complete oral intake	d21	d7	d12

CT = computed tomography; ICA = internal carotid artery; TORS = transoral robotic surgery

advantages of transoral robotic surgery for enhancing the surgical field visualization in oropharyngeal tumors and for improving the postoperative outcomes as compared to open approaches have been confirmed by numerous authors since the first descriptions by Weinstein and O'Malley.<sup>1-4,18-20</sup> To date, a retropharyngeal ICA has, however, been considered to be a contraindication for TORS due to the risk of a catastrophic vascular injury.<sup>10,21</sup> We have developed and recently published the cervical-transoral robotic oropharyngectomy approach with free flap reconstruction as a refined procedure for complex situations such as salvage oropharyngectomy.<sup>11</sup> The goals are to ensure the vascular safety and optimal quality of deep margins, by performing the primary dissection of the internal carotid artery in the parapharyngeal space through the neck approach, then en bloc resection of the parapharyngeal space combined with the transoral robotic surgery. Irrespective of the approach used, a lateral oropharyngectomy in a patient with a retropharyngeal ICA will in fact always require a meticulous vascular dissection and will invariably result in the ICA being exposed in the surgical field after completion of the resection independently of the tumor size. Regardless of the approach, exposure of the carotid artery and creation of a large oro-cervical operative fistula will always require a surgical cover of vital structures, particularly after radiotherapy. De Almeida et al. have proposed a consensual algorithm for reconstruction decision in TORS based on a classification that takes into account the number of anatomical subsites of the oropharynx that are removed, the ICA exposure in the pharynx, a

communication with the neck, and the extent of the soft palate resection.<sup>7</sup> In fact, this algorithm could be an option for any oropharyngectomy procedure independently of the approach used, thus highlighting its relevance. We fully agree with the authors that an extended resection involving more than one anatomical subsite associated with ICA exposure is probably among the more complex situations that may be encountered (class IV) and it will require a free flap reconstruction if the patient is amenable to such a surgery. Thus, the cervical-transoral robotic oropharyngectomy with free flap reconstruction is the result of all of these experience-based principles and it benefits from the best of the knowledge of our peers. This allows TORS to be performed with permanent safety, even in patients with a retropharyngeal internal carotid artery.

## BIBLIOGRAPHY

- O'Malley BW Jr, Weinstein GS, Snyder W, Hockstein NG. Transoral robotic surgery (TORS) for base of tongue neoplasms. *Laryngoscope* 2006;116:1465-1472.
- Weinstein GS, O'Malley BW Jr, Snyder W, Sherman E, Quon H. Transoral robotic surgery: radical tonsillectomy. *Arch Otolaryngol Head Neck Surg* 2007;133:1220-1226.
- Hans S, Badoual C, Gorphe P, Brasnu D. Transoral robotic surgery for head and neck carcinomas. *Eur Arch Otorhinolaryngol* 2012;269:1979-1984.
- Hutcheson KA, Holsinger FC, Kupferman ME, Lewin JS. Functional outcomes after TORS for oropharyngeal cancer: a systematic review. *Eur Arch Otorhinolaryngol* 2015;272:463-471.
- Holsinger FC, Ferris RL. Transoral endoscopic head and neck surgery and its role within the multidisciplinary treatment paradigm of oropharynx cancer: robotics, lasers, and clinical trials. *J Clin Oncol* 2015;33:3285-3292.
- Lim GC, Holsinger FC, Li RJ. Transoral endoscopic head and neck surgery: the contemporary treatment of head and neck cancer. *Hematol Oncol Clin North Am* 2015;29:1075-1092.



7. de Almeida JR, Park RC, Villanueva NL, Miles BA, Teng MS, Genden EM. Reconstructive algorithm and classification system for transoral oropharyngeal defects. *Head Neck* 2014;36:934–941.
8. Weinstein GS, O'Malley BW Jr, Magnuson JS, et al. Transoral robotic surgery: a multicenter study to assess feasibility, safety, and surgical margins. *Laryngoscope* 2012;122:1701–1707.
9. de Almeida JR, Li R, Magnuson JS, et al. Oncologic outcomes after transoral robotic surgery: a multi-institutional study. *JAMA Otolaryngol Head Neck Surg* 2015;141:1043–1051.
10. Weinstein GS, O'Malley BW Jr, Rinaldo A, Silver CE, Werner JA, Ferlito A. Understanding contraindications for transoral robotic surgery (TORS) for oropharyngeal cancer. *Eur Arch Otorhinolaryngol* 2015;272:1551–1552.
11. Gorphe P, Temam S, Kolb F, Qassemyar Q. Cervical-transoral robotic oropharyngectomy and thin anterolateral thigh free flap. *Eur Ann Otorhinolaryngol Head Neck Dis* 2018;135:71–74.
12. Gorphe P, Von Tan J, El Bedoui S, et al. Early assessment of feasibility and technical specificities of transoral robotic surgery using the da Vinci Xi. *J Robot Surg* 2017;11:455–461.
13. Qassemyar Q, Aguilar P, Temam S, Kolb F, Gorphe P. [The thin ALT perforator flap for oropharyngeal robotic-assisted reconstruction]. *Ann Chir Plast Esthet* 2017;62:1–7.
14. Genty E, Marandas P, Beautru R, Schwaab G, Luboinski B. [Mandibulotomy for cancer of the oral cavity and oropharynx: functional and carcinologic outcome in 107 cases]. *Ann Otolaryngol Chir Cervicofac* 2001;118:26–34.
15. Chu F, Tagliabue M, Giugliano G, Calabrese L, Preda L, Ansarin M. From transmandibular to transoral robotic approach for parapharyngeal space tumors. *Am J Otolaryngol* 2017;38:375–379.
16. Singh AM, Bahadur S, Tandon DA, Pande RM. Anterior mandibulotomy for oral and oropharyngeal tumours. *J Laryngol Otol* 1993;107:316–319.
17. Roux M, Dassonville O, Ettaiche M, Poissonnet G, Sudaka A, Bozec A. Transoral-transcervical oropharyngectomy without mandibulotomy, associated to fasciocutaneous radial forearm free-flap reconstruction, for oropharyngeal cancer: Postoperative course, oncologic and functional results, and prognostic factors. *Eur Ann Otorhinolaryngol Head Neck Dis* 2017;134:71–76.
18. Chen AY. A shifting paradigm for patients with head and neck cancer: transoral robotic surgery (TORS). *Oncology (Williston Park)* 2010;24:1030,1032.
19. Weinstein GS, O'Malley BW Jr, Cohen MA, Quon H. Transoral robotic surgery for advanced oropharyngeal carcinoma. *Arch Otolaryngol Head Neck Surg* 2010;136:1079–1085.
20. White H, Ford S, Bush B, et al. Salvage surgery for recurrent cancers of the oropharynx: comparing TORS with standard open surgical approaches. *JAMA Otolaryngol Head Neck Surg* 2013;139:773–778.
21. Loevner LA, Learned KO, Mohan S, et al. Transoral robotic surgery in head and neck cancer: what radiologists need to know about the cutting edge. *Radiographics* 2013;33:1759–779.